

Letter to the Editor (Case report)

Rheumatology 2021;60:e143–e145
 doi:10.1093/rheumatology/keaa717
 Advance Access Publication 21 November 2020

A case of antisynthetase syndrome with thrombotic thrombocytopenic purpura

Rheumatology key message

- Thrombotic thrombocytopenic purpura may be a rare complication of antisynthetase syndrome.

DEAR EDITOR, Antisynthetase syndrome (AS) is a systemic autoimmune disease characterized by the presence of autoantibodies directed against aminoacyl-tRNA synthetases, most commonly anti-Jo-1 (anti-histidyl-tRNA synthetase). Clinical manifestations are variable: most commonly interstitial lung disease and inflammatory myositis, as well as arthritis, fever, mechanic's hands, and Raynaud's phenomenon [1]. Here, we report a case of anti-Jo-1 positive AS complicated by thrombocytopenic thrombotic purpura (TTP).

A 59-year-old male with a 15-pack-year smoking history presented to primary care with an 'inability to make a fist' and several weeks of pain, swelling and stiffness in both hands and wrists. His laboratory work-up was notable only for an elevated creatine kinase (CK) (4185 U/l, ref. 60–400 U/l) and elevated aminotransferases (alanine aminotransferase 72 U/l, ref. 2–60 U/l; aspartate aminotransferase 127 U/l, ref. 2–50 U/l). Out of concern for statin-induced myopathy, his atorvastatin was discontinued. However, his stiffness and weakness ultimately progressed to involve his upper arms and thighs. He also reported an intermittent dry cough with low-grade fevers.

New symptoms of haematuria (3+ blood on urinalysis, 16–25 red blood cells per high power field) and an increasingly elevated CK (7892 U/l, ref. 60–400 U/l) prompted an inpatient admission. He had bibasilar rales on auscultation and mild weakness in his upper and lower extremities, including 4/5 strength with bilateral shoulder abduction and hand grip, neck flexion and right hip flexion. Laboratory findings demonstrated thrombocytopenia (10 000/mm³, ref. 150 000–400 000/mm³), elevated lactate dehydrogenase (1008 U/l, ref. 110–210 U/l), indirect bilirubin (1.9 mg/dl, ref. 0–0.6 mg/dl), undetectable haptoglobin (ref. 30–200 mg/dl), negative direct antiglobulin (Coombs) test, low ADAMTS13 activity (11%, ref. ≥70%) and presence of ADAMTS13 inhibitor (titre of 6.7, normal <0.4). The peripheral blood smear was notable for schistocytes (Fig. 1 B). An extensive autoimmune evaluation was positive for anti-Jo-1 antibody, lupus anticoagulant and antinuclear antibody (titre of 1:640, speckled pattern from an outside lab followed

by an ANA of 1:640, homogeneous pattern at our institution) (Fig. 1 F–H), and negative for anti-double stranded DNA antibody. A muscle biopsy of the right anterolateral thigh showed necrotic fibres and patchy inflammatory infiltrates, consistent with an inflammatory myopathy (Fig. 1 C and D). A high-resolution CT of the chest showed lower lobe reticular, groundglass and consolidative opacities consistent with interstitial lung disease (Fig. 1 E). The patient was up to date with age-appropriate cancer screening, and a CT of the chest, abdomen and pelvis did not reveal any concern for an underlying malignancy.

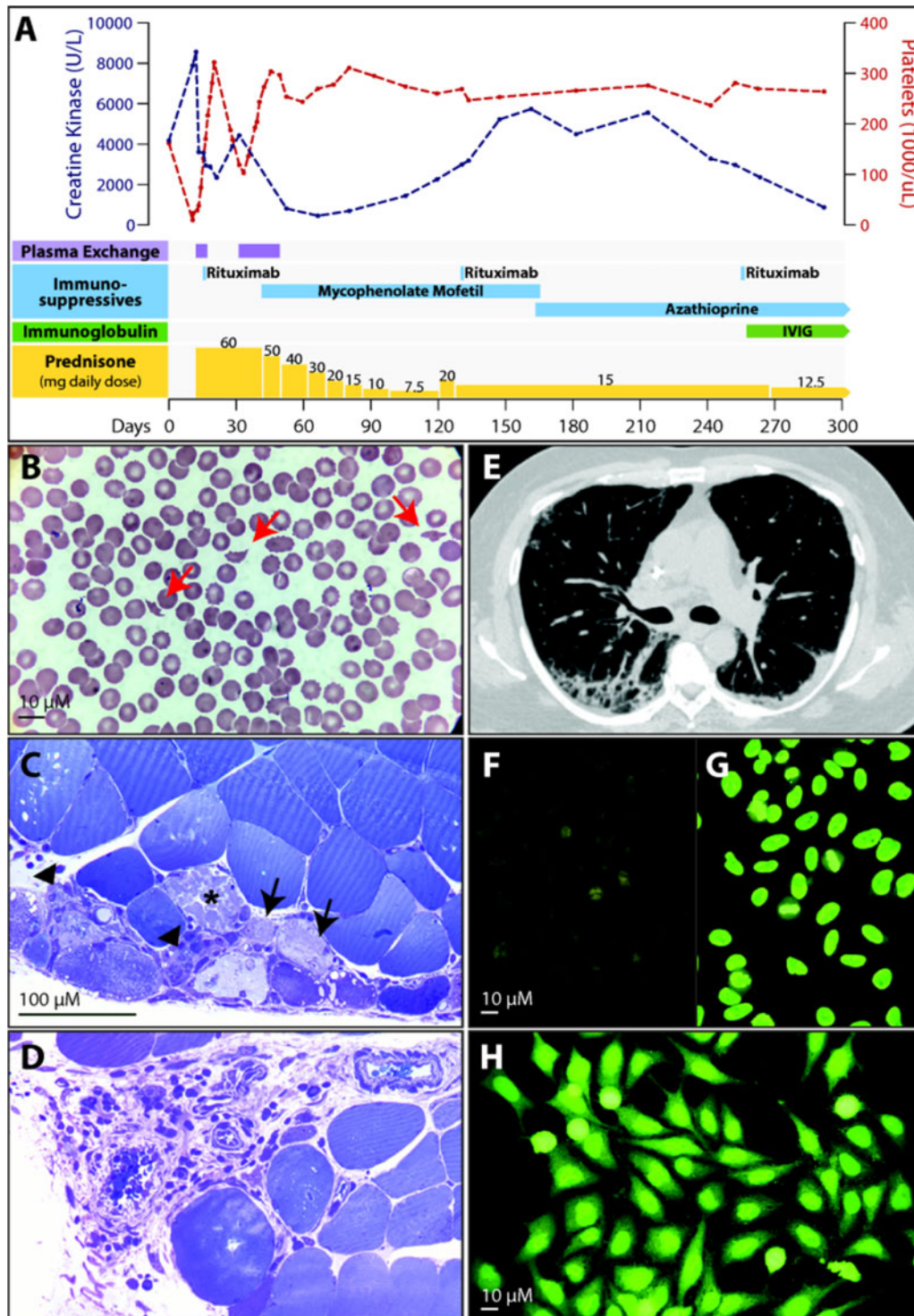
In the setting of microangiopathic haemolytic anaemia with thrombocytopenia and low ADAMTS13 activity, he was diagnosed with TTP and received emergent therapeutic plasma exchange. Given his disease severity and need for dual management of TTP and AS, he also received high-dose prednisone and up-front rituximab. His outpatient course was complicated by a relapse of TTP shortly after discharge that responded well to the resumption of plasma exchange. His CK remained persistently elevated despite treatment with prednisone and rituximab, so azathioprine and IVIG were initiated with good response (Fig. 1 A).

The classic triad of interstitial lung disease, myositis and arthritis/artralgias (all present in our patient) is considered a 'complete' presentation of AS. In one retrospective analysis of over 200 patients with anti-Jo-1 positive AS, fewer than 20% of patients had the complete triad on initial presentation [2]. Notably, anti-Ro positivity (such as the weakly positive anti-Ro52 in our patient) in anti Jo-1 positive AS is associated with a complete presentation, more severe myositis and joint involvement, malignancy and overall worse prognosis [2, 3]. Rarer complications of AS include cardiac or gastrointestinal involvement [4], though to our knowledge, there have been no reports of concomitant AS and TTP. Given the evolution of diagnostic criteria for both AS and TTP over the past few decades, including diagnostic laboratory markers such as AS antibodies and ADAMTS13 activity, these conditions may have been unrecognized and hence under-reported [1, 5].

Thrombotic microangiopathy (TMA) refers to a broad category of disorders involving microangiopathic haemolytic anaemia, thrombocytopenia and end-organ damage. TTP is a subtype of TMA caused by acquired autoantibodies that target and clear the metalloprotease ADAMTS13, whose job it is to cleave plasma von Willebrand factor (vWF). TTP and other TMAs have been documented in association with several rheumatic diseases, including SLE and much more rarely polymyositis or dermatomyositis [5, 6].

The pathogenesis of AS and TTP remains poorly understood, though one might speculate a common underlying mechanism given the autoimmune nature of

Fig. 1 Patient treatment, laboratories, peripheral blood smear, imaging, and biopsies



(A) Timeline depicting treatment regimen as well as the response of patient's platelet count (red) and creatine kinase (blue), with day 0 representing his initial presentation to primary care. (B) Peripheral blood smear ($\times 100$ magnification) demonstrating schistocytes (red arrows). (C) Muscle biopsy demonstrating necrotic fibre (*), regenerating fibre (black arrows) and fibres undergoing myophagocytosis (black arrowhead). (D) Perivascular inflammation consistent with inflammatory myopathy. (E) High-resolution CT scan of the chest demonstrating reticular opacities and traction bronchiectasis consistent with interstitial lung disease. (F) Antinuclear antibody staining (ANA) negative control; (G) homogeneous control; (H) patient sample demonstrating homogeneous nuclear staining and fine cytoplasmic granularity suggestive of a myositis pattern (titre 1:640).

both diseases and their concurrent presentation in our patient. Proinflammatory states can result in decreased vWF proteolysis, thereby increasing circulating vWF levels, such as in the case of lupus-associated TTP [6]. Among the most common clinical conditions associated with TTP are infections, autoimmune disease, various medications (i.e. mitomycin C, ciclosporin, clopidogrel) and pregnancy [7]. In the rare cases of myositis complicated by TTP or secondary TMA, an exacerbation of the myositis has often coincided with the onset of TMA, suggesting that circulating myositis-associated autoantibodies may inhibit ADAMTS13 cleaving activity [5, 8]. Our patient similarly presented initially with progressive musculoskeletal symptoms and CK elevation consistent with AS, and rapidly developed thrombocytopenia due to TTP.

In conclusion, TTP may be a rare complication of AS. Continued research into these two rare autoimmune disorders will be vital to understanding their underlying pathophysiological mechanisms and potentially overlapping aetiologies.

Acknowledgements

We would like to thank Dr. Mandakolathur Murali for his guidance and expertise in immunology, as well as the primary medical team for their thoughtful care of the patient during his inpatient admission.

Funding: No specific funding was received from any bodies in the public, commercial or not-for-profit sectors to carry out the work described in this article. N.S.B. is supported by the National Institutes of Health Ruth L. Kirschstein Institutional National Research Service Award (T32-AR-007258).

Disclosure statement: The authors declare no relevant conflicts of interest.

Ethics: The patient in this manuscript has seen the manuscript and had the Rheumatology Patient Consent Form explained to him. He has signed the form in full knowledge of how his data will be used.

Data availability statement

Not applicable.

Ashley Goreschnik¹, **Naomi Serling-Boyd**², **Miranda Theodore**², **Samantha Champion**³, **Anat Stemmer-Rachamimov**³ and **David B. Sykes**²

¹Harvard Medical School, ²Department of Medicine, Massachusetts General Hospital and ³Department of Pathology, Massachusetts General Hospital, Boston, MA, USA

Accepted 19 October 2020

Correspondence to: Ashley Goreschnik, Harvard Medical School, 25 Shattuck St, Boston, MA 02115, USA.

E-mail: Ashley_goreschnik@hms.harvard.edu

References

- 1 Witt LJ, Curran JJ, Strek ME. The diagnosis and treatment of antisyndetase syndrome. *Clin Pulm Med* 2016;23:218–26.
- 2 Cavagna L, Nuño L, Scirè CA *et al.* Clinical spectrum time course in anti Jo-1 positive antisyndetase syndrome: results from an international retrospective multicenter study. *Medicine (Baltimore)* 2015;94:e1144.
- 3 Marie I, Hatron PY, Dominique S *et al.* Short-term and long-term outcome of anti-Jo1-positive patients with anti-Ro52 antibody. *Semin Arthritis Rheum* 2012;41: 890–9.
- 4 Hervier B, Benveniste O. Clinical heterogeneity and outcomes of antisyndetase syndrome. *Curr Rheumatol Rep* 2013;15:349.
- 5 Yamada S, Yamashita H, Nakano M *et al.* Thrombotic microangiopathy with polymyositis/dermatomyositis: three case reports and a literature review. *Intern Med* 2018;57: 2259–65.
- 6 Babar F, Cohen SD. Thrombotic microangiopathies with rheumatologic involvement. *Rheum Dis Clin N Am* 2018; 44:635–49.
- 7 Joly BS, Coppo P, Veyradier A. Thrombotic thrombocytopenic purpura. *Blood* 2017;129:2836–46.
- 8 Tudorancea AD, Ciurea PL. Severe thrombocytopenia in patient with dermatomyositis. *Curr Health Sci J* 2018; 192–6.