

## Oncology

# Complete response of penile mycosis fungoides with systemic brentuximab therapy

Christian Schaufler<sup>a</sup>, Katalin Ferenczi<sup>b</sup>, Upendra Hegde<sup>c</sup>, Benjamin T. Ristau<sup>a,\*</sup>

<sup>a</sup> University of Connecticut Health Center, Division of Urology, 263 Farmington Avenue, Farmington, CT, 06030, United States

<sup>b</sup> University of Connecticut Health Center, Division of Dermatology, 263 Farmington Avenue, Farmington, CT, 06030, United States

<sup>c</sup> University of Connecticut Health Center, Division of Medicine, 263 Farmington Avenue, Farmington, CT, 06030, United States



## ARTICLE INFO

## Keywords:

Mycosis fungoides  
Brentuximab  
Anti-CD30  
Imiquimod  
Remission

## ABSTRACT

Mycosis fungoides with penile involvement is extremely rare. Previous reports have shown successful treatment with imiquimod or a combination of beam radiation and chemotherapy. We present a patient with mycosis fungoides and penile involvement. The penile lesions were initially treated with topical imiquimod; however, he developed worsening glandular lesions and discharge. Therefore the treatment was discontinued. Subsequent treatment with brentuximab (anti-CD30) targeted therapy resulted in complete resolution of the penile lesions. To our knowledge, this represents the first case of a complete penile mycosis fungoides response to brentuximab therapy. Brentuximab may be considered for refractory penile mycoses fungoides.

## Introduction

Mycosis fungoides (MF) is the predominant form of cutaneous T-cell lymphoma (CTCL) and accounts for 50–65% of cases.<sup>1</sup> MF is rare, with an incidence in the United States of only 0.3–1 cases per 100,000. MF can be identified as erythematous patches or plaques, most often in a non-sun-exposed (so-called bathing trunk) distribution. Most patients present with patches or plaques, representing early stage disease; rarely, MF can progress to more advanced stages with tumors or erythroderma.

Treatment of early stage MF commonly includes topical therapies such as corticosteroids, nitrogen mustard, phototherapy, imiquimod, retinoids and local radiation.<sup>2,3</sup> Advanced disease requires systemic treatment, such as bexarotene, methotrexate, histone deacetylase inhibitors, pralatrexate, brentuximab vedotin (anti-CD30), and/or allogeneic stem cell transplantation.<sup>2,4</sup> Early diagnosis and treatment is generally associated with a good prognosis, and 5-year survival rates approach 90%.<sup>1</sup> Penile involvement with MF is rare with only 2 cases reported in the literature.<sup>3,5</sup> We present the first report of complete response of penile MF with systemic brentuximab therapy.

## Case presentation

A 71 year old uncircumcised Caucasian male with history of diabetes mellitus and MF, presented with new onset lesions on his glans and

penile shaft. He had been originally diagnosed with MF, stage IB, in 2014. At the time of the diagnosis, he had plaques involving the lower abdomen, left flank and proximal left thigh. His lesions were initially under control with narrow-band ultraviolet therapy and methotrexate; however, 3 years later, he developed new erythematous plaques on his glans and shaft associated with a decreased urinary stream. Oral antibiotic and topical antifungal treatment provided only temporary improvement of his symptoms. He denied dysuria, penile discharge, fevers or weight loss. Physical examination demonstrated an uncircumcised penis with phimotic foreskin, a 1.5cm erythematous, nontender, mobile lesion on the right inner preputial surface, and inflammation on the glans penis surrounding the urethral meatus. There were no lesions or stricture involving the urethral mucosa. Biopsies were obtained from the abnormal areas.

Histology showed a dense mononuclear inflammatory infiltrate involving the epidermis and dermis. Numerous atypical, enlarged lymphocytes with hyperchromatic nuclei were noted in the epidermis, superficial and mid-dermis with evidence of fibroplasia (Fig. 1). The cells were predominantly CD3 positive T-cells, with rare CD30 cells. These findings were consistent with his previous biopsies and a diagnosis of MF. Following the biopsy a urethral dilation was performed, which resulted in improvement of the patient's stream.

In order to improve hygiene he underwent a circumcision, after which he developed purulent exudates on the glans penis. Topical imiquimod 5% was started; however, the patient discontinued treatment

\* Corresponding author. UConn Health – Urology Outpatient Pavilion, 7th floor 263 Farmington Avenue Farmington, CT, 06030, United States.

E-mail addresses: [Schaufler@uchc.edu](mailto:Schaufler@uchc.edu) (C. Schaufler), [Ferenczi@uchc.edu](mailto:Ferenczi@uchc.edu) (K. Ferenczi), [uhedge@uchc.edu](mailto:uhedge@uchc.edu) (U. Hegde), [benristaum@gmail.com](mailto:benristaum@gmail.com) (B.T. Ristau).

<https://doi.org/10.1016/j.eucr.2020.101460>

Received 9 October 2020; Accepted 20 October 2020

Available online 21 October 2020

2214-4420/© 2020 Published by Elsevier Inc. This is an open access article under the CC BY-NC-ND license (<http://creativecommons.org/licenses/by-nc-nd/4.0/>).

### Abbreviations

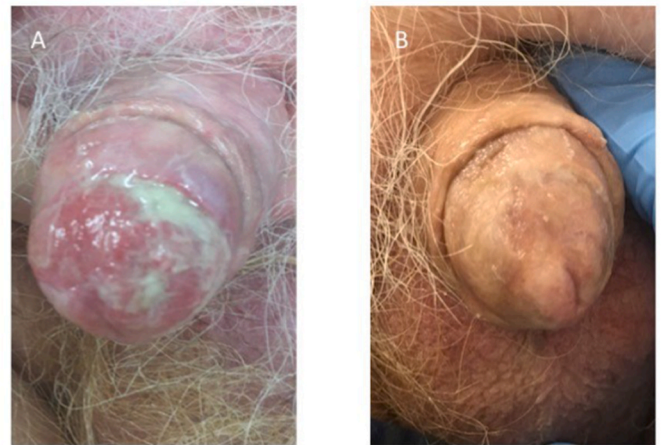
1. MF Mycosis Fungoides
2. CTCL Cutaneous T-cell lymphoma
3. CHOP Cyclophosphamide, doxorubicin hydrochloride, vincristine sulfate, prednisone

after 3 weeks due to increased purulent secretions (Fig. 2A) and further weakening of urinary stream secondary to involvement of the urethral meatus. Shortly thereafter, he presented with swelling over the left eyelid consistent with progression of MF and underwent local radiation therapy as treatment. Unfortunately, he progressed further with lesions to the right orbit, lateral mouth, and chest. At this point systemic brentuximab therapy was initiated at 1.8mg/kg every three weeks. After two infusions, the patient noted a marked improvement in his urinary stream, and physical exam demonstrated normal epidermal skin on the glans (Fig. 2B). Initial side effects of brentuximab included mild GI upset and fatigue. After 3 infusions peripheral neuropathy was noted. Treatment was discontinued after 7 infusions due to refractory neuropathy. Eight months following cessation of brentuximab infusions, no further lesions were noted on the penis. However, his disease recurred with large cell transformation, sparing the penis, while he was off treatment. The patient underwent further treatment with pralatrexate and gemcitabine, but unfortunately passed away from refractory disease 4 months after restarting chemotherapy.

### Discussion

Penile involvement in MF is rare, with only 2 case reports in the literature to date. Reports of MF of the penis have shown tissue preserving remission with immune system modifiers and combinations of electron beam radiation and chemotherapy.<sup>3,5</sup> Chiam and Chan reported a case of a 32 year old healthy man from Bangladesh with a pink plaque on the glans that had been present for 15 years.<sup>3</sup> After 6 weeks of treatment with topical clobetasol propionate, which failed to provide improvement, he was switched to 5% imiquimod. After 4–5 months of therapy the patient was in complete remission. During treatment he developed pain at the application site and a skin erosion requiring cessation of therapy. A second case reported by O'Brien et al. involved a 64 year old with an ulcer on the penile meatus.<sup>5</sup> The patient initially underwent surgical excision of the lesion, and was later treated with 15 fractions of 27 Gy radiotherapy and mini-CHOP. This combination treatment provided a complete response.

Our case is unique, as complete response of penile MF to brentuximab systemic therapy has not yet been reported. Brentuximab vedotin is an anti-CD30 monoclonal antibody that has been shown to provide

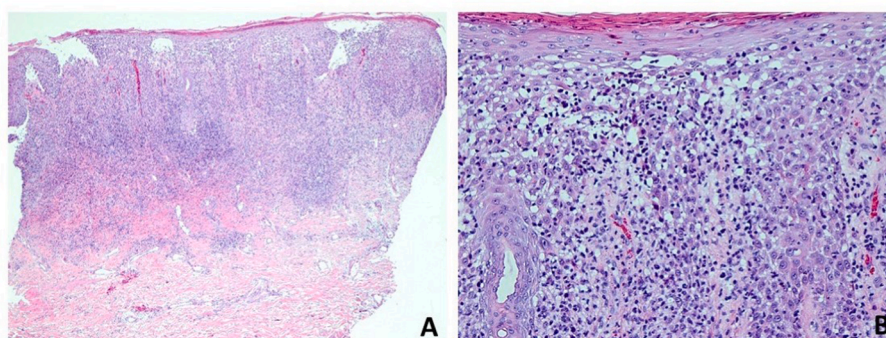


**Fig. 2.** Gross images of penile mycosis fungoides before (A) and after (B) 2 brentuximab infusions.

effective targeted therapy for cutaneous T-cell lymphomas.<sup>2</sup> Brentuximab was initially approved for the treatment of Hodgkin's lymphoma to target CD30 on Reed-Sternberg cells.<sup>4</sup> The Food Drug Administration approved its use for the treatment of patients with CTCL in 2017. Initially, it was used to treat patients with CD30 expressing CTCL, such as primary cutaneous anaplastic large cell lymphoma and CD30 expressing MF. However, Brentuximab has shown efficacy in CTCL patients with low CD30 expression, as it was the case in our patient.<sup>2</sup> Potential side effects of brentuximab therapy include neuropathy, leukopenia and fatigue.<sup>4</sup> Additionally there are multiple reports indicating that progressive multifocal leukoencephalopathy is associated with treatment. Our patient developed neuropathy leading to gait instability after 7 cycles, at which point therapy was stopped. In patients with refractory Hodgkin lymphoma, brentuximab chemotherapy is commonly followed by hematopoietic stem cell transplant.<sup>4</sup> Our patient was not a suitable candidate for stem cell transplantation due to underlying comorbidities. As brentuximab was the likely cause of the patient's neuropathy, hematopoietic stem cell transplant may have provided a more tolerable treatment.

### Conclusion

In summary, brentuximab systemic targeted therapy may be considered as a treatment option for patients with penile MF refractory to more traditional topical therapies.



**Fig. 1.** Histologic features showed a dense mononuclear inflammatory infiltrate in the epidermis and mid-dermis (A), H&E 4x; Note the presence of enlarged atypical lymphocytes with hyperchromatic nuclei in the epidermis (B), H&E, 40x.

## Consent

The patient provided consent for this case report including the use of images.

## Funding

This research did not receive any specific grant from funding agencies in the public, commercial, or not-for-profit sectors.

## Declaration of competing interest

The authors have no conflicts of interest to disclose.

## Acknowledgements

Thank you to the patient and to the supporting clinical staff.

## References

1. Amorim GM, Niemeyer-Corbellini JP, Quintella DC, Cuzzi T, Ramos-e-Silva M. Clinical and epidemiological profile of patients with early stage mycosis fungoides. *An Bras Dermatol*. 2018;93(4):546–552. <https://doi.org/10.1590/abd1806-4841.20187106>.
2. Prince HM, Kim YH, Horwitz S, et al. Brentuximab vedotin or physician's choice in CD30-positive cutaneous T-cell lymphoma (ALCANZA): an international, open-label, randomised, phase 3, multicentre trial. *Lancet*. 2017;390(10094):555–566. [https://doi.org/10.1016/S0140-6736\(17\)31266-7](https://doi.org/10.1016/S0140-6736(17)31266-7).
3. Chiam LY, Chan YC. Solitary plaque mycosis fungoides on the penis responding to topical imiquimod therapy. *Br J Dermatol*. 2007;156(3):560–562. <https://doi.org/10.1111/j.1365-2133.2006.07599.x>.
4. Ishizawa K, Yanai T. Hematopoietic stem cell transplantation and brentuximab vedotin for patients with relapsed or refractory Hodgkin lymphoma and systemic anaplastic large-cell lymphoma. *Adv Ther*. 2019;36(10):2679–2696. <https://doi.org/10.1007/s12325-019-01046-w>.
5. O'Brien JS, Manning T, Perera M, Prince HM, Lawrentschuk N. Blueprint unknown: a case for multidisciplinary management of advanced penile mycosis fungoides. *Can J Urol*. 2017;24(6):9139–9144. <http://www.ncbi.nlm.nih.gov/pubmed/29260643>. Accessed October 30, 2019.