

Contents lists available at [ScienceDirect](http://www.sciencedirect.com)

## International Journal of Surgery Case Reports

journal homepage: [www.casereports.com](http://www.casereports.com)

# Primary signet ring cell carcinoma of the cervix: A case report and review of the literature

Veysel Sal<sup>a</sup>, Ilker Kahramanoglu<sup>a,\*</sup>, Hasan Turan<sup>a</sup>, Nedim Tokgozoglu<sup>a</sup>, Tugan Bese<sup>a</sup>, Ovgu Aydin<sup>b</sup>, Fuat Demirkiran<sup>a</sup>, Macit Arvas<sup>a</sup>

<sup>a</sup> Department of Obstetrics and Gynecology, Division of Gynecologic Oncology, Cerrahpasa Medical Faculty, Istanbul University, Turkey

<sup>b</sup> Department of Pathology, Cerrahpasa Medical Faculty, Istanbul University, Turkey

## ARTICLE INFO

### Article history:

Received 20 January 2016

Received in revised form 27 January 2016

Accepted 1 February 2016

Available online 6 February 2016

### Keywords:

Signet cell

Primary

Cervical

Immunohistochemical

Cytokeratin

## ABSTRACT

**INTRODUCTION:** Primary signet cell carcinoma of the cervix has been reported only in 18 cases to date. **PRESENTATION OF CASE:** A 48-year-old woman was seen at our Gynecologic Oncology Unit, because she complained postcoital bleeding during the last three months. She had 1–2 cm cervical mass, originating from the endocervical canal. A biopsy revealed a signet ring cell-type adenocarcinoma. Suspected primary sites were excluded after gastroscopy, colonoscopy and mammography. The patient underwent a laparoscopic type-3 radical hysterectomy with bilateral salpingo-oophorectomy, pelvic lymph node dissection and paraaortic lymph node dissection with a presumed diagnosis of primary signet ring cell carcinoma of the cervix. Microscopically, the tumour consisted of 70% signet ring cell type and 30% endocervical adenocarcinoma. She did not receive any adjuvant treatment. Follow-up at 18 months after surgery showed no evidence of recurrence.

**DISCUSSION:** Nineteenth case of a primary signet ring cell carcinoma of the cervix was presented. Immunohistochemical studies and HPV DNA positivity may help in diagnosis.

**CONCLUSION:** It is crucial to differentiate primary tumour from metastatic signet cell carcinoma, while treatment and prognosis differ significantly.

© 2016 The Authors. Published by Elsevier Ltd. on behalf of IJS Publishing Group Ltd. This is an open access article under the CC BY-NC-ND license (<http://creativecommons.org/licenses/by-nc-nd/4.0/>).

## 1. Introduction

Pure or predominantly signet-ring cell carcinoma of the cervix is extremely rare in the literature. In total, 18 cases of primary cervical adenocarcinoma containing signet-ring cells have been reported to date [1]. The infrequency with which it is encountered makes primary signet-ring cell carcinoma of the cervix a diagnostic challenge. Possible metastasis from any site should be excluded, as management and prognosis vary between metastatic and primary signet ring cell carcinomas of the cervix.

Herein, we report a case of primary predominantly signet ring cell carcinoma of the cervix with immunohistochemical findings and review the literature.

## 2. Case report

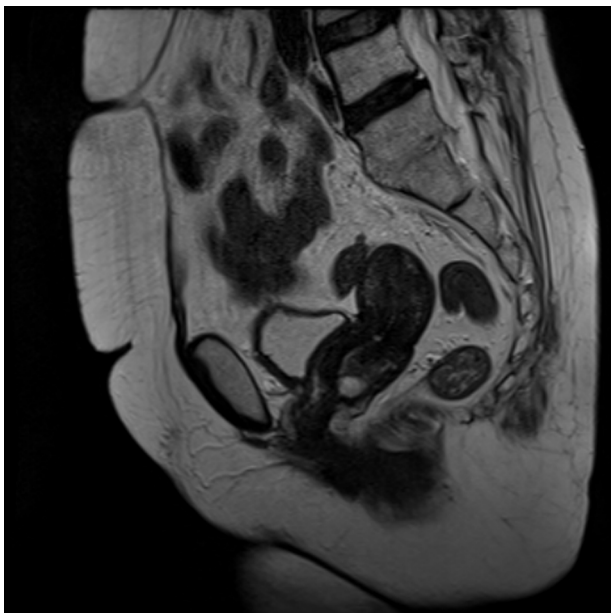
A 48-year-old, gravida 5, para 3 woman with post-coital vaginal bleeding during the last 3 months was seen in our hospital. Her body mass index was 24 and she had no significant

medical or family history. A pelvic examination revealed a 1–2 cm cervical mass, which appeared to originate from endocervical canal. A biopsy revealed a signet ring cell-type adenocarcinoma. Laboratory studies, including cancer antigen 125 (CA-125), carcinoembryonic antigen (CA 19-9), cancer antigen 15-3 (CA 15-3), carcinoembryonic antigen (CEA), and alpha-fetoprotein (AFP), were within normal limits. Magnetic resonance imaging (MRI) showed a 1.7 × 1.5-cm cervical mass with a homogeneous intensity on T1-weighted images and a heterogeneous intensity on T2-weighted images (Fig. 1). Increased FDG uptake on the positron emission tomography (PET)/computed tomography (CT) images were found for the cervical mass (SUVmax: 13.5). A gastroscopy and colonoscopy were performed to reveal the possible primary site of the tumour, however, both did not the site. In addition, her preoperative mammogram was negative. The patient underwent a laparoscopic type-3 radical hysterectomy with bilateral salpingo-oophorectomy, pelvic lymph node dissection and paraaortic lymph node dissection with a presumed diagnosis of primary signet ring cell carcinoma of the cervix. There was no pathologic finding in the pelvic cavity or abdomen.

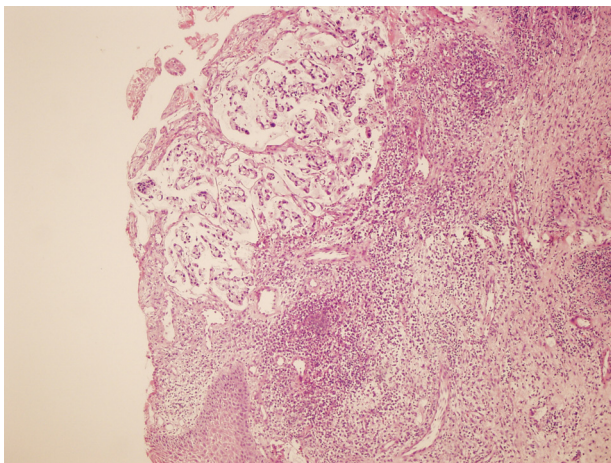
Macroscopically, tumour measured 25 × 18 × 13 mm in size and it was located in ecto- and endocervix. Microscopically, the tumour consisted of 70% signet ring cell type and 30% endocervical adenocarcinoma. Signet ring cells were within pools of extracellular

\* Corresponding author at: Cerrahpasa Medical Faculty, Department of Obstetrics and Gynecology, Division of Gynecologic Oncology Fatih, Istanbul, Turkey.

E-mail address: [ilkerkahramanoglu@hotmail.com](mailto:ilkerkahramanoglu@hotmail.com) (I. Kahramanoglu).



**Fig. 1.** (A) 1.7 × 1.5-cm cervical mass with a homogeneous intensity on T1-weighted images and a heterogeneous intensity on T2-weighted images on posterior cervix.



**Fig. 2.** The tumor was located in ecto-endocervix. HE X50.

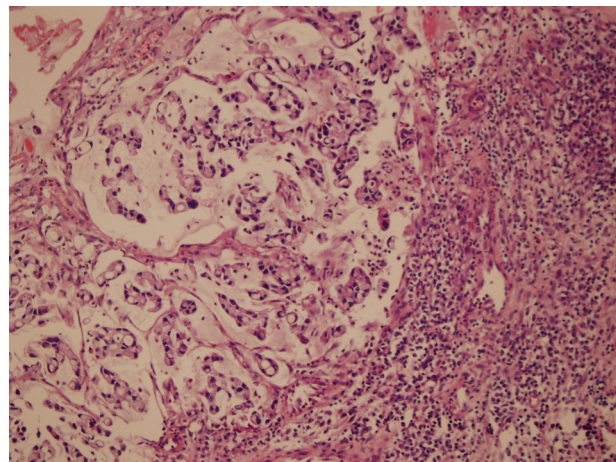
mucin (Figs. 2 and 3). The tumour cells had hyperchromatic, eccentrically located nuclei and large mucin filled cytoplasmic vacuoles. An immunohistochemical study of the tumour showed positivity for p16 (Fig. 4), CDX-2, MUC1, MUC2 and MUC5AC and negativity for synaptophysin, chromogranin A and CK-20. The parametrium, pelvic and paraaortic lymph nodes were negative and no lympho-vascular space invasion was observed.

The patient did not receive postoperative chemotherapy. Follow-up at 18 months after surgery showed no evidence of recurrence.

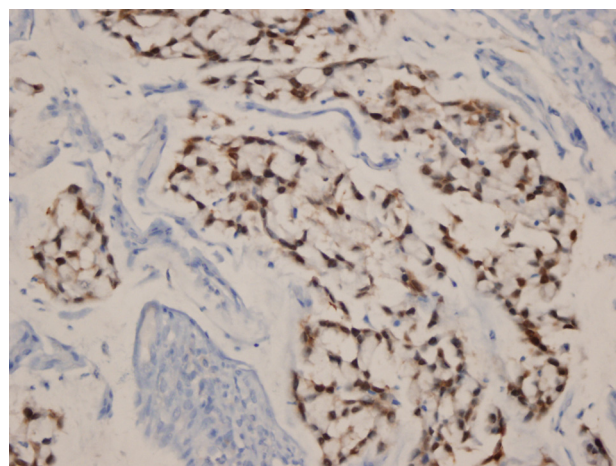
Written informed consent was obtained from the patient to publish these data.

### 3. Discussion

Previous cases of primary signet-ring cell carcinoma of the cervix are presented in Table 1. It is essential to distinguish a primary tumour from metastasis when there are signet ring cells in a carcinoma within cervix. The stomach, colon, breast, appendix, bladder are possible primary sites for metastasis [1]. Therefore,



**Fig. 3.** The tumor was composed of signet ring cells within pools of extracellular mucin. HE ×200.



**Fig. 4.** The nuclei of tumor cells were diffusely positive for p16. p16 ×400.

further evaluations for other primary sites are mandatory to exclude metastasis. In addition, an earlier report described some features in favour of a primary cervical tumour such as a history of HPV infection, the coexistence of high-grade squamous intraepithelial lesion and adenocarcinoma in situ with an invasive disease and HPV type 18 in tumour tissue [4]. In our case, a gastroscopy and colonoscopy were performed and the patient underwent MRI and PET/CT. However, no other tumour lesion was found. Our patient had a history of HPV infection, and HPV type 18 was found in her tumour tissue. HPV type 18 is a well-known risk factor for cervical adenocarcinomas. Hence, almost all of the reports searching for HPV-DNA in cases with primary signet ring cell adenocarcinoma of the cervix including ours showed HPV type 18 positivity, an association with HPV type 18 and primary signet ring cell adenocarcinoma of the cervix may be easily suggested.

Immunohistochemical studies were performed in most of the previous studies. However, conflicting results have been obtained (Table 1). Three cases were negative for mammaglobin and no positive case was reported. Similarly, two cases reported positive reaction with p16, which may show an HPV effect on the tumour. No negative case was reported with p16 immunohistochemical staining. To date, positivity for cytokeratin 7 was shown in five cases, and it seems to be the most prominent immunohistochemical marker. In a recent study, cervical cytokeratin 7 positivity was found to be associated with progression of low grade cervical lesions to high grade cervical lesions [15]. The literature regarding

**Table 1**  
Summary of cases of primary signet-ring cell carcinoma of the cervix, modified from Giordano et al. [14].

Author, year	Age (years)	Presenting symptom	Immunohistochemical studies other than ER and PR	ER, PR	HPV	FIGO stage	Treatment	Outcome
Moll et al., 1990 [2]	50	Postcoital vaginal bleeding, menometrorrhagia	NA	NA	NA	III	Sx, Rx	DOD 10 mo
Mayorga et al., 1997 [3]								
Case 1	68	Postcoital vaginal bleeding	NA	NA	NA	Ib	NACT and Sx	Disease-free at 35 mo
Case 2	74	Postmenopausal bleeding	NA	NA	NA	Ib	Sx	Disease-free at 35 mo
Haswani et al., 1998 [4]								
Case 1	33	Asymptomatic (routine vaginal smear: AGC-NOS)	NA	ER: –	HPV type 18: +	III	Rx, Chemo	DOD 10 mo
Case 2	38	Postcoital vaginal bleeding	NA	ER: –, PR: –	NA	Ib	Sx and Rx	Disease-free at 18 mo
Cardosi et al., 1999 [5]	53	Perimenopausal bleeding	NA	ER: +, PR: +	NA	Ib	Sx, Rx, Chemo	Disease-free at 6 mo
Moritani et al., 2004 [6]	29	AUB	Positive for CK, MUC5AC Negative for vimentin, MUC2, MUC6	ER: –, PR: –	–	III	Chemo	Disease-free at 6 mo
Suárez- et al., 2007 [7]	80	Vaginal discharge	Positive for CK AE1-AE3, CK 20, carcinoembryonic antigen, chromogranin A, synaptophysin Negative for vimentin, S-100 protein, HMB-45, adrenocorticotrophic hormone, prolactin, thyroid-stimulating hormone, follicle-stimulating hormone, luteinizing hormone, growth hormone, gross cystic disease fluid protein 15	NA	NA	III	Rx, Chemo	DOD 18 mo

Table 1 (Continued)

Author, year	Age (years)	Presenting symptom	Immunohistochemical studies other than ER and PR	ER, PR	HPV	FIGO stage	Treatment	Outcome
Insabato et al., 2007 [8]	46	AUB (cervical polypoid lesion)		NA	NA	Ib	Sx, Rx, Chemo	Disease-free at 3 years
McCluggage et al., 2007 [9] (2 cases)	NR	NR	Positive for CK 7 and CK 16 Negative for CK 20 and CDX2	NA	NR	NR	NR	NR
Versas et al., 2009 [10]								
Case 1	36	Thromboembolic events	Positive for p16 and CK 7 Negative for CK 20, CDX2 and Dpc4	ER: –, PR: –	+	IV	Chemo	Dod 7 weeks
Case 2	43	Metastases of lung and lymph nodes	Positive for p16 and CK 7 Negative for CK 20, CDX2 and mammoglobin	ER: –, PR: –	NA	IV	Chemo	Dod 2 mo
Lowery et al., 2009 [11]	About 60	Postmenopausal bleeding	NA	NA	NA	Ib1	Rx and Sx (for synchronous endometrial cancer)	Disease-free at >10 years
Balci et al., 2010 [12]	53	Postmenopausal bleeding	Positive for CK, p16, CEA, MUC1, and MUC5. Negative for CK 20, GCDFP15, MUC2, chromogranine, synaptophysin, PGP 9.5, CD56, vimentin, CDX-2, TTF-1, and mammoglobin	ER: –, PR: –	HPV type 18: +	NR	Sx	NR
Yoon et al., 2011 [13]	47	Postcoital vaginal bleeding	Positive for p53 and Rb	NA	NA	Ib1	Sx	Dod 6 mo
Giordano et al., 2012 [14]	45	Persistent AUB	Positive for CK 7, CA-125, CEA and p16 Negative for vimentin	NA	HPV type 18: +	Iib	Sx	NR
Washimi et al., 2015 [1]	31	AUB	Positive for MUC2, CDX2, CEA, CK7 Negative for MUC1, MUC5AC, MUC6, p53, CK20, TTF-1, GCDFP-1, mammoglobin, chromogranin-1, p16, HIK1083	ER: –, PR: –	HPV type 18: +	Ib1	Sx and chemo	Disease-free at 41 mo
Present case	48	Postcoital vaginal bleeding	Positive for p16, CDX-2, MUC1 MUC2, MUC5AC Negative for synaptophysin, chromogranin A, CK20	ER: –, PR: –	HPV type 18: +	Ib1	Sx	Disease-free at 18 mo

CK: cytokeratin. MUC: mucin. TTF: thyroid transcription factor. GCDFP: gross cystic disease fluid protein. ER: estrogen receptor. PR: progesterone receptor. NA: not available. Sx: surgery. Rx: radiation therapy. DOD: died of disease. Mo: months. NACT: neoadjuvant chemotherapy. Chemo: chemotherapy. AUB: abnormal uterine bleeding. NR: not reported.

immunohistochemical staining with MUC 1, MUC 2, MUC 5, chromogranin A and synaptophysin showed different results. Only one but 6 cases stained for CK 20 showed negativity. In addition, while CDX2 was shown to be negative in all of four cases that were stained, for the first time, we found positivity. This finding might be considered as unexpected, since CDX2 is specifically expressed in colorectal adenocarcinomas. Based on conflicting results, one can conclude that immunohistochemical studies are not even close to rejecting or proving the diagnosis of primary signet cell cervical cancer.

While the data on primary signet cell carcinoma of the cervix is not enough to provide a recommendation regarding treatment, we managed our patient as having an adenocarcinoma of the cervix. Because there were no intermediate (large tumour size, cervical stromal invasion to the middle or deep one-third, lymphovascular space invasion) or high risk factors (positive margins, positive lymph nodes, parametrial involvement) for recurrent disease, we did not offer any adjuvant treatment.

It is not easy to predict survival because of the small number of the cases. In two cases with stage IV, patients died of disease in 2 months [10]. However, more than 10 years disease-free survival was reported in a patient with stage IB1 disease. While our case was staged as IB1, a long-term survival may be hoped.

In conclusion, it is crucial to differentiate primary from metastatic signet cell carcinoma of the cervix. If our case had been accepted as a metastasis, it would have been stage IV and received a very different kind of therapy. A clinical examination and imaging studies should be performed carefully for this purpose. Immunohistochemical studies may be helpful, especially when the number of cases increases. In addition, HPV DNA positivity may confirm the diagnosis as primary.

#### Conflict of interest

We declare that we have no conflict of interest.

#### Funding

None.

#### Ethical approval

Our study did not require ethical form.

#### Consent

Written informed consent form was obtained from the patient for publication of this case report and images.

#### Author contribution

V.S. Data collection, design. I.K. Literature search, writing the manuscript. H.T. Data analysis, data collection. N.T. Data interpretation. T.B. Final review. O.A. Data analysis. data collection. F.D. Final review. M.A. Final review.

#### Guarantor

Ilker Kahramanoglu.

#### Acknowledgement

None.

#### References

- [1] K. Washimi, T. Yokose, A. Noguchi, K. Ono, K. Kawachi, Y. Maruyama, et al., Diagnosis of primary pure signet-ring cell carcinoma of the cervix, *Pathol. Int.* 65 (7) (2015) 393–395.
- [2] U.M. Moll, J.C. Chumas, W.J. Mann, B. Patsner, Primary signet ring cell carcinoma of the uterine cervix, *N. Y. State J. Med.* 90 (1990) 559–560.
- [3] M. Mayorga, A. Garcia-Valtuille, F. Fernandez, J.F. Val-Bernal, E. Cabrera, Adenocarcinoma of the uterine cervix with massive signet-ring cell differentiation, *Int. J. Surg. Pathol.* 5 (1997) 95–100.
- [4] P. Haswani, J. Arseneau, A. Ferenczy, Primary signet ring cell carcinoma of the uterine cervix: a clinicopathologic study of two cases with review of the literature, *Int. J. Gynecol. Cancer* 8 (1998) 374–379.
- [5] R.J. Cardosi, M.B. Reedy, J.R. Van Nagell, S.E. Spires, Neuroendocrine signet ring cell adenocarcinoma of the endocervix, *Int. J. Gynecol. Cancer* 9 (5) (1999) 433–437.
- [6] S. Moritani, S. Ichihara, R. Kushima, F. Sugiura, M. Mushika, S.G. Silverberg, Combined signet ring cell and glassy cell carcinoma of the uterine cervix arising in a young Japanese woman: a case report with immunohistochemical and histochemical analyses, *Pathol. Int.* 54 (2004) 787–792.
- [7] J.M. Suárez-Peñaranda, I. Abdulkader, F.J. Barón-Duarte, E. González Patiño, A. Novo-Domínguez, J. Varela-Durán, Signet-ring cell carcinoma presenting in the uterine cervix: report of a primary and 2 metastatic cases, *Int. J. Gynecol. Pathol.* 26 (2007) 254–258.
- [8] L. Insabato, S. Simonetti, R. De Cecio, S. Di Tuoro, G. Bifulco, A. Di Spiezio Sardo, Primary signet-ring cell carcinoma of the uterine cervix with long term follow-up: case report, *Eur. J. Gynaecol. Oncol.* 28 (2007) 411–414.
- [9] W.G. McCluggage, R. Shah, L.E. Connolly, H.A. McBride, Intestinal-type cervical adenocarcinoma in situ and adenocarcinoma exhibit a partial enteric immunophenotype with consistent expression of CDX2, *Int. J. Gynecol. Pathol.* 27 (2008) 92–100.
- [10] E. Veras, M. Srodon, E.S. Neijstrom, B.M. Ronnett, Metastatic HPV-related cervical adenocarcinomas presenting with thromboembolic events (Trousseau syndrome): clinicopathologic characteristics of 2 cases, *Int. J. Gynecol. Pathol.* 28 (2) (2009) 134–139.
- [11] W.J. Lowery, M.J. Difurio, M.J. Sundborg, C.A. Leath, Cervical Signet-Ring Cell Carcinoma Presenting as a Synchronous Primary Carcinoma With Uterine Adenocarcinoma, *Mil. Med.* 174 (2) (2009) 212.
- [12] S. Balci, A. Saglam, A. Usubutun, Primary signet-ring cell carcinoma of the cervix: case report and review of the literature, *Int. J. Gynecol. Pathol.* 29 (2010) 181–184.
- [13] A. Yoon, S.-H. Kim, H.-J. Kim, D.-S. Bae, J.-W. Lee, Primary signet ring cell carcinoma of the uterine cervix: a case report, *Korean J. Obstet. Gynecol.* 54 (2011) 570–573.
- [14] G. Giordano, S. Pizzi, R. Berretta, T. D'Adda, A new case of primary signet-ring cell carcinoma of the cervix with prominent endometrial and myometrial involvement: Immunohistochemical and molecular studies and review of the literature, *World J. Surg. Oncol.* 10 (2012) 7.
- [15] C. Paquette, A.M. Mills, M.H. Stoler, Predictive value of cytokeratin 7 immunohistochemistry in cervical low-grade squamous intraepithelial lesion as a marker for risk of progression to a high-grade lesion, *Am. J. Surg. Pathol.:* Post Author Corrections (November) (2015), <http://dx.doi.org/10.1097/PAS.0000000000000548>.

#### Open Access

This article is published Open Access at [sciedirect.com](http://sciedirect.com). It is distributed under the [IJSCR Supplemental terms and conditions](#), which permits unrestricted non commercial use, distribution, and reproduction in any medium, provided the original authors and source are credited.