




Since January 2020 Elsevier has created a COVID-19 resource centre with free information in English and Mandarin on the novel coronavirus COVID-19. The COVID-19 resource centre is hosted on Elsevier Connect, the company's public news and information website.

Elsevier hereby grants permission to make all its COVID-19-related research that is available on the COVID-19 resource centre - including this research content - immediately available in PubMed Central and other publicly funded repositories, such as the WHO COVID database with rights for unrestricted research re-use and analyses in any form or by any means with acknowledgement of the original source. These permissions are granted for free by Elsevier for as long as the COVID-19 resource centre remains active.



# Current Problems in Diagnostic Radiology

journal homepage: [www.cpdjournal.com](http://www.cpdjournal.com)



## Implementing a Novel Through-Glass Chest Radiography Technique for COVID-19 Patients: Image Quality, Radiation Dose Optimization, and Practical Considerations

Jessica Chan, MD<sup>a</sup>, William Auffermann, MD, PhD<sup>a</sup>, Peter Jenkins, PhD, CHP, DABR<sup>b</sup>, Seth Streitmatter, PhD, DABR<sup>b</sup>, Phuong-Anh Duong, MD<sup>a,\*</sup>

<sup>a</sup> University of Utah School of Medicine, Department of Radiology and Imaging Sciences, Salt Lake City, UT

<sup>b</sup> University of Utah Hospital, Salt Lake City, UT

### ABSTRACT

**Rationale and objectives:** The novel coronavirus (COVID-19) pandemic has presented many logistical challenges, including unprecedented shortages of personal protective equipment (PPE). A technique of obtaining portable chest radiographs (pCXR) through glass doors or windows to minimize technologist-patient contact and conserve PPE has gained popularity, but remains incompletely evaluated in the literature. Our goal was to quickly implement this technique and evaluate image quality and radiation dose. **Materials and methods:** An infographic and video were developed to educate nurses and technologists on the through-glass pCXR technique. Imaging parameters were optimized using a phantom and scatter radiation was measured. Three reviewers independently evaluated 100 conventionally obtained and 100 through-glass pCXRs from March 13, 2020 to April 30, 2020 on patients with suspected COVID-19, using criteria for positioning and sharpness/contrast on a 1 (confident criteria not met) to 5 (confident criteria met) scale. Imaging parameters, including deviation index (DI) were recorded for all radiographs. **Results:** The through-glass method was rapidly adopted and conserved one isolation gown per interaction. Although there was a statistically significant difference in the positioning ( $P$  value 0.018) and sharpness/contrast ( $P$  value 0.016), the difference in mean ratings was small: 4.82 vs 4.65 for positioning and 4.67 vs 4.50 (conventional vs modified) for sharpness/contrast. Scatter radiation was measured using a thorax phantom and found to be acceptable for the patient and nearby personnel. Standard deviation was higher for the DI for the through-glass technique (2.8) compared to the conventional technique (1.8), although the means were similar. **Conclusion:** The through-glass technique was quickly implemented, producing diagnostic quality chest radiographs while conserving PPE and reducing risks to radiology staff. There was more variability with imaging technique and DI using the through-glass technique, likely due to technologist uncertainty regarding technical modifications. Further work to reduce this variation is necessary to optimize quality and dose.

© 2021 Elsevier Inc. All rights reserved.

### Introduction

The novel coronavirus (COVID-19) pandemic has presented many logistical challenges for health care systems as they care for patients with known or suspected COVID-19 infection, from the development of drive-through screening programs to caring for the critically ill patient in the intensive care unit (ICU). One of the greatest challenges in the United States is the shortage of personal protective equipment (PPE), which has led to increased risk of COVID-19 transmission to frontline healthcare workers.<sup>1</sup> At our hospital, the types of PPE worn by personnel in contact with patients known or suspected of having COVID-19 varies based on current PPE availability, with the most protective forms being limited to personnel in continuous contact with these patients. Radiology technologists come in close contact with these patients when acquiring chest

radiographs during the patient's initial assessment or during their hospitalization.<sup>2,3</sup> Imaging these patients with suboptimal PPE poses a risk to radiology technologists and to other patients with whom technologists interact.

Recently, a technique for imaging patients through glass windows and doors has been discussed in electronic forums and implemented at some hospitals to reduce risk of COVID-19 transmission.<sup>4</sup> One hospital has furthered this concept by employing this technique for "walk-up" chest imaging at COVID-19 drive-through testing sites.<sup>5</sup> Despite the rapid popularity of the modified through-glass chest radiography method, literature establishing its benefit and discussing limitations such as image quality and radiation dose is incomplete. Our goal was to implement this modified chest radiography method because it was feasible at our institution; it conserves PPE and reduces the risk of transmission to radiology technologists.

We describe our implementation strategy at our institution and the performance (quality, safety, and PPE conservation) of this modified technique. As with any new technique, we found successful implementation requires buy-in, training, and monitoring of performance.

Declaration of competing interest: None.

Funding: This research did not receive any specific grant from funding agencies in the public, commercial, or not-for-profit sectors.

\*Reprint requests: Phuong-Anh Duong, MD, University of Utah School of Medicine, Department of Radiology and Imaging Sciences, 30 N Medical Dr, RM 1A071, Salt Lake City, UT 84132.

E-mail address: [Phuong-anh.duong@utah.edu](mailto:Phuong-anh.duong@utah.edu) (P.-A. Duong).

<https://doi.org/10.1067/j.cpradiol.2020.12.003>

0363-0188/© 2021 Elsevier Inc. All rights reserved.

**Methods**

*Workflow of the Modified Technique*

We implemented the modified (through-glass) chest radiograph imaging acquisition technique, using our portable radiography unit (DRX-Revolution, Carestream Health, NY USA) in the Emergency Care Unit (ECU). At our institution, patients suspected of having the novel coronavirus are typically housed in the ECU, which has rooms with sliding glass doors.

Prior to implementing the new technique, a team comprised of radiologists, the radiography manager, and a lead radiography technologist created a process map to determine the technologist’s workflow and PPE usage during the conventional (in-room) chest radiograph technique. This team then developed a process map for the modified radiography technique to understand the new workflow for the technologist and nurse, as well as PPE usage by the technologist. In this technique, patients are imaged through the glass window or door of their patient room, with the technologist remaining in the hallway, and a nursing staff in the room equipped with proper PPE to assist with patient and detector positioning. The step-by-step process is illustrated by the process map (Fig 1). Important steps in this process are positioning of the patient and detector and transferring and cleaning of the detector and radiation shield. The patient’s bed should be brought close and perpendicular to the glass, with the patient’s head of bed elevated to 90 degrees. The detector is in landscape orientation, centered behind the patient’s back, with the superior margin reaching 1 inch above the patient’s shoulders. At the beginning of the modified technique, the detector, covered by a single layer of protective plastic, and the radiation shield are passed sequentially from the technologist to the nursing staff in the room through the patient room doorway with the minimum clearance necessary. The nurse stands behind the portable radiation shield during image acquisition. At the end of the modified technique these objects are then passed back, out of the room, sequentially allowing for the time necessary to clean each object before the next is passed.

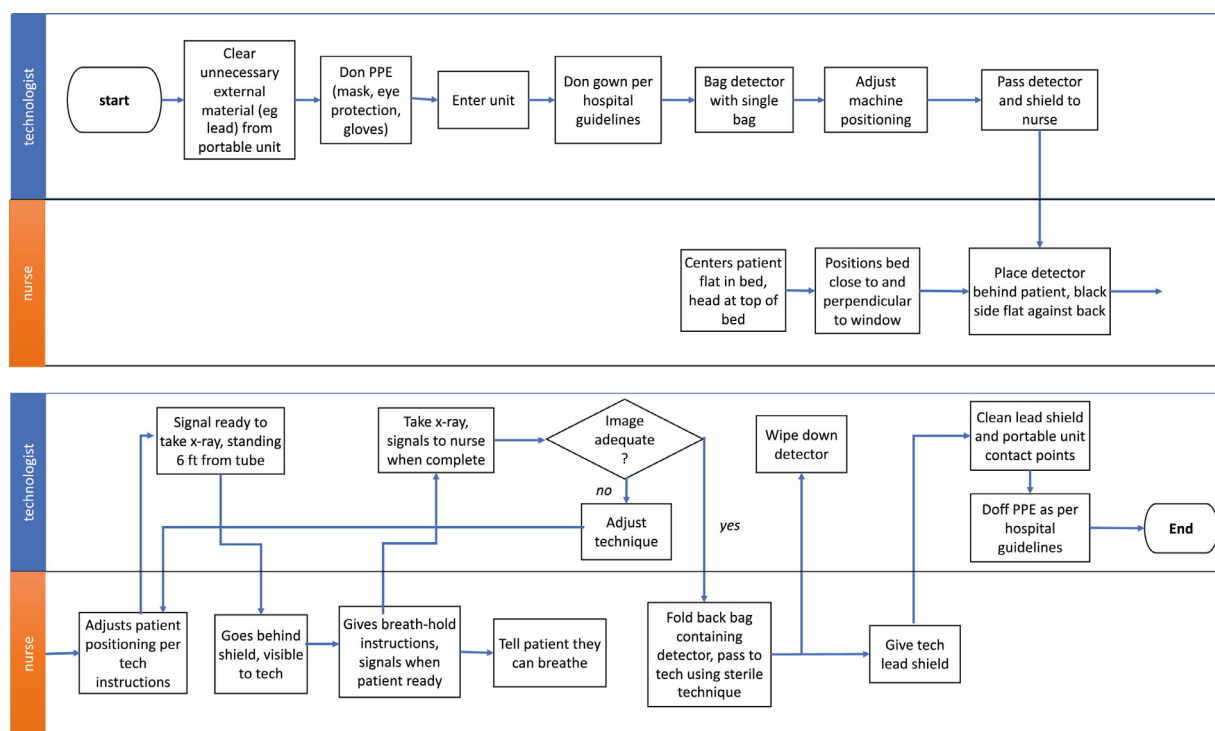
An infographic and educational video were developed to describe the workflow of the modified chest radiography technique and was made publicly available on our institution’s website (See Fig 2).<sup>6</sup>

*Technical Parameters and Radiation Safety of the Modified Technique*

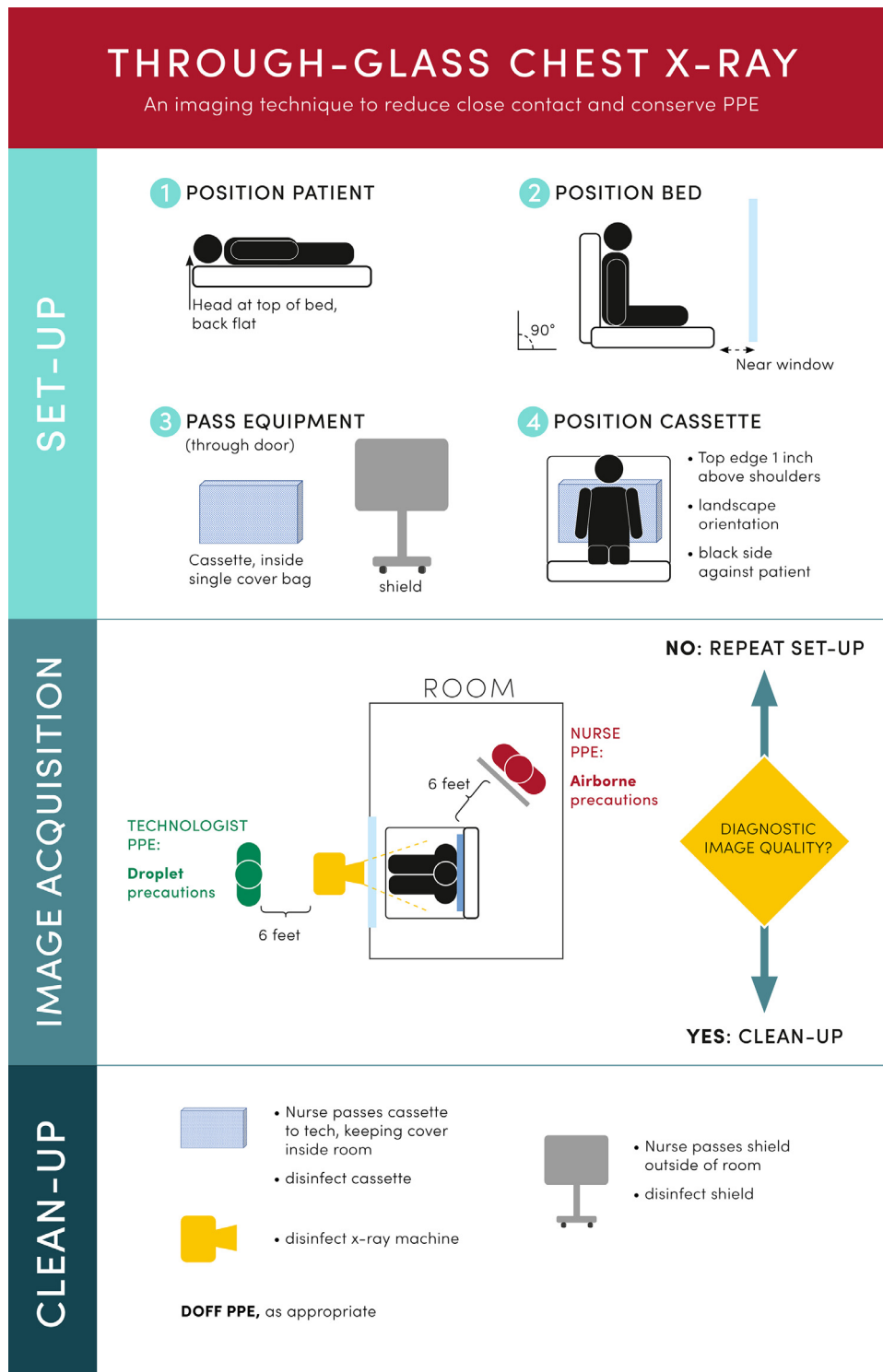
Radiation safety to surrounding staff was demonstrated by direct measurement of exposure from radiation scatter generated from an anthropomorphic phantom utilizing the modified imaging technique; measurement locations of the optimal and likely positions of nursing staff inside the room as well as staff in the corridor and surrounding areas outside the room during exposure. An inexpensive, and easily cleaned, radiation shield was created for staff to stand behind inside the patient room, comprising of a standard IV pole, a rectangular 24 × 48 inch vinyl 0.5 mm lead shield (Bar-Ray, PA, USA), a traction frame, and 2 clamps, costing less than \$500 (see Fig 3).

We used an anthropomorphic thorax phantom to determine our image acquisition parameters prior to imaging patients. To simulate an obese patient, 6 cm of Lucite was added to the phantom. We experimented with positioning of the phantom and X-ray machine and determined modifications in tube current-time product (mAs) and tube potential (kVp) necessary to produce diagnostic quality images at the same level as in the traditional, in-room technique. The source to image distance (SID) for the through-glass technique was greater than the conventional technique and was more variable due to necessary adjustments of positioning for imaging through the glass. We optimized the technique by imaging the phantom at the increased distance as a starting point. These new technique parameters were verified by reproducing similar high and low contrast resolution and deviation index (DI), which quantifies the difference between the detector exposure index and the target exposure index<sup>7</sup>, for both the conventional and through-glass techniques using the thorax phantom.

Patient dosimetry was assessed by taping a solid-state kV/dose multisensor (AGMS-DM+, Radcal, CA, USA) around the level of the diaphragm of the phantom and measuring the entrance skin exposure (ESE) for conventional and through-glass techniques. Also



**FIG. 1.** Swim-lane diagram. Swim-lane process map detailing process steps for the technologist and nurse for the through-glass chest radiography technique. (Color version of figure is available online.)





**FIG. 3.** Protective lead shield. (A) Improvised shield for protecting nursing staff in the room. The vinyl lead sheet is easy to clean and the structure is lightweight. (B) Close-up of clamps used to affix lead sheet to frame. (Color version of figure is available online.)

*Evaluation of Image Quality of the Chest Radiographs Acquired by the Modified Technique*

Radiology reports from portable chest radiographs of adult patients suspected of having COVID-19 (“person under investigation,” PUI) in the ECU using the conventional and through-glass (modified) chest radiography techniques, performed from March 13, 2020 to April 30, 2020, were retrospectively reviewed with IRB approval. In March, a new imaging code was created to identify portable chest radiographs acquired with the modified technique, and a report template was introduced for chest radiographs of PUI patients, regardless of acquisition technique. Using an available data mining tool (mPower Clinical Analytics, Nuance, MA USA) 200 studies were selected, 100 of which were performed with the traditional radiograph method and 100 that were performed with the modified method, as identified by their imaging code. Furthermore, by searching for key phrases from the PUI report template, we were able ensure an even number of normal and abnormal findings among our 2 techniques within our cohort.

After images were anonymized and randomized, they were independently reviewed on the hospital Picture Archiving and Communication System (PACS), Philips IntelliSpace (Philips, USA), by 3 thoracic radiologists with 1, 10, and 16 years of experience. Chest radiographs were evaluated using a variant of visual grading characteristics (VGC) analysis.<sup>8</sup> Chest radiograph evaluation criteria were based on the European Guidelines on Quality Criteria for Diagnostic Radiographic Images.<sup>9</sup> Image criteria were grouped into those pertaining to positioning and image sharpness/contrast (See Table 1). A score of 1-5 was assigned for each of the 2 aggregate categories for each chest radiograph, wherein 1 represents “confident the criteria were not

fulfilled” and 5 represents “confident the criteria were fulfilled.” Readers’ responses were adjusted to the mean and scores were compared between the 2 techniques using a pooled 2 sample T test. A type II ( $\alpha$ ) error level of 0.05 was selected for statistical significance.

**Results**

The through-glass technique was piloted in March and was quickly implemented. Of the 354 portable chest radiographs performed between March 13th and April 30th on patients suspected of COVID-19 in the ECU, 233 radiographs were obtained using the modified technique. During the first week of implementation, 13 chest radiographs were obtained with the modified technique, comprising

**TABLE 1**  
Criteria for scoring image quality

Criteria	
Positioning	<ol style="list-style-type: none"> <li>1. Reproduction of the whole rib cage above the diaphragm</li> <li>2. Symmetrical reproduction of the thorax as shown by central position of the spinous process between the medial ends of the clavicles</li> </ol>
Sharpness/contrast	<ol style="list-style-type: none"> <li>1. Visually sharp reproduction of the vascular pattern in the whole lung, particularly the peripheral vessels</li> <li>2. Visually sharp reproduction of:                             <ol style="list-style-type: none"> <li>(a) The trachea and proximal bronchi,</li> <li>(b) The borders of the heart and aorta,</li> <li>(c) The diaphragm and lateral costo-phrenic angles</li> </ol> </li> <li>3. Visualization of the retrocardiac lung and the mediastinum</li> <li>4. Visualization of the spine through the heart shadow</li> </ol>

45% of the total portable PUI chest radiographs, while during the final week of the study period 71 chest radiographs were obtained with the modified technique, comprising 82%.

Because the technologist remained outside the room in the modified technique, they followed droplet precautions, as opposed to airborne precautions if they were inside the room. The required PPE for these types of precautions may vary between institutions and depending on available PPE. At our institution, under droplet precautions the technologist used only 1 blue gown per interaction, as opposed to 2 blue gowns used in the conventional portable chest radiography method. 233 gowns are estimated to have been saved during the study time period. As of August 1st, no radiography technologists have tested positive for COVID-19.

Radiation exposure rates from scatter utilizing the modified imaging technique were found to be safe for staff both inside and outside the patient room during image acquisition (See Figs 6 and 7). Assuming all individuals outside the patient room would remain at least 2 m from X-ray machine during exposure, the suggested technique could safely be repeated many times (approximately 3200 times per year for the above-described technique) and the public dose limit of 1 mSv (100 mrem) would not be exceeded. Similarly, the nursing staff inside the patient room would also be afforded the similar levels of exposure near the bedside, but would also receive additional exposure reduction due to the use of the portable shield.

Suggested imaging technique for the modified and conventional portable chest radiograph acquisition techniques were optimized for both normal and obese patients and are provided in Table 2. However, we found that, in practice, that these guidelines were not routinely followed, and the technique utilized by technologists varied widely. The mean DI for the conventional and modified techniques were similar (conventional: 1.5 vs modified: 1.4); however, the standard deviation was greater for the modified technique as compared to the conventional technique (2.8 vs 1.8) (see Table 3).

Image quality ratings for the conventional and modified technique are displayed using frequency polygons in Figure 4. Additionally, sample chest radiographs acquired by the 2 techniques from the reviewed cohort are provided in Figure 5. Using a type II error level

**TABLE 2**  
Comparison of conventional and modified techniques derived from phantom studies

	mAs	ESE (mR)	ESAK ( $\mu$ Gy)	DI	CNR	SNR
kVp: 110	0.9	4.23	37.07	-0.81	3.23	12.94
SID (cm): 168						
Scenario: Conventional						
Phantom: Thorax						
kVp: 110	2.0	8.59	75.25	0.36	2.79	17.91
SID (cm): 168						
Scenario: Conventional						
Phantom: Thorax + 6 cm						
kVp: 110	2.0	2.29	20.08	-1.08	2.90	12.30
SID (cm): 218	3.2*	3.85	33.73	1.23	3.19	12.73
Scenario: Through-glass	4.0*	4.90	42.94	2.30	3.53	13.82
Phantom: Thorax						
kVp: 110	3.2	4.09	35.80	-1.81	1.95	9.80
SID (cm): 218	4.0	5.17	45.27	-0.72	2.11	10.59
Scenario: Through-glass	5.0*	6.54	57.31	0.34	2.21	10.66
Phantom: Thorax + 6 cm	6.2*	8.44	73.90	1.38	2.53	11.50

\*Indicates the suggested range of mAs for through-glass exposures. Contrast-to-noise (CNR), Deviation index (DI), entrance skin air kerma (ESAK), entrance skin exposure (ESE), source-to-image distance (SID), signal-to-noise (SNR).

**TABLE 3**  
Deviation index summary statistics for conventional and through-glass techniques

	Mean	Standard deviation	Minimum	Maximum
Conventional	1.5	1.8	-3.8	4.8
Through-glass technique	1.4	2.8	-7.2	6.9

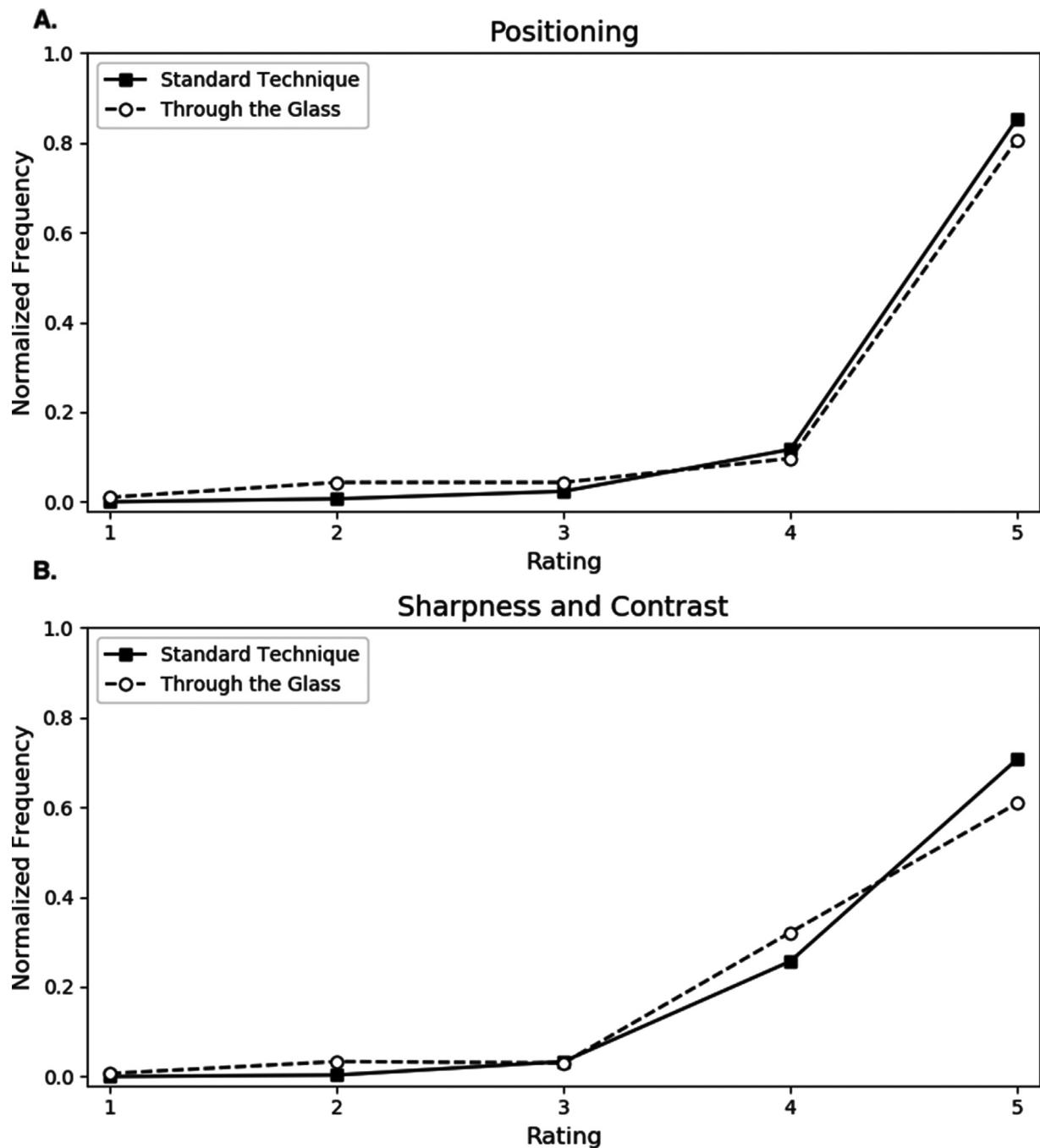
of 0.05, there was a statistically significant difference in the positioning and sharpness/contrast between these 2 techniques, *P* value of 0.018 and 0.016 respectively. However, the difference in mean ratings for both parameters was small: 4.82 (conventional) vs 4.65 (modified) for positioning and 4.67 (conventional) vs 4.50 (modified) for sharpness/contrast. For the phantom image quality measurements, all the through-glass techniques have some decrease in CNR when comparing to target exposure index (Table 2). However, looking at the ESE values of the proposed technique, there is an opportunity to increase the technique (mAs) and DI while still staying within the ESE for a conventional technique. In practice this was difficult to implement because of inconsistent techniques used by the technologists.

**Discussion**

Meeting the challenge of these unprecedented times requires healthcare systems to adapt and quickly incorporate new workflows and techniques. In only a couple of weeks, we implemented the through-glass chest radiography technique, and it became the predominant method of chest radiography for patients suspected of having or known to have COVID-19. To accomplish this, we obtained buy-in from the nursing staff and provided multimedia educational materials to both the nursing staff and radiology technologists. Although we measured the scatter radiation to nearby personnel and found it to be minimal, some nurses were concerned about their radiation exposure because they remained in the patient room during image acquisition. To address their concerns and obtain buy-in, we constructed a lead barrier using a lead vinyl sheet that could easily be cleaned and costs far less than typical moveable barriers. We made an infographic and an educational video to clearly communicate the new standard workflow for both nursing staff and radiology technologists. Finally, we provided technical guidance to technologists, based on phantom data acquired with the modified technique, to ensure diagnostic quality images while minimizing radiation exposure.

As a result of using this modified imaging method, there was decreased exposure to COVID-19 for radiography technologists who did not have the same level of PPE as the staff exclusively caring for COVID-19 patients. As the radiology technologist remained outside the room, only droplet precautions were necessary with the modified technique which saves an isolation gown for each interaction, a type of PPE that was in short supply in our hospital. The required PPE for droplet vs airborne precautions may vary at other institutions and may vary depending on PPE shortages. As of August 1st, none of the radiography technologists at our institution have tested positive for the virus.

There was a statistically significant difference in the image quality in the through-glass vs conventional images, but the difference in image ratings was small. The positioning and technique differences would have likely been overcome as nursing staff and radiologic technologists gained more experience. The difference in sharpness/contrast was primarily due to decreased visualization of the thoracic spine through the cardiac silhouette, a feature of little clinical importance in the diagnosis of pulmonary abnormality particularly for COVID-19 infection which most commonly affects the peripheral lung. All the cardiothoracic radiologists at our institution stated they thought the images acquired using the modified technique were of adequate diagnostic quality. Previous work evaluating this technique used phantoms or did not compare the image quality to comparable images using the conventional method. One study showed that the image quality was rated as uniformly excellent when the technique was used on a phantom but did not evaluate this imaging technique on patients.<sup>10</sup> Brady and colleagues reported that 30 through-glass radiographs were assessed by 2 readers: one scored 70% of them as acceptable quality while the other scored 90% of them acceptable.<sup>11</sup> However, they did not compare these images to conventionally



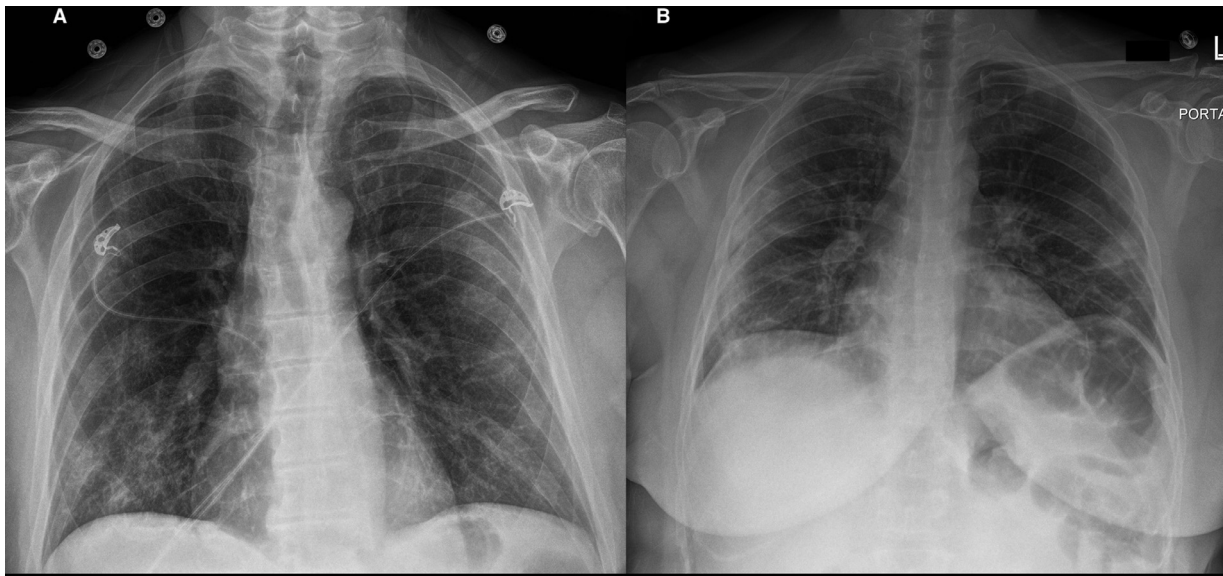
**FIG. 4.** Visual grading characteristics. Frequency polygons comparing visual grading characteristics (VGC) scoring of conventional vs through-glass chest radiography technique for (A) positioning and (B) sharpness/contrast. Score ranges from 1 to 5, with 1- confident criteria are not met and 5- confident criteria met.

obtained radiographs. Thus, it cannot be determined if image quality was equivalent.

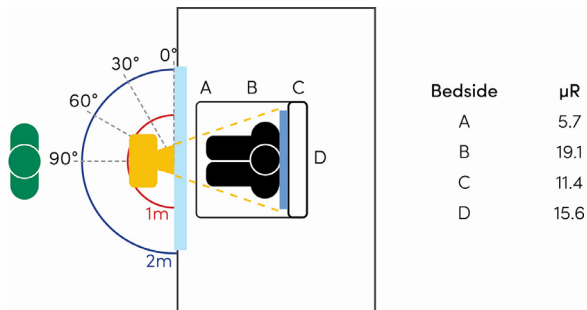
Although there was a small clinically insignificant difference in image quality between the 2 methods, we found variability in technique and radiation dose for the modified technique. Despite the initial technique recommendations from the phantom studies provided to the technologists, there was significant variation in the DI of the modified technique as compared to the conventional technique. This may be due differences in positioning of the patient or equipment, as well as technologist uncertainty in their attempt to compensate for increased attenuation and scatter by the barrier and increased SID. SID for through-glass images was greater than for conventional portable imaging due to the necessary adjustment of positioning for imaging through the window. Even with the bed pushed all the way

to the door, there is at least a foot or more difference between the modified technique and the one taken conventionally, where the tube is over the bed. The SIDs were held as constant as possible for the modified technique, although the introduction of the barrier did not allow for directly measuring SID. Also, some variability was expected due to patient factors and because a nurse rather, than an experienced technologist, positioned the detector and patient within the room.

Other important considerations include the beam quality and values of interest identification for the EI<sup>7</sup> and thus reported DI. The added filtration from the glass door changes the beam quality compared to a conventional acquisition. The phantom studies could only provide a starting point for mA adjustments for the 2 idealized patients habitus examined, while the study subjects had an average



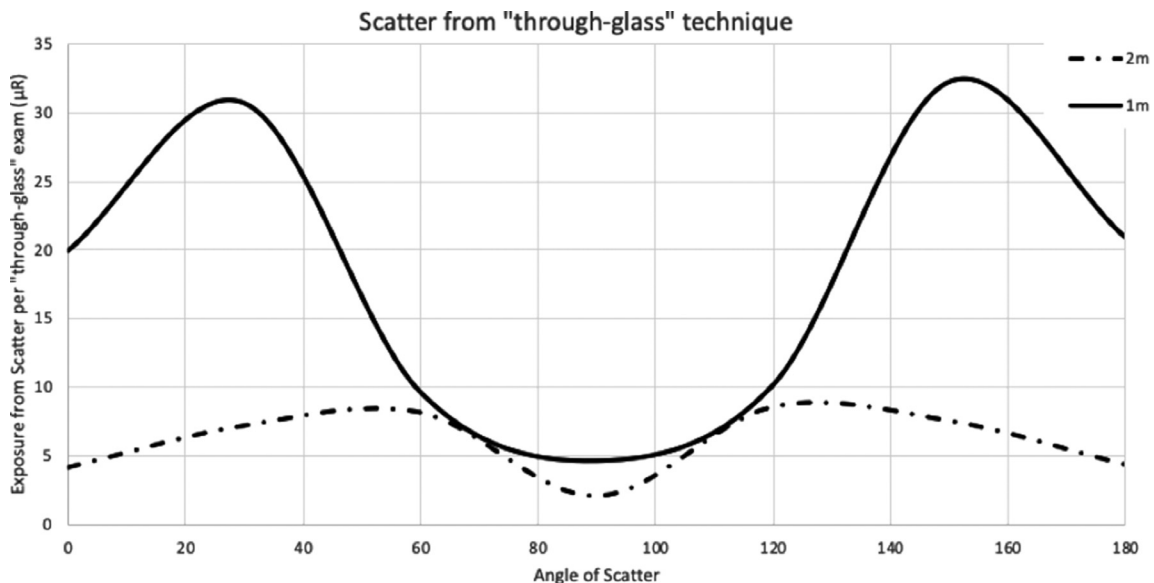
**FIG. 5.** Example chest radiographs. Sample chest radiographs from the reviewed cohort, obtained by the conventional technique (A) and through-glass chest radiography technique (B). Peripheral opacities are seen in both radiographs and both patients later tested positive for COVID-19.



**FIG. 6.** Scatter radiation. Measured exposure in air from patient scatter at bedside using through-glass chest radiography technique parameters. Scatter values are in air per acquisition for key locations (A-D) and at 1 m and 2 m from X-ray machine. Measured exposure in air at 1 m and 2 m from the X-ray machine are described further in Figure 7. (Color version of figure is available online.)

BMI of 30 kg/m<sup>2</sup>, with a standard deviation of 14 kg/m<sup>2</sup>. A wider spread of DIs is expected for mobile radiography, as technique is manually selected, and no option exists for photo timing exposures. Since this was a new technique and the collected data was from the first month and a half of experience, the technologist and nurse learning curve likely influenced the statistics as well.

Introducing a barrier between the X-ray machine and patient requires increase of the mAs to achieve the same exposure to the digital imaging receptor but has a negligible impact on patient dose. However, the increased attenuation and filtration of the beam by the barrier has the potential to cause some degradation of image quality by increasing the average energy of the beam and thus impacting CNR and low contrast detectability (See Table 2). For through-glass techniques, where the X-ray beam experiences added attenuation and filtration from the barrier, the displayed DI may not be as reliable an indicator of exposure as in the conventional scenario. As can be



**FIG. 7.** Scatter radiation. Scatter from glass to area surrounding X-ray machine and technologist using through-glass chest radiography technique parameters. Scatter values are in air per acquisition. 90 degrees in parallel to primary beam, with 0 and 180 degrees being perpendicular at the adjacent wall. Both 1 m (solid line) and 2 m (dashed line) scatter measurements were taken behind the mobile x-ray machine. All scatter measurement were made 1.5 m above the floor.



**TABLE 4**  
Transmission and half-value layer comparison

		mAs	mR	HVL (mm Al)	Transmission	mR/mAs @ 100 cm
kVp:	110	2.0	8.63	4.23	—	10.78
SSD (cm):	150	4.0	17.97			
Scenario:	Conventional	7.9	36.84			
kVp:	110	2.0	3.83	6.70	45.3%	5.01
SSD (cm):	150	4.0	8.16			
Scenario:	Through-glass	7.9	16.94			

Half-value layer (HVL), source-to-skin distance (SSD).

seen in the differences in technique, attenuation and HVL between the conventional and through-glass scenarios examined (See Table 4), the barrier can have a significant impact and every scenario should be treated uniquely and examined individually to assess modified techniques needed and impact on image quality.

Moving forward, more frequent guidance and closer monitoring of the technical parameters used by radiology technologists is necessary. Currently, our institution has moved all patients suspected of having COVID-19 to a centrally located unit, which does not have glass doors or windows of sufficient size to perform the modified technique, precluding further refinement of the modified chest radiography technique.

### Conclusion

We have demonstrated that rapid implementation of the through-glass chest radiograph technique is feasible with buy-in and training of nursing staff and radiology technologists, and the resulting image quality is sufficient for detecting lung disease in COVID-19 infection. We learned that, as with any new technique, frequent technical guidance and close monitoring is necessary to ensure consistent radiation exposure. We present our findings to guide other institutions in employing this novel way of imaging patients suspected of having or known to have COVID-19 while conserving PPE and reducing risk of transmission.

### Acknowledgments

We would like to thank Alex Nieves, MHA (Manager, Diagnostic Radiology) and Jason Black RT (R, MR) (Radiology Supervisor) for their work on this project.

### References

- Jacobs A, Richtel M, Baker M. At War With No Ammo: Doctors Say Shortage of Protective Gear is Dire. *New York: New York Times*; 2020 A.G. Sulzberger.
- Jacobi A, Chung M, Bernheim A, et al. Portable chest X-ray in coronavirus disease-19 (COVID-19): A pictorial review. *Clin Imaging* 2020;64:35–42.
- Vancheri SG, Savietto G, Ballati F, et al. Radiographic findings in 240 patients with COVID-19 pneumonia: Time-dependence after the onset of symptoms. *Eur Radiol* 2020;30:6161–9.
- Mossa-Basha M, Medverd J, Linnau K, et al. Policies and guidelines for COVID-19 preparedness: Experiences from the University of Washington. *Radiology* 2020;296:E26–31.
- Palmer WJ. Walk-Up X-ray Booth Offers Quick Scans to COVID-19 Patients. *Diagnostic Imaging*; 2020.
- Mozdy, M. Safer, PPE Conserving X-rays for Patients at University Hospital. *Radiology and Imaging Science Stories* 2020 [cited 2020 April 10, 2020]; Available from: <https://medicine.utah.edu/radiology/news/2020/04/x-ray-through-glass.php>.
- Dave JK, Jones AK, Fisher R, et al. Current state of practice regarding digital radiography exposure indicators and deviation indices: Report of AAPM Imaging Physics Committee Task Group 232. *Med Phys* 2018;45:e1146–60.
- Bath M, Mansson LG. Visual grading characteristics (VGC) analysis: A non-parametric rank-invariant statistical method for image quality evaluation. *Br J Radiol* 2007;80:169–76.
- Blanc D. European guidelines on quality criteria for diagnostic radiographic images. *Radioprotection* 1998;32:2.
- Sng LH, Arlany L, Toh LC, et al. Initial data from an experiment to implement a safe procedure to perform PA erect chest radiographs for COVID-19 patients with a mobile radiographic system in a "clean" zone of the hospital ward. *Radiography (Lond)* 2020;27:48–53.
- Brady Z, Scoullar H, Grinstead B, et al. Technique, radiation safety and image quality for chest X-ray imaging through glass and in mobile settings during the COVID-19 pandemic. *Phys Eng Sci Med* 2020;43:765–79.