



Original Article

# Can paracetamol lower stress and anxiety by blunting emotions during and after computer guided dental implant surgeries? Findings from a randomized crossover clinical trial



Mahmoud Sedky Adly <sup>a,b\*</sup>, Afnan Sedky Adly <sup>c,d</sup>,  
Sanad Faleh Alreshidi <sup>e</sup>, Abdulaziz Mohsen Alotaibi <sup>f</sup>,  
Meshari Faleh Alreshidi <sup>g</sup>, Aya Sedky Adly <sup>h</sup>

<sup>a</sup> Faculty of Oral and Dental Medicine, Cairo University, Cairo, Egypt

<sup>b</sup> Royal College of Surgeons of Edinburgh, Scotland, United Kingdom

<sup>c</sup> Faculty of Physical Therapy, Cardiovascular-Respiratory Disorders and Geriatrics, Laser Applications in Physical Medicine, Cairo University, Cairo, Egypt

<sup>d</sup> Faculty of Physical Therapy, Internal Medicine, Beni-Suef University, Beni-Suef, Egypt

<sup>e</sup> College of Dentistry, Oral and Dental Medicine, Hail University, Hail, Saudi Arabia

<sup>f</sup> Ministry of Health, Oral and Dental Medicine, Riyadh, Saudi Arabia

<sup>g</sup> College of Dentistry, Orthodontics, Hail University, Hail, Saudi Arabia

<sup>h</sup> Faculty of Computers and Artificial Intelligence, Helwan University, Cairo, Egypt

Received 19 April 2020; Final revision received 17 May 2020

Available online 4 July 2020

## KEYWORDS

One-piece implant;  
Computer vision  
system;  
Acetaminophen;  
Ibuprofen;  
Pain;  
Salivary cortisol

**Abstract** *Background/purpose:* Dental implants insertion can be a major factor in stress and anxiety. The aim was to evaluate the paracetamol ability to lower stress and anxiety when compared with ibuprofen during and after computer guided implant surgery utilizing CAD/CAM surgical template and a computer vision system for assessment.

*Materials and methods:* Thirty patients were enrolled in a crossover study design having bilateral missing lower molars. Patients were randomized into 2 equal groups with the first assigned for dental implant insertion in the lower molar area on one side with the administration of paracetamol (with 7-day follow-up) followed by 2-week washout period, then another implant was inserted on the contra-lateral side with ibuprofen. The second group received the same drugs but in reversed order. Salivary cortisol level was used to measure anxiety and a computer

\* Corresponding author. Cairo University, 1 Gamaa Street, Giza 12613, Egypt.  
E-mail address: [dr.mahmoud.sedky@gmail.com](mailto:dr.mahmoud.sedky@gmail.com) (M.S. Adly).

vision system was used to measure swelling. Visual-Analogue-Scale pain score from 0-to-100 was also utilized.

**Results:** Only 29 patients completed the study. Stress and anxiety was found to be significantly lower in paracetamol group ( $4.1 \pm 1.08$  ng/mL and  $6.2 \pm 0.94$  ng/mL for paracetamol/ibuprofen respectively). Pain score was  $13.1 \pm 1.1$  and  $12.9 \pm 2.3$  in paracetamol/ibuprofen groups respectively with no significant differences. Swelling showed significant difference favoring the paracetamol group ( $0.91 \pm 0.41$  and  $0.61 \pm 0.31$  for paracetamol/ibuprofen respectively).

**Conclusion:** Paracetamol is effective in reducing stress by minimizing anxiety and blunting emotions of "fear-from-pain" so that pain is no longer perceived as much. However, paracetamol lacks the ability to control swelling at implant site. Computer guided flapless-implant surgery with immediate loading can be recommended for fearful patients.

© 2020 Association for Dental Sciences of the Republic of China. Publishing services by Elsevier B.V. This is an open access article under the CC BY-NC-ND license (<http://creativecommons.org/licenses/by-nc-nd/4.0/>).

## Introduction

Pain, stress, and anxiety during and after the surgical insertion of dental implants have a major effect in patient rejection of dental implant as a viable choice for teeth replacement.<sup>1,2</sup> Many patients argue about the risk of pain that may be encountered if they accepted such treatment. Even if the patient accepted the treatment, just knowing that suturing is needed after surgery could raise the level of anxiety which further increases the patient's perception of pain.<sup>3,4</sup>

Controlling pain and anxiety caused by implant surgery can be achieved surgically by minimally invasive procedures such as flapless implant surgery with immediate loading protocol (to avoid a second surgery for fixture exposure) and pharmacologically by the use of effective analgesics.<sup>5,6</sup>

Computer applications and systems are currently regarded as an integral facilitation technology in different medical aspects such as data analysis, computer guided therapy, imaging and telemedicine.<sup>7-9</sup>

Computer guided flapless implant surgery using cone beam computed tomography (CBCT) is an accurate, simple and minimally invasive procedure that may not require suturing and thus yields a minimal perception of pain. It was reported to have a high success rate, which was found to be comparable to that of the open flap technique.<sup>10,11</sup> The advancement of imaging techniques allowed the flapless implant surgery to be favored by many clinicians due to its reduced surgical time, faster wound healing, minimal bleeding and lesser amount of crestal bone resorption as the detachment of the periosteum is avoided.<sup>6</sup>

According to WHO (World Health Organization), paracetamol or acetaminophen is the first step on the pain control ladder and is considered as the first-line therapy for many painful conditions.<sup>12</sup> Safety of this drug and its minimal side effects makes it a valuable choice for control of pain. Unlike NSAIDs (non-steroidal anti-inflammatory drugs), paracetamol does not cause adverse effects on bone metabolism or gastro-intestinal disturbances and can be prescribed safely for patients with gastritis and peptic ulcers.<sup>13,14</sup>

It was also found that paracetamol is able to decrease the unpleasantness when patients are subjected to noise blasts. This may suggest a great benefit when used before dental operations, as we continuously need to work with noisy tools.<sup>15</sup>

Ibuprofen on the other hand, is usually regarded as a more effective analgesic than paracetamol due to its additional anti-inflammatory action by inhibiting cyclooxygenases (COX-1 and COX-2).<sup>16</sup> Unfortunately, inhibition of COX-1 affect mainly the gastric mucosa causing stomach injury and to a lesser extent platelet aggregation causing subclinical bleeding tendency.<sup>14</sup> The importance of COX-2 (which is an enzyme that promotes swelling and inflammation, thus increases the supply of cells involved in bone formation and implant osseointegration) was addresses in some studies.<sup>17,18</sup> It was shown that mice with deficiency in COX-2 had very minimal amount of bone formation around implants when compared with the control.<sup>19</sup>

Another indirect adverse effect of ibuprofen on osseointegration of dental implants is that it may lead to stomach disturbances, which may necessitate the use of proton pump inhibitors. These drugs was also found to impair osseointegration of dental implants.<sup>20</sup>

Level of salivary cortisol was found to be a reliable and accurate measure of stress and anxiety for more than half a century.<sup>21,22</sup> It was used in dentistry to measure the level of anxiety during dental treatment.<sup>23,24</sup>

To our knowledge, no other study has investigated the effect of paracetamol on stress reduction in implant surgeries. Thus, the aim of this study was to assess the ability of paracetamol to lower stress and anxiety when compared with ibuprofen during and after a minimally traumatic computer guided flapless implant surgery with immediate loading protocol using one-piece dental implant.

## Materials and methods

This study was a double blinded, cross over randomized clinical trial which was conducted at the Centre of Oral Rehabilitation. The study was following the Declaration of Helsinki guidelines and was conducted according to CONSORT recommendations. Ethical approval was obtained

from the local ethics committee (LIC2212019). Informed consent was also taken from all patients before starting treatment.

Thirty patients with age ranging from 19 to 46 years (15 males and 15 females) were enrolled into this study. The inclusion criteria were: ASA Class I or II (American Society of Anesthesiologists physical status classification), having bilateral missing lower teeth in molar area for more than 6 months, bone height and bone width not less than 12 mm and 4 mm respectively. Exclusion criteria were: history of peptic ulcers or chronic consumption of analgesics, bad oral hygiene and parafunctional habits.

Patients were randomized into 2 groups (1:1 ratio) using computer generated randomization software (Statsdirect version 2.7.7, StatsDirect Ltd., Cheshire, UK) which was done by an independent co-worker. First group ( $n = 15$ ) was assigned for flapless implant insertion in the lower molar area on one side with paracetamol followed by a washout period for 2 weeks then another implant was inserted on the contra-lateral side with ibuprofen. Second group ( $n = 15$ ) was assigned for flapless implant insertion in the lower molar area with ibuprofen followed by a washout period for 2 weeks then another implant was inserted on the contra-lateral side with paracetamol. Immediate implant loading protocol was adopted using one-piece implant design (Rough Implant, Mono Implant, Novodent, Switzerland) with 10 mm length and 3.7 mm diameter. Sides for implant placement during the first round of treatment were randomly selected by flipping of a coin.

Experienced pharmacist was assigned to conceal the drugs for blinding of the clinician and the patient. Paracetamol was prepared in yellow colored capsules and ibuprofen was prepared in green color capsules. Each yellow capsule contained 1000 mg of paracetamol while green capsules contained 600 mg of ibuprofen. All yellow and green capsules were identical in shape. These capsules were provided to the patients in closed containers, each containing 10 capsules and labelled by yellow and green colors according to the color of the capsules inside. Patients were informed to avoid any other type of analgesic other than the given one. Capsules were given 1 h before surgery and every 8 h for a period of 3 days after the day of surgery.

Before surgery, a surgical guide was constructed from a CBCT image. Each patient received 2 g of amoxicillin or 600 mg clindamycin if allergic to penicillin and 1 capsule of the assigned analgesic (either yellow or green) 1 h before surgery and rinsed with antiseptic mouthwash (chlorhexidine 0.2%) for 1 min. Patients were treated under local anesthesia using articaine with epinephrine 1: 100,000. CAD/CAM surgical template was utilized to accurately determine the exact position of the osteotomy site. A 3.5 mm tissue punch was utilized to punch the tissue, the osteotomy site was prepared according to the surgical protocol of the manufacturer, and provisional crowns were utilized to cover the implants.

Most of the patients needed more than two implants to construct a prosthesis so additional implants were inserted after the end of the study. The implant insertion was done by a single well trained clinician who did not take part in the evaluation of the results. Both the patients and the evaluator were blinded to the random allocation.

Stress and anxiety were assessed by measuring the salivary cortisol level at the same time every day and was regarded as the primary outcome of the study. Patient were instructed to avoid eating, drinking, brushing, smoking and exercising for at least one hour before collection of the samples and refrain from alcohol and caffeine for 24 h before the test. To collect the salivary samples for analysis Salivette® Cortisol (Sarstedt, Rommelsdorft, Germany) was utilized following manufacturer instructions. Samples of saliva were collected 1 day before surgery to determine the baseline level of cortisol in the saliva and were analyzed by a laboratory technician who was blinded to the groups of study.

Other secondary outcomes were the degree of pain and swelling. Pain was assessed by using Visual Analogue Scale (VAS) on scale from 0 to 100. Swelling was also evaluated using a scale ranging from 0 to 3 where, 0: denotes no swelling, 1: denotes intra oral swelling limited to the area of implant placement, 2: denotes intra oral swelling beyond the area of implant placement, 3: denotes extra oral swelling. Swelling was assessed using a computer vision system developed by the authors to avoid subjectivity, which was revised visually for confirmation.

The system has the ability to instantaneously display the score, creating spatial graphs and tables as well as constructing comparisons with previous scores. The swelling was calculated by analyzing shape and color characteristics. This software was trained by a professional dentist to effectively provide pixel-wise swelling segmentations. The problem of deviations in the camera's location, angle, and lighting conditions was handled by larger datasets, which is evenly distributed with many variations of different positions, rotations, and brightness.

Collection and evaluation of pain and swelling scores were done by a single clinician who was blinded to the groups after 2 h, 6 h then after 1, 2, 3, 4 and 7 days post-surgically. Saliva samples were also collected at the same periods but with additional samples taken at the day before surgery, immediately before surgery and 1 h after surgery. All outcomes were collected at the same time of the day for all patients.

The sample size was calculated based on the primary outcomes with a power of 80% and level of significance of 5% ( $\alpha = 0.05$ ). This analysis showed that the sample size was adequate. Differences between the two drugs were assessed by means and standard deviations. Comparison between the two drugs was done using chi square test and paired t-test and for the changes in each group using repeated measure ANOVA. All data were statistically analyzed by an independent statistician who was blinded to the types of drugs using IBM SPSS statistical software version 20 (IBM, NY, USA).

## Results

Only twenty-nine (15 males and 14 females) of the thirty patients that were enrolled in the study completed the total period which was one month for every patient (See Fig. 1). The mean age of patients was  $33.7 \pm 9.3$  years.

Salivary cortisol level showed a statistically significant difference with a significantly higher level in the ibuprofen

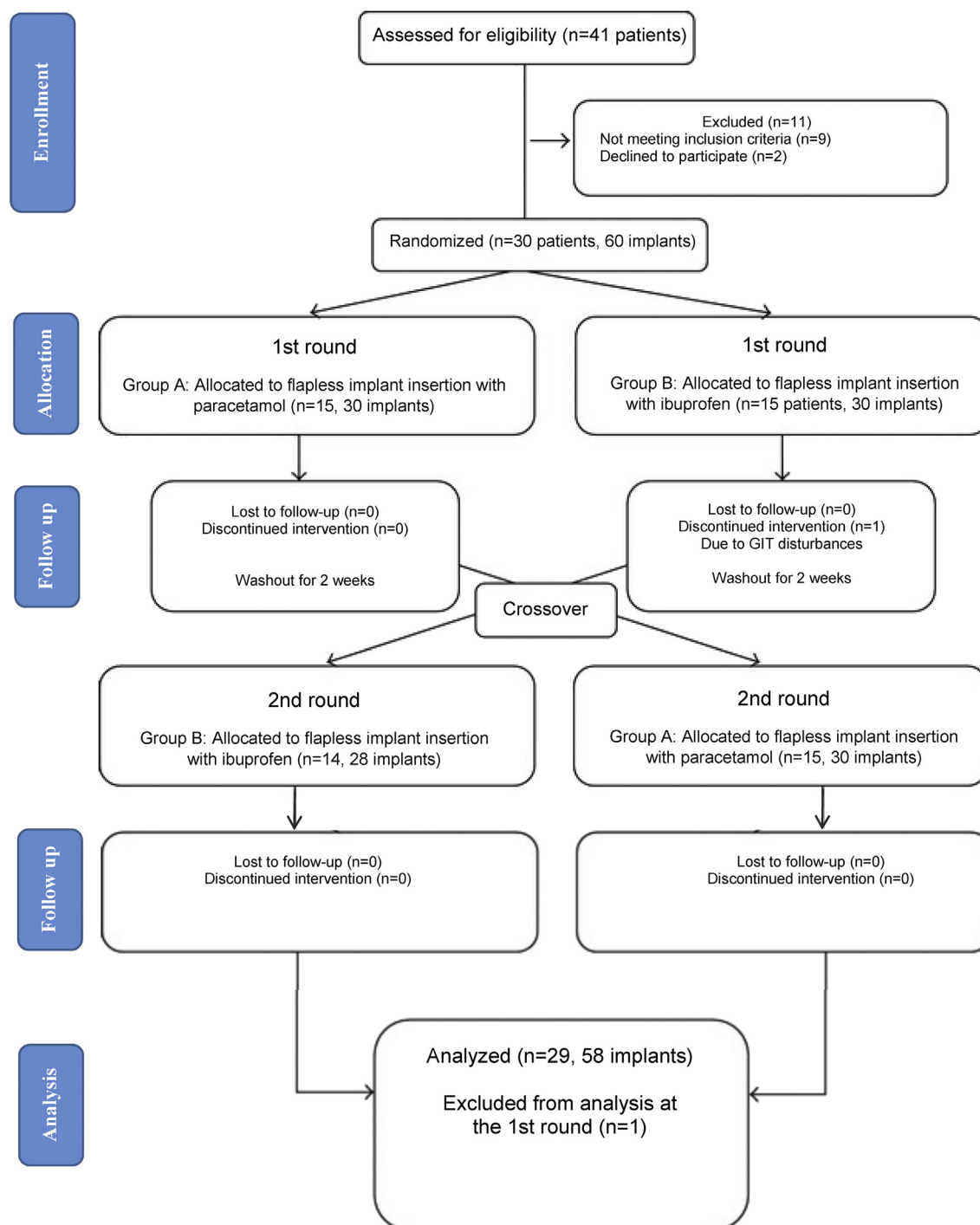


Figure 1 The CONSORT flow diagram.

groups. Levels of salivary cortisol increased immediately before surgery in both groups but with minimal amount in the paracetamol group; while in the ibuprofen group a marked increase was observed ( $4.1 \pm 1.08$  ng/mL for paracetamol group and  $6.2 \pm 0.94$  ng/mL for the ibuprofen group) compared to the average baseline records which was  $3.09 \pm 2.55$  ng/mL at the same time in 1 day pre-operatively ( $p < 0.5$ ). The cortisol level continued to increase in both groups at 1 h post-operatively with lower

levels in the paracetamol group. The highest levels of salivary cortisol in both groups were recorded at 2 h post-operatively ( $5.9 \pm 1.41$  ng/mL for paracetamol group and  $7.8 \pm 1.53$  ng/mL for the ibuprofen group). This was followed by a marked decline at 6 h in both groups. At day 1 (morning hours) there was an increase in the average cortisol levels which were higher than the baseline record of the day before surgery ( $3.7 \pm 0.85$  ng/mL for paracetamol group and  $4.9 \pm 1.03$  ng/mL for the ibuprofen group)

but was also significantly lower in the paracetamol group when compared to ibuprofen group. Day 2 and day 3 demonstrated a gradual decrease in the levels of cortisol in both groups with slightly lower values in the paracetamol group but without statistically significant differences ( $p > 0.5$ ). At day 4 and 7 the levels of cortisol returned to its normal levels with no statistically significant differences between groups (Fig. 2).

In general, no statistically significant differences were detected in the pain score between the paracetamol group and ibuprofen group. The pain in the paracetamol group scored a mean of  $13.1 \pm 1.1$  while in the ibuprofen group it was  $12.9 \pm 2.3$  ( $P > 0.05$ ). The pain score gradually increased in both groups from 2h to 6h then it gradually declined in the next three days and it nearly disappeared in most of the patients at day 4 post-operatively (Fig. 3).

On the other hand, swelling showed a statistically significant difference between groups with an obviously higher

score in the paracetamol group ( $0.91 \pm 0.41$  for the paracetamol group and  $0.61 \pm 0.31$  for ibuprofen group) ( $P < 0.05$ ). At 2 h post-operatively swelling was minimal in the paracetamol group and nearly absent in the ibuprofen group ( $0.98 \pm 0.28$  and  $0.31 \pm 0.09$  respectively). After 6 h, swelling increased in both groups and again showing higher swelling score in the paracetamol group. The highest swelling scores were observed at day 1 and 2 post-operatively with significantly higher scores in the paracetamol group. No significant differences were observed between groups at day 4 and 7 (Fig. 4).

### Discussion

Pain and anxiety control after implant surgery is an important aspect for many patients as it may have a strong impact on their desire for completion of the treatment. This study was a randomized cross over clinical trial which

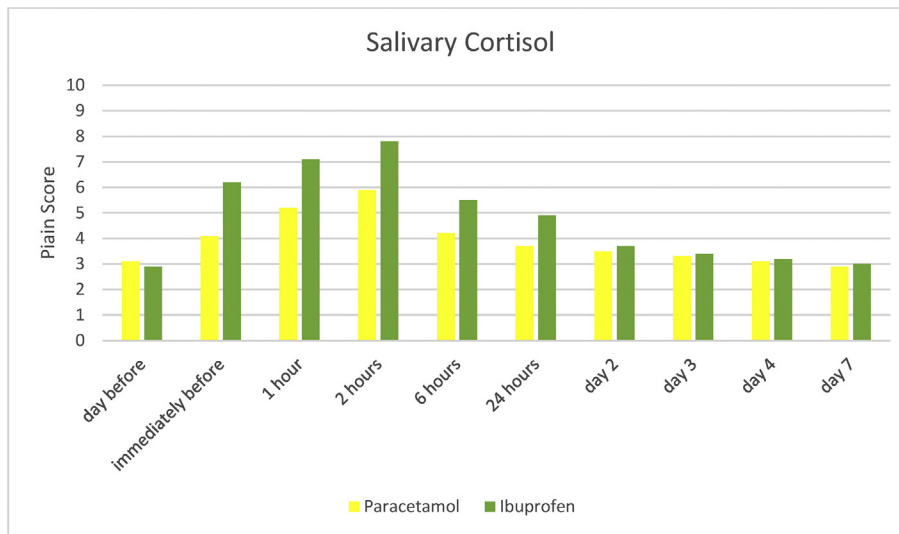


Figure 2 Salivary cortisol score during different follow-up periods in paracetamol and ibuprofen groups.

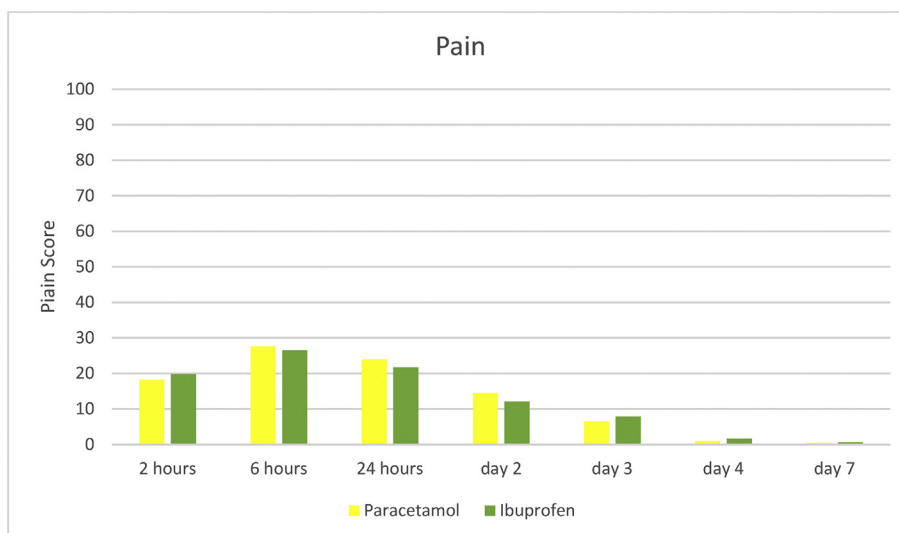
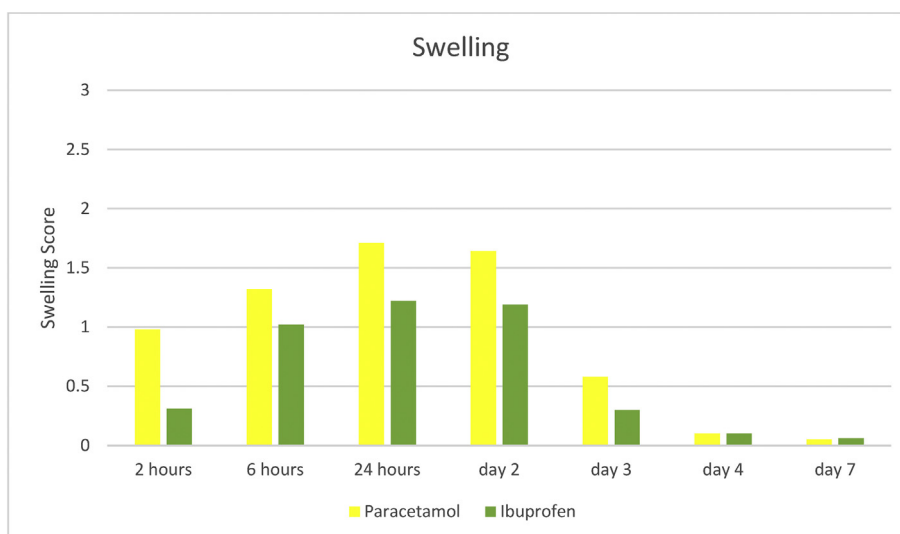


Figure 3 Pain score during different follow-up periods in paracetamol and ibuprofen groups.



**Figure 4** Swelling score during different follow-up periods in paracetamol and ibuprofen groups.

was designed to assess the efficiency of paracetamol as stress reducing drug during and after implant insertion.

The main advantage of the crossover design is that it only requires a smaller sample size when compared to the parallel design combined with the elimination of inter-individual variabilities between subjects thus giving a more precise results than parallel groups.<sup>25</sup> A wash out period of 2 weeks after each round was chosen to ensure the complete resolution of pain and swelling following implant surgery before starting the second round of treatment.

Regarding stress and anxiety, it was noted that the highest level of anxiety was recorded after 2 h of surgery due to the resolution of the local anesthetic effect. Paracetamol was able to significantly lower the level of anxiety before, during, and after implant surgery. This was consistent with another study that found that when taking paracetamol, a lower cortisol levels in challenging tasks were recorded when compared to NSAIDs.<sup>26</sup> The effect of paracetamol on lowering anxiety and pain was also assessed by many studies that found a marked blunting effect of emotions after administration of paracetamol and showed that even if the person feels pain, this no longer bothers him.<sup>15,27–30</sup> A possible explanation for this is the ability of paracetamol to decrease the neural activity in the anterior cingulate cortex and anterior insula of the brain which controls the negative emotional response to pain.<sup>30</sup>

Pain score did not show any major differences between groups. The logical reason is that both drugs have adequate analgesic properties that acts centrally on the brain but with different mechanisms.<sup>31</sup> The highest pain score was recorded at 6 h post-operatively and then declined gradually. This can be explained by the gradual increase in chemical mediators that causes pain and swelling during the first 3–6 h after surgery.<sup>32,33</sup>

Pain intensity was ranging from mild to moderate on average, with mild pain being more dominant in all cases. This was explained by the preemptive effect of analgesics, which means administering the analgesic before surgery to prevent the reaction of pain before it starts. This method of administration was reported in many studies to significantly decrease pain when compared with patients who received

analgesics after surgery.<sup>34–37</sup> This finding was also consistent with another study that measured pain and anxiety following placement of implant and found low to moderate pain levels after implant insertion.<sup>38</sup>

A profound analgesia was achieved by using paracetamol with a dose of 1000 mg. Such dosage was chosen to attain a higher bioavailability which was reported to be 0.89 when compared with a dose of 500 mg which is 0.63 and thus reaching adequate analgesic effect and still being within the safe dose of the drug.<sup>39,40</sup> Paracetamol has a main advantage over ibuprofen of being well tolerated by patients suffering from gastrointestinal problems and even in patients with renal impairment.<sup>39,41</sup> This was reflected in the results of this study as no one complained about gastrointestinal disturbances caused by paracetamol while one of the patients could not tolerate ibuprofen and showed symptoms of gastritis, which necessitated her exclusion from the study and substitution of ibuprofen with paracetamol to relieve pain.

Ibuprofen on the other hand, is one to the members of NSAIDs having an advantage over other types of NSAIDs being less irritant to gastric mucosa with a lower incidence of gastrointestinal bleeding when compared to diclofenac and naproxen. It also has a limited ability to cause gastrointestinal irritation when compared with other types of NSAIDs.<sup>14,42</sup> It was also found that a dose higher than 600 mg of ibuprofen appeared to show very little additional analgesic effect with higher risk of side effects from the drug.<sup>43</sup>

Effect of ibuprofen on osseointegration showed conflicting results with most of studies confirms its negative effect on osseointegration only on long term administration. However, the administration period of ibuprofen in this study was only 3 days which is a relatively short period of time and cannot have any negative effect on osseointegration as most of the studies reported such effect after a week or more of administration.<sup>18,44</sup>

It was not surprising to find that swelling was significantly lower in the ibuprofen group as it is well known that ibuprofen has an obvious anti-inflammatory effect while paracetamol lacks such effect.<sup>37</sup> It is worth to mention that

flapless implant surgery did not cause any extra-oral swelling even in the paracetamol group because of its minimally invasive nature.

It is still needed to assess paracetamol in more invasive implant surgeries. Combining both paracetamol and ibuprofen to decrease anxiety and swelling was not attempted in this study due to the limitation caused by the selected study design. Assessing such effect may be useful to combine the advantages of both drugs and to decrease their dose and thus reducing their side effects.

It can be concluded that in addition to its analgesic effect, paracetamol can be regarded as a safe and effective stress-reducing drug that may allow the patient to tolerate pain with minimal anxiety especially if used with computer guided minimally invasive flapless implant surgeries. However, paracetamol failed to control swelling when compared with ibuprofen. On the other hand, ibuprofen was significantly less effective in controlling stress and anxiety when compared with paracetamol. Computer guided flapless implant surgery with immediate loading protocol following administration of paracetamol can be recommended for fearful and low pain threshold patients especially if patients are suffering from gastro-intestinal disturbances.

## Declaration of competing interest

The authors have no conflict of interest to declare.

## Acknowledgements

None.

## References

- Wong HM, Mak CM, To WM. Development of a dental anxiety provoking scale: a pilot study in Hong Kong. *J Dent Sci* 2015;10:240–7.
- Lin CS, Wu SY, Yi CA. Association between anxiety and pain in dental treatment: a systematic review and meta-analysis. *J Dent Res* 2017;96:153–62.
- Al-Khabbaz AK, Griffin TJ, Al-Shammari KF. Assessment of pain associated with the surgical placement of dental implants. *J Periodontol* 2007;78:239–46.
- Jung W, Lee KE, Suh BJ. Influence of psychological factors on the prognosis of temporomandibular disorders pain. *J Dent Sci* 2020. <https://doi.org/10.1016/j.jds.2020.02.007> (in press).
- Lai YL, Kao SY, Yeung TC, Lee SY. Rapid implant therapies: immediate implant placement and immediate restoration. *J Dent Sci* 2009;4:1–6.
- Romero-Ruiz MM, Mosquera-Perez R, Gutierrez-Perez JL, Torres-Lagares D. Flapless implant surgery: a review of the literature and 3 case reports. *J Clin Exp Dent* 2015;7:e146.
- Adly MS, Adly AS, Adly AS. Assessment of early orthodontic treatment on functional shifts by telemonitoring mandibular movements using a smart phone. *J Telemed Telecare* 2020;26:150–60.
- Adly AS, Adly AS, Adly MS, Mostafa YM, El Sayed AEHI. Effectiveness of laser acupuncture as adjunctive therapy for limited range of motion in rheumatoid arthritis. *Laser Phys* 2018;29:025601.
- Adly AS, Adly AS, Adly MS, Serry ZM. Laser acupuncture versus reflexology therapy in elderly with rheumatoid arthritis. *Laser Med Sci* 2017;32:1097–103.
- Romanos GE, Aydin E, Locher K, Nentwig GH. Immediate vs. delayed loading in the posterior mandible: a split-mouth study with up to 15 years of follow-up. *Clin Oral Implants Res* 2016;27:e74–9.
- Poli PP, Muktadar AK, Souza FÁ, Maiorana C, Beretta M. Computer-guided implant placement associated with computer-aided bone regeneration in the treatment of atrophied partially edentulous alveolar ridges: a proof-of-concept study. *J Dent Sci* 2020. <https://doi.org/10.1016/j.jds.2020.02.010> (in press).
- Jordan K, Arden N, Doherty M, et al. EULAR recommendations 2003: an evidence based approach to the management of knee osteoarthritis: report of a task force of the standing committee for international clinical studies including therapeutic trials (ESCISIT). *Ann Rheum Dis* 2003;62:1145–55.
- Bannwarth B, Pehourcq F. Pharmacological rationale for the clinical use of paracetamol: pharmacokinetic and pharmacodynamic issues. *Drugs* 2003;63:5–13.
- Matsui H, Shimokawa O, Kaneko T, Nagano Y, Rai K, Hyodo I. The pathophysiology of non-steroidal anti-inflammatory drug (NSAID)-induced mucosal injuries in stomach and small intestine. *J Clin Biochem Nutr* 2011;48:107–11.
- Mischkowski D, Crocker J, Way BM. From painkiller to empathy killer: acetaminophen (paracetamol) reduces empathy for pain. *Soc Cognit Affect Neurosci* 2016;11:1345–53.
- Weiser T, Richter E, Hegewisch A, Muse D, Lange R. Efficacy and safety of a fixed-dose combination of ibuprofen and caffeine in the management of moderate to severe dental pain after third molar extraction. *Eur J Pain* 2018;22:28–38.
- Gomes FIF, Aragão MGB, de Paulo Teixeira Pinto V, et al. Effects of nonsteroidal anti-inflammatory drugs on osseointegration: a review. *J Oral Implantol* 2015;41:219–30.
- Apostu D, Lucaciu O, Lucaciu GDO, et al. Systemic drugs that influence titanium implant osseointegration. *Drug Metab Rev* 2017;49:92–104.
- Chikazu D, Tomizuka K, Ogasawara T, et al. Cyclooxygenase-2 activity is essential for the osseointegration of dental implants. *Int J Oral Maxillofac Surg* 2007;36:441–6.
- Al Subaie A, Emami E, Tamimi I, et al. Systemic administration of omeprazole interferes with bone healing and implant osseointegration: an in vivo study on rat tibiae. *J Clin Periodontol* 2016;43:193–203.
- Hellhammer DH, Wüst S, Kudielka BM. Salivary cortisol as a biomarker in stress research. *Psychoneuroendocrinology* 2009;34:163–71.
- Dembinska E, Rutkowski K, Sobanski J, Cyranka K, Mielimaka M, Citkowska-Kisielewska A. The cortisol awakening response in anxiety disorders and personality disorders and changes in salivary cortisol level after psychotherapy. *Eur Psychiatr* 2017;41:S408.
- Gadicherla S, Shenoy RP, Patel B, Ray M, Naik B, Pentapati KC. Estimation of salivary cortisol among subjects undergoing dental extraction. *J Clin Exp Dent* 2018;10:e116.
- AlMaummar M, AlThabit HO, Pani S. The impact of dental treatment and age on salivary cortisol and alpha-amylase levels of patients with varying degrees of dental anxiety. *BMC Oral Health* 2019;19:1–8.
- Elbourne DR, Altman DG, Higgins JP, Curtin F, Worthington HV, Vail A. Meta-analyses involving cross-over trials: methodological issues. *Int J Epidemiol* 2002;31:140–9.
- Hibel LC, Granger DA, Kivlighan KT, Blair C, Investigators FLP. Individual differences in salivary cortisol: associations with common over-the-counter and prescription medication status in infants and their mothers. *Horm Behav* 2006;50:293–300.

27. Gross JJ, John OP. Revealing feelings: facets of emotional expressivity in self-reports, peer ratings, and behavior. *J Pers Soc Psychol* 1997;72:435–48.
28. Maio GR, Esses VM. The need for affect: individual differences in the motivation to approach or avoid emotions. *J Pers* 2001;69:583–614.
29. Randles D, Heine SJ, Santos N. The common pain of surrealism and death: acetaminophen reduces compensatory affirmation following meaning threats. *Psychol Sci* 2013;24:966–73.
30. Durso G. Over-the-counter relief from pains and pleasures alike: acetaminophen blunts sensitivity to both negative and positive reactions. *Psychol Sci* 2015;26:750–8.
31. Pozzi A, Gallelli L. Pain management for dentists: the role of ibuprofen. *Ann Stomatol* 2011;2:3–24.
32. Larrazábal C, García B, Peñarrocha M, Peñarrocha M. Influence of oral hygiene and smoking on pain and swelling after surgical extraction of impacted mandibular third molars. *J Oral Maxillofac Surg* 2010;68:43–6.
33. López-Ramírez M, Vilchez-Pérez MÁ, Gargallo-Albiol J, Arnat-Domínguez J, Gay-Escoda C. Efficacy of low-level laser therapy in the management of pain, facial swelling, and postoperative trismus after a lower third molar extraction. A preliminary study. *Laser Med Sci* 2012;27:559–66.
34. Ong CKS, Lirk P, Seymour RA, Jenkins BJ. The efficacy of preemptive analgesia for acute postoperative pain management: a meta-analysis. *Anesth Analg* 2005;100:757–73.
35. Mahgoobifard M, Mirmesdagh Y, Imani F, Najafi A, Nataj-Majd M. The analgesic efficacy of preoperative oral Ibuprofen and acetaminophen in children undergoing adenotonsillectomy: a randomized clinical trial. *Anesthesiol Pain Med* 2014;4:e15049.
36. Kharouba J, Hawash N, Peretz B, et al. Effect of intravenous paracetamol as pre-emptive compared to preventive analgesia in a pediatric dental setting: a prospective randomized study. *Int J Paediatr Dent* 2018;28:83–91.
37. Kharouba J, Ratson T, Somri M, Blumer S. Preemptive analgesia by paracetamol, ibuprofen or placebo in pediatric dental care: a randomized controlled study. *Int J Clin Pediatr Dent* 2019;43:51–5.
38. Hashem AA, Claffey NM, O'Connell B. Pain and anxiety following the placement of dental implants. *Int J Oral Maxillofac Implants* 2006;21:943–50.
39. Bannwarth B, Pehourcq F. Pharmacological rationale for the clinical use of paracetamol: pharmacokinetic and pharmacodynamic issues. *Drugs* 2003;63:5–13.
40. Lee S. Paracetamol misuse/overdose. *Reactions* 2016;1629:194–226.
41. Rao TD, Kumar MS. Analgesic efficacy of paracetamol vs ketorolac after dental extractions. *Res J Pharm Technol* 2018;11:3375–9.
42. Pérez-Gutthann S, Jick S. Pharmacq epidemiology. *Pharmacotherapy* 1999;19:854–9.
43. Moore PA, Hersh EV. Combining ibuprofen and acetaminophen for acute pain management after third-molar extractions: translating clinical research to dental practice. *J Am Dent Assoc* 2013;144:898–908.
44. Samieirad S, Afrasiabi H, Tohidi E, et al. Evaluation of caffeine versus codeine for pain and swelling management after implant surgeries: a triple blind clinical trial. *J Cranio Maxill Surg* 2017;45:1614–21.