

OPEN

# Corneal Complications During and After Vitrectomy for Retinal Detachment in Photorefractive Keratectomy Treated Eyes

Gian Marco Tosi, MD, PhD, Stefano Baiocchi, MD, Angelo Balestrazzi, MD, PhD, Gianluca Martone, MD, Davide Marigliani, MD, Giovanni Neri, MD, and Tomaso Caporossi, MD, PhD

**Abstract:** To evaluate the occurrence of late-onset corneal haze (LOCH) after vitrectomy for rhegmatogenous retinal detachment (RRD) in photorefractive keratectomy (PRK)-treated eyes.

This observational cohort study comprised 13 eyes of 13 patients who underwent vitrectomy for RRD and who had been subjected to PRK years earlier. The occurrence of LOCH was evaluated together with all the preoperative, intraoperative, and postoperative factors that could affect final corneal status.

LOCH developed in 2 eyes. Both patients had undergone PRK for high myopia—one 3 years and the other 9 years prior to RRD. Both patients presented with RRD due to giant retinal tear and were subjected to scleral buckle, 20-gauge vitrectomy, and silicone oil tamponade. Three months after vitrectomy and 1 month after silicone oil removal they both developed LOCH. During vitreoretinal surgery neither of the 2 patients needed mechanical epithelial debridement. Intraoperative epithelial debridement was performed in 2 of the other patients of the series, who had undergone previous PRK for high myopia and had clear corneas at presentation; in 1 of them this manoeuvre hampered intraoperative visualization. Follow-up after retinal detachment surgery ranged from 6 to 156 months (mean, 37.5 months).

Subepithelial corneal scarring may be reactivated many years after PRK. In our series this happened after vitrectomy.

(*Medicine* 94(50):e2215)

**Abbreviations:** BCVA = best corrected visual acuity, IOL = intraocular lens, IOP = intraocular pressure, LASEK = laser-assisted subepithelial keratectomy, LOCH = late-onset corneal haze, MMC = mitomycin-C, NSAID = nonsteroidal anti-inflammatory drugs, PDGF = platelet-derived growth factors, PPV = pars plana vitrectomy, PRK = photorefractive keratectomy, PTK = phototherapeutic keratectomy, PVR = proliferative vitreoretinopathy, RRD = rhegmatogenous retinal detachment, SB = scleral buckling, TGFB = transforming growth factor B, UV = ultraviolet light.

Editor: Alparslan Sahin.

Received: August 22, 2015; revised: October 27, 2015; accepted: November 8, 2015.

From the Ophthalmology Unit of the Department of Medicine, Surgery and Neuroscience, University of Siena, Siena (GMT, SB, AB, GM, DM, GN); and Ophthalmology Department, University of Florence, AOUC, Florence, Italy (TC).

Correspondence: Gian Marco Tosi, Ophthalmology Unit, Department of Medicine, Surgery and Neuroscience, University of Siena, Viale Bracci 1, 53100 Siena, Italy (e-mail: gmtosi@tin.it).

The authors have no funding and conflicts of interest to disclose.

Copyright © 2015 Wolters Kluwer Health, Inc. All rights reserved.

This is an open access article distributed under the Creative Commons Attribution-NonCommercial-NoDerivatives License 4.0, where it is permissible to download, share and reproduce the work in any medium, provided it is properly cited. The work cannot be changed in any way or used commercially.

ISSN: 0025-7974

DOI: 10.1097/MD.0000000000002215

## INTRODUCTION

Photorefractive keratectomy (PRK) is widely and safely used for the correction of myopia. However, the subsequent wound healing-related response may lead to postoperative complications (ie, regression, and reduction of corneal clarity, termed “haze”). In most corneas the level of haze is minimal and transient; more rarely some corneas, especially those with corrections of greater than 6 diopters of myopia, develop severe and clinically significant haze.<sup>1–3</sup> This last form, termed late-onset corneal haze (LOCH), shows documentable clinical and biological differences from the milder and more common form and is usually noted between 2 and 5 months after otherwise uneventful surgery.<sup>4–10</sup>

LOCH is more frequent in eyes that have not been treated with mitomycin-C (MMC) prophylaxis but has also been reported following MMC prophylaxis, confirming the very complex and sometimes unpredictable biological response at its basis.<sup>3,11,12</sup> Severe LOCH has been reported in PRK-treated eyes without MMC prophylaxis after epithelial debridement,<sup>13</sup> retreatment,<sup>14</sup> or trauma<sup>11</sup> and, spontaneously<sup>12</sup> or after trauma,<sup>3</sup> in laser-assisted subepithelial keratectomy (LASEK) with MMC prophylaxis.

In 2004, we reported a case of late corneal scarring after pars plana vitrectomy (PPV) without intraoperative epithelial debridement, which occurred 42 months after PRK without MMC prophylaxis.<sup>15</sup> Since then we have treated with PPV for rhegmatogenous retinal detachment (RRD) 12 more patients who were previously subjected to PRK.

The trend among retinal specialists of performing primary PPV instead of scleral buckle is increasing worldwide and in the near future a growing number of refractive surgery-treated eyes will probably be managed with PPV if affected by RRD.

In the present case series, we evaluated the occurrence of LOCH after PPV for RRD in PRK-treated eyes without MMC prophylaxis.

## METHODS

We reviewed the clinical records of patients affected by RRD who underwent PPV at the Ophthalmology Unit of the Department of Medicine, Surgery and Neuroscience, University of Siena, Siena, Italy, and who had been previously subjected to PRK without MMC prophylaxis. The research conformed to the provisions of the 1995 Declaration of Helsinki (as revised in Edinburgh in 2000), and the institutional review board approved the study. The inclusion criteria were: having undergone PRK for myopia correction followed by PPV for RRD with and without proliferative vitreoretinopathy (PVR),<sup>16</sup> and use of the same contact panoramic viewing system during PPV surgery (AVI lenses).<sup>17</sup>

Exclusion criteria were: a history of diabetes mellitus; prior intraocular surgery, except cataract surgery or vitreoretinal surgery; glaucoma; ocular traumas; and ocular surface disease.

All patients were operated on under general or local anesthesia and subjected to PPV. Scleral buckling (SB) was associated with PPV in all patients. Three-port PPV was performed using 1 of 2 types of vitrectomy instrument (Bausch and Lomb Millennium, Bausch and Lomb, Rochester, NY; or the Bausch and Lomb Stellaris PC, Bausch and Lomb, Rochester, NY) and using a panoramic viewing system with wide angle contact lenses (Advanced Vitreous Instruments, New York).

For those patients who had been previously subjected to scleral buckle for RRD, no SB revision was performed. Intraocular tamponade was performed with either silicone oil 1000 cSt or gas (C3F8). When deemed necessary by the surgeon, cataract surgery was performed through phacoemulsification and intraocular lens (IOL) implantation in phakic patients, to achieve adequate posterior segment visualization. All patients were subjected to corneal endothelial cell count.

In patients' ocular history we reviewed: time of PRK treatment; interval between PRK and PPV; excimer laser used for PRK; eye axial length; pre-PRK refractive error; corneal pachymetry before PRK; corneal diseases before PRK; ablation zone; ablation depth; ratio between ablation depth and pre-PRK pachymetry; corneal pachymetry post-PRK; myopic regression; notes reporting haze post-PRK; cataract surgery and the year of its performance, together with any associated complications; retinal surgery and the year of its performance, together with any associated complications.

The following variables were recorded before PPV: best corrected visual acuity (BCVA) at first visit, and anterior segment status following PRK, including phakic status, intraocular pressure (IOP), and RRD characteristics. As for the corneal status, we evaluated the presence of haze. Corneal haze was measured at the slit lamp and graded from 0 to 4 according to a clinical system described by Fantès et al.<sup>18,19</sup> A corneal endothelial cell count was performed in patients who were scheduled to undergo combined cataract surgery, in those who were phakic without a combined surgical plan, and in those who were pseudophakic.

From the surgical notes of the PPV procedure we recorded: surgical time; type of PPV (noncannulated 20-gauge, protected 23- or 25-gauge); PPV-associated procedures (scleral buckle, cataract surgery, and PVR removal); the intraoperative use as a corneal lubricant of either hydroxypropyl methylcellulose 2% (HPMC 2%) (Gel 4000, Bruschettini, Genoa, Italy)<sup>17</sup> or sodium hyaluronate 1.2% (IAL; Bausch & Lomb Inc, Rochester, NY);<sup>17</sup> intentional intraoperative epithelial debridement; intraoperative visibility problems; bottle height; tamponade at the end of the procedure (silicone oil, gas; in case of gas, its type and concentrations were recorded); and any PPV-associated complications.

Post-PPV we recorded: intraocular pressure and any need for postoperative IOP-lowering medication; epithelial alterations/defects; re-epithelialization time; the need to achieve re-epithelialization of eye patching, bandage contact lens application and steroid and nonsteroidal anti-inflammatory drugs (NSAID) discontinuation; worsening of preoperative corneal haze, as well as the occurrence of LOCH and its treatment; postoperative topical medications and duration of their application.

As for post-PPV procedures, we noted: time of silicone oil removal; procedures associated with oil removal; PVR recurrence; post-PPV cataract surgery; time interval between PPV and post-PPV cataract surgery; and any associated cataract surgery complications.

The main outcome measure was a change in subepithelial corneal status after PPV.

## RESULTS

Detailed information regarding the demographics and clinical course of each patient is provided in Tables 1 and 2.

Eleven patients did not undergo cataract or retinal surgery before PRK; 1 patient underwent cataract surgery complicated by posterior capsule rupture (patient 2) and another underwent scleral buckle for RRD (patient 3).

Axial length ranged from 24.28 to 30.11 mm (mean: 27.81 mm). Four patients showed myopic regression after PRK (patients 6, 9, 10, and 11) but none of them showed haze at presentation nor developed LOCH after PPV (Tables 1 and 2).

Between PRK and presentation 2 patients underwent retinal surgery: 1 showed RRD after 20-gauge PPV and gas tamponade for myopic macular hole (patient 10) and the other showed recurrent RRD after scleral buckle (patient 11).

At presentation all patients presented with clear corneas except 2 who showed trace haze; 1 of them developed LOCH after PPV, while in the other the corneal opacity remained unchanged after PPV. Twelve out of the 13 patients showed an endothelial cell count of above 2000 cells, while patient 11 presented with Fuchs endothelial corneal dystrophy and an endothelial cell count of 900 cells. His cornea remained clear after combined cataract surgery, PPV, and silicone oil tamponade (follow-up: 24 months) (Table 2).

Intraocular pressure at entry ranged from 12 to 20 mm Hg (mean: 14 mm Hg); no patient was on anti-glaucoma medication or had a history of glaucoma.

Retinal detachment occurrence after PRK ranged from 1 to 16 years (mean: 9.6 years).

Three patients (nos. 2, 12, and 13) presented with a giant retinal tear. Patients 12 and 13 developed LOCH. Two patients (nos. 1 and 5) presented with grade B PVR (Table 2).

Patients 1, 7, 12, and 13 underwent 20-gauge PPV using the Bausch and Lomb Millennium (Bausch and Lomb), while the others underwent 23-gauge PPV using the Bausch and Lomb Stellaris PC (Bausch and Lomb).

Follow-up after retinal detachment surgery ranged from 6 to 156 months (mean: 37.5 months) (Table 2).

No rise in bottle height was documented in any of the patients.

Surgical time ranged between 120 and 205 minutes (mean: 166 minutes). Patients 12 and 13, who experienced LOCH after PPV, had surgical procedure times of 180 and 160 minutes, respectively.

Due to corneal epithelial edema and clouding, patients 6 and 9 underwent intraoperative epithelial debridement. In patient 6 the manoeuvre was followed by an immediate increase in visualization, while in patient 9 visualization was further reduced after epithelial debridement. In this second patient PRK was performed with a high ablation depth and small ablation zone. Notwithstanding, both achieved complete re-epithelialization 1 week after surgery, not requiring eye patching, bandage contact lens, or steroid and anti-inflammatory drug continuation. Neither of them developed reopening of the epithelial corneal defect, or experienced clinically evident subepithelial corneal scarring (Table 2).

The other patients, who did not undergo intraoperative epithelial debridement, did not experience epithelial corneal

TABLE 1. Demographics; Refractive and Corneal Parameters

Patient-Sex/Age	Myopic Refractive Error (Diopters)	Pre-PRK Corneal Pachymetry (μm)	Excimer Laser Type (PRK Time)	Optical Zone	Ablation Depth (μm)	Ablation depth/corneal pachymetry ratio	Post-PRK corneal pachymetry (μm)	Myopic regression	Haze after PRK
1-M/65	-2.5=-1.5 ax 170	530	Technolas (2001)	5.5	61	0.11	469	no	0
2-M/55	-1=-0.75ax75	544	Technolas WF (2003)	6.2	100	0.18	444	no	0
3-F/35	-3.5=-0.5 ax 20	595	Technolas (2012)	6.4	76	0.12	519	no	0
4-F/58	-5.5=-1.5ax180	553	Technolas (2000)	6	120	0.21	433	no	0
5-M/54	-5.5=-0.5 ax 20	488	Technolas TS (2013)	6	80	0.16	408	no	0
6-M/52	-7.50=-3ax180	610	Technolas (1997)	6	120	0.19	490	yes	0
7-M/62	-10=-1ax180	540	Technolas (1998)	5	126	0.23	414	no	trace
8-F/64	-9=-3ax95	556	Technolas (2000)	5.5	170	0.3	386	no	0
9-F/56	-16	540	VISX 20/20 (2000)	4.5	123	0.22	417	yes	0
10-M/65	-7.5=-2.5 ax 160	553	Technolas (1999)	5.2	130	0.23	423	yes	0
11-M/54	-8.5	551	VISX 20/20 (2000)	5	98	0.17	453	yes	0
12 <sup>1,5</sup> -M/45	-9=-3ax50	607	Technolas (1998)	4.2	134	0.22	473	no	trace
13-F/41	-8.50 -2.00 ax 100	621	Technolas (1998)	5.8	171	0.27	450	no	0

alterations after surgery, or postoperative corneal disepithelialization (Table 2).

The number of postoperative medications and their duration and frequency of application did not differ among patients, except in patients 2, 4, and 8 who needed combined topical antiglaucoma medication for raised IOP. This additional therapy was discontinued 15 days after surgery when IOP returned within the normal range. The temporary IOP rise in patients 2, 4, and 8 did not affect the corneal wound healing process.

Silicone oil was removed between 2 and 4 months. No further surgery was needed, except in patient 5 who required additional membrane peeling at the time of silicone oil removal (4 months after PPV) and new tamponing with silicone oil. Following the second PPV the silicone oil remained in the eye for an additional 11 months, due to the patient having work problems. He did not develop haze or LOCH after either procedure (Table 2).

Five patients underwent cataract surgery at the time of PPV (patients 3, 5, 6, 8, 11), while patients 1, 4, 7, 9, 12, and 13 underwent cataract surgery 12, 9, 12, 10, 12, and 5 months after PPV, respectively (Table 2).

**LOCH Patients (Nos.12 and 13)**

Herein, we illustrate the case of patient 13, since that of patient 12 has been already illustrated in a previous paper.<sup>15</sup> (See essential features in Tables 1 and 2).

**Patient 13**

In September 1998, a 32-year-old woman had uneventful PRK in the right eye. Her ocular and general medical history was unremarkable. Before treatment, the BCVA in the both eyes was 20/20, with a cycloplegic refraction of -8.50-2.00 ax100 in the right eye and -2.75-0.50 ax5 in the left eye. Pachymetry revealed a corneal thickness of 621 and 618 μm, respectively.

Following administration of topical anesthesia and removal of the central epithelium with a blunt spatula, a Chiron Technolas 217C flying-spot excimer laser with a 2.00-mm beam diameter was used on the right eye. The fluence was 135 to 140 mJ/cm<sup>2</sup> and the repetition rate was 50 Hz. To achieve the desired correction of -8.50-2.00 ax100 in the right eye the diameter of the ablation zone was 5.8mm with a depth of 171 μm.

After laser ablation, a soft bandage contact lens was applied to the treated eye. Chloramphenicol-vitamin A, unreserved diclofenac, and enoxacin eye drops were used 4 times daily for 3 days. On day 3, the bandage contact lens was removed after reepithelialization had been confirmed biomicroscopically and the medication was changed to fluorometholone 0.2% drops and artificial tears (hyaluronic acid 0.1%). Fluorometholone 0.2% drops were used 4 times a day for 45 days, with a subsequent gradual decrease each month to once a day at 6 months. Follow-up examinations were performed at 1 week and 1, 2, 3, 4, 6, 12, and 24 months. Right eye visual acuity was 20/20 with a refraction of -0.50.

The postoperative course remained unchanged until April 2007, when RRD developed in the right eye consequent to a giant retinal tear. The BCVA was 20/20. SB, 20-gauge PPV, endolaser, and intravitreal silicone oil tamponade were performed in the right eye. No mechanical de-epithelialization was necessary during surgery. After the silicone oil was removed 2 months later, the visual acuity was 20/25 with a refraction of -2.00 dipoters. In July 2007, 3 months after vitrectomy and 9

**TABLE 2.** Patients' Clinical Characteristics Before Vitreoretinal Surgery: Intraoperative and Postoperative Notes

Patient	BCVApreVx	Retinal Status (Casuative Retinal Tear)	Haze at Entrance/Corneal Diseases	Lens Status	Vx Associated Procedures	Intraoperative Corneal protector	Disepithelialization	Tamponade	Re-epithelial Postoperative Epithelial Defects	Postoperative LOCH (haze treatment)	Follow up	BCVA last follow up (haze presence)
1	20/80	RD, PVR (PRT)	0/no	P	–	Sodiumhyaluronate 1.2%	no	SO	na/no	no	50 M	20/40 (no)
2	CF	RD (GRT)	0/no	PP	–	Sodiumhyaluronate 1.2%	no	SO	na/no	no	16 M	20/30 (no)
3	20/80	RD (PRT)	0/no	P	P + IOL	Sodiumhyaluronate 1.2%	no	SO	na/no	no	18 M	20/30 (no)
4	20/200	RD (PRT)	0/no	P	–	Hydroxypropylmethylcellulose 2%	no	C3F8 (10%)	na/no	no	16 M	20/25 (no)
5	HM	RD, PVR (MRT)	0/no	P	P + IOL	Sodiumhyaluronate 1.2%	no	SO	na/no	no	6 M	20/80 (no)
6	20/200	RD, VH (PRT)	0/no	P	P + IOL	Sodiumhyaluronate 1.2%	yes	C3F8 (10%)	7/no	no	7 M	20/100 (no)
7	HM	RD (MRT, MH)	trace/no	P	–	Hydroxypropylmethylcellulose 2%	no	C3F8 (14%)	na/no	unchanged	49 M	20/100 (trace)
8	LP	RD (PRT)	0/no	P	P + IOL	Sodiumhyaluronate 1.2%	no	C3F8 (12%)	na/no	no	12 M	20/200 (no)
9	20/200	RD, MP (PRT)	0/no	P	–	Hydroxypropylmethylcellulose 2%	yes	C3F8 (9%)	7/no	no	26 M	20/200 (no)
10	HM	RD (MRT, MH)	0/no	PP	–	Sodiumhyaluronate 1.2%	no	C3F8 (12%)	na/no	no	24 M	20/200 (no)
11	20/70	RD (PRT)	0/CEFD	P	P + IOL	Hydroxypropylmethylcellulose 2%	no	SO	na/no	no	24 M	20/25 (no)
12 <sup>15</sup>	20/200	RD (GRT)	trace/no	P	–	Hydroxypropylmethylcellulose 2%	no	SO	na/no	LOCH (PTK)	156 M	20/200 (yes)
13	20/20	RD (GRT)	0/no	P	–	Hydroxypropylmethylcellulose 2%	no	SO	na/no	LOCH (PTK)	84 M	20/200 (yes)

CEFD = corneal endothelial Fuchs' dystrophy; CF = counting fingers; GRT = giant retinal tear; HM = hand motions; LOCH = late onset corneal haze; LP = light perception; MH = macular hole; MP = macular pucker; MRT = multiple retinal tears; na = not applicable; P+IOL = phacoemulsification + intraocular lens implantation; P = phakic; PP = pseudophakic; PRT = posterior retinal tear; PTK = phototherapeutic keratectomy; PVR = proliferative vitreoretinopathy; RD = retinal detachment; SO = silicone oil; VH = vitreous haemorrhage.



years after PRK, the patient complained of photophobia and blurred vision in the right eye. The visual acuity was 20/100. Slit lamp examination revealed marked reticular scarring in the central cornea of the right eye and no changes in the left eye. Consequently, a diagnosis of LOCH was made in the right eye. A 3-month history showed no increased exposure to ultraviolet (UV) light. Use of eyedrops containing a mixture of dexamethasone 0.1% and tobramycin 4 times a day for 4 weeks was prescribed, followed by fluorometholone acetate 0.1% 4 times a day for 4 weeks, then 3 times a day for 4 weeks, and 2 times a day for 2 weeks. The haze was unresponsive to corticosteroids. Finally, phototherapeutic keratectomy (PTK) was performed in the right eye.

The PTK was performed with the Visx S4 excimer laser, programmed with a 67-mm optical zone and 0.2-mm transition zone. Significant residual corneal scarring is affecting the patient's final visual acuity of 20/100 (Figure 1A and B).

## DISCUSSION

In the present series we only included patients who were affected by RRD after PRK and managed by PPV. Previous studies have failed to demonstrate a causative relationship between refractive surgery and the occurrence of RRD.<sup>20–25</sup> The mean interval of 9.6 years between PRK and RRD occurrence in the present case series confirms that a causative relationship between the 2 events can be excluded.

To the best of our knowledge, the 13 patients herein treated with PPV after PRK are the largest series presented so

far.<sup>20,21,25</sup> Moreover, in other evaluations of RRD characteristics after PRK the corneal status after PPV has not been mentioned,<sup>20,25,26</sup> while in studies with long follow-up periods after PRK only 2 patients were diagnosed with RRD in 2 different series, and their treatment was not specified.<sup>19,27–30</sup>

In 2004, we reported a case of corneal scarring after vitrectomy without intraoperative epithelial debridement, occurring 42 months after PRK without MMC prophylaxis.<sup>15</sup> No other similar complications have been reported in the literature.

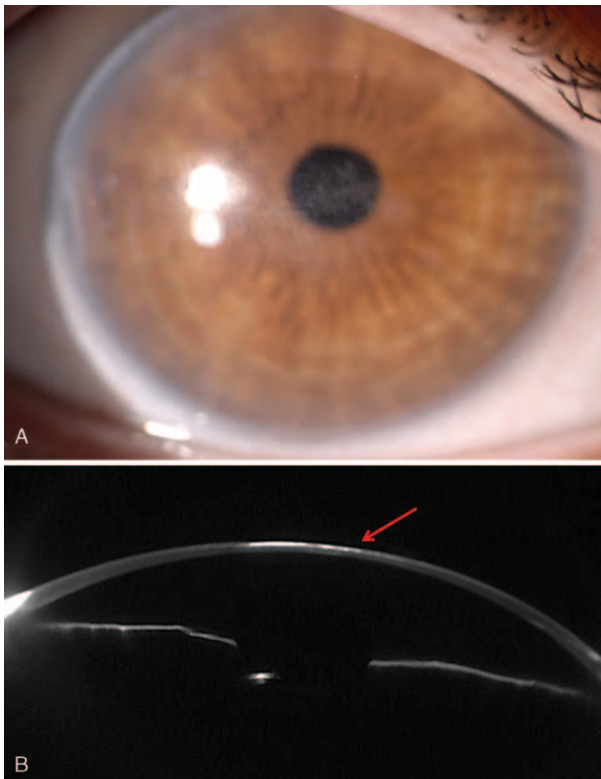
In our present case series, another patient treated with PRK 9 years earlier experienced LOCH 3 months after PPV for RRD.

The phenomenon of the excessive wound healing response following PRK has been studied extensively, in terms of both regular haze and LOCH. High myopia with a greater ablation depth has been suggested to contribute to haze formation.<sup>3,10,11</sup> Ablation depth does not explain haze and LOCH formation completely, since larger ablation zones are associated with better refractive and scarring outcomes.<sup>1</sup> In fact, the smoothness of the stromal surface after ablation and persistent structural and functional defects of the epithelial basement membrane have been demonstrated to play an important role.<sup>4–7,10,11</sup> The complexity of haze pathogenesis and its unpredictability are confirmed by the occurrence of subepithelial corneal scarring many months after PRK, following a new triggering event such as epithelial debridement, retreatment, trauma, and even after PPV for RRD.<sup>11–15</sup>

In the present series, the 2 patients with LOCH were affected by high myopia and underwent PRK with an ablation zone of 4.2 and 5.8 mm, respectively; the other patients in the series showed a mean ablation zone of 5.6 mm. However, in 1 of the patients without postoperative corneal complications the ablation zone was 4.5 mm and during PPV she was subjected to epithelial debridement to enhance fundus visualization. The 2 cases with LOCH had an ablation depth of 134 and 171  $\mu\text{m}$  and an ablation depth/corneal thickness ratio of 0.22 and 0.27, respectively.<sup>31,32</sup> The other patients in the series had a mean ablation depth of 109  $\mu\text{m}$  and a mean ablation depth/corneal thickness ratio of 0.19. However, among the patients without post-PPV LOCH, 4 (patients 7, 8, 9, and 10) had a high ratio (from 0.22 to 0.3). In 1 (patient 9) this ratio was associated with an optical zone in the low range and intraoperative epithelial debridement, and in another (patient 10) the high ratio was associated with multiple vitreoretinal surgeries.

Pre-PPV corneal scarring was absent in all patients, except 2 who showed trace haze; 1 of these 2 developed LOCH after PPV, while in the other no increase in haze was observed. This behavior is in line with the hypothesized different pathogenesis between regular haze and LOCH.<sup>7</sup> Endothelial cell counts were in the normal range in all patients, except the one who showed Fuchs endothelial corneal dystrophy. In contrast to previous reports of corneal degeneration after PPV and silicone oil tamponade in PRK-treated eyes, our patient showed neither postoperative subepithelial opacity nor endothelial decompensation after 2 years, notwithstanding the presence of preoperative endothelial degeneration.<sup>33,34</sup>

Hence, the question may be: did the RRD characteristics and the PPV-related intraoperative inflammation affect the process of corneal subepithelial wound healing? Due to the low number of patients considered the answer can be only speculative. When we described the first patient with LOCH,<sup>15</sup> we hypothesized that the giant retinal tear might have played a role in increasing ocular corneal cell proliferation. Also the second patient with LOCH presented with RRD due to a giant



**FIGURE 1.** A, Residual scarring after PTK performed for LOCH after PPV. B, Post-PTK Scheimpflug image of the residual subepithelial stromal opacity (arrow) showing clumpy high reflectivity.

retinal tear. However, no LOCH was observed in the 2 patients with grade B PVR and in the 5 patients who underwent simultaneous phacoemulsification and PPV.

Pre- and post-RRD surgery data on the status of the anterior cornea provided by confocal microscopy might have facilitated understanding of the corneal risk factors for LOCH development after PPV and for corneal reaction after PPV.<sup>4–7,10,11</sup> Unfortunately, both patients experiencing LOCH after PPV came to our attention before confocal microscopy was available at our Institution.

In the 2 patients experiencing LOCH we might hypothesize that a persistently abnormal basal membrane function through the years may have maintained a high subepithelial level of transforming growth factor B (TGFB), platelet-derived growth factors (PDGF), and other cytokines.<sup>7,10</sup> In fact, PPV may have stimulated the further production of growth factors by injured and/or intact epithelium, as well as by activated stromal cells, inflammatory cells and tear film, to such an extent so as to activate the formation of corneal and bone marrow-derived myofibroblasts.<sup>7</sup>

An alternative possibility is that retinal surgery had only an indirect role in the development of the late haze. Having left the eye open for retinal surgery might have caused an epithelial injury, at least from desiccation, and this leads to stromal cell activation and development of myofibroblasts as the result of a repeated injury to the epithelial basement membrane in an eye that had had prior PRK.<sup>8</sup>

Both the 2 cases presenting LOCH used hydroxypropyl methylcellulose 2% as an intraoperative corneal protector. Sodium hyaluronate 1.2% has been demonstrated to favor postsurgical re-epithelialization when the vitreoretinal surgeon is used to working with a contact panoramic viewing system.<sup>17</sup>

We experienced LOCH many years after PRK in 2 patients after silicone oil removal following vitrectomy + scleral buckling + silicone oil tamponade without any intraoperative epithelial debridement. However, we could not find any logical explanation for the occurrence of LOCH in these 2 patients. Two other patients in our series underwent intraoperative epithelial debridement; this did not induce LOCH occurrence, despite the fact that 1 of them had a high ablation depth and a small ablation zone. However, in 1 of the 2 this surgical maneuver decreased intraoperative visualization. On the basis of this experience, when we plan to perform PPV associated with scleral buckle in eyes previously subjected to PRK, we always place scleral buckling at the end of the procedure to avoid any minimal epithelial trauma before PPV.

## REFERENCES

- Rajan MS, O'Brart D, Jaycock P, et al. Effects of ablation diameter on long-term refractive stability and corneal transparency after photorefractive keratectomy. *Ophthalmology*. 2006;113:1798–1806.
- Hassell JR, Birk DE. The molecular basis of corneal transparency. *Exp Eye Res*. 2010;91:326–335.
- Teus MA, de Benito-Llopis L, Alió JL. Mitomycin C in corneal refractive surgery. *Surv Ophthalmol*. 2009;54:487–502.
- Toricelli AA, Singh V, Santhiago MR, et al. The corneal epithelial basement membrane: structure, function, and disease. *Invest Ophthalmol Vis Sci*. 2013;54:6390–6400.
- Singh V, Jaini R, Torricelli AA, et al. A method to generate enhanced GFP+ chimeric mice to study the role of bone marrow-derived cells in the eye. *Exp Eye Res*. 2013;116:366–370.
- Toricelli AA, Singh V, Agrawal V, et al. Transmission electron microscopy analysis of epithelial basement membrane repair in rabbit corneas with haze. *Invest Ophthalmol Vis Sci*. 2013;54:4026–4033.
- Wilson SE. Corneal myofibroblast biology and pathobiology: generation, persistence, and transparency. *Exp Eye Res*. 2012;99:78–88.
- Toricelli AA, Marino GK, Santhanam A, et al. Epithelial basement membrane proteins perlecan and nidogen-2 are up-regulated in stromal cells after epithelial injury in human corneas. *Exp Eye Res*. 2015;134:33–38.
- Toricelli AA, Wilson SE. Cellular and extracellular matrix modulation of corneal stromal opacity. *Exp Eye Res*. 2014;129:151–160.
- Netto MV, Mohan RR, Sinha S, et al. Stromal haze, myofibroblasts, and surface irregularity after PRK. *Exp Eye Res*. 2006;82:788–797.
- Gomes BA, Smadja D, Espana EM, et al. Very late-onset corneal scar triggered by trauma after photorefractive keratectomy. *J Cataract Refract Surg*. 2012;38:1694–1697.
- Qazi MA, Johnson TW, Pepose JS. Development of late-onset subepithelial corneal haze after laser-assisted subepithelial keratectomy with prophylactic intraoperativemitomycin-C Case report and literature review. *J Cataract Refract Surg*. 2006;32:1573–1578.
- Meyer JC, Stulting RD, Thompson KP, et al. Late onset of corneal scar after excimer laser photorefractive keratectomy. *Am J Ophthalmol*. 1996;121:529–539.
- Cua IY, Pepose JS. Late corneal scarring after photorefractive keratectomy concurrent with development of systemic lupus erythematosus. *J Refract Surg*. 2002;18:750–752.
- Tosi GM, Baiocchi S, Caporossi T. Late corneal scarring after retinal detachment surgery 42 months after photorefractive keratectomy. *J Cataract Refract Surg*. 2004;30:1124–1126.
- Machemer R, Aaberg TM, Freeman HM, et al. An updated classification of retinal detachment with proliferative vitreoretinopathy. *Am J Ophthalmol*. 1991;112:159–165.
- Tosi GM, Marigliani D, Bacci T, et al. Impact of intraoperative topical hydroxypropyl methylcellulose 2% versus sodium hyaluronate 1.2% on corneal reepithelialization after intentional epithelial debridement during vitrectomy. *Cornea*. 2014;33:942–945.
- Fantes FE, Hanna KD, Waring GO 3rd et al. Wound healing after excimer laser keratomileusis (photorefractive keratectomy) in monkeys. *Arch Ophthalmol*. 1990;108:665–675.
- Guerin MB, Darcy F, O'Connor J, et al. Excimer laser photorefractive keratectomy for low to moderate myopia using a 5.0 mm treatment zone and no transitional zone: 16-year follow-up. *J Cataract Refract Surg*. 2012;38:1246–1250.
- Ruiz-Moreno JM, Artola A, Alió JL. Retinal detachment in myopic eyes after photorefractive keratectomy. *J Cataract Refract Surg*. 2000;26:340–344.
- Ruiz-Moreno JM, Alió JL. Incidence of retinal disease following refractive surgery in 9,239 eyes. *J Refract Surg*. 2003;19:534–547.
- Arevalo JF. Retinal detachment after photorefractive keratectomy. *J Cataract Refract Surg*. 2000;26:1268–1270.
- Arevalo JF, Ramirez E, Suarez E, et al. Retinal detachment in myopic eyes after laser in situ keratomileusis. *J Refract Surg*. 2002;18:708–714.
- Panozzo G, Parolini B. Relationships between vitreoretinal and refractive surgery. *Ophthalmology*. 2001;108:1663–1668.
- Lee SY, Ong SG, Yeo KT, et al. Retinal detachment after laser refractive surgery at the Singapore National Eye Centre. *J Cataract Refract Surg*. 2006;32:536–538.
- Salazar PF, Rodriguez FJ, Medina DM, et al. Outcomes of vitreoretinal surgery for retinal detachment after LASIK for myopia. *Eur J Ophthalmol*. 2006;16:435–439.

27. O'Connor J, O'Keeffe M, Condon PI. Twelve-year follow-up of photorefractive keratectomy for low to moderate myopia. *J Refract Surg.* 2006;22:871–877.
28. Bricola G, Scotto R, Mete M, et al. A 14-year follow-up of photorefractive keratectomy. *J Refract Surg.* 2009;25:545–552.
29. Pietilä J, Mäkinen P, Pajari T, et al. Eight-year follow-up of photorefractive keratectomy for myopia. *J Refract Surg.* 2004;20:110–115.
30. Koshimizu J, Dhanuka R, Yamaguchi T. Ten-year follow-up of photorefractive keratectomy for myopia. *Graefes Arch Clin Exp Ophthalmol.* 2010;48:1817–1825.
31. Lin N, Yee SB, Mitra S, et al. Prediction of corneal haze using an ablation depth/corneal thickness ratio after laser epithelialkeratomileusis. *J Refract Surg.* 2004;20:797–802.
32. Møller-Pedersen T, Cavanagh HD, Petroll WM, et al. Corneal haze development after PRK is regulated by volume of stromal tissue removal. *Cornea.* 1998;17:627–639.
33. Buch H, Vesti Nielsen N. Keratopathy and pachymetric changes after photorefractive keratectomy and vitrectomy with silicone oil injection. *J Cataract Refract Surg.* 2000;26:1078–1081.
34. Pinter O, Haas A, Faschinger C. Corneal degeneration after silicone oil tamponade in a photorefractive keratectomy treated eye. *J Cataract Refract Surg.* 2003;29:217–219.