

CASE REPORT

Twin anemia polycythemia sequence in dichorionic diamniotic twins: A case report and review of the literature

Dhusyanthy Kanagaretnam¹  | Roshini Nayyar^{1,2} | Monica Zen^{1,2,3}

¹Department of Obstetrics and Gynaecology, Westmead Hospital, Westmead, NSW, Australia

²Westmead Institute for Maternal Fetal Medicine, Westmead Hospital, Westmead, NSW, Australia

³Westmead Clinical School, Faculty of Medicine and Health, Westmead Hospital, The University of Sydney, Westmead, NSW, Australia

Correspondence

Dhusyanthy Kanagaretnam, Department of Obstetrics and Gynaecology, Westmead Hospital, Westmead, NSW, Australia.
Email: dhusy.k@gmail.com

Abstract

Although rare, literature demonstrates evidence that vascular anastomoses do occur in dichorionic twins. Therefore, twin anemia polycythemia sequence should be considered as a differential diagnoses in dichorionic twins if there is suspicion on antenatal ultrasound.

KEYWORDS

dichorionic, feto-fetal transfusion, monozygotic, placental anastomoses, twin anemia polycythemia sequence, twins, twin-twin transfusion syndrome

1 | INTRODUCTION

While twin anemia polycythemia sequence (TAPS) is considered a complication only of monochorionic twins, there are several case reports demonstrating evidence of TAPS, twin-twin transfusion syndrome (TTTS), and acardiac twinning with evidence of vascular anastomoses in dichorionic twins. Thus, TAPS should be considered as differential diagnoses where appropriate in dichorionic twin pregnancy.

Twin anemia polycythemia sequence (TAPS) is a syndrome described in monochorionic twins characterized by anemia in one twin and polycythemia in the other twin, without discordance in the amniotic fluid volume, being first coined in the literature in 2007 by Lopriore et al.¹ The pathophysiology is proposed to be through slow transfer of red cells from a donor twin to the recipient twin via small (<1 mm) arteriovenous anastomoses in the placenta.^{1,2} TAPS occurs most commonly following laser treatment of twin-twin transfusion syndrome (TTTS). However, in 3%-5% of monochorionic twins, TAPS can occur spontaneously, usually in the late second or third trimester.^{3,4}

Previously, TAPS was not considered a potential diagnosis in a dichorionic twin pregnancy, as vascular anastomoses were not considered possible in dichorionic placentas. However, within the literature, in dichorionic twins there have been several cases of TTTS, one case of possible TAPS, one case of acardiac twinning described.⁵⁻¹⁵ Furthermore, there have been studies that have found the presence of vascular anastomosis in dichorionic placentas.^{16,17}

Timely diagnosis of TAPS is important. It allows appropriate management and closer monitoring, with the option of treatment, with or without early delivery as indicated, which can possibly lead to improved outcomes. It is thus important to recognize TAPS when it occurs in dichorionic diamniotic (DCDA) twins.⁴

2 | SEARCH STRATEGY

Pubmed was searched from 1959 to July 2020 for the following terms: "twin anemia-polycythemia," "TAPS," "twin-twin transfusion," "twin to twin transfusion,"

This is an open access article under the terms of the Creative Commons Attribution NonCommercial NoDerivs License, which permits use and distribution in any medium, provided the original work is properly cited, the use is non commercial and no modifications or adaptations are made.

© 2021 The Authors. *Clinical Case Reports* published by John Wiley & Sons Ltd.

“TTTS,” “twin reversed arterial perfusion,” “TRAP,” “acardiac twin” and “twin oligohydramnios polyhydramnios” in combination with “dichorionic monozygotic,” “monozygotic,” “dichorionic,” “dichorionic-monozygotic” and “dichorionic-diamniotic.” One thousand and sixty-six results were filtered by manual screening of titles, which yielded 66 manuscripts, whose abstracts were reviewed. Following abstract screening, 37 full-text articles were reviewed, which resulted in 14 relevant manuscripts at the end of the search. This included 12 case reports and two studies that conducted placental dye studies to investigate for vascular anastomoses in dichorionic placentas. No review articles were found. Additionally, the reference lists of included manuscripts were screened to ensure no articles were missed.

3 | CASE REPORT

A 34-year-old, gravida 2 parity 1, was transferred to our tertiary center at 31 weeks and 5 days gestation with a spontaneous DCDA twin pregnancy. Dichorionicity was diagnosed at the first-trimester ultrasound. Her pregnancy was complicated by Tetralogy of Fallot and early-onset growth restriction in twin 2, in addition to onset of preeclampsia at 30 weeks gestation. Ultrasound at 16 weeks demonstrated twin 1 with normal growth and liquor volume, while the biometry of twin 2 was suggestive of early-onset growth restriction with an estimated fetal weight and abdominal circumference less than the 5th centile, anhydramnios and absent fetal bladder. Following this report, the first-trimester ultrasound images were reviewed and dichorionicity was once again confirmed.

Morphology ultrasound at 19 weeks and 2 days gestation demonstrated Tetralogy of Fallot in twin 2. Subsequent ultrasounds demonstrated normal interval growth of twin 1 and selective growth restriction of twin 2 with adequate interval growth. Twin 2 demonstrated improvement of liquor volume at 21 weeks, where anhydramnios progressed to oligohydramnios (maximum vertical pocket of 1.9 cm), and fetal stomach and bladder were now visible. Subsequent scans demonstrated normal liquor volume and bladder in both twins. Invasive testing was offered following morphology ultrasound in view of congenital heart defect in twin 2 and declined at the time. Chorionic villous sampling was later performed at 31 weeks gestation on twin 2, and chromosome microarray was reported as normal.

At 32 weeks gestation, the first ultrasound was performed at our tertiary unit, where twin 1 demonstrated adequate interval growth, with an estimated fetal weight (EFW) 1904 g and abdominal circumference (AC) at 62nd centile as per Hadlock, normal liquor volume, and normal umbilical artery Doppler's. However, the middle cerebral

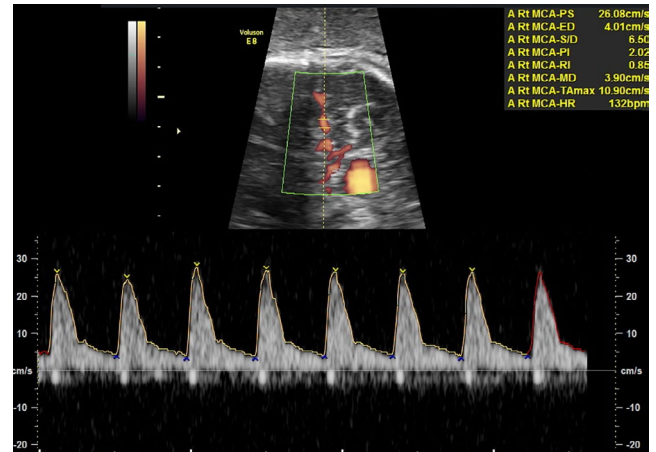


FIGURE 1 MCA Doppler of twin 1. MCA PSV 26 cm/s and 0.56 MoM suggestive of polycythemia

artery peak systolic value was 26 cm/s at 0.56 multiples of the mean (MoM), demonstrated in Figure 1. Twin 2 demonstrated Tetralogy of Fallot, appropriate interval growth weighing 1128 g and AC less than 5th centile and normal liquor volume. Umbilical artery Doppler values for twin 2 were within the normal range, and MCA-PSV 50.9 cm/s at 1.3 MoM. Twin 1 had a normal-appearing placenta, and twin 2 demonstrated an echogenic and thickened placenta (Figure 2).

The above ultrasound findings raised the suspicion of a diagnosis of TAPS. With this in mind, a decision for an emergency cesarean section the following day at 32 + 2 weeks gestation was made due to an acute change in the characteristics of the CTG at this time (Figure 3). At birth, twin 1 had a formal hemoglobin of 266 g/L, with a hematocrit of 0.77, reticulocyte count of 291×10^9 , and reticulocyte percentage of 4.5%. Twin 1 was treated with plasma exchange for the polycythemia. Twin 2 was pale, with a pale placenta, thin umbilical cord and a hemoglobin of 49 g/L and hematocrit of 0.19. A reticulocyte count was not performed on twin B due to the emergent clinical scenario and urgent packed red cell transfusion was given for anemia. While it is possible to have demonstrated an increased reticulocyte count post-transfusion and stabilization, unfortunately, as the twins were transferred to another facility, this was not performed despite requests. However, we feel that the timing of delivery was optimal given the large intertwin hemoglobin difference at birth, alongside the CTG changes.

Placental histopathology demonstrated two layers of amnion and a central fused chorion confirming dichorionicity. Twin 1 had a darker placenta and a pale nodule of villous infarction, while twin 2 had a pale placenta, thin umbilical cord, and immature villi. Unfortunately, due to pathology services issues, dye studies were unable to be performed.

FIGURE 2 (A) Placenta of twin 1: normal appearing (B) Placenta of twin 2: thickened and echogenic

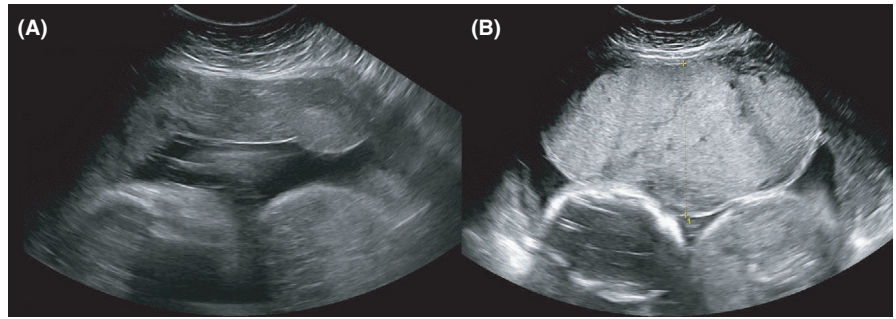
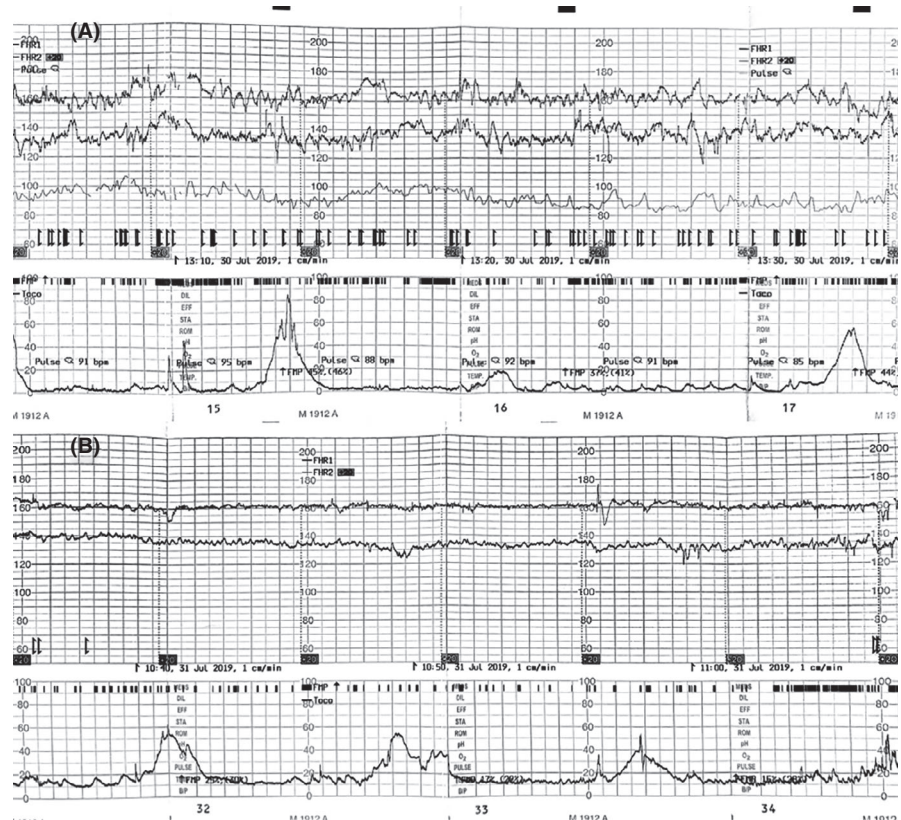


FIGURE 3 CTG of twin 1 and twin 2 (A) 1 d prior to delivery (32 wk) and (B) on the day of delivery (32 wk and 1 d)



4 | DISCUSSION

Antenatally, suspicion of TAPS was raised in our case due to a large difference in MCA-PSV and marked difference in placental echogenicity. Further, the progression in twin 2 from anhydramnios to oligohydramnios to liquor volume within normal limits during the course of the pregnancy, without history of premature rupture of membranes, was again suspicious for placental anastomoses with fetofetal transfusion.

Our twins had a MCA-PSV of 0.56 MoM and 1.3 MoM, respectively. The recipient polycythemic twin meets the ISUOG criteria for TAPS of MCA-PSV < 1.0 MoM; however, our donor anemic twin did not meet criteria of MCA-PSV > 1.5 MoM.¹⁸ Thus, our case does not currently meet current ISUOG antenatal criteria for TAPS. However, we believe it still represents a likely diagnosis of TAPS as it does fulfill new proposed criteria, where the difference in the MCA-PSV between the donor and recipient twin is used.

Tollenaar et al¹⁹ propose a difference in the MCA-PSV between the donor and recipient twin of >0.5 MoM (delta MCA PSV > 0.5 MoM), which provides better sensitivity and higher diagnostic accuracy when compared to separate anemia and polycythemia cut-offs, and thus improved detection of cases antenatally. Khalil et al²⁰ agree, reporting a consensus of expert opinions with the conclusion that either a difference in MCA-PSV or a separate cut-off for the recipient and donor twin were suitable.

Postnatally, our twins had a large hemoglobin difference of 217 g/L, which meets the postnatal ISUOG criteria of at least 80 g/L between twins. However, postnatal criteria require either a reticulocyte count ratio of >1.7 or an evidence of small (<1 mm) anastomoses seen in the placenta, which was not performed in our case due to clinical circumstances. The difference in echogenicity of the placentas on ultrasound and significant color difference in the placentas at birth support the diagnosis of TAPS; however, these are not part of

the diagnostic criteria. Placental histopathology confirmed a dichorionic placenta; thus, the chorionicity was correctly diagnosed. Postnatal criteria for TAPS are not satisfied as reticulocyte count or dye studies were not performed. However, we believe this is a likely case of TAPS due to the large difference in MCA PSV and placental echogenicity antenatally, large discrepancy in hemoglobin at birth and significant color difference in placentas at delivery. There is also evidence that placental appearance on ultrasound in TAPS can support the diagnosis, including placental echogenicity with the donors having a thicker more echogenic placenta, and the recipient having an echolucent thin placenta.¹⁹

It is evident that there is uncertainty within the literature and among specialists regarding optimal antenatal criteria for diagnosis of TAPS, reflecting the difficulty in diagnosis of TAPS.

4.1 | Literature review

Our case demonstrates the possible occurrence of TAPS in DCDA twins and prompted a review of the literature, which revealed one case of likely TAPS,¹⁵ one case of acardiac twinning, and several case studies of TTTS in DCDA twins.⁵⁻¹⁵

The only case of TAPS diagnosed in DCDA twins to our knowledge in the literature was by Zillox et al. A case of TAPS was described, which developed at 31 weeks gestation in twins diagnosed to be dichorionic in first trimester and confirmed by placenta histopathology. All ISUOG antenatal and postnatal diagnostic criteria¹⁸ were proposed to be fulfilled, including MCA-PSV, hemoglobin difference, reticulocyte ratio, and the presence of anastomoses on dye studies. However, it should be noted that the placental dye studies noted large arteriovenous connections, which is dissimilar to the small <1 mm anastomoses that are typical of TAPS. Further, it is possible that that these connections belong to the same twins whose vessels run velamentously. The other TAPS criteria including MCA-PSV, hemoglobin count, and reticulocyte ratio were fulfilled.

There are also several case reports demonstrating TTTS in dichorionic twins.^{5,6,9-14} Quintero¹³ and Lanna¹⁰ performed photocoagulation of communicating vessels in the dichorionic placentas, while Molnar-Nadasdy¹¹ and Murata¹² performed serial amnioreduction in the sac with polyhydramnios in a DCDA twin pregnancy. In addition, French⁷ described twin reversed arterial perfusion (TRAP) sequence in DCDA twins. King⁸ described evidence of fetofetal transfusion from one dichorionic twin to the other, where following a blood transfusion to one twin, there was subsequent evidence of transfusion to the other twin, which was demonstrated by Kleihauer and blood group testing.

Alongside clinical cases, analyses of dichorionic placentae in previous studies have described vascular anastomoses.^{16,17}

It should be noted that one study investigating vascular anastomoses in both monochorionic ($n = 134$) and dichorionic ($n = 124$) placentae via color dye studies found no vascular anastomoses among the dichorionic cohort.²¹ Zygosity was not known or tested in this cohort, and we assert that zygosity is of likely importance in dichorionic twin cases with TTTS.

Among the cases of TTTS, TAPS, and acardiac twinning found within the literature that tested for zygosity, all twins were tested postnatally and all demonstrated monozygosity.^{8,9,12,13} We, therefore, propose that in cases of DCDA twins where a pattern emerges on ultrasound suggestive of TTTS/TAPS, consideration should be given antenatally for analyses of cell-free DNA for zygosity. Noninvasive antenatal testing (NIPT) is currently commercially available to test for zygosity by one provider; however, we anticipate there will be other providers in the near future.²² A single nucleotide polymorphism-based test is performed, which is effective in diagnosing zygosity, but it should be noted that testing is not performed in cases with donor eggs.²³ If twins are diagnosed as monozygotic, complications due to vascular anastomoses should be considered in these twins if clinically indicated.

Finally, there is a lack of evidence for optimal management of TAPS but options include expectant management, early delivery, intrauterine or partial exchange transfusion, and laser coagulation. Early diagnosis allows for more vigilant monitoring and better outcomes. Management including indications for delivery depends on TAPS staging, gestation, and the progression of disease, such as the presence of cardiac compromise or hydrops.⁴

Given several case studies within the literature demonstrating either TAPS or TTTS in dichorionic twins, as well as vascular anastomoses in dichorionic placentas, we think it is important to consider the possibility of complications due to vascular anastomoses in twins presumed to be dichorionic. It is possible that there may be more cases that may benefit from closer observation and potential intervention if TAPS or TTTS were considered a differential diagnosis.

5 | CONCLUSION

Currently, the diagnosis of twin anemia polycythemia sequence (TAPS) is largely only recognized in monochorionic twins as it is thought to arise from arteriovenous anastomoses, thought to be exclusive to monochorionic placentas. A review of the literature reveals that arteriovenous anastomoses and the subsequent sequelae including TTTS/TAPS do occur in dichorionic placentae. If TAPS is suspected antenatally, hemoglobin and reticulocyte count as well as placental dye studies should be performed postnatally to confirm diagnosis. Current guidelines of TAPS may also not be detecting all cases antenatally, raising the question of whether criteria need to be widened to improve

antenatal diagnosis and thus lead to an improvement in outcomes. We believe that vascular anastomoses do occur in dichorionic twins, and thus, TTTS and TAPS should be considered in dichorionic twins.

ACKNOWLEDGMENTS

We would like to acknowledge the images taken by Dora Mangiokas. Published with written consent of the patient.

CONFLICT OF INTEREST

None declared.

AUTHOR CONTRIBUTION

The authorship list conforms to the journal policy. All authors are in agreement with the content of the manuscript.

ETHICAL APPROVAL

We have written informed consent from the patient for publication of this case report.

DATA AVAILABILITY STATEMENT

The data that support the findings of this study are available from the corresponding author upon request.

ORCID

Dhusyanthy Kanagaretnam  <https://orcid.org/0000-0003-2774-7932>

REFERENCES

- Lopriore E, Middeldorp JM, Oepkes D, Kanhai HH, Walther FJ, Vandenbussche FP. Twin anemia-polycythemia sequence in two monochorionic twin pairs without oligo-polyhydramnios sequence. *Placenta*. 2007;28(1):47-51.
- Zhao DP, de Villiers SF, Slaghekke F, et al. Prevalence, size, number and localization of vascular anastomoses in monochorionic placentas. *Placenta*. 2013;34(7):589-593.
- Lopriore E, Oepkes D. Fetal and neonatal haematological complications in monochorionic twins. *Semin Fetal Neonatal Med*. 2008;13(4):231-238.
- Tollenaar LS, Slaghekke F, Middeldorp JM, et al. Twin anemia polycythemia sequence: current views on pathogenesis, diagnostic criteria, perinatal management, and outcome. *Twin Res Hum Genet*. 2016;19(3):222-233.
- Cavazza MC, Lai AC, Sousa S, Pina R. Dichorionic pregnancy complicated by a twin-to-twin transfusion syndrome. *BMJ Case Rep*. 2019;12(10):e231614.
- Chmait RH, Floyd R, Benirschke K. Duplicity: sonography suggested a twin gestation was dichorionic-and monochorionic. *Am J Obstet Gynecol*. 2011;205(1):87.e1-87.e2.
- French CA, Bieber FR, Bing DH, Genest DR. Twins, placentas, and genetics: acardiac twinning in a dichorionic, diamniotic, monozygotic twin gestation. *Hum Pathol*. 1998;29(9):1028-1031.
- King AD, Soothill PW, Montemagno R, Young MP, Sams V, Rodeck CH. Twin-to-twin blood transfusion in a dichorionic pregnancy without the oligohydramnios-polyhydramnios sequence. *Br J Obstet Gynaecol*. 1995;102(4):334-335.
- Lage JM, Vanmarter LJ, Mikhail E. Vascular anastomoses in fused, dichorionic twin placentas resulting in twin transfusion syndrome. *Placenta*. 1989;10(1):55-59.
- Lanna M, Faiola S, Casati D, Rustico MA. Twin-twin transfusion syndrome in dichorionic twin pregnancy: rare but not impossible. *Ultrasound Obstet Gynecol*. 2019;54(3):417-418.
- Molnar-Nadasdy G, Altshuler G. Perinatal pathology casebook. A case of twin transfusion syndrome with dichorionic placentas. *J Perinatol*. 1996;16(6):507-509.
- Murata S, Takano M, Kagawa Y, Fujiwara M, Sumie M, Nakata M. Twin-twin transfusion syndrome in a monozygotic pregnancy with obvious lambda sign in first-trimester ultrasound. *Taiwan J Obstet Gynecol*. 2016;55(6):904-906.
- Quintero R, Kontopoulos EV, Barness E, et al. Twin-twin transfusion syndrome in a dichorionic-monozygotic twin pregnancy: the end of a paradigm? *Fetal Pediatr Pathol*. 2010;29(2):81-88.
- Rodriguez JG, Porter H, Stirrat GM, Soothill PW. Twin to twin blood transfusion in a dichorionic pregnancy without the oligohydramnios-polyhydramnios sequence. *Br J Obstet Gynaecol*. 1996;103(10):1056.
- Zilliox M, Koch A, Favre R, Sananes N. Unusual twin anemia-polycythemia sequence in a dichorionic diamniotic pregnancy. *J Gynecol Obstet Hum Reprod*. 2019;48(5):359-361.
- Foschini MP, Gabrielli L, Dorji T, et al. Vascular anastomoses in dichorionic diamniotic-fused placentas. *Int J Gynecol Pathol*. 2003;22(4):359-361.
- Robertson EG, Neer KJ. Placental injection studies in twin gestation. *Am J Obstet Gynecol*. 1983;147(2):170-174.
- Khalil A, Rodgers M, Baschat A, et al. ISUOG practice guidelines: role of ultrasound in twin pregnancy. *Ultrasound Obstet Gynecol*. 2016;47(2):247-263.
- Tollenaar LSA, Lopriore E, Middeldorp JM, et al. Improved prediction of twin anemia-polycythemia sequence by delta middle cerebral artery peak systolic velocity: new antenatal classification system. *Ultrasound Obstet Gynecol*. 2019;53(6):788-793.
- Khalil A, Gordijn S, Ganzevoort W, et al. Consensus diagnostic criteria and monitoring of twin anemia polycythemia sequence: a Delphi procedure. *Ultrasound Obstet Gynecol*. 2019;53(6):388-394.
- Zhao D, Lipa M, Wielgos M, et al. Comparison between monochorionic and dichorionic placentas with special attention to vascular anastomoses and placental share. *Twin Res Hum Genet*. 2016;19(3):191-196.
- Lanna MM, Consonni D, Faiola S, et al. Color-dye injection of monochorionic placentas and correlation with pregnancy complications. *Placenta*. 2015;36(10):1095-1099.
- Norwitz ER, McNeill G, Kalyan A, et al. Validation of a single-nucleotide polymorphism-based non-invasive prenatal test in twin gestations: determination of zygosity, individual fetal sex, and fetal aneuploidy. *J Clin Med*. 2019;8(7):937.

How to cite this article: Kanagaretnam D, Nayyar R, Zen M. Twin anemia polycythemia sequence in dichorionic diamniotic twins: A case report and review of the literature. *Clin Case Rep*. 2021;9:e04184. <https://doi.org/10.1002/ccr3.4184>