



Case Report

Resolution of retro-odontoid cyst in a patient with atlanto-occipital assimilation after occipitocervical fixation

Masahiro Kawanishi¹, Yutaka Ito¹, Hidekazu Tanaka¹, Kunio Yokoyama¹, Makoto Yamada¹, Akira Sugie¹

¹Department of Neurosurgery, Takeda General Hospital, Fushimiku, Kyoto, Japan.

E-mail: *Masahiro Kawanishi - mkawanis@takedahp.or.jp; Yutaka Ito - yutaka_727@yahoo.co.jp; Hidekazu Tanaka - bozu.hidekazu@nifty.com; Kunio Yokoyama - neu100@osaka-med.ac.jp; Makoto Yamada - neu090@osaka-med.ac.jp; Akira Sugie - neu055@osaka-med.ac.jp



***Corresponding author:**
Masahiro Kawanishi, MD, PhD,
Department of Neurosurgery,
Takeda General Hospital,
Fushimiku, Kyoto, Japan.
mkawanis@takedahp.or.jp

Received : 01 October 2020
Accepted : 14 October 2020
Published : 28 January 2021

DOI
10.25259/SNI_688_2020

Quick Response Code:



ABSTRACT

Background: Fusion of the atlas with the lower part of the occiput is clinically known as atlanto-occipital assimilation (AOA) or atlas occipitalization. This can be either partial or complete depending on the extent of fusion. AOA is one of the most common congenital anomalies of the craniovertebral junction and is usually asymptomatic.

Case Description: An 80-year-old female presented with a retro-odontoid cyst in conjunction with AOA. Following posterior occipitocervical fixation without resection of the cyst, the patient improved, and the postoperative MR documented cyst resolution.

Conclusion: Patients with AOA and a retro-odontoid cyst may be successfully managed with occipitocervical fixation without resection of the cyst. However, we would recommend preoperative computed tomography angiography to document whether the vertebral artery follows an anomalous course to avoid an intraoperative neurovascular injury.

Keywords: Assimilation, Occipitocervical fusion, Retroodontoid pseudo tumor

INTRODUCTION

Atlas occipitalization or atlanto-occipital assimilation (AOA) is one of the most common osseous congenital anomalies of the craniovertebral junction.^[4,6,7] Although most patients with atlas assimilation may be asymptomatic, some patients may experience myelopathy attributed to cervical cord impingement and occipitocervical instability. Those with progressive symptomatic segmental instability and/or increasing neurological deficits are candidates for occipitocervical reconstruction and fusion.

Here, we described a case in which AOA associated with a retro-odontoid cyst was successfully fused, resulting in spontaneous regression of the cyst.

CASE REPORT

An 80-year-old female was admitted with progressive gait disturbance, and weakness of the upper extremities of 6 months' duration. She demonstrated a useless right hand, a spastic quadriparesis,

This is an open-access article distributed under the terms of the Creative Commons Attribution-Non Commercial-Share Alike 4.0 License, which allows others to remix, tweak, and build upon the work non-commercially, as long as the author is credited and the new creations are licensed under the identical terms.

©2020 Published by Scientific Scholar on behalf of Surgical Neurology International

and diffuse hyperreflexia, accompanied by bilateral Babinski signs.

The dynamic X-rays showed AOA without atlantoaxial instability, while the sagittal MR demonstrated a retro-odontoid cystic mass compressing the spinal cord [Figure 1a]. The 3D-CT documented assimilation of C1, left vertebral artery (VA) agenesis, and an anomalous right VA that entered the spinal canal /foramen magnum below the occipitalized C1 posterior arch [Figures 1b and 2].

Operation

An occiput–C2 fusion was performed. Screws were secured to the occipital bone while C2 pedicle screws were applied; fixation then consisted of connection of the two with bilateral rods; and the fusion construct then included placement of structural iliac bone grafts affixed with smaller screws [Figures 3 and 4].

Postoperative course

Within 3 postoperative months, she regained normal strength, and the follow-up MR revealed moderate regression of the retroodontoid cystic mass [Figure 3].

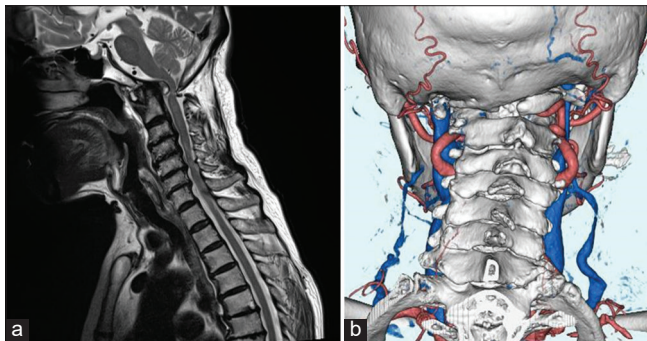


Figure 1: (a) Sagittal T2-WI revealed retro-odontoid cystic mass compressing the spinal cor. (b) Posterior view of three-dimensional computed tomography clearly demonstrates an assimilation with agenesis of the left VA and right VA entering the spinal canal below the occipitalized C1 posterior arch [Figures 1b and 2].

DISCUSSION

Congenital assimilation of the atlas (AOA) is caused by the failure of segmentation between the last occipital, and first cervical sclerotome during the early fetal development.^[8,9] It is the most common anomaly of the craniocervical junction (0.8–3.6%) and occurs more commonly in males/females (5:1).^[1,3,10] The four patterns of occipitalization follow (e.g., Zones 1, 2, and 3; the 4th is a combination of those zones) [Table 1].^[2] Zone 2, as in our patient, involved fusion of the lateral processes (fused lateral masses).

Symptomatic versus asymptomatic AOA

AOA is often asymptomatic, except where occipitalization results in fixation of both atlanto-occipital joints that bear more than 50% of the flexion/ extension motion.^[7] As such, the first mobile segment between the skull and the spine becomes the C1–C2 junction; this can result in “over stretch” of transverse ligament.^[7] Synovial cysts can also arise at the C1–C2 level reflecting joint instability.^[5,12]

Association with anomalous VA

Patients with AOA may demonstrate an abnormal course of the VA involving its third segment. Our patient had such an anomaly of the right VA. Wang *et al.* reported four distinct types of VA anomalies associated with occipitalization of the atlas [Table 2].^[11] For Type 2, the VA courses below the occipitalized C1 lateral mass and extends medially after it leaves the transverse foramen of the axis, thus entering the spinal canal/foramen magnum below the occipitalized C1

Table 1: Failure segmentation parts (Gholve *et al.*).^[2]

	Segmentation
Zone-1	Anterior arch
Zone-2	Lateral mass
Zone-3	Posterior arch
Zone-4	combination of zones

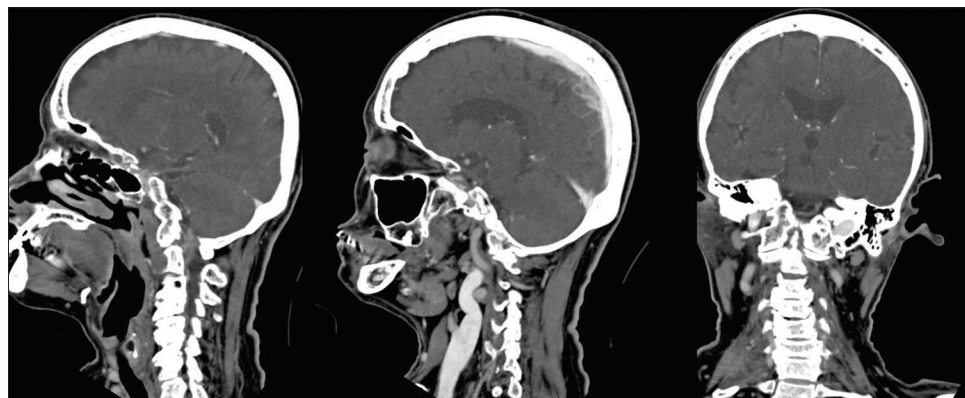


Figure 2: Computed tomography demonstrates an occipito atlas assimilation.

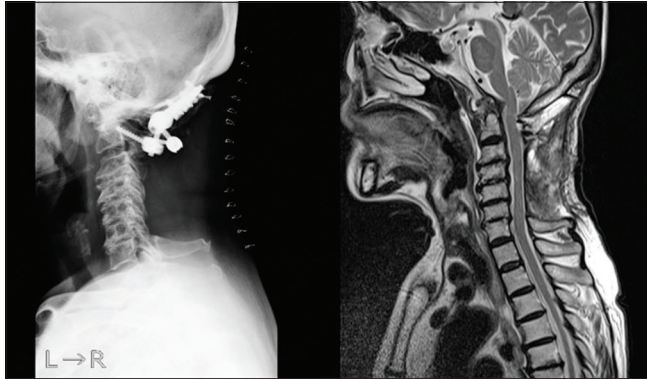


Figure 3: Postoperative Xp demonstrating C1-C2 fusion and MRI demonstrating resolution of retro-odontoid cyst.

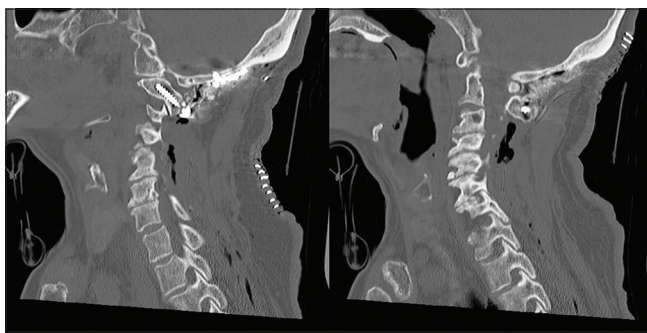


Figure 4: Postoperative CT.

Table 2: Four types of VA at craniocervical junction (Wang *et al.*).^[11]

	Percentage	VA course
Type I	8	Below the occipitalized C1 lateral mass
Type II	25	Posterior surface of the occipitalized C1 lateral mass
Type III	61	Osseous foramen created between the fused atlas and occiput absent on one side of the CVJ
Type IV	6	Below the occipitalized C1 lateral mass

posterior arch. As our patient had this Type 2 anomaly with a high-riding VA, C2 laminar screws were placed instead of C2 pedicle screws to avoid damaging the VA. To assess the course of the VA before this type of surgery, we recommend obtaining a preoperative cervical CTA.

CONCLUSION

Patients with AOA and a retro-odontoid cyst may be successfully managed with occipitocervical fixation without resection of the cyst. However, we would recommend preoperative computed tomography angiography to document whether the vertebral artery follows an anomalous course to avoid an intraoperative neurovascular injury.

Declaration of patient consent

The authors certify that they have obtained all appropriate patient consent.

Financial support and sponsorship

Nil.

Conflicts of interest

There are no conflicts of interest.

REFERENCES

- Burke SM, Huhta TA, Mackel CE, Riesenburger RI. Occipital condyle fracture in a patient with occipitalisation of the atlas. *BML Case Rep* 2015;2015:bcr2015209623.
- Gholve PA, Hosalkar HS, Ricchetti ET, Pollock AN, Dormans JP, Drummond DS. Occipitalization of the atlas in children. Morphologic classification, associations, and clinical relevance. *J Bone Joint Surg Am* 2007;89:571-8.
- Khamanarong K, Woraputtaporn W, Ratanasuwan S, Namking M, Chaijaroonkhanarak W, Sae-Jung S. Occipitalization of the atlas: Its incidence and clinical implications. *Acta Med Acad* 2013;42:41-5.
- Lang J. *Skull Base and Related Structures: Atlas of Clinical Anatomy*. New York, Stuttgart: Schattauer; 1995. p. 54.
- Lu K, Lee TC. Spontaneous regression of periodontoid pannus mass in psoriatic atlantoaxial subluxation. Case report. *Spine (Phila Pa 1976)* 1999;24:578-81.
- Macalister A. Notes on the development and variations of the Atlas. *J Anat Physiol* 1893;27:519-42.
- Mudaliar RP, Shetty S, Nanjundiah K, Kumar JP, Kc J. An osteological study of occipitocervical synostosis: Its embryological and clinical significance. *J Clin Diagn Res* 2013;7:1835-7.
- Offiah CE, Day E. The craniocervical junction: Embryology, anatomy, biomechanics and imaging in blunt trauma. *Insights Imaging* 2017;8:29-47.
- Sharma DK, Sharma D, Sharma V. Atlantooccipital fusion: Prevalence and its developmental and clinical correlation. *J Clin Diagn Res* 2017;11:AC01-3.
- Soni P, Sharma V, Sengupta J. Cervical vertebrae anomalies-incidental findings on lateral cephalograms. *Angle Orthod* 2008;78:176-80.
- Wang S, Wang C, Liu Y, Yan M, Zhou H. Anomalous vertebral artery in craniocervical junction with occipitalization of the atlas. *Spine (Phila Pa 1976)* 2009;34:2838-42.
- Yamaguchi I, Shibuya S, Arima N, Oka S, Kanda Y, Yamamoto T. Remarkable reduction or disappearance of retroodontoid pseudotumors after occipitocervical fusion. Report of three cases. *J Neurosurg Spine* 2006;5:156-60.

How to cite this article: Kawanishi M, Itoh Y, Tanaka H, Yokoyama K, Yamada M, Sugie A. Resolution of retro-odontoid cyst in a patient with atlanto-occipital assimilation after occipitocervical fixation. *Surg Neurol Int* 2021;12:34.