

“Tape dermatoscopy”: constructing a low-cost dermatoscope using a mobile phone, immersion fluid and transparent adhesive tape

Andreas Blum¹, Jason Giacomel²

1 Public, Dermatology, Konstanz, Germany

2 Skin Spectrum Medical Services, Como, Western Australia, Australia

Key words: low-cost, dermoscopy, dermatoscopy, simplified dermatoscopy, tape dermatoscopy, tape dermoscopy, transparent adhesive tape, mobile phone

Citation: Blum A, Giacomel J. “Tape dermatoscopy”: constructing a low-cost dermatoscope using a mobile phone, immersion fluid and transparent adhesive tape. *Dermatol Pract Concept* 2015;5(2):17. doi: 10.5826/dpc.0502a17

Received: September 21, 2014; **Accepted:** March 3, 2015; **Published:** April 30, 2015

Copyright: ©2015 Blum et al. This is an open-access article distributed under the terms of the Creative Commons Attribution License, which permits unrestricted use, distribution, and reproduction in any medium, provided the original author and source are credited.

Funding: None.

Competing interests: The authors have no conflicts of interest to disclose.

All authors have contributed significantly to this publication.

Corresponding author: Andreas Blum, MD, Dermatology, Seestrasse 3a, 78464, Konstanz, Germany. Tel. +49 7531 643 11; Fax. +49 7531 600 54. E-mail: a.blum@derma.de

ABSTRACT Importance: Medical professionals and indeed the general public have an increasing interest in the acquisition of dermatoscopic images of suspect or ambiguous skin lesions. To this end, good dermatoscopic image quality and low costs are important considerations.

Observations: Images of seven lesions (seborrheic keratosis, melanoma in-situ, blue and dermal nevus, basal cell carcinoma and two squamous cell carcinomas) were taken. A novel technique of “tape dermatoscopy” involved:

1. Using immersion fluid (i.e., water, olive oil, disinfectant spray) placed on the flat or slightly elevated lesion;
2. Covering the lesion with transparent adhesive tape with lateral tension;
3. Using ambient indoor or outdoor lighting for illumination (rather than flash photography);
4. Positioning a photographic device at an angle of approximately 45° from the side of the lesion to avoid light reflection;
5. Recording a focused image with a mobile phone or digital camera at a distance of approximately 25-30 cm from the lesion; and
6. Enlarging the image on the screen of the device.

Essential dermatoscopic features enabling a correct diagnosis were visible in 6 of the 7 lesions. “Tape dermatoscopy” images of the lesions were compared to standard dermatoscopy (using a Fotofinder handyscope® in combination with a mobile phone). The latter confirmed the dermatoscopic features in six of seven lesions.

Conclusions and Relevance: “Tape dermatoscopy” images can be recorded by medical personnel and even the general public without a dermatoscope. However, the limitations of this method are that images may be unfocused, exophytic tumors may be difficult to assess, excess pressure on tumoral blood vessels may lead to compression artefact, dermatoscopic features that are only visible under polarized light are unable to be detected (particularly “crystalline” or “chrysalis” structures) and tumors in certain anatomic locations may be difficult to assess (e.g., edges of nose, ears [demonstrated in one case], nails). Comparative prospective studies are necessary in order to test reproducibility of these preliminary findings, to establish special indications for the technique, and to develop guidelines for its effective use.

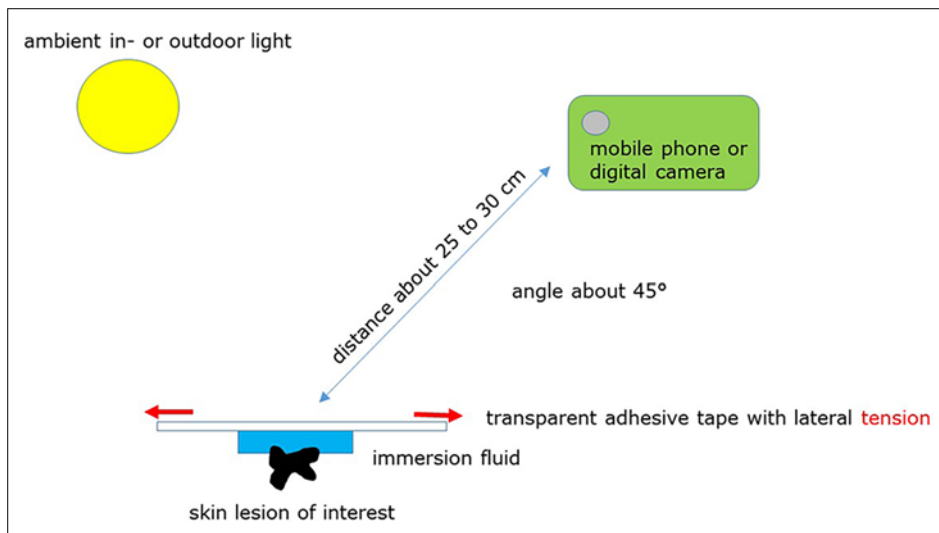


Figure 1. Schematic drawing demonstrating the “tape dermatoscopy” technique: (1) covering the lesion with immersion fluid (e.g., water, olive oil or disinfectant spray), (2) applying transparent adhesive tape over the lesion with lateral tension, (3) using ambient indoor or outdoor light for illumination, (4) approaching the lesion with the recording device at an angle of approximately 45° to avoid light reflection from the tape, and (5) recording a sharp image with a mobile phone or digital camera (with good macro capability) at a distance of approximately 20 to 30 cm. [Copyright: ©2015 Blum et al.]

Introduction

Diagnosing skin cancer with the naked eye can be difficult, especially for early tumors. For this purpose dermatoscopy is extremely helpful [1-3]. Medical professionals and, indeed, the general public have an increasing interest in the acquisition of dermatoscopic images of suspect or ambiguous skin lesions. Preferably, this could be achieved at low cost without compromising image quality. Saweda and Tanaka have developed a low-cost dermatoscopic device using echo-gel on the skin lesion, mounting a glass slide, illuminating the lesion at an angle from above using a torch, and examining the lesion using a microscope eyepiece (ocular) lens [4]. However, a procedure to record images is not provided by this technique. In the current pilot study, an approach is presented for a useful, simplified and inexpensive “tape dermatoscope.” Seven flat or slightly elevated skin lesions were examined. Transparent adhesive tape was applied to each lesion with lateral tension after covering the lesion with immersion fluid. Finally, images were recorded using a mobile phone or digital camera (Figure 1).

Report of the cases

Case 1

A 48-year-old female sent an e-mail image of an enlarging, slightly elevated lesion on her right breast. “Tape dermatoscopy” was subsequently performed by a family member instructed in the technique. After applying olive oil and transparent adhesive tape on the lesion, images were taken in outdoor daylight using a 5 megapixel iPhone 4 mobile phone (Apple Inc., Cupertino, CA, USA) (Figure 2A). The image

revealed the dermatoscopic features of comedo-like openings, milia-like cysts, gyri, sulci and homogeneous yellowish to brownish colors, suggestive of a seborrheic keratosis. On the following day standard dermatoscopic images were taken with a Fotofinder handyscope (FotoFinder Systems, Bad Birnbach, Germany) attached to an iPhone 5 (Apple Inc., Cupertino, CA, USA). The latter confirmed the dermatoscopic features and “tape dermatoscopy” diagnosis (Figure 2B), and no histology was considered necessary.

Case 2

An 88-year-old man noticed a change in a flat lesion on his left arm. A “tape dermatoscopy” image was taken (by A.B.) using disinfectant spray as immersion fluid, clear adhesive tape, indoor ambient light, and a mobile phone with an 8 megapixel camera (iPhone 5). A thin melanoma was suspected, as the image showed the “tape dermatoscopy” features of atypical homogeneous brownish, whitish and pinkish areas, multiple grey dots, and some asymmetric, patchy, tan-brown pigmentation (Figure 3A). A subsequent standard dermatoscopic image was taken with a Fotofinder handyscope, confirming the dermatoscopic features and provisional diagnosis (Figure 3B). Histopathology revealed lentigo maligna on actinic damaged skin.

Case 3

A 78-year-old woman presented with an unchanged flat, pigmented lesion on her left forearm. A “tape dermatoscopy” image was taken (by A.B.) with a mobile phone (iPhone 5) in ambient indoor lighting, using disinfectant spray as immer-

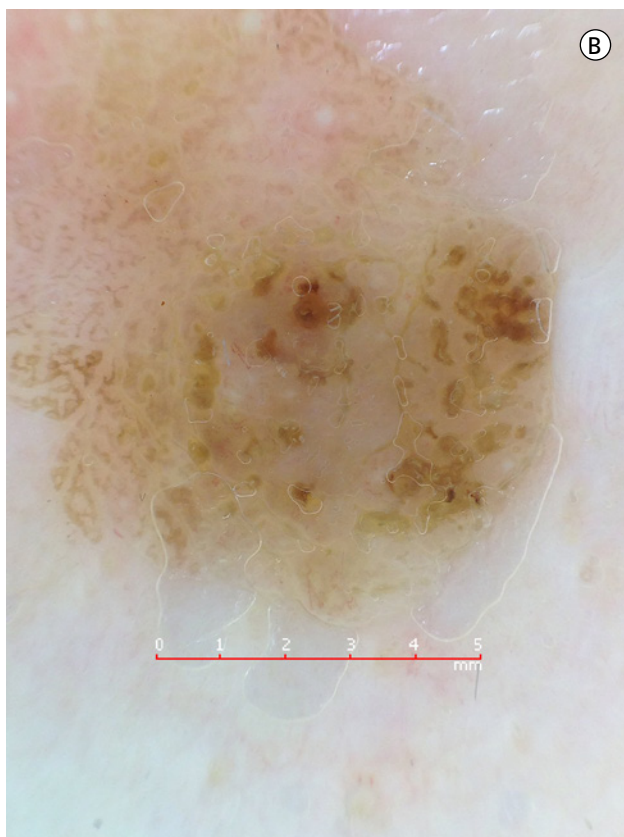
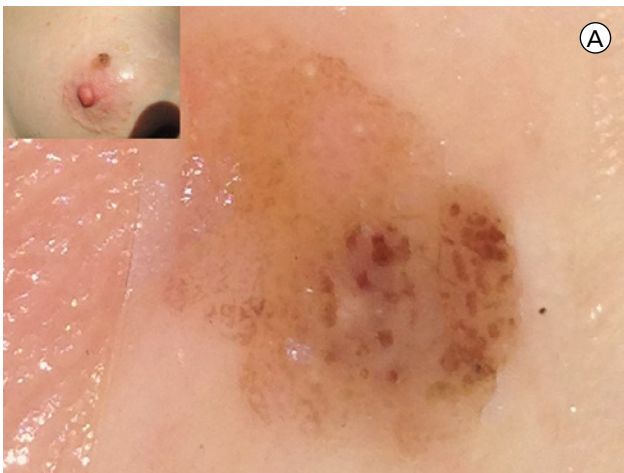


Figure 2. Seborrheic keratosis on the right breast. (A) Enlarged “tape dermatoscopy” image of the lesion. The lesion had been covered with immersion fluid (olive oil) and a tensioned transparent adhesive tape applied. (B) Standard non-polarized dermatoscopic image taken with a Fotofinder handyscope. [Copyright: ©2015 Blum et al.]

sion fluid and transparent adherent tape. A homogeneous blue color was seen, suggestive of a blue nevus (Figure 4A). A subsequent standard dermatoscopic image (taken with Fotofinder handyscope) revealed the same feature (Figure 4B). Histologic confirmation was deemed unnecessary.

Case 4

A 90-year-old female presented with a recent onset of a reddish-brown, slightly elevated lesion on her left temple. A “tape dermatoscopy” image was taken using a mobile phone

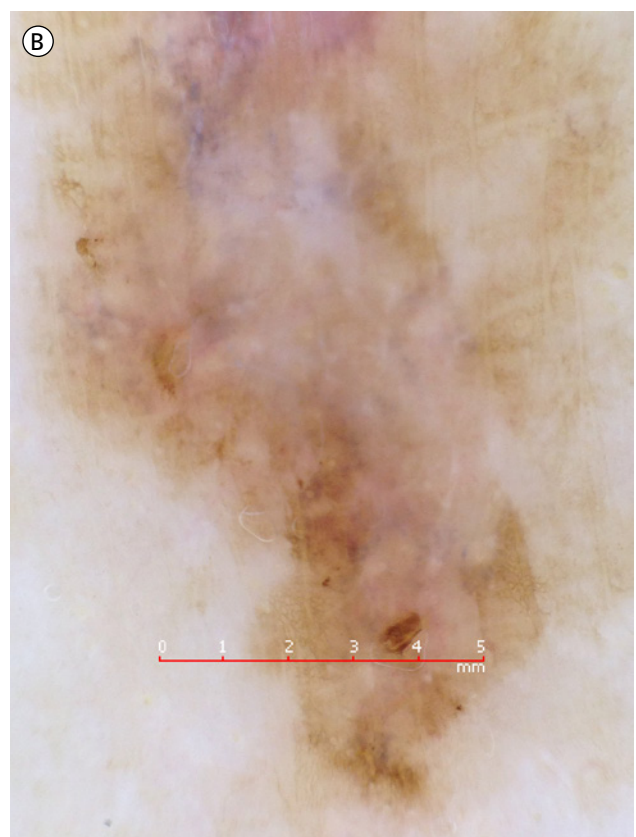
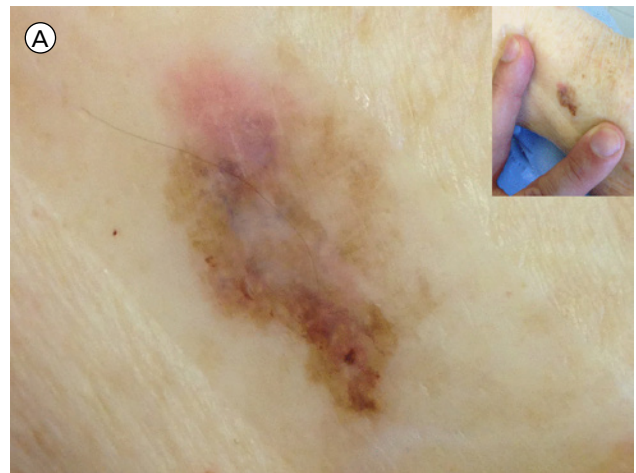


Figure 3. Lentigo maligna on actinic damaged skin of the left arm. (A) Enlarged “tape dermatoscopy” image of the flat lesion which had been covered with immersion fluid and tensioned transparent adhesive tape. Photograph taken using an iPhone 5 camera. (B) Normal non-polarized dermatoscopic image taken with a Fotofinder handyscope. [Copyright: ©2015 Blum et al.]

camera (iPhone 5) (by A.B). Disinfectant spray as an immersion fluid and transparent adherent tape were used, and the photographs were taken in ambient indoor light (Figure 5A). Standard dermatoscopic images of the same lesion were later recorded with a Fotofinder handyscope (Figure 5B). In both images the atypical arborizing vessels of a basal cell carcinoma (lower part), the milia-like cysts, and homogeneous yellowish to brownish colors of a seborrheic keratosis (upper part) were clearly visible. Histopathology confirmed this collision tumor.

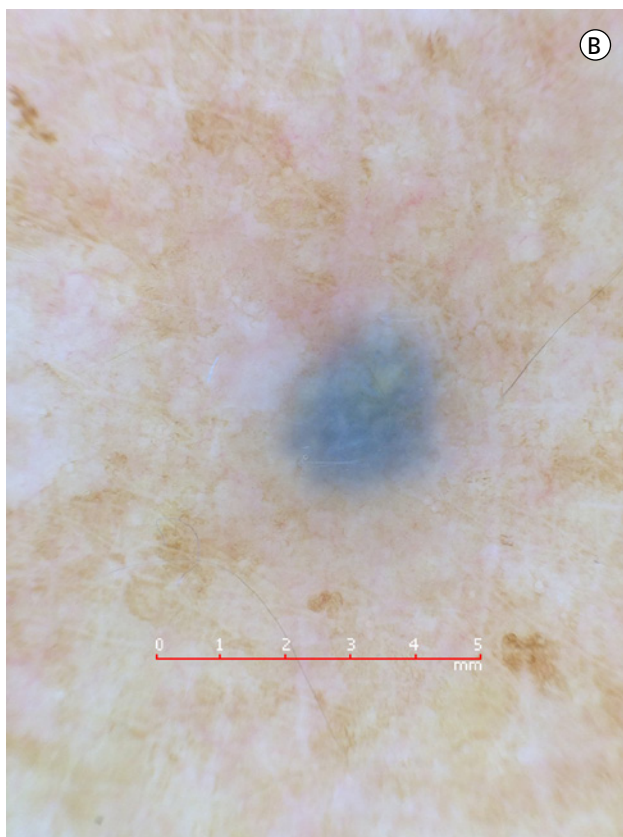
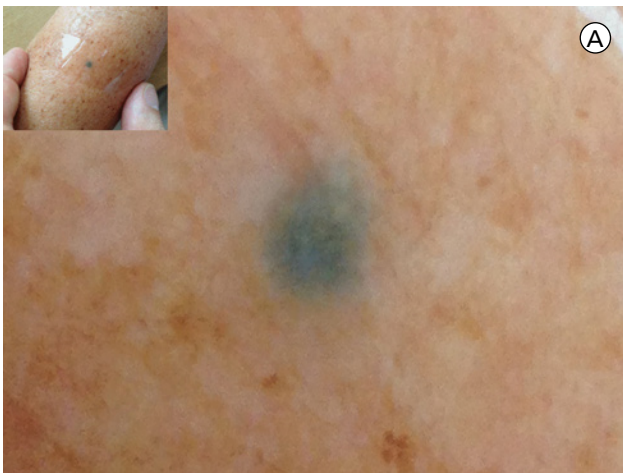


Figure 4. Blue nevus on the left forearm. (A) Enlarged “tape dermatoscopy” image of the lesion after covering with immersion fluid and a tensioned transparent adhesive tape. (B) Standard non-polarized dermatoscopic image taken with a Fotofinder handyscope. [Copyright: ©2015 Blum et al.]

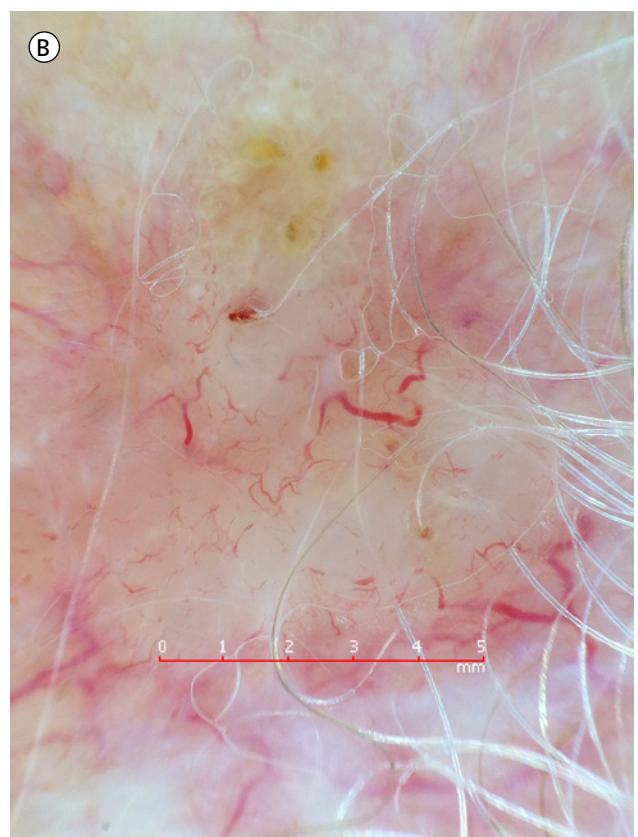
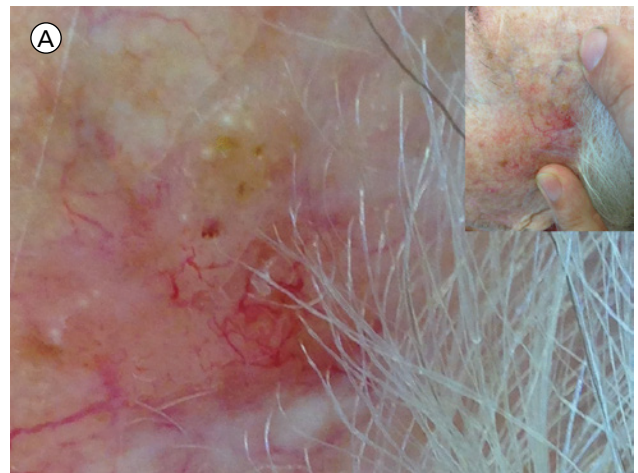


Figure 5. Collision tumor of a basal cell carcinoma (lower part) and seborrheic keratosis (upper part) on the left temple. (A) Enlarged “tape dermatoscopy” image of the lesion taken after applying immersion fluid and a tensioned transparent adhesive tape. (B) Regular non-polarized dermatoscopic image taken with a Fotofinder handyscope. [Copyright: ©2015 Blum et al.]

Case 5

A 77-year-old woman presented with a reddish exophytic tumor on the left zygomatic area. Clinical (Figure 6A) and “tape dermatoscopy” images (Figure 6B and C) were recorded (by A.B.). Disinfectant spray was employed as an immersion fluid, and transparent adhesive tape, ambient indoor lighting, and an iPhone 5 were used. Subsequent standard dermatoscopy images were taken with a Fotofinder handyscope (Figure 6D), during a regular office consultation. “Tape

dermatoscopy” revealed some (albeit unfocused) atypical vessels, ulcerations, whitish circles, and white lines (Figure 6B and C). In the normal dermatoscopic image taken with a Fotofinder handyscope linear irregular and hairpin-like vessels were clearly visible. In addition, there were ulcerations with blood spots, whitish circles and white lines (Figure 6D). Histopathologic examination confirmed an invasive squamous cell carcinoma.

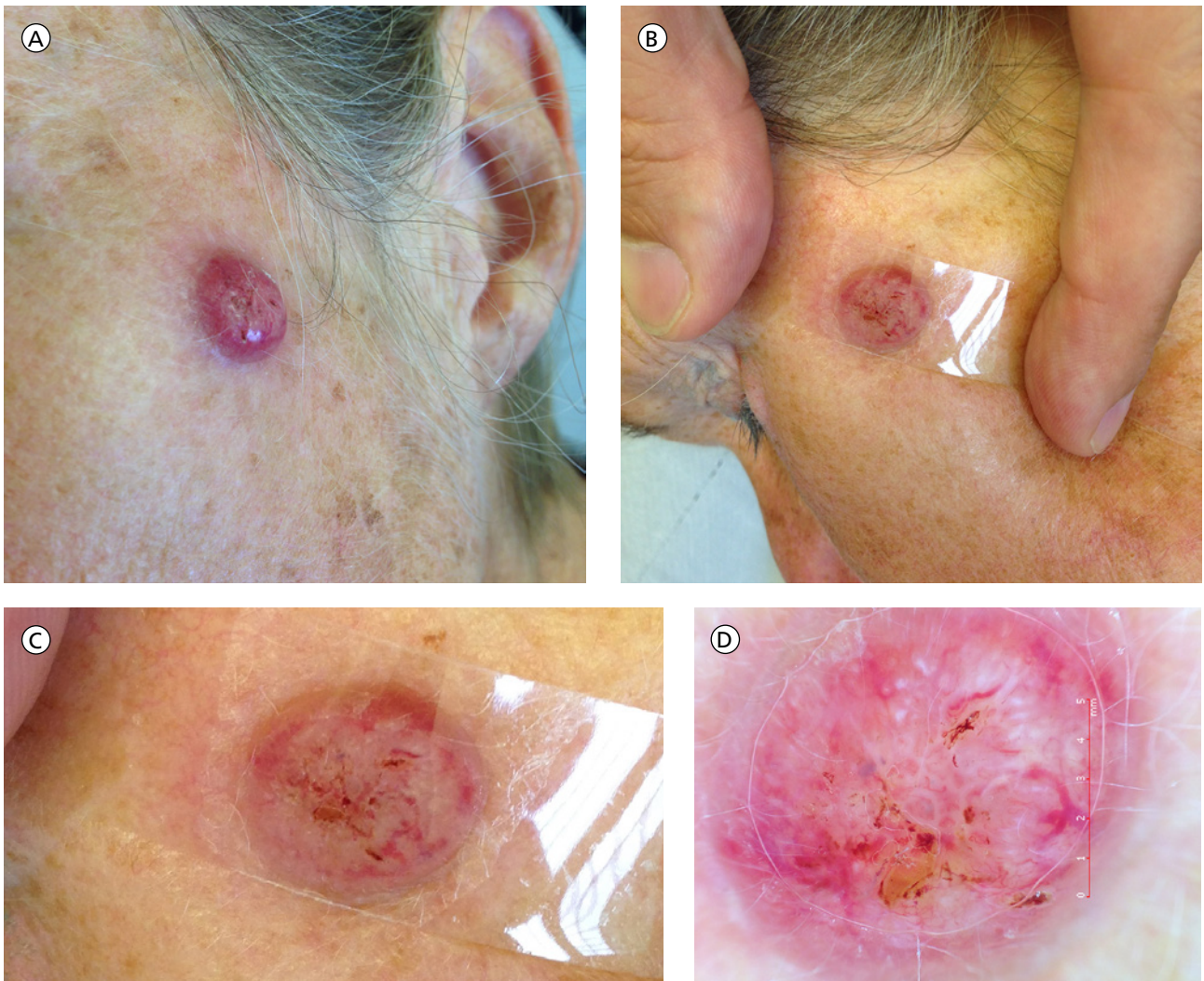


Figure 6. (A) Clinical image of invasive squamous cell carcinoma on the left zygomatic area. (B) “Tape dermatoscopy” image taken with a mobile phone after the lesion was covered with immersion fluid and a tensioned transparent adhesive tape. (C) Enlarged image of Figure 6b. (D) Normal non-polarized dermoscopic image taken with a Fotofinder handyscope. [Copyright: ©2015 Blum et al.]

Case 6

A 75-year-old man presented with an exophytic tumor on the lower antihelix of the right ear (Figure 7A). Low-cost “tape dermatoscopy” was carried out (by A.B.) using disinfectant spray as an immersion fluid, transparent adhesive tape, indoor ambient lighting, and an iPhone 5 (Figure 7B). However, the “tape dermatoscopy” technique was not effective for the exophytic tumor at this anatomic area (left side of Figure 7B) and the image of the surface of the tumor was unfocused (right side of Figure 7B).

Standard dermatoscopy images were then recorded using a Fotofinder handyscope (Figure 7C). It was only possible to take a standard dermoscopic image from the lateral aspect of the exophytic tumor. The latter revealed whitish circles, white-to-yellow keratotic areas, blood spots, and linear vessels in the upper part of the image (Figure 7C). Histopathologic examination confirmed an invasive squamous cell carcinoma.

Case 7

A 38-year-old man presented with a soft, elevated tumor on the scalp (Figure 8a). Low-cost “tape dermatoscopy” was performed (by A.B.) using disinfectant spray as an immersion fluid, transparent adhesive tape, indoor ambient lighting, and an iPhone 5. “Tape dermatoscopy” revealed aggregated brownish globules (Figure 8B). Standard dermoscopic photographs were subsequently taken with a Fotofinder handyscope (Figure 8C). The latter confirmed the presence of aggregated light-brown globules (“cobblestone pattern”) but also disclosed a few comma vessels (Figure 8C). The diagnosis of dermal nevus was confirmed by histopathologic examination.

Discussion

The current pilot study demonstrates the simple, cost-effective technique of “tape dermatoscopy.” “Tape dermatoscopy” images of flat or slightly elevated skin lesions can be recorded

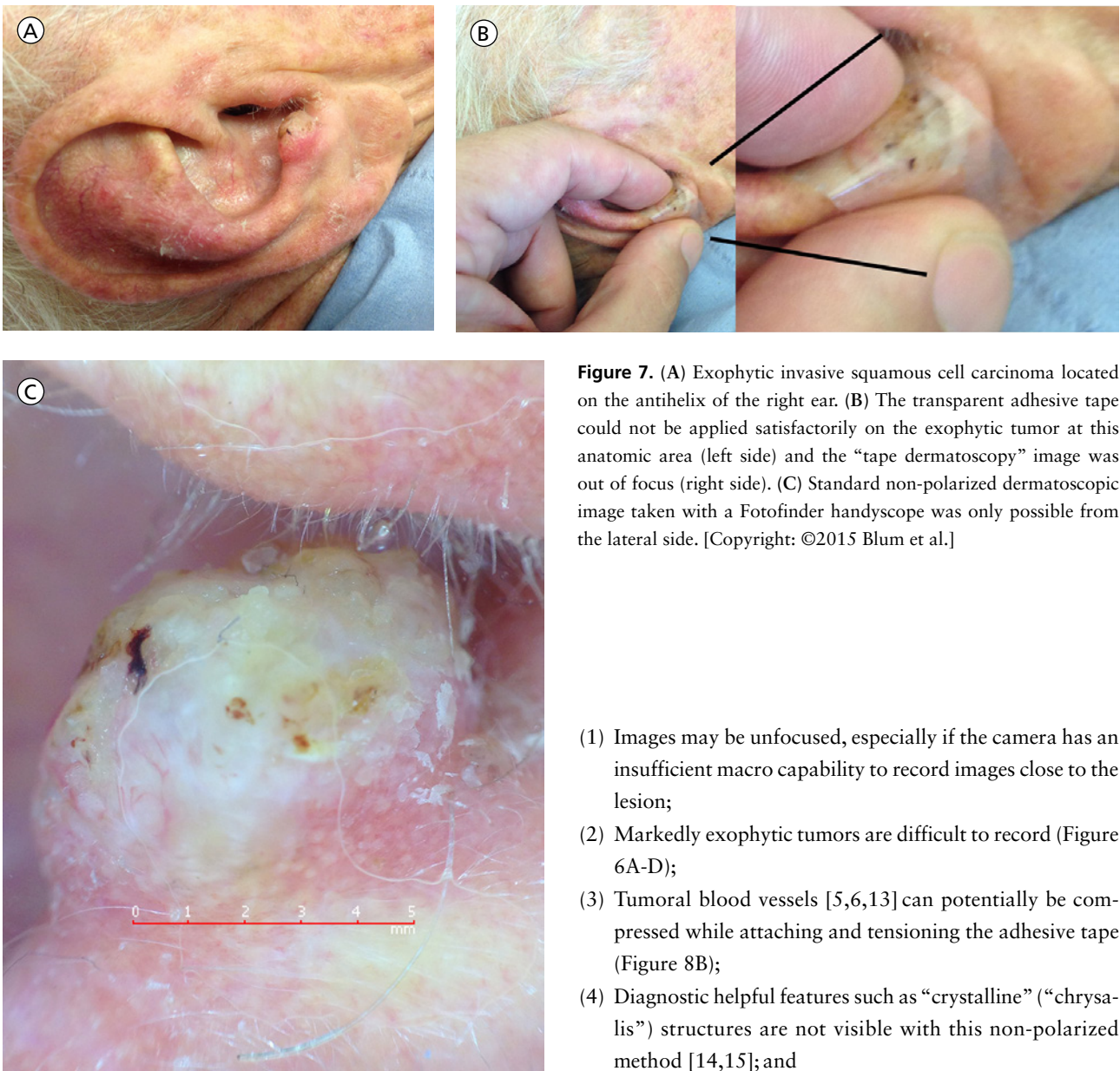

Figure 7. (A) Exophytic invasive squamous cell carcinoma located on the antihelix of the right ear. (B) The transparent adhesive tape could not be applied satisfactorily on the exophytic tumor at this anatomic area (left side) and the “tape dermatoscopy” image was out of focus (right side). (C) Standard non-polarized dermatoscopic image taken with a Fotofinder handyscope was only possible from the lateral side. [Copyright: ©2015 Blum et al.]

- (1) Images may be unfocused, especially if the camera has an insufficient macro capability to record images close to the lesion;
- (2) Markedly exophytic tumors are difficult to record (Figure 6A-D);
- (3) Tumoral blood vessels [5,6,13] can potentially be compressed while attaching and tensioning the adhesive tape (Figure 8B);
- (4) Diagnostic helpful features such as “crystalline” (“chrysalis”) structures are not visible with this non-polarized method [14,15]; and
- (5) Tumors in difficult locations (e.g., convex surfaces of the nose, ears, and nails) may not be able to be recorded with adequate image quality (Figure 7A-C).

However, for many types of skin lesions located on relatively flat anatomic areas (including the scalp), the “tape dermatoscopy” method is easily applicable and potentially effective.

Prospective studies of this proposed new technique are required, using large comparative series. The latter would involve comparing “tape dermatoscopy” images recorded by non-professionals with standard dermatoscopic images taken by professionals with a standard dermatoscope. Such studies may elucidate special indications for the technique and develop practicable guidelines for public use.

References

1. Kittler H, Pehamberger H, Wolff K, Binder M. Diagnostic accuracy of dermoscopy. *Lancet Oncol* 2002;3(3):159-65.

by medical professionals and even untrained persons without the need of a standard dermatoscope. The technique may be useful for several types of skin lesions, including seborrheic keratosis, dermal nevus, blue nevus, invasive squamous cell carcinoma, lentigo maligna (highlighting diagnostically useful features such as multiple grey dots and pink areas) [5,6], and basal cell carcinoma. “Tape dermatoscopy” images can be recorded and immediately scrutinized on the screen of a mobile phone, camera or computer and may be transmitted worldwide in a teledermatoscopic setting [7-10]. Furthermore, the method may enable a triage system for skin cancer detection by patients themselves [11]. This could result in early cure of both non-melanoma skin cancer as well as melanoma, with reduced morbidity and even mortality [12].

However, the “tape dermatoscopy” technique does have several limitations:

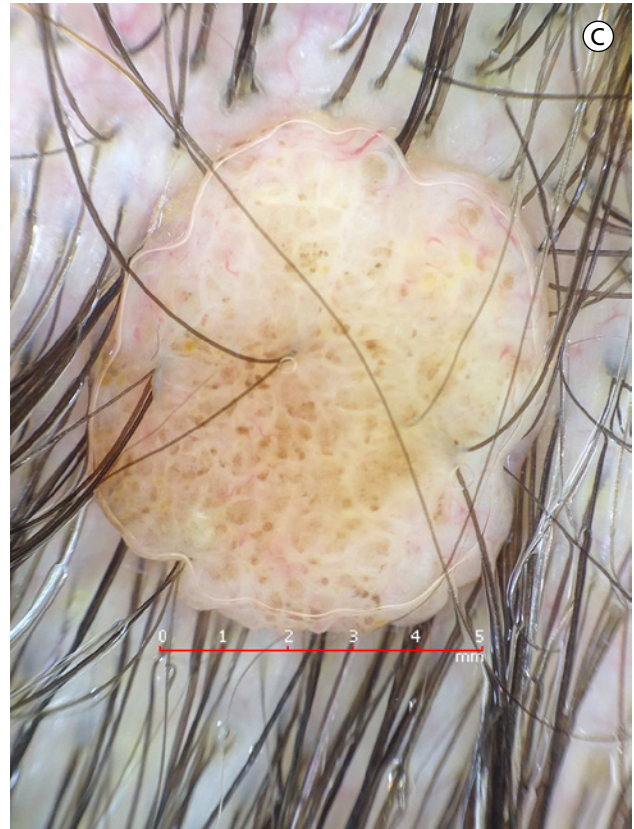
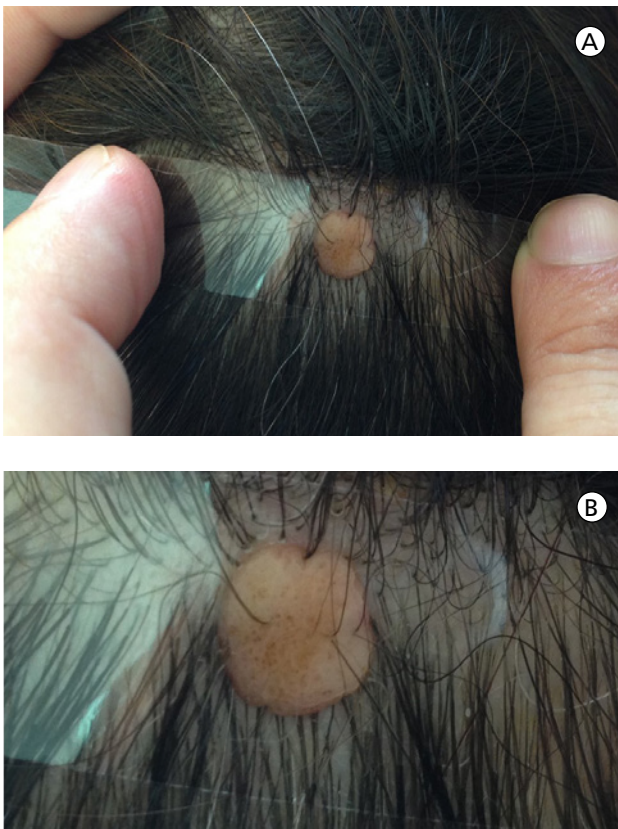

Figure 8. (A) “Tape dermatoscopy” image of an elevated dermal nevus on the scalp. The lesion had been covered with immersion fluid (disinfectant spray) and tensioned transparent adhesive tape. (B) Enlarged image of Figure 8A. (C) Normal non-polarized dermatoscopic image taken with a Fotofinder handyscope. [Copyright: ©2015 Blum et al.]

- Vestergaard ME, Macaskill P, Holt PE, Menzies SW. Dermoscopy compared with naked eye examination for the diagnosis of primary melanoma: a meta-analysis of studies performed in a clinical setting. *Br J Dermatol* 2008;159(3):669-76.
- Argenziano G, Giacomel J, Zalaudek I, et al. A clinico-dermoscopic approach for skin cancer screening: recommendations involving a survey of the International Dermoscopy Society. *Dermatol Clin* 2013;31(4):525-34.
- Sawada M, Tanaka M. Self-assembly of a simple low-cost dermoscope for examination of skin lesions. *Dermatol Pract Concept* 2013;3(4):35.
- Fabbrocini G, Balato A, Rescigno O, et al. Telediagnosis and face-to-face diagnosis reliability for melanocytic and non-melanocytic ‘pink’ lesions. *J Eur Acad Dermatol Venereol* 2008;22(2):229-34.
- Giacomel J, Zalaudek I. Pink lesions. *Dermatol Clin* 2013;31(4):649-78.
- Tan E, Yung A, Jameson M, Oakley A, Rademaker M. Successful triage of patients referred to a skin lesion clinic using teledermoscopy (IMAGE IT trial). *Br J Dermatol* 2010;162(4):803-11.
- Lim D, Oakley AM, Rademaker M. Better, sooner, more convenient: a successful teledermoscopy service. *Australas J Dermatol* 2012;53(1):22-5.
- Massone C, Maak D, Hofmann-Wellenhof R, Soyer HP, Früh-auf J. Teledermatology for skin cancer prevention: an experience on 690 Austrian patients. *J Eur Acad Dermatol Venereol* 2014;28(8):1103-8.
- Karavan M, Compton N, Knezevich S, et al. Teledermatology in the diagnosis of melanoma. *J Telemed Telecare* 2014;20(1):18-23.
- Börve A, Gyllencreutz JD, Terstappen K, et al. Smartphone teledermoscopy referrals: a novel process for improved triage of skin cancer patients. *Acta Derm Venereol*. 2015 Jan 15; 95(2):186-90.
- Ferrándiz L, Ruiz-de-Casas A, Martín-Gutiérrez FJ, et al. Effect of teledermatology on the prognosis of patients with cutaneous melanoma. *Arch Dermatol* 2012;148(9):1025-8.
- Menzies SW, Kreuzsch J, Byth K, et al. Dermoscopic evaluation of amelanotic and hypomelanotic melanoma. *Arch Dermatol* 2008;144(9):1120-27.
- Balagula Y, Braun RP, Rabinovitz HS, et al. The significance of crystalline/chrysalis structures in the diagnosis of melanocytic and nonmelanocytic lesions. *J Am Acad Dermatol* 2012;67(2):194.e1-8.
- Wang SQ, Dusza SW, Scope A, et al. Differences in dermoscopic images from nonpolarized dermoscope and polarized dermoscope influence the diagnostic accuracy and confidence level: a pilot study. *Dermatol Surg* 2008;34(10):1389-95.