

Arthroscopic capsular shift technique and volume reduction

Przemyslaw Lubiowski · Piotr Ogrodowicz ·
Marcin Wojtaszek · Maciej Breborowicz · Jan Długosz ·
Leszek Romanowski

Received: 19 July 2011 / Accepted: 25 August 2011 / Published online: 21 September 2011
© The Author(s) 2011. This article is published with open access at Springerlink.com

Abstract Multidirectional instability is very complex pathology. Excessively redundant capsule is one of the important reasons causing symptomatic laxity in multiple planes. Arthroscopic techniques are not able to reproduce the potential of open methods to reduce the joint volume. Most of the studies based their measurements on cadaver model. The aim of the study was to develop simple and reproducible technique to perform arthroscopic capsular shift and measure its volume reduction potential in both cadaveric and clinical setting. Technique is described in the paper. Capsular shift was applied both in cadaver and clinical scenario. Based on group of 5 cadaver shoulder specimen, glenohumeral joint volume was reduced from average of 19.4 ± 7.8 ml to 11.9 ± 4.5 ml following arthroscopic capsular shift (37.9% volume reduction). Clinical material consisted of 12 consecutive patients shoulder with instability and joint laxity undergoing the arthroscopic capsular shift. Average glenohumeral volume before capsular shift was 43.5 ± 10 ml and was reduced to 17.5 ± 4.3 ml (58.8% volume reduction). Arthroscopic capsular shift presented in this paper seems to be relatively easy to perform and safe procedure. The technique provides significant decrease in joint volume in both cadaveric and clinical parts of the study.

Keywords Shoulder instability · Capsular shift · Shoulder arthroscopy · Multidirectional instability

Introduction

Shoulder instability is very complex pathology. Multidirectional instability (MDI) needs special attention, and conservative treatment is standard to begin with. Excessively, redundant capsule is one of the important reasons causing symptomatic laxity in multiple planes [1]. Open capsular shift has been a gold standard operative treatment for those symptomatic patients who do not respond to proper exercise program [2–4]. Multiple open techniques have been described in the past with different volume reduction potentials [3–10]. In recent years, arthroscopy has made a major change in the treatment of shoulder instability. Several methods have been described to perform capsular shift arthroscopically, with probably most popular classic shift described by Snyder [11–21]. Arthroscopic techniques are not able to reproduce the potential of open methods to reduce the joint volume [7, 8, 10, 15, 21]. However, the joint volume reduction was measured on cadaver model in majority of papers. That does not reproduce normal tissue properties and age of typical patient with shoulder instability. In our opinion, arthroscopic capsular shift should be easy, reproducible, accurate (be able to control the amount of plication according to arthroscopic findings), efficacious and safe (for axillary nerve). Our hypothesis is that arthroscopic capsular shift presented in our study significantly reduces joint volume.

The aim of the study was to develop simple and reproducible technique to perform arthroscopic capsular shift and measure its volume reduction potential in both cadaveric and clinical setting.

Electronic supplementary material The online version of this article (doi:10.1007/s00590-011-0865-z) contains supplementary material, which is available to authorized users.

P. Lubiowski (✉) · P. Ogrodowicz · M. Wojtaszek ·
M. Breborowicz · J. Długosz · L. Romanowski
Department of Orthopaedics, Traumatology and Hand Surgery,
University of Medical Sciences in Poznan, Ul.
28 Czerwca 1956r 135/147, 62-545 Poznan, Poland
e-mail: przemyslaw.lubiowski@rehasport.pl

Materials and methods

Technique

Shoulder arthroscopy is performed in a standard way. Three arthroscopic portals are used. Posterior portal is used to introduce scope and camera. Then, anterior midglenoid portal (AMGP) with cannula is established with out-side in technique. That portal is used to insert the anchors. The second cannula (third portal- antero-superior portal- ASP) is introduced antero-superiorly. That portal is used to manipulate the capsule. Before starting the procedure, standard arthroscopic evaluation is performed and joint volume is measured. Most important part is to manage antero-inferior capsule and inferior-glenohumeral ligament. Surface of shifted capsule is rasped or gently shaved to cause superficial bleeding. Antero-inferior anchor is introduced in 5.30 position of glenoid rim for right shoulder or 6.30 for left. Then, the capsular shift is performed (Fig. 1). We use both anterior portals simultaneously. Accurate portion of capsule is grabbed with suture manipulator or grasper via ASP and shifted superiorly toward the anchor site. We can redo this maneuver if too little or too much tissue has been engaged. Then, flap of capsule is pierced with penetrating grasper introduced via AMGP, and suture is retrieved. Standard sliding knot is tightened over the shifted capsule. Then, additional capsular shift is performed with more superior capsule (MGHL). If we need with same technique, postero-inferior capsule can be shifted. For this purpose, the scope is transferred to AMGP, tissue grasper is moved to ASP and anchor and suture handling performed via posterior portal. For massive instability with spacious joints, we perform rotator interval closure.

Cadaver study

Study was based on 5 cadaver shoulders. Shoulders included in this study did not have any operations, visible deformity or rotator cuff tears. Shoulder with signs of osteoarthritis or rotator cuff tears were excluded from the study. Whole shoulders with all tissues preserved were used for the study. Procedure was performed in lateral decubitus position. Technique of capsular shift was performed according to above description. We used fully threaded 8.5-mm cannulas (Smith and Nephew) and Twinfix 2.8-mm anchors for stabilization (Smith and Nephew). Volume of the joint was measured before the procedure after establishing portals and after procedure of capsular shift with cannulas still in the joint. Cannulas were filled with obturators for measurements.

Clinical study

Twelve consecutive patients with shoulder instability and joint laxity operated in 2008–2009 in our department were included in the study. Clinical diagnosis was based on history and physical examination. All patients had either atraumatic shoulder instability or instability induced by minor trauma accompanied by significant joint laxity. Pattern of instability was multidirectional in all patients. All patients had CT or MR scan performed before operation to identify possible bone defects. No significant glenoid defects were seen in this group of patients. Those patients did not respond to conservative treatment in preoperative period. The average age of the patients was 24 years (19–27). There were 4 women and 8 men in our group.

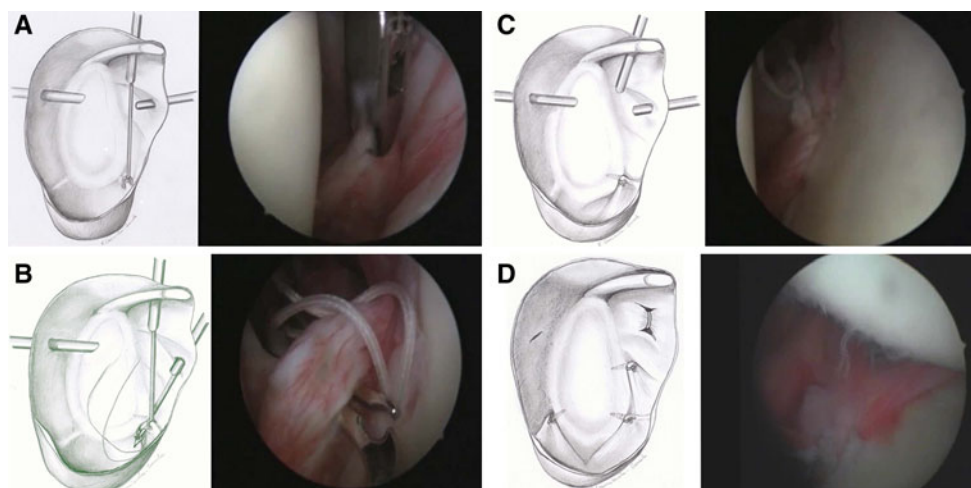


Fig. 1 Drawings and arthroscopic pictures of capsular shift. Two anterior cannulas are used. First antero-inferior capsule is grasped with tissue grasper (a). Following anchor implantation, penetrating grasper

is used to retrieve the sutures (b). Knots are tightened to stabilize the capsular shift (c). Posterior capsular shift is performed to address postero-inferior capsular redundancy (d)

All patients were operated in lateral decubitus position. Both brachial plexus block and general anesthesia were used. Procedure was performed according to technique described above. Arthroscopic pump was used for fluid management with pressure of 90 mm Hg and flow 1.5 l/min.

Volume measurements

All volume measurements were performed before and after procedure. For each procedure, first measurements were done after establishing portals. Cannulas were occluded with obturators. Glenohumeral joint was filled with saline by means of arthroscopic pump. Care was taken to remove all air remnants from the joint. Then, inflow was closed, and all fluid from the joint was aspirated with 50-ml syringe via arthroscope under arthroscopic control. Measurements were repeated to obtain average value of two measurements. Final measurements were taken after capsular shift. Cannulas were left in place but closed and occluded with obturators. Joint was filled with fluid (no air). Then, inflow was closed, and fluid fully aspirated with 50-ml syringe. Two measurements were taken to obtain average value.

Volume reduction potential was calculated by dividing difference between initial (before shift) and final (after shift) volume by initial volume of the joint and multiplying by 100. *T*-student test and Wilcoxon's test were used to determine statistical significance.

Results

Cadaveric study

Initial average glenohumeral joint volume was 19.4 ± 7.8 ml. This volume was reduced following capsular shift to the value of 11.9 ± 4.5 ml. Joint space was reduced by average of 37.9%. Reduction was statistically significant ($P = 0.007$). Detailed data collection is included in Table 1.

Clinical study

Average glenohumeral volume before capsular shift was 43.5 ± 10 ml. Joint volume was diminished after capsular shift was performed to the value of 17.5 ± 4.3 ml. The differences were statistically significant ($P = 0.002$). Based on those values, volume mean reduction potential was 58.8%. There were no immediate and short-term complications of the procedure. Detailed data collection is included in Table 2.

Table 1 Glenohumeral volume measurement and volume reduction potential in cadaveric study

| | Initial glenohumeral volume (ml) | GH volume after capsular shift (ml) | Volume reduction potential (%) |
|--------------|----------------------------------|-------------------------------------|--------------------------------|
| Specimen I | 9 | 6 | 33.3 |
| Specimen II | 26 | 15.5 | 40.4 |
| Specimen III | 25 | 15 | 40 |
| Specimen IV | 24 | 15 | 37.5 |
| Specimen V | 13 | 8 | 38.5 |
| Average | 19.4 | 11.9 | 37.9 |
| SD | 7.8 | 4.5 | 2.8 |

Table 2 Glenohumeral volume measurement and volume reduction potential in clinical study

| Case no. | Initial glenohumeral volume (ml) | GH volume after capsular shift (ml) | Volume reduction potential (%) |
|----------|----------------------------------|-------------------------------------|--------------------------------|
| 1 | 44 | 13 | 70.4 |
| 2 | 36 | 16 | 55.6 |
| 3 | 37 | 19 | 48.6 |
| 4 | 38 | 20 | 47.4 |
| 5 | 40 | 19 | 52.5 |
| 6 | 43 | 21 | 51.2 |
| 7 | 70 | 20 | 71.4 |
| 8 | 35 | 20 | 42.8 |
| 9 | 47 | 14 | 70.2 |
| 10 | 49 | 16 | 67.3 |
| 11 | 50 | 24 | 52 |
| 12 | 33 | 8 | 75.7 |
| Average | 43.5 | 17.5 | 58.8 |
| SD | 10 | 4.3 | 11.4 |

Discussion

Arthroscopic capsular shift presented in this paper has shown to reduce capsular volume significantly. The procedure was easy to perform and did not cause any immediate or short-term complications. That was our main idea of capsular shift. Relation of instruments and sutures to axillary nerve was not measured. One of potential advantages of grasping the capsule and lifting superiorly with grasper is that no instrument (penetrating grasper or suture passer) is introduced through the capsule into axillary area. All "sharp" maneuvers are performed anteriorly to glenoid.

Our technique of arthroscopic capsular shift is modification of previously reported techniques [10, 12, 13, 18–20]. General idea of plication of capsule using multiple suture anchors remains the same. Main difference is manipulation of capsule and suture handling that make technique very simple and efficient. The advantages of our technique are precise control of capsular plication, ease of capsular shift and suture manipulation, potential safety for axillary nerve.

Presented here technique proved to be very efficient with ca. 59% volume reduction in clinical setting and ca. 38% in cadaveric study. It is similar or slightly better to other arthroscopic plication techniques tested on cadaver model. Other studies evaluating capsular shift performed arthroscopically showed various potential of volume reduction. Karas et al. reported 19% reduction with capsular plication and tuck stabilization in area of 4–8 o'clock [15]. Flanigan et al. with same location of stabilization but controlled amount of tissue plication (5 and 10 mm increments) achieved 35% reduction [21]. Another study by Cohen showed 22.8% volume reduction [10]. Capsule was shifted in 3 points at 5, 4 and 8 o'clock positions. Thermal shrinkage showed similar or slightly better potential. Victoroff et al. and Karas et al. showed potential of 37 and 34%, respectively [14, 15]. When this technique served as an adjunct to capsular shift, reduction achieved value of 41% [15].

Open capsular shift, which is considered gold standard for MDI, showed potential of 46–66% in many previous studies especially for humeral-based shifts [6–10].

All those studies (including our cadaver part of study) have obvious limitations. Cadaveric tissue does not reflect natural conditions with normal capsular elasticity and volume. There is different age of cadaver and instability patients, and comorbidities are present (e.g., osteoarthritis). The average volume of shoulder in our study was 19.4 ml and was simply not comparable to the volume in clinical group (43.5 ml). Some of the studies utilized cadaver model including all tissues (muscles, skin), and others were based on shoulder having purely capsule and rotator cuff coverage.

To our knowledge, there are no studies measuring the joint volume following arthroscopic capsular shift in shoulder in clinical scenario. Two clinical human studies where joint volume was recorded in shoulder instability dealt only with correlation of joint volume and shoulder instability. Those papers question the presence of increased joint volume in shoulder instability [22, 23]. However, the material consisted of patients with traumatic shoulder instability. Five shoulders in Sperber's study had bilateral instability but were all defined as anterior instability. Paper by Dietz et al. showed correlation between joint volume and body surface area (BSA) [22]. They used the index of volume/BSA for volume measurement. Contrary to that, correlation was not found in Sperber's study [23]. We did not use

volume/BSA index in our paper nor was that index used in cadaver studies before. Our clinical results showed a decrease in the glenohumeral joint volume by 58.8%.

The pathogenesis of shoulder instability is still not very clear. It is not very clear what is the role of joint volume in shoulder instability. What is the main stabilizing effect of capsular shift—decreased volume or tensioned capsule. They both occur during procedure. Arthroscopic thermal shrinkage decreases both volume and translation in glenohumeral joint [14]. We know that if just anterior capsule is shifted in lateral to medial direction then external rotation limitation may be anticipated and increased load on posterior glenoid provoked [24, 25]. Theoretically, our arthroscopic capsular shift follows not only lateral/medial but mostly superior direction. Yet, that has not been investigated.

Decreased joint volume influences joint pressure and tensions the ligaments. It may also affect proprioception and in this way improve dynamic control of the joint. We know that more capsule is shifted the more reduction in volume can be achieved [21]. We obviously do not know how much capsule should be shifted anteriorly or posteriorly. Another issue that has not been defined is what is the optimal volume reduction for shoulder stabilization in MDI.

Conclusions

Arthroscopic capsular shift presented in this paper seems to be relatively easy to perform and safe procedure. The technique provides significant decrease in joint volume. That has been confirmed by cadaver (37.9% volume reduction) and clinical study (58.8% volume reduction).

Conflict of interest None.

Open Access This article is distributed under the terms of the Creative Commons Attribution Noncommercial License which permits any noncommercial use, distribution, and reproduction in any medium, provided the original author(s) and source are credited.

References

1. Smith A, Miller J (2006) Knee prostheses in elderly. *Spine* 8:705–712
2. Itoi E (2004) Pathophysiology and treatment of atraumatic instability of the shoulder. *J Orthop Sci* 9:208–213
3. Gerber C, Nyffeler RW (2002) Classification of glenohumeral joint instability. *Clin Orthop Relat Res* 400:65–76
4. Caprise PA Jr, Sekiya JK (2006) Open and arthroscopic treatment of multidirectional instability of the shoulder. *Arthroscopy* 22(10):1126–1131
5. Yamaguchi K, Flatow EL (1995) Management of multidirectional joint instability. *Clin Sports Med* 14(4):885–902
6. Neer CS II, Foster CR (1980) Inferior capsular shift for involuntary inferior and multidirectional instability of the shoulder. A preliminary report. *J Bone Joint Surg Am* 62:897–908

7. Lubowitz J, Bartolozzi A, Rubinstein D et al (1996) How much does inferior capsular shift reduce shoulder volume? *Clin Orthop Rel Res* 328:86–90
8. Miller MD, Larsen KM, Luke T, Leis HT, Plancher KD (2003) Anterior capsular shift volume reduction: an in vitro comparison of 3 techniques. *J Shoulder Elbow Surg* 12:350–354
9. Luke TA, Rovner AD, Karas SG, Hawkins RJ, Plancher KD (2004) Volumetric change in the shoulder capsule after open inferior capsular shift versus arthroscopic thermal capsular shrinkage: a cadaveric model. *J Shoulder Elbow Surg* 13:146–149
10. Wiater JM, Vibert BT (2007) Glenohumeral joint volume reduction with progressive release and shifting of the inferior shoulder capsule. *J Shoulder Elbow Surg* 16:810–814
11. Cohen SB, Wiley W, Goradia VK, Pearson S, Miller MD, Cohen SB (2005) Anterior capsulorrhaphy: an in vitro comparison of volume reduction—arthroscopic plication versus open capsular shift. *Arthroscopy* 21(6):659–664
12. Gartsman GM, Roddey TS, Hammerman SM (2001) Arthroscopic treatment of bi-directional glenohumeral instability: two- to five-year follow-up. *J Shoulder Elbow Surg* 10:28–36
13. Wolf EM, Eakin CL (1998) Arthroscopic capsular plication for posterior shoulder instability. *Arthroscopy* 14:153–163
14. Millett PJ, Clavert P, Warner JJP (2003) Arthroscopic management of anterior, posterior, and multidirectional shoulder instability: pearls and pitfalls. *Arthroscopy* 19(suppl 1):86–93
15. Victoroff BN, Deutsch A, Protomastro P, Barber JE, Davy DT (2004) The effect of radiofrequency thermal capsulorrhaphy on glenohumeral translation, rotation and volume. *J Shoulder Elbow Surg* 13:138–145
16. Karas SG, Creighton RA, DeMorat GJ (2004) Glenohumeral volume reduction in arthroscopic shoulder reconstruction: a cadaveric analysis of suture plication and thermal capsulorrhaphy. *Arthroscopy* 20:179–184
17. Lino W, Belangero WD (2006) Labrum repair combined with arthroscopic reduction of capsular volume in shoulder instability. *Int Orthopaed (SICOT)* 30:219–223
18. Sekiya JK (2005) Arthroscopic labral repair and capsular shift of the glenohumeral joint: technical pearls for a multiple pleated plication through a single working portal. *Arthroscopy* 21(6):766.e1–767.e1
19. Wichman MT, Snyder SJ (1997) Arthroscopic capsular plication for multidirectional instability of the shoulder. *Oper Tech Sports Med* 5(4):238–243
20. Cacak N, Klobucar H, Bicanic G, Trsek D (2005) Arthroscopic extracapsular plication to treat multidirectional instability of the shoulder. *Arthroscopy* 21(10):1278.e1–1278.e6
21. Wiley WB, Goradia VK, Pearson SE (2005) Arthroscopic capsular plication-shift. *Arthroscopy* 21(1):119–121
22. Flanigan DC, Forsythe T, Orwin J, Kaplan L (2006) Volume analysis of arthroscopic capsular shift. *Arthroscopy* 22(5):528–533
23. Dietz SO, Bartl C, Magosch P, Lichtenberg S, Habermeyer P (2006) Intra-articular volume assessment in glenohumeral instability. *Knee Surg Sports Traumatol Arthrosc* 14:189–192
24. Sperber A, Wredmark T (1994) Capsular elasticity and joint volume in recurrent anterior shoulder instability. *Arthroscopy* 10:598–601
25. Ahmad CS, Wang VM, Sugalski MT, Levine WN, Bigliani LU (2005) Biomechanics of shoulder capsulorrhaphy procedures. *J Shoulder Elbow Surg* 14:12S–18S