

A case of delayed cardiac perforation of active ventricular lead

Hangyuan Guo, Yangbo Xing, Fukang Xu
Department of Cardiology, Shaoxing People's Hospital, Shaoxing Hospital of Zhejiang University, Shaoxing, China

Abstract

A 65-year-old man was admitted as for one month of repetitive dizziness and one episode of syncope. Electrocardiogram showed sinus bradycardia and his Holter monitoring also showed sinus bradycardia with sinus arrest, sino-atrial block and a longest pause of 4.3 s. Then sick sinus syndrome and Adam-Stokes syndrome were diagnosed. Then a dual chamber pacemaker (Medtronic SDR303) was implanted and the parameters were normal by detection. The patient was discharged 1 week later with suture removed. Then 1.5 month later the patient was presented to hospital once again for sudden onset of chest pain with exacerbation after taking deep breath. Pacemaker programming showed both pacing and sensing abnormality with threshold of $> 5.0V$ and resistance of 1200Ω . Lead perforation was revealed by chest X-ray and confirmed by echocardiogram. Considering the fact that there was high risk to remove ventricular lead, spiral tip of previous ventricular lead was withdrawn followed by implantation of a new ventricular active lead to the septum. Previous ventricular lead was maintained. As we know that the complications of lead perforation in the clinic was rare. Here we discuss the clinical management and the possible reasons for cardiac perforation of active ventricular lead.

Introduction

The ventricular pacemaker lead could pass the signal from the pacemaker to the pacing site and active the local muscle. Then the cardiac excitation spreads to the right and left ventricular and makes the whole heart contract. That's the way the pacemaker achieves its function for the patients.¹

By connecting to the Myocardial, the lead tip could fixed to the pacing site.² However, as the heart beats continuously and the patient breathes every day, the lead will swing accordingly. During the process, it not only makes the lead abrasion or degeneration, but also makes it moving. And the complications of lead dislocation in the clinic was common.³ To be seri-

ous, there would be fatal event-the perforation of active ventricular lead. And here we mention a man who undergone the event.

Case Report

This was a 65-year-old male patient presented with 1 month of repetitive dizziness and 1 episode of syncope. He did not have known history of hypertension or diabetes mellitus. Physical examination revealed a BP of 120/60 mmHg and a regular cardiac rhythm with heart rate of 60bpm. On auscultation there was no cardiac murmur and his lung was clear without rales. He was lean and his abdominal palpitation was supple. He did not have bilateral lower limb edema. There were no abnormal findings on routine blood test, biochemistry, coagulation, chest X-ray and echocardiogram. Electrocardiogram showed sinus bradycardia and his Holter monitoring also showed sinus bradycardia with sinus arrest and sino-atrial block and a longest pause of 4.3 s. Thus, sick sinus syndrome and Adam-Stokes syndrome were diagnosed. A dual chamber pacemaker (Medtronic SDR303) was implanted with an atrial threshold (passive lead) of 1.0V, sensing of 6.0mV and resistance of 600Ω . Ventricular threshold (active lead) was 1.0V and sensing was 6.0mV while resistance was 780Ω . The patient was discharged 1 week later with suture removed. His various parameters 2 weeks after procedure were normal during pacing programming. He presented to hospital with sudden onset of chest pain with exacerbation after taking deep breath 1.5 month after procedure. Pacemaker programming showed both pacing and sensing abnormality with threshold of $> 5.0V$ and resistance of 1200Ω . Chest X-ray revealed lead perforation in right ventricle and a concomitant left pneumothorax (10% compression) (Figure 1A). Echocardiogram indicated right ventricular lead perforation without evident pericardial effusion. Considering the fact that there was high risk to remove ventricular lead, spiral tip of previous ventricular lead was withdrawn followed by implantation of a new ventricular active lead to septum. Previous ventricular lead was maintained (Figure 1B). Patient was asymptomatic after procedure and repeat chest X-ray did not show abnormal location of previous lead. There was no evident pericardial effusion on echocardiogram and the patient remained uneventful during 6-month follow-up after procedure.

Discussion

Cardiac perforation after permanent pacemaker implantation was first reported in 1996

Correspondence: Hangyuan Guo, Department of Cardiology, Shaoxing People's Hospital, Shaoxing Hospital of Zhejiang University, Shaoxing, 312000, China.
Tel. +86.575.882.288.88 - Fax: +86.575.882.288.99
E-mail: ghangyuan@hotmail.com

Key words: pacemaker, complication, perforation, ventricular lead.

Received for publication: 11 October 2011.
Accepted for publication: 18 October 2011.

This work is licensed under a Creative Commons Attribution NonCommercial 3.0 License (CC BY-NC 3.0).

©Copyright H. Guo et al., 2011
Licensee PAGEPress, Italy
Clinics and Practice 2011; 1:e104
doi:10.4081/cp.2011.e104

by Crow.⁴ By definition, it is cardiac perforation happened during or after pacemaker implantation and is related to pacing leads. Most of the perforations locate at atrial or ventricular myocardium. Usually the diagnosis can be established if the tip of the pacing lead exceeds 3mm of the cardiac contour. Cardiac perforation happened within 1 month after procedure is referred to as early perforation. Whereas that happened more than 1 month after procedure is referred to as delayed perforation.⁵ With the development of contemporary pacing leads and improvement of implantation technique, the complication of cardiac perforation decreases significantly with an incidence of early perforation 5%~7%. According to retrospective analysis 2535 pacemaker implantations by Zado from US in 2006, the incidence of delayed perforation was 0.17%.⁶ Most cardiac perforation was related to manipulation of pacing lead. Therefore, most perforation happened during or early after procedure. In some cases there was no evidence of lead perforation during procedure, while cardiac perforation occurred 24 h or several days or even 3 years after procedure. Common causes for cardiac perforation after pacemaker implantation were: on or previous prescription of corticosteroids, use of active lead, excessive lead length or tension, BMI <20 and use of bipolar electrode.⁷ Clinical manifestation of cardiac perforation varies from case to case. Most cases presented asymptotically or only presented as pacing or sensing abnormality, which usually underwent unnoticed.⁸ Severe cases could be presented as pulmonary embolism, hemopneumothorax, cardiac tamponade or even sudden death.⁹ Cardiac perforation typically presented as chest pain⁵ or extracardiac muscle stimulation by pacing lead,¹⁰ e.g. intercostal muscle, mediastinum

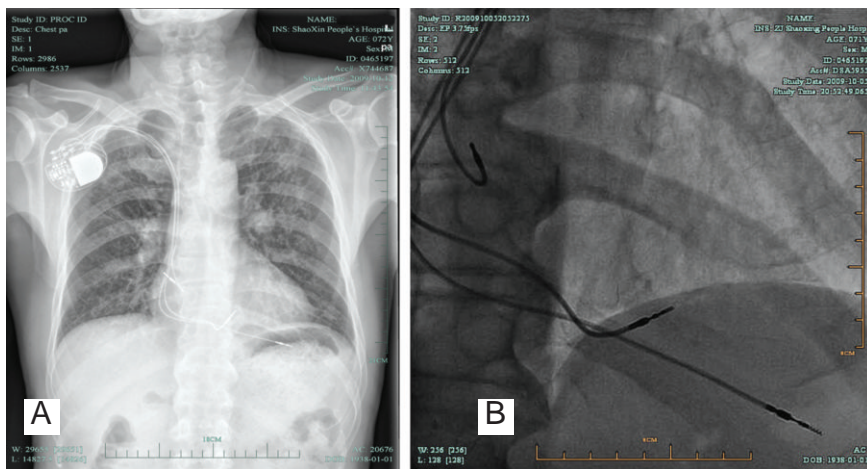


Figure 1. A) Chest X-ray revealed perforation of myocardium by active lead of RV; B) Withdraw spiral tip of first lead and implant a new active lead into septum.

and diaphragm. If cardiac tamponade occurred, consequently it will be presented as palpitation, dyspnea, cyanosis and agitation.¹¹ The key issue of management of cardiac perforation caused by pacing lead is whether perforated lead needs treatment and if so, how. Currently, there are not adequate proofs as to which strategy is best. Generally speaking, extraction of pacing lead and implantation of new lead under echocardiogram guidance and surgical backup is preferred with high success rate, though experience is limited. The treatment of delayed cardiac perforation as to whether treat it conservatively or surgically and whether to remain or remove the perforated lead are still high debatable and evidence is scarce. Liu Jian reported a case of delayed chronic perforation 2 years after implantation of a ventricular passive lead. There was no symptom of cardiac tamponade and a new lead was implanted while previous lead was remained. This leads to good follow up result.¹² Li Xuebin reported 8 cases of acute perforation with the longest delay after procedure of 17 days. Previous leads were all removed and new leads were introduced. This also leads to good follow up result.¹³ Storm *et al.* reported 3 cases of cardiac tamponade caused by perforation of atrial active lead, among which 2 received open chest surgery and relocation of pacing lead. One patient underwent removal of previous lead in cathlab with pericardial drainage in situ.¹⁴ Zado reported 5 cases of delayed cardiac perforation, among which only 2 had alteration in pacing parameters, 2 only underwent pericardiocentesis, 2 pericardial drainage, 1 removal of previous lead when pericardial drainage was in situ, 2 underwent open chest surgery. There were no severe complications during patient follow up.⁶

In our case, the patient presented suddenly with chest pain typically after taking deep breath 1.5 year after procedure. Programming

of pacemaker showed both pacing and sensing abnormality for ventricular pacing lead. Chest X-ray revealed lead perforation in right ventricle and a concomitant left pneumothorax (10% compression). Echocardiogram indicated right ventricular lead perforation without evident pericardial effusion. The possible reason for the perforation could be: use of ventricular active and bipolar lead, lean body stature, lead tip perforated although various parameters were normal, excessive lead length or tension. Pneumothorax was caused by piercing of lung tissue by spiral lead and chest pain was also deemed to be related to this reason. Precise time of cardiac perforation was hard to determine. After literature review the feasible options were: maintain previous lead while withdraw spiral tip and simultaneous implantation of a new lead; surgical consultation and open chest surgery; removal and relocation of previous lead under pericardial drainage and surgical backup. Considering the fact that the patient was hemodynamically stable and without pericardial effusion, it was possible that perforation was contained by blood clot and fat tissue. Thus, there was high risk to remove ventricular lead or referred the patient to surgery. First option was adopted to withdraw spiral tip of previous ventricular lead followed by implantation of a new ventricular active lead to septum. Previous ventricular lead was maintained. Patient was asymptomatic after procedure and repeat chest X-ray did not show abnormal location of previous lead. There was no evident pericardial effusion on echocardiogram and the patient remained uneventful during 6 month follow-up after procedure.

Acute or chronic cardiac perforation caused by pacing lead is not rare and warrant caution and prompt management by clinicians. Remain the previous lead and implantation of a new lead might be a safe treatment when

patient is hemodynamically stable and there is no cardiac tamponade.

References

- Glikson M, Hayes DL. Cardiac pacing. A review. *Med Clin North Am* 2001;85:369-421.
- Cano O, Osca J, Sancho-Tello MJ, et al. Comparison of effectiveness of right ventricular septal pacing versus right ventricular apical pacing. *Am J Cardiol* 2010;105:1426-32.
- Bailey SM, Wilkoff BL. Complications of pacemakers and defibrillators in the elderly. *Am J Geriatr Cardiol* 2006;15:102-107.
- Crow EW. Myocardial perforation by a pacemaker catheter. *J Kans Med Soc* 1966;67:309.
- Schroeter T, Doll N, Borger MA, et al. Late perforation of a right ventricular pacing lead: a potentially dangerous complication. *Thorac Cardiovasc Surg* 2009;57:176-7.
- Geyfman V, Storm RH, Lico SC, Oren JW 4th. Cardiac tamponade as complication of active-fixation atrial lead perforations: proposed mechanism and management algorithm. *Pacing Clin Electrophysiol* 2007;30:498-501.
- Mahapatra S, Bybee KA, Bunch TJ, et al. Incidence and predictors of cardiac perforation after permanent pacemaker placement. *Heart Rhythm* 2005;2:907-11.
- Rubens M, Anbe DT, Drake EH, Ormond RS. Clinical evaluation of myocardial perforation as a complication of permanent transvenous pacemakers. *Chest* 1973;63:185-8.
- deRoux SJ. Fatality following right atrial perforation by a screw-in pacemaker electrode. *J Forensic Sci* 2005;50:1191-3.
- Ellenbogen KA, Wood MA, Shepard RK. Delayed Complications Following Pacemaker Implantation. *Pacing Clin Electrophysiol* 2002;25:1155-8.
- Gershon T, Kuruppu J, Olshaker J. Delayed cardiac tamponade after pacemaker insertion. *J Emerg Med* 2000;18:355-9.
- Jian Liu, Kanghua Ma, ZirongYang Yue Li. A case of chronic cardiac perforation induced by endocardial electrode wire. *J Chongqing Med Uni* 2001;26:346.
- Li X, Wang B, Liu S, et al. Clinical manifestation and management in the patients with early phase pacing lead perforation. *J Clin Cardiol* 2008;24:565-7.
- Polin GM, Zado E, Nayak H, et al. Proper management of pericardial tamponade as a late complication of implantable cardiac device placement. *Am J Cardiol* 2006;98:223-5.