



## Case report

# A distinguished case of a spontaneously dissecting Left Common Iliac Artery Aneurysm, associated with an Elastinopathy, in a healthy 36-year-old male, successfully treated with open surgical repair - A Case Report

Omar Hariri<sup>a,b</sup>, Omar Al Laham<sup>a,b,\*</sup>, Ammar Mohammad<sup>c</sup>

<sup>a</sup> Department of Surgery, Al-Mouwasat University Hospital, Mazzah, Damascus, Syria

<sup>b</sup> Department of Surgery, Al Assad University Hospital, April 17th St. Kafar Sousah, Damascus, Syria

<sup>c</sup> Department of Vascular Surgery, Al Assad University Hospital, April 17th St. Kafar Sousah, Damascus, Syria

## ARTICLE INFO

## Keywords:

Case Report

Elastinopathies

Aneurysms

Spontaneously dissecting Iliac Artery

Aneurysm

Vascular Surgery emergency

Aorto-bi-Femoral Bypass

## ABSTRACT

**Introduction and importance:** Elastin is a major protein of the Extracellular Matrix (ECM), essential in providing elasticity to the vascular wall, which enables blood vessels to reversibly expand and contract.

Several inherited or acquired etiologies, such as elastinopathies and fibrillinopathies negatively impact the objective of the Extracellular Matrix via compromising the Elastin fibers in the Cardiovascular System (CVS) and the skin.

Such compromises will have devastating ramifications through the increase in vascular wall stiffness and the inability to properly dissipate energy. This impact on the vascular wall will contribute to the development of arterial aneurysms and dissections.

**Case presentation:** Our case is of a 36-year-old previously healthy male patient who presented with an acute onset of left lower limb pain associated with cold sensation two days prior to admission. Radiology demonstrated a dissecting aneurysm in the left Common Iliac Artery.

**Clinical discussion:** The patient was surgically treated with an Aorto-bi-Femoral Bypass (ABFB).

Histopathological analysis of the excised aortic and iliac specimens revealed no Elastin fibers in the vessel walls.

**Conclusion:** Isolated Iliac aneurysms are a rare entity and are challenging to diagnose preoperatively. In our case, there were no risk factors whatsoever and the patient's history - including family history - was negative. It is vital to establish preoperative diagnostic approaches in such cases and keep them in mind so that we can diminish the morbidity and mortality resultants from the complications.

## 1. Introduction

Aneurysms are defined as any pathological increase of more than 50% of the original arterial diameter. Isolated Iliac Artery Aneurysms (IAAs) are exceptionally rare, comprising less than 2% of all aneurysmal pathologies with an incidence rate of merely 8–11% in patients older than 65 years of age [1,2]. We consider an Iliac arterial diameter of more than (1.8 cm) in males or more than (1.5 cm) in females to constitute the diagnosis of an aneurysm [1,3]. We triage a patient with an Iliac Artery diameter exceeding (3.5 cm) [4] or an expansion rate of more than (1 cm) per year, a candidate for intervention [5]. This is conventionally

witnessed in older males with a history of hypertension, smoking, or less commonly due to iatrogenic injury, trauma, arteritis, connective tissue pathologies, or infections [6–10]. Classically, they are asymptomatic, thus, problematic to diagnose preoperatively during physical examination unless they reached a large size evident on palpation. Nonetheless, preoperative suspicion can be originated if there was a compromise of nearby vital structures (i.e., the urinary system, bowel loops, nerve roots, pelvic veins), as a complication of thrombus formation, rupture, or dissection [9]. Patient presentation varies, this can be depicted by several ill-defined symptoms, the commonest of which is sudden abdominal, groin, or flank pain. Moreover, patients report intermittent

**Abbreviations:** ECM, Extracellular Matrix; CVS, Cardiovascular System; ABFB, Aorto-bi-Femoral Bypass; IAAs, Iliac Artery Aneurysms; CRP, C-Reactive Protein; ESR, Erythrocyte Sedimentation Rate; DUS, Doppler Ultrasound; CTA, Computed Tomography Angiography; AAAs, Abdominal Aortic Aneurysms; CT, Computed Tomography; SMCs, Smooth Muscle Cells; MRI, Magnetic Resonance Imaging.

\* Corresponding author at: Department of Surgery, Al-Mouwasat University Hospital, Mazzah, Damascus, Syria.

E-mail addresses: [omar.hariri1992@gmail.com](mailto:omar.hariri1992@gmail.com) (O. Hariri), [3omar92@gmail.com](mailto:3omar92@gmail.com) (O. Al Laham), [ammarmhd@yahoo.fr](mailto:ammarmhd@yahoo.fr) (A. Mohammad).

<https://doi.org/10.1016/j.ijscr.2022.107253>

Received 29 April 2022; Received in revised form 25 May 2022; Accepted 28 May 2022

Available online 30 May 2022

2210-2612/© 2022 The Author(s). Published by Elsevier Ltd on behalf of IJS Publishing Group Ltd. This is an open access article under the CC BY-NC-ND license (<http://creativecommons.org/licenses/by-nc-nd/4.0/>).

claudication or chronic vague lower limb discomfort [9]. This leads to misdiagnoses, which in turn, raise the rates of morbidity and mortality.

The work has been reported in line with the SCARE criteria and the revised 2020 SCARE guidelines [30].

## 2. Presentation of case

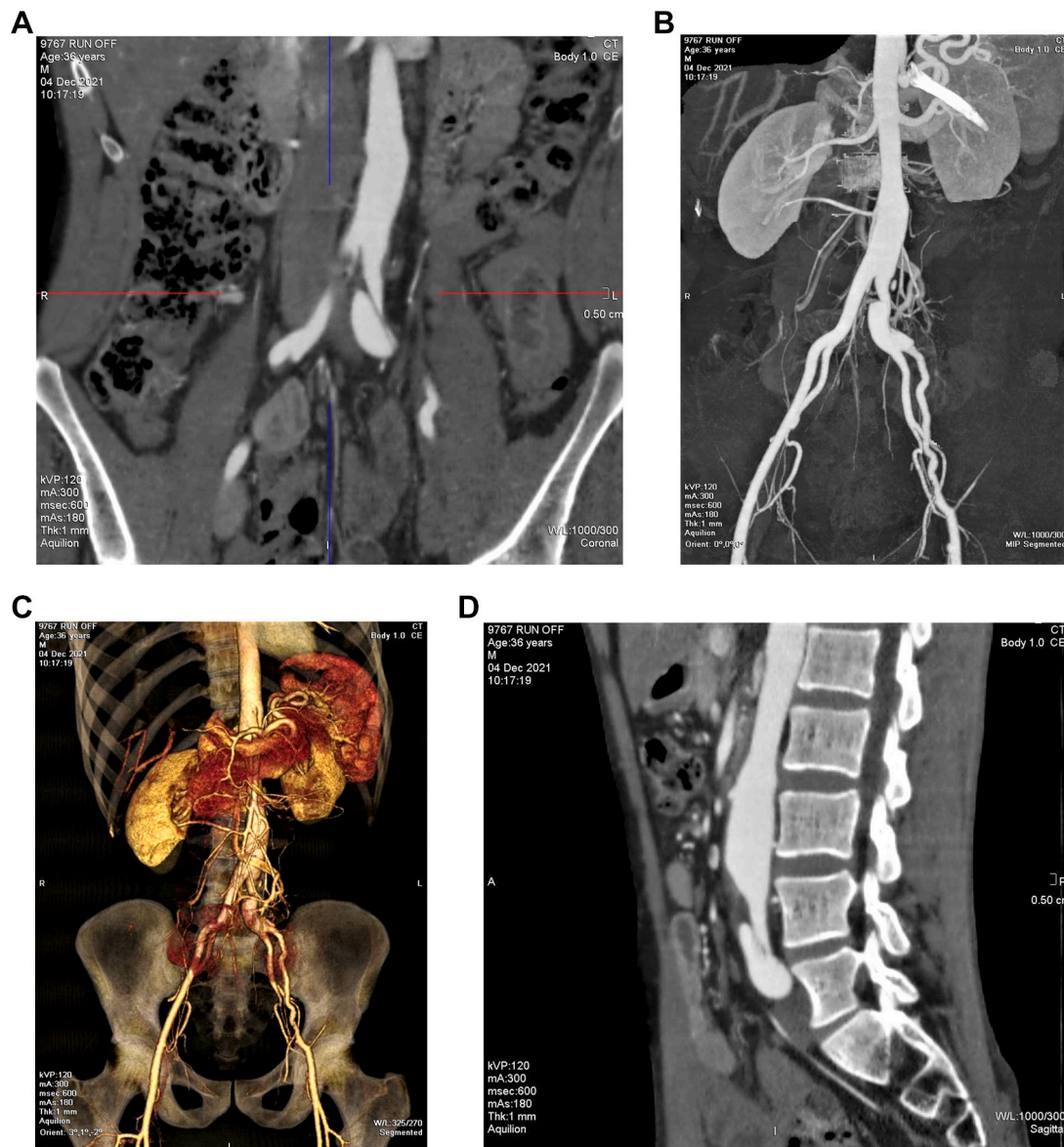
### 2.1. Patient information

We present the case of a previously healthy 36-year-old Middle Eastern male patient, who presented to the Vascular Surgery clinic at our tertiary university hospital with symptoms commencing 10 days prior to admission. His story instigated as an acute onset of unspecific left lower limb pain. It was sudden, persistent, scaling 4 out of 10 according to the patient, and associated with numbness, paresthesia, and coldness of the affected lower limb, which lasted for two days. Afterwards, the pain was

concentrated in left groin, the limb's temperature was spontaneously restored. However, the pain was unresponsive to over-the-counter analgesics. It was aggravated by ambulation and partially relieved by lying down. He reported a history of lacrimation when subjected to light sources. No intermittent claudication, fever, vascular ulceration, or skin changes were stated. Moreover, no genitourinary symptoms or alteration of bowel habits were reported. The patient is an ex-smoker with a 3-pack-year smoking history. He isn't an alcoholic. His BMI is 19 kg/m<sup>2</sup>. His height is 1.5 m. Surgical history involved an open Appendectomy 20 years ago and two exploratory laparotomies for adhesiolysis. Familial, drug, and allergic histories were all negative.

### 2.2. Clinical findings

Vital signs were normal. Upon inspection, no skin changes were noted -including ulceration, pallor, ecchymosis, or reticular spotting-



**Fig. 1.** A–B: Computed Tomography Angiography (CTA) coronal view yielded; Terminal abdominal aortic dilation measuring (3.0 cm), and an isolated dissected left Common Iliac Artery aneurysm, estimated to measure (5.5 × 4.5 cm). No calcifications were noted.

C: Computed Tomography Angiography (CTA) three-dimensional view yielded; Terminal abdominal aortic dilation measuring (3.0 cm), and an isolated dissected left Common Iliac Artery aneurysm, estimated to measure (5.5 × 4.5 cm).

D: Computed Tomography Angiography (CTA) sagittal view yielded; Terminal abdominal aortic dilation measuring (3.0 cm), and an isolated dissected left Common Iliac Artery aneurysm, estimated to measure (5.5 × 4.5 cm).

Upon palpation, pulse was vividly palpable along the entire arterial axis of the left lower limb. No palpable masses in the abdomen, groin, or popliteal fossa were detected. Upon auscultation, a notable thrill was heard over the path of the left Common Femoral Artery. No other thrills were auscultated over the rest of the arterial axis.

### 2.3. Laboratory investigations

C-Reactive Protein (CRP) was normal and was 0.1 mg/dl. Erythrocyte Sedimentation Rate (ESR) was normal and was 12 mm/h in the 1st hour. The remaining laboratory panel was within normal ranges.

### 2.4. Diagnostic assessment

Doppler Ultrasound (DUS) revealed a dissecting left Common Iliac Artery aneurysm spanning into the left External Iliac Artery, with a visual flap in it. It measured approximately (4 × 5 cm) with wall thrombosis seen within it. The remainder of the arterial axis was normal. Upon admission, a Computed Tomography Angiography (CTA) was done and yielded; terminal abdominal aortic dilation measuring (3.0 cm), and an isolated dissected left common Iliac Artery Aneurysm, estimated to measure (5.5 × 4.5 cm). No calcifications were noted (Fig. 1A–D).

Initial management included keeping the patient in a nil-per-mouth status, establishing intravenous access, prophylactic antibiotics, complete blood panel, blood sampling and crossmatch for surgical preparation. Noteworthy challenges were the unavailability of a laparoscopic machine in the Emergency Department at the time of surgery and the inability to perform genotyping for the patient due to his low socioeconomic status and unavailability of the required materials in the accessible labs.

### 2.5. Therapeutic intervention

Based on the clinical preoperative assessment which was comprised of the following elements: A previously healthy male with short stature, low BMI, young age, negative familial and risk factor histories, aortic ectasia, and an isolated dissecting Common Iliac Artery aneurysm (Arterial wall dilation in more than one segment), a rheumatologic consultation was warranted. Surgery was accomplished at our university hospital by a Vascular Surgery consultant with 15 years of Vascular Surgery experience. It was undergone under general anesthesia with no complications. It concluded that this case could be a result of an

undiagnosed connective tissue such as the vascular variant of Ehlers-Dalnos Syndrome or an overall Elastinopathy.

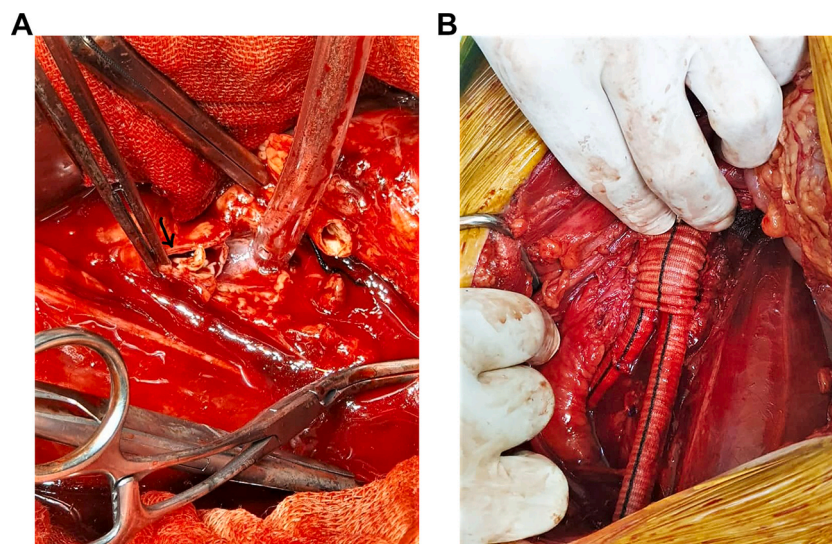
To evade the unpredictable intraoperative complications, an ABFB was deemed to be the therapeutic intervention. Based on the patient's prior surgical history, a classical midline abdominal incision was circumvented, and a pararectal retroperitoneal incision was done. The intraoperative findings confirmed the preoperative radiological analysis.

As suspected prior to surgery, the arterial walls were abnormally stretching and were friable during the anastomotic phase of the operation, we covered the aortic anastomosis with a tube of Dacron to minimize the risk of developing aneurysms and to protect the anastomosis from rupture. The Inferior Mesenteric Artery, the terminal Aorta, the External and Left Internal Iliac Arteries were ligated. An ABFB was done with a Dacron (16 × 8 cm) prosthesis (Fig. 2A–B).

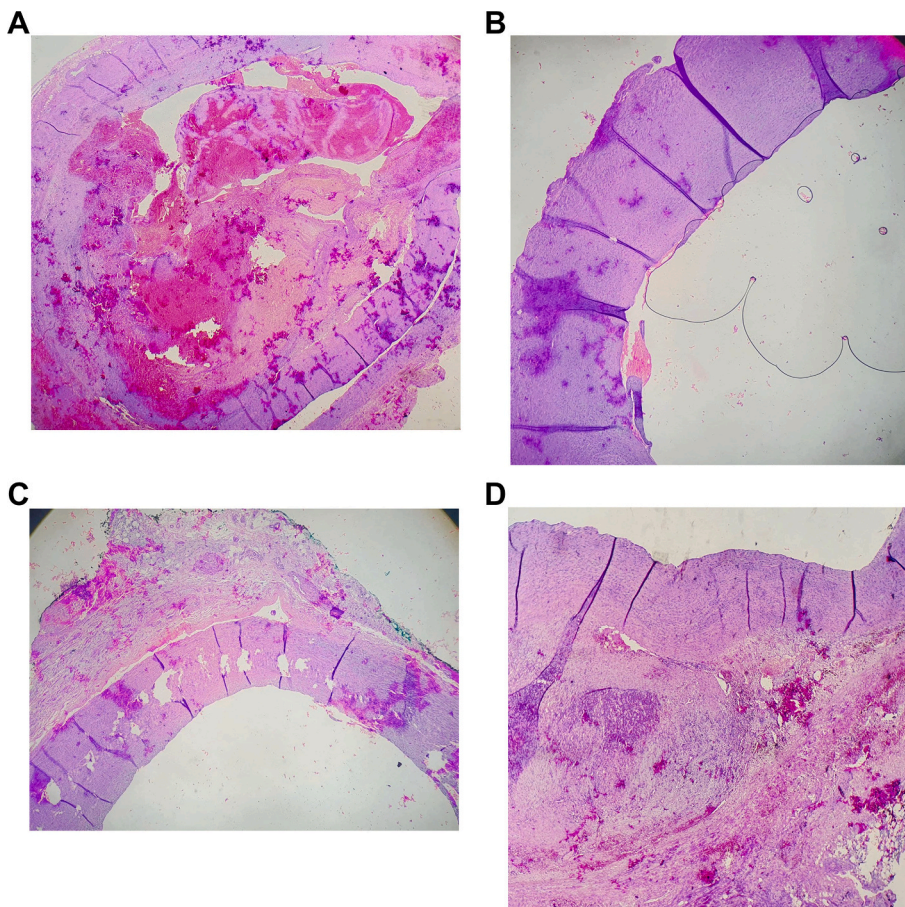
A full thickness aortic wall biopsies from the right and left Common Iliac Arteries and the abdominal Aorta, with proper length was taken to confirm the suspected etiology behind the diagnosis. Histopathological analysis revealed dilation and an organized thrombus formation. Furthermore, no elastic fibers were noted (Fig. 3A–D). The patient had an uneventful postoperative recovery and was discharged within 5 days of surgery. He was provided with instructions which ameliorate his recovery (i.e., regular sterile wound dressings, analgesics, and a prescription of postoperative antibiotics). A follow-up protocol was assigned in the outpatient settings for 6 months now. He has had regular appointments at the Vascular Surgery clinic to undergo surgical examination and DUS imaging.

### 3. Discussion

Ad Hoc Committee depicted in their report to the Society for Vascular Surgery in 1991 that what constitutes an arterial aneurysm is when an artery suffers from 50% increase in its original diameter as a minimum [11]. The most prevalent occurrence site for extracranial arterial aneurysms is in the infrarenal aortic segments [12–14]. Furthermore, Abdominal Aortic Aneurysms (AAAs) are estimated to be 9 times more rampant than thoracic aortic aneurysms [15]. It is settled that merely 5% of males and 1.7% of females who are older than 65 years of age will develop an infrarenal aortic segment aneurysm with a diameter larger than (3 cm). Nevertheless, it's projected that there's a 6% increase in the chance of developing an aortic aneurysm for every subsequent decade after the previously mentioned age [16].



**Fig. 2.** A: Intraoperative image where the black arrow depicts the dissected aneurysmal Iliac Artery lumen (Arrow). B: Intraoperative image depicting the ABFB which was done with a Dacron (16 × 8 cm) prosthesis.



**Fig. 3.** A: Histopathological analysis revealed arterial dilation and an organized thrombus formation. B: Histopathological analysis of the right Common Iliac Artery revealing the absence of Elastin from the arterial wall. C–D: Histopathological analysis of left Common Iliac Artery revealing the dissection and the absence of Elastin from the arterial wall. Furthermore, no Elastic fibers were found.

The most common segments affected by the pathophysiology of aneurysmal degeneration are in descending order; the common iliacs (70–90%), the internal iliacs (10–30%), or those two simultaneously. In contrast, an External Iliac Artery aneurysm is ponderously rare in occurrence [3,17].

Conventionally, IAAs are stumbled-upon incidentally preoperatively whilst clinical screening for a AAA, especially when a patient undergoes ultrasonography or an abdominal/pelvis Computed Tomography (CT) scan to diagnose other suspected pathologies [1,3]. This is classically observed in older males with a history of hypertension, smoking, or less commonly due to iatrogenic injury, trauma, arteritis, connective tissue pathologies, or infections [6–10].

Traditionally, they are asymptomatic, thus, problematic to diagnose preoperatively during physical examination unless they reached a large size evident on palpation. Nonetheless, preoperative suspicion could be present if there was a compromise of nearby vital structures (i.e., the urinary system, bowel loops, nerve roots, pelvic veins), as a complication of thrombus formation, rupture, or dissection [9].

The integrity and function of an arterial blood vessel walls is maintained by key elements such as the delicate balance between the degradation of the ECM by proteins, mechanical patency, inflammation processes, and the malfunctioning remodeling complex mechanism. This all occurs in the setting of increased risk-patients, whether due to congenital predisposition or sporadic environmental factors [4,18].

When it comes to the integrity and aortic blood vessel wall patency, Elastin fibers are key components necessitated for the proper recoil and expansive tasks of the arterial walls. Any dysfunction in those fibers can lead to devastating effects in the affected arteries [19].

We must also highlight the vitality of Elastin fibers working conjointly with Smooth Muscle Cells (SMCs) to enable the arterial wall to correctly transmit the mechanical signals emitted by the actinomyosin

component and directed towards the elastic lamella. We must emphasize the recurrent failure of clinical physical examination in discovering IAAs [20].

We reliably resort to radiological analysis due to its proven sensitivity and specificity in identifying such aneurysms and in turn, plan for surgical interventions. For example, Doppler Ultrasound in the hand of an expert user constitutes the corner stone for screening and diagnosis of aneurysms. Moreover, CT and Magnetic Resonance Imaging (MRI) are the gold standard for depicting a detailed anatomical image of the affected arteries, hence, providing an enhanced accuracy in diagnosing and documenting such aneurysms. However, planning surgical interventions can be challenging and requires an extensive degree of imaging analysis. This is provided by CT arteriography because of its high-resolution imaging output. Finally, with the aid of radiology software, we depict 3-D postprocessing images to fully visualize the vascular tree and the affected arterial segments [21].

Symptomatic IAAs warrant surgical intervention. The current consensus prefers an elective repair for asymptomatic IAAs with a diameter greater than (3.5 cm) in previously healthy individuals [4]. However, asymptomatic IAAs with a diameter smaller than (3 cm) are preferred to be surveilled with regular imaging modalities [21,22].

There's a considerable risk for bleeding in conventional surgical interventions. It is especially challenging because of the anatomical situation of IAAs in the pelvis, in addition to the high density of pelvic veins, the coexisting atherosclerotic plaques and calcifications [23].

Previously healthy patients who possess unremarkable risk factors undergo a smooth and successful open surgical operation to repair IAAs. The main purpose behind this surgery is to keep a healthy distal limb blood perfusion whilst attempting to stop any more degree of arterial wall degeneration, thus dissection [20].

The open surgical technique classically involves a midline,

transplant-type, or a retroperitoneal incision. This is based on the previous surgical history of the patient, the extent of said aneurysm, whether the pathology is uni-/bilateral, and naturally, the surgeon's experience.

One essential benefit of open surgical repair of IAAs is the ability to maintain adequate collateral flow of blood to the pelvis via the mesenteric and lumbar arteries. This will in turn, considerably diminish the risk of postoperative pelvic and/or colonic ischemia [24].

The general prevalence of perioperative complications can rise-up to 22%. This demarcates lower limb ischemia, visceral or pelvic organs ischemia, aneurysmal dissection or rupture, arterioenteric fistula development, infection of used graft, sepsis, and surrounding organs injury [4,17,25].

Regarding graft patency, early and late complications are seldom seen. Nonetheless, its primary efficacy at the 5-year mark could reach 100% [26,27].

The ongoing scientific advancement in the field of newer generation bifurcated AAA grafts has morphed the surgical intervention from its open approach to the lesser-risk endovascular approach. Endovascular treatment of aortoiliac aneurysms and IAAs has therefore been favored if possible, over the classical open surgical intervention [28].

The endovascular approach to treatment of IAAs has proven to plunge perioperative patient complications, reduce hospital stay for patients, decrease intraoperative blood loss, and avoid the need for intensive care unit admissions postoperatively [29].

The prevalence of ruptured IAAs at the time of initial diagnosis can reach up to 33% and this is accompanied by an imminent risk of increased mortality. This is described by Bacharach et al. [9].

Emergency surgical intervention is associated with an estimated mortality risk of 28% in the past two decades. This is compared to a marked mortality risk of 5% for the elective surgical repair of IAAs [4].

#### 4. Conclusion

Elastin is a major protein component of the ECM. Its presence and its collaboration with the SMCs and other ECM constituents, play an unequivocal role in the CVS and skin patency and function. Elastinopathies are rare and result in devastating consequences such as dissecting arterial aneurysms, which will in turn, lead to increased morbidity and mortality for patients. The diagnosis of congenital Elastinopathies can further protect other asymptomatic family members by setting-up regular screening dates to avoid any possible complications.

Clinical suspicion ought to be present when presented with such cases so that we can perform timely interventions which limit the complications of such pathologies. Surgical intervention remains the gold standard treatment modality with the preferred approach being endovascular rather than open surgical techniques. Nonetheless, prognosis is satisfactory, and the success depends on a multifactorial set of elements, the most important of which is dependent on each individual case. Documentation is a key factor, such rare cases must be documented to aid in setting thorough preoperative diagnostic approaches, intraoperative surgical techniques, and postoperative optimal patient care.

#### Consent of patient

Written informed consent was obtained from the patient for publication of this case report and accompanying images. A copy of the written consent is available for review by the Editor-in-Chief of this journal on request.

#### Availability of data and materials

The datasets generated during and/or analyzed during the current study are not publicly available because the Data were obtained from the hospital computer-based in-house system. Data are available from the corresponding author upon reasonable request.

#### Provenance and peer review

Not commissioned, externally peer-reviewed.

#### Ethical approval

Institutional review board approval is not required for deidentified single case reports or histories based on institutional policies.

#### Funding

This research did not receive any specific grant from funding agencies in the public, commercial, or not-for-profit sectors.

#### Guarantor

Omar Al Laham.

#### Research registration number

N/A.

#### CRediT authorship contribution statement

OA, OH: Conceptualization, resources, who wrote, original drafted, edited, visualized, validated, and literature reviewed the manuscript. AM: Vascular Surgery Specialist, who performed and supervised the operation. Supervision, project administration, and review of the manuscript.

OA: The corresponding author who submitted the paper for publication.

All authors read and approved the final manuscript.

#### Declaration of competing interest

The authors declare that they have no competing interests.

#### Acknowledgements

- Radiology Department at Al Assad University Hospital, Damascus, Syria. For their role in radiological imaging and result interpretation.
- Pathology Department at Al Assad University Hospital, Damascus, Syria. For their role in the histopathological analysis and interpretation of the excised specimens which helped to establish the definitive diagnosis.

#### References

- [1] N. Levi, et al., Isolated iliac artery aneurysms, *Eur. J. Vasc. Endovasc. Surg.* 16 (4) (1998) 342–344, [https://doi.org/10.1016/S1078-5884\(98\)80054-3](https://doi.org/10.1016/S1078-5884(98)80054-3).
- [2] R.J. Kasulke, et al., Isolated atherosclerotic aneurysms of the internal iliac arteries: report of two cases and review of literature, *Arch. Surg.* 117 (1) (1982) 73–77, <https://doi.org/10.1001/archsurg.1982.01380250051012>.
- [3] R.A. McCreedy, et al., Isolated iliac artery aneurysms, *Surgery* 93 (5) (1983) 688–693. PMID: 6845175.
- [4] R.S. Sandhu, et al., Isolated iliac artery aneurysms, *Semin. Vasc. Surg.* 18 (2005) 209–215, <https://doi.org/10.1053/j.semvascsurg.2005.09.007>.
- [5] S.M. Santilli, et al., Expansion rates and outcomes for iliac artery aneurysms, *J. Vasc. Surg.* 31 (2000) 114–121, [https://doi.org/10.1016/s0741-5214\(00\)70073-5](https://doi.org/10.1016/s0741-5214(00)70073-5).
- [6] J. Ferreira, et al., Isolated iliac artery aneurysms: six-year experience, *Interact. Cardiovasc. Thorac. Surg.* 10 (2) (2010) 245–248, <https://doi.org/10.1510/icvts.2009.218305>.
- [7] J. Brunkwall, et al., Solitary aneurysms of the iliac arterial system: an estimate of their frequency of occurrence, *J. Vasc. Surg.* 10 (4) (1989) 381–384, <https://doi.org/10.1067/mva.1989.13733>.
- [8] W.C. Krupski, et al., Contemporary management of isolated iliac aneurysms, *J. Vasc. Surg.* 28 (1998) 1–11, [https://doi.org/10.1016/s0741-5214\(98\)70194-6](https://doi.org/10.1016/s0741-5214(98)70194-6).

- [9] J.M. Bacharach, et al., State of the art: management of iliac artery aneurysmal disease, *Catheter. Cardiovasc. Interv.* 71 (5) (2008) 708–714, <https://doi.org/10.1002/ccd.21507>.
- [10] P.E. Norman, et al., Site specificity of aneurysmal disease, *Circulation* 121 (2010) 560–568, <https://doi.org/10.1161/circulationaha.109.880724>.
- [11] P.F. Lawrence, et al., Peripheral aneurysms and arteriomegaly: is there a familial pattern? *J. Vasc. Surg.* 28 (1998) 599–605, [https://doi.org/10.1016/S0741-5214\(98\)70082-5](https://doi.org/10.1016/S0741-5214(98)70082-5).
- [12] M. Heron, Deaths: leading causes for, *Natl. Vital Stat. Rep.* 2007 (59) (2011) 1–95. PMID: 21950210.
- [13] G. Slaney, A history of aneurysm surgery, in: R.M. Greenhalgh (Ed.), *The Cause And Management of Aneurysms*, WB Saunders, Philadelphia, 1990, pp. 1–18, [https://doi.org/10.1007/978-0-387-68113-9\\_61](https://doi.org/10.1007/978-0-387-68113-9_61).
- [14] Centers for Disease Control and Prevention, Underlying cause of death 1999–2013 on CDC WONDER Online Database released 2015 and Go AS, Mozaffarian D, Roger VL, et al. heart disease and stroke statistics—2013 update: a report from the American Heart Association, *Circulation* 127 (2013) e6–e245, <https://doi.org/10.1161/CIR.0b013e31828124ad>.
- [15] H. Kuivaniemi, et al., Opportunities in abdominal aortic aneurysm research: epidemiology, genetics, and pathophysiology, *Ann. Vasc. Surg.* 26 (2012) 862–870, <https://doi.org/10.1016/j.avsg.2012.02.005>.
- [16] R.A. Scott, et al., Abdominal aortic aneurysm in 4237 screened patients: prevalence, development and management over 6 years, *Br. J. Surg.* 78 (1991) 1122–1125, <https://doi.org/10.1002/bjs.1800780929>.
- [17] J.W. Richardson, et al., Natural history and management of iliac aneurysms, *J. Vasc. Surg.* 8 (1988) 165–171. PMID: 3294450.
- [18] G. Ailawadi, et al., Current concepts in the pathogenesis of abdominal aortic aneurysm, *J. Vasc. Surg.* 38 (2003) 584–588, [https://doi.org/10.1016/s0741-5214\(03\)00324-0](https://doi.org/10.1016/s0741-5214(03)00324-0).
- [19] M.E. Safar, B.I. Levy, H. Struijker-Boudier, Current perspectives on arterial stiffness and pulse pressure in hypertension and cardiovascular diseases, *Circulation* 107 (2003) 2864–2869, <https://doi.org/10.1161/01.CIR.0000069826.36125.B4> [PubMed: 12796414].
- [20] Q. Desiron, et al., Isolated atherosclerotic aneurysms of the iliac arteries, *Ann. Vasc. Surg.* 9 (suppl) (1995) S62–S66, [https://doi.org/10.1016/s0890-5096\(06\)60453-6](https://doi.org/10.1016/s0890-5096(06)60453-6).
- [21] US Preventive Services Task Force, Screening for abdominal aortic aneurysm: recommendation statement, AHRQ publication 05-0569-A, <https://www.uspreventiveservicestaskforce.org/uspstf05/aaascr/aaars.htm>, February 2005. (Accessed 1 June 2012).
- [22] RESCAN Collaborators, Surveillance intervals for small abdominal aortic aneurysms: a meta-analysis, *JAMA* 309 (8) (2013) 806–813, <https://doi.org/10.1001/jama.2013.950>.
- [23] W.A. Lee, Advanced aneurysm management techniques: management of internal iliac aneurysm disease, in: R.L. Dalman (Ed.), *Operative Techniques in Vascular Surgery*, Wolters Kluwer Health, The Netherlands, 2015, pp. 2015–2023, <https://doi.org/10.21037/cdt.2017.09.05>.
- [24] W. Dorigo, et al., The treatment of isolated iliac artery aneurysm in patients with non-aneurysmal aorta, *Eur. J. Vasc. Endovasc. Surg.* 35 (5) (2008) 585–589, <https://doi.org/10.1016/j.ejvs.2007.11.017>.
- [25] F.A. Lederle, et al., Smokers' relative risks for aortic aneurysm compared with other smoking-related diseases: a systematic review, *J. Vasc. Surg.* 38 (2003) 329–334, [https://doi.org/10.1016/s0741-5214\(03\)00136-8](https://doi.org/10.1016/s0741-5214(03)00136-8).
- [26] Y. Huang, et al., Common iliac artery aneurysm: expansion rate and results of open surgical and endovascular repair, *J. Vasc. Surg.* 47 (2008) 1203–1210, <https://doi.org/10.1016/j.jvs.2008.01.050>.
- [27] N.V. Patel, et al., Open vs. endovascular repair of isolated iliac artery aneurysms: a 12-year experience, *J. Vasc. Surg.* 49 (2009) 1147–1153, <https://doi.org/10.1016/j.jvs.2008.11.101>.
- [28] M. Prinszen, et al., A randomized trial comparing conventional and endovascular repair of abdominal aortic aneurysms, *N. Engl. J. Med.* 351 (16) (2004) 1607–1618, <https://doi.org/10.1056/nejmoa042002>.
- [29] C.J. Buckley, et al., Technical tips for endovascular repair of common iliac artery aneurysms, *Semin. Vasc. Surg.* 21 (1) (2008) 31–34.
- [30] R.A. Agha, T. Franchi, C. Sohrabi, G. Mathew, A. Kerwan, SCARE Group, The SCARE 2020 guideline: updating consensus Surgical CAse REport (SCARE) guidelines, *Int. J. Surg.* 84 (2020 Dec) 226–230, <https://doi.org/10.1016/j.ijsu.2020.10.034>.