

Isolated Gastric Varices Refractory to Balloon-occluded Retrograde Transvenous Obliteration (BRTO) Successfully Treated by Shunt-occluded Endoscopic Injection Sclerotherapy (SO-EIS): A Case Report and Review of the Literature

Takeshi Hatanaka^{1,2}, Satoru Kakizaki³, Yuhei Suzuki^{1,4}, Takashi Ueno¹, Yasushi Shimada¹, Daichi Takizawa^{1,5}, Kenji Katakai⁶, Ken Sato³, Motoyasu Kusano³ and Masanobu Yamada³

Abstract

Balloon-occluded retrograde transvenous obliteration (BRTO) is widely used to treat isolated gastric varices (IGVs) in Japan. However, BRTO is difficult to perform for IGVs with many small collateral veins, and no secondary treatment has been established. We herein report a rare case of IGVs refractory to BRTO successfully treated by shunt-occluded endoscopic injection sclerotherapy (SO-EIS), which is a combination therapy of major shunt occlusion by a balloon catheter and endoscopic injection sclerotherapy. Since SO-EIS can be performed regardless of the IGVs' anatomical configuration, it may be a promising alternative treatment for IGVs refractory to BRTO.

Key words: isolated gastric varices, shunt-occluded endoscopic injection sclerotherapy (SO-EIS), balloon-occluded retrograde transvenous obliteration (BRTO)

(Intern Med 56: 1041-1048, 2017)

(DOI: 10.2169/internalmedicine.56.7761)

Introduction

Portal hypertension is a major complication of liver cirrhosis and results in the development of esophagogastric varices. The prevalence of isolated gastric varices (IGVs) is lower than the prevalence of esophageal varices (1, 2). Hemorrhaging from esophagogastric varices remains a major cause of morbidity and mortality in patients with portal hypertension (3), and rupture of IGVs is associated with an increased mortality rate (45-50%).

Balloon-occluded retrograde transvenous obliteration (BRTO) is the primary treatment for IGVs in Japan (4-9). However, despite the efficacy and low recurrence rate of BRTO, it is difficult to perform for some IGVs, especially those with many small collateral veins. Further complicating matters is the lack of an optimal secondary treatment for

IGVs refractory to BRTO. One proposed alternative treatment is shunt-occluded endoscopic injection sclerotherapy (SO-EIS) (10-14), which is a combination therapy of major shunt occlusion by a balloon catheter and endoscopic injection sclerotherapy. However, the efficacy and safety of SO-EIS for IGVs refractory to BRTO are unclear.

We herein report a rare case of IGVs refractory to BRTO successfully treated by SO-EIS.

Case Report

A 64-year-old man with hepatitis C cirrhosis was admitted for the prophylactic treatment of IGVs. He had a history of interferon and ribavirin therapy after partial splenic embolization (PSE) at 61 years of age, but he had not achieved a sustained virological response (SVR). He also had a history of hepatocellular carcinoma (HCC) treated by partial

¹Department of Internal Medicine, Isesaki Municipal Hospital, Japan, ²Department of Gastroenterology, Takasaki General Medical Center, National Hospital Organization, Japan, ³Department of Medicine and Molecular Sciences, Gunma University Graduate School of Medicine, Japan, ⁴Department of Internal Medicine, Sanshikai Kusunoki Hospital, Japan, ⁵Department of Gastroenterology, Maebashi Red Cross Hospital, Japan and ⁶Department of Internal Medicine, Katakai Clinic, Japan

Received for publication May 25, 2016; Accepted for publication September 8, 2016

Correspondence to Dr. Takeshi Hatanaka, hatanaka@qk9.so-net.ne.jp

Table. The Laboratory Data on Admission.

<Hematology>		Alb	3.9 g/dL
WBC	4,400 / μ L	BUN	18 mg/dL
RBC	508×10^4 / μ L	Cr	0.8 mg/dL
Hemoglobin	13.9 g/dL	Na	138 mEq/L
Platelet	10×10^4 / μ L	K	3.7 mEq/L
<Coagulation>		Cl	105 mEq/L
PT	88 %	Blood glucose	177 mg/dL
<Biochemistry>		CRP	0.25 mg/dL
T.bil	0.99 mg/dL	<Immunology>	
AST	73 IU/L	AFP	8 ng/mL
ALT	50 IU/L	PIVKA-II	15 mAU/mL
LDH	193 IU/L	<Viral markers>	
ALP	391 IU/L	HBs-Ag	Negative
γ -GTP	43 IU/L	HCV-Ab	Positive
TP	7.5 g/dL		

hepatic resection at 63 years of age, and no recurrence of HCC had been observed. The laboratory data on admission (Table) were as follows: erythrocyte count of $508 \times 10^4/\text{mm}^3$, hemoglobin level of 13.9 g/dL, a decreased platelet count of $10.0 \times 10^4/\text{mm}^3$, total bilirubin of 0.99 mg/dL, elevated levels of aspartate aminotransferase (AST) at 73 IU/L, elevated levels of alanine aminotransferase (ALT) at 50 IU/L, elevated levels of alkaline phosphatase (ALP) at 391 IU/L, gamma-glutamyltransferase (γ -GTP) of 43 IU/L, total protein of 7.5 g/dL, serum albumin of 3.9 g/dL, blood urea nitrogen of 18 mg/dL, and creatinine of 0.8 mg/dL; the findings for hepatitis B surface antigens were negative, as were those for alpha-fetoprotein and des- γ -carboxy-prothrombin (DCP). Hepatitis C virus antibodies were positive. Since he had no history of hepatic ascites or hepatic encephalopathy, his hepatic function was Child-Pugh class A score 5.

Esophagogastroduodenoscopy (EGD) showed the IGVs to be white, large, and located in the cardia and fundus (Fig. 1a). Dynamic computed tomography (CT) also showed that the IGVs were in the cardia and fundus, with the left renal vein suspected to be their efferent vein (Fig. 1b and c).

To assess the hemodynamics of the IGVs, we performed arterial angiography and balloon-occluded retrograde transvenous varicerography (BRTV) as follows: First, we inserted a 3.5-Fr YASHIRO type catheter (Terumo Clinical Supply, Tokyo, Japan). The portal phase of superior mesenteric angiography showed that the portal flow was hepatopetal, and the IGVs were not visualized (Fig. 2a). We performed CT of splenic arterial portography to evaluate the precise hemodynamic of IGVs and found that the afferent vein was the short gastric vein and the efferent veins were the inferior phrenic vein, pericardiophrenic vein, para-esophageal vein, and left renal vein, which was the main drainage route of the IGVs (Fig. 2b-e). We then punctured the right femoral vein and introduced a 6.5-Fr balloon catheter with a 19-mm diameter (Create Medic, Yokohama, Japan). We advanced it to the left renal shunt and inflated the balloon to occlude the end of the efferent vein. BRTV showed that the IGVs were

not opacified because the inferior phrenic vein was working as a collateral vein (Fig. 3). We evaluated them as grade 4 according to the Hirota classification (15).

Twenty-one days after arterial angiography and BRTV, we tried to perform BRTO. We punctured the right internal jugular vein and introduced an 8-Fr balloon catheter with a 20-mm diameter (Terumo Clinical Supply). We advanced it to the left renal vein and occluded the end of the efferent vein (Fig. 4a). We performed BRTV and advanced the microcatheter to occlude the inferior phrenic vein, but we were unable to access the inferior phrenic vein. We then tried to cannulate the inferior phrenic vein from the inferior vena cava (IVC). We injected contrast medium via the balloon catheter and performed CT to determine where the end of the inferior phrenic vein was located. Although we used various types of catheter, such as Cobra, Multipurpose, and Michaelson types, we were unable to cannulate due to indentation (Fig. 4b and c). We concluded that BRTO for the IGVs was difficult because we were unable to occlude the collateral veins. We therefore decided to perform SO-EIS instead.

First, we occluded the outlet of the left renal shunt with an 8-Fr balloon catheter with a 20-mm diameter (Terumo Clinical Supply). We administered 4,000 units of haptoglobin (Japan Blood Products Organization, Tokyo, Japan) intravenously just before treatment to prevent renal damage induced by hemolysis due to ethanolamine oleate (EOI) (Oldamin; ASKA Pharmaceutical, Tokyo, Japan). We mixed 10 mL of 10% EOI with an equal volume of contrast medium, resulting in 20 mL of a 5% EOI mixture. We inserted the endoscope into the stomach and then directly punctured the IGVs using the endoscope. We attempted to opacify not only the IGVs themselves but also the left gastric vein by EOI. We first punctured the IGVs and injected 5 mL of 5% EOI. Although the inferior phrenic vein was opacified, the IGVs themselves and the left gastric vein were not confirmed initially. Because an additional injection of EOI might have resulted in inflow to the systemic circulation, we

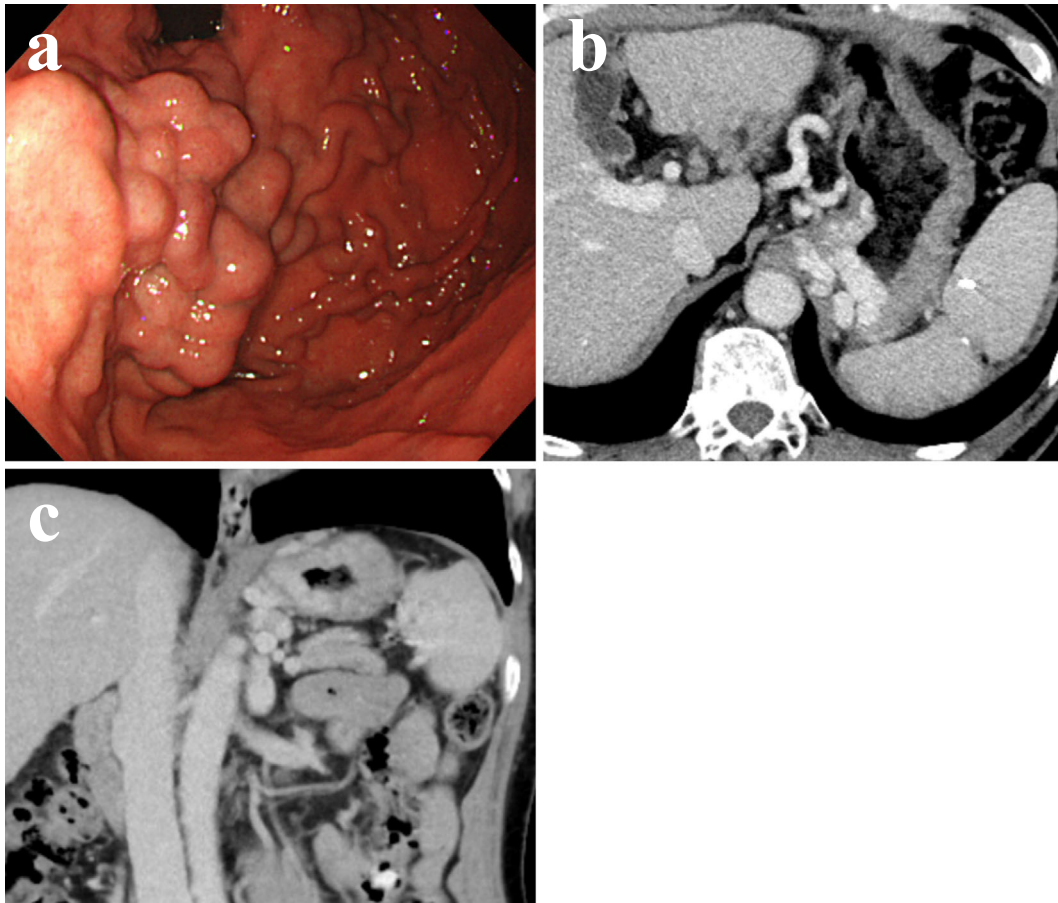


Figure 1. (a) Esophagogastroduodenoscopy (EGD) showed that the isolated gastric varices (IGVs) were white, large, and located in the cardia and fundus. (b, c) Dynamic computed tomography (CT) also showed that IGVs were in the cardia and fundus, suggesting that the left renal vein was the efferent vein.

stopped the injection of EOI and instead injected a mixture of 0.5 mL of cyanoacrylate and 0.3 mL of lipiodol to prevent bleeding from the puncture site (Fig. 5a and b). We then re-punctured the IGVs and injected 10 mL of 5% EOI. This time, the IGVs and left gastric vein were also successfully opacified, so we again injected the mixture of 0.5 mL of cyanoacrylate and 0.3 mL of lipiodol to prevent bleeding (Fig. 5c-e).

No complications were observed. One week after SO-EIS, EGD and enhanced CT showed complete thrombosis of the IGVs and afferent vein (Fig. 6a-c). Three months after SO-EIS, EGD showed that the IGVs had shrunk markedly (Fig. 6d). Fifteen months after SO-EIS, no episodes of bleeding from the gastric varices were observed. Enhanced CT showed that there were deposits of cyanoacrylate in the gastric wall, and we were unable to identify any recurrence of IGVs (Fig. 6e). The inferior phrenic vein, paraesophageal vein, and left renal shunt were also enhanced, indicating that they had been preserved as the collateral veins (Fig. 6f and g).

Discussion

SO-EIS is a treatment for IGVs using endoscopic injec-

tion sclerotherapy (EIS) after temporary major shunt occlusion by a balloon catheter to cause stagnation of the blood flow (10-14). A previous study reported that the technical success rate was 90-100%, with no serious complications observed, although the number of cases in whom this procedure had been performed were limited. One advantage of SO-EIS over BRTO is that SO-EIS achieves thrombosis of the IGVs themselves and the afferent veins without occlusion of the major shunt, resulting in no increase in the pressure of the portal vein. Preserving the major shunt after SO-EIS may be attributed to the avoidance of exacerbation of esophageal varices and appearance of ascites (11). Another advantage of SO-EIS is that this procedure can be used to treat all IGVs, regardless of their anatomical configuration, even those which cannot be treated by BRTO for anatomical reasons such as the presence of many small collateral veins. However, this technique has drawbacks in terms of requiring more medical personnel for catheter intervention and endoscopy and the need to puncture the GVs directly, which may cause bleeding from the IGVs.

To date, in Asian countries such as Japan, BRTO is the established standard treatment for IGVs (4-9), although it is not described in the American Association for the Study of Liver Diseases (AASLD) practice guidelines (16). The tech-

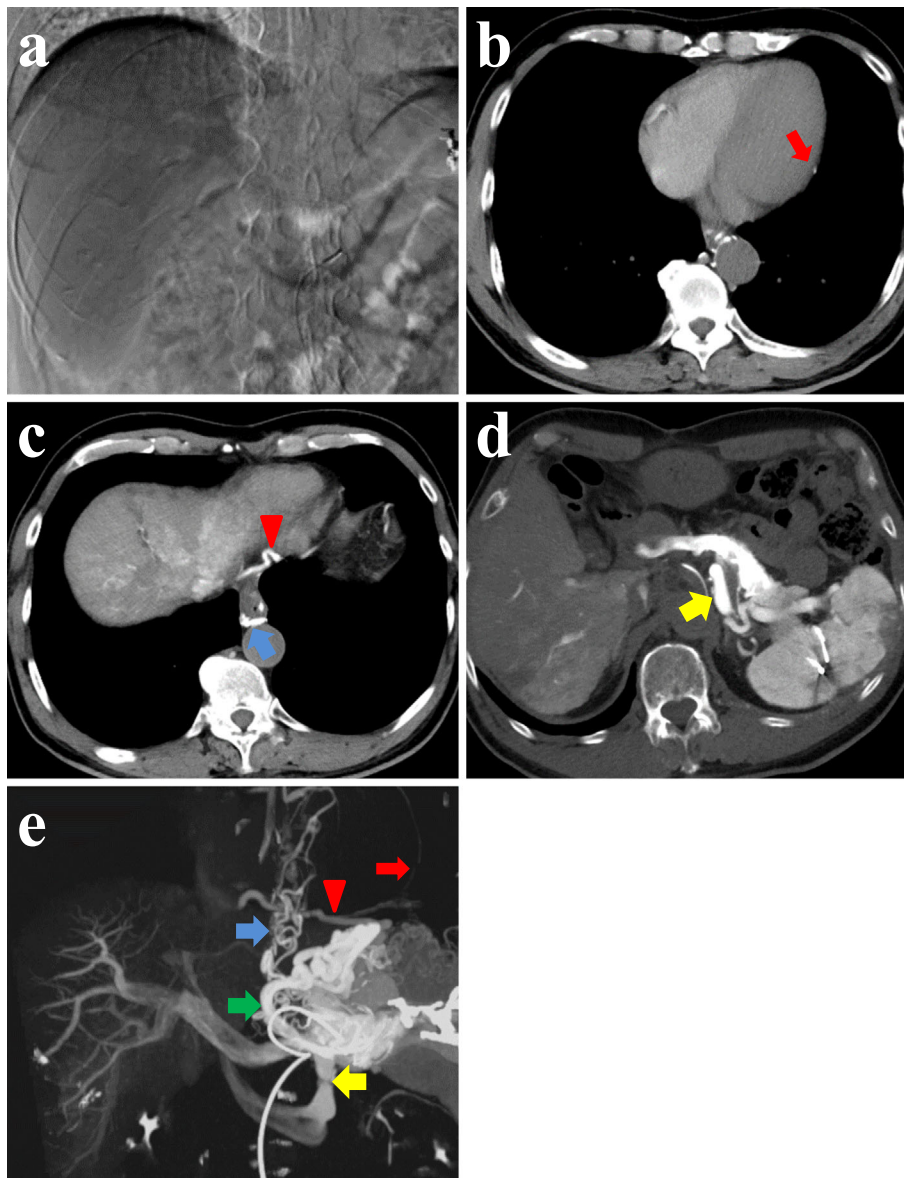


Figure 2. The portal phase of superior mesenteric angiography showed that portal flow was hepatopetal, and the IGVs were not visualized (a). CT of splenic arterial portography showed that the efferent veins were the pericardiophrenic vein (red arrow) (b), inferior phrenic vein (red triangle), para-esophageal vein (blue arrow) (c), and left renal vein (yellow arrow), which was the main drainage route afferent vein (d). CT also showed that the short gastric vein (green arrow) was the afferent vein (e).

nical success rate and mortality rate of BRTO range from 76.9-100% (4-9, 17-19) and 0-4.1% (4-8, 17), respectively. The rate of rebleeding from IGVs after BRTO treatment ranged from 1.3-2.4% in several previous studies (5, 18, 19), and the 1-, 3-, and 5-year survival rates after BRTO ranged from 83.1-96.5%, 65.7-96.5%, and 54.0-81.7%, respectively (5-7, 17, 20).

In the US, a transjugular intrahepatic portosystemic shunt (TIPS) is used to treat many complications related to portal hypertension, such as refractory ascites and variceal bleeding (21). According to the AASLD guidelines (16, 22), although a TIPS should be considered for patients with uncontrolled bleeding from gastric varices or with rebleeding from gastric varices despite combined pharmacological and

endoscopic therapy, it is contraindicated for patients with gastric varices which have never bled, as in the present case.

In our case, we adequately evaluated the hemodynamics of IGV by CT of splenic arterial portography and tried to perform BRTO as a first-line treatment. Unfortunately, we were unable to cannulate the left inferior phrenic vein or occlude the collateral veins and were therefore forced to give up on BRTO. At present, no standard secondary treatment strategy has yet been established.

One suggested secondary treatment for IGVs is balloon-occluded antegrade transvenous obliteration (BATO), commonly referred to in the Japanese literature as percutaneous transhepatic obliteration (PTO), either alone or combined with BRTO therapy. The technical success rate of PTO

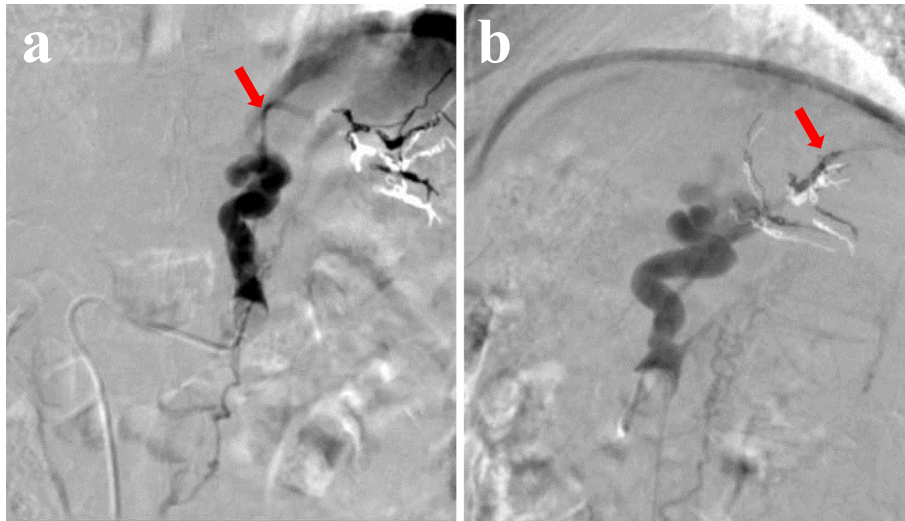


Figure 3. Balloon-occluded retrograde transvenous varicography (BRTV) showed that the IGVs were not opacified because the inferior phrenic veins (red arrow) worked as collateral veins. (a) Frontal view, (b) lateral view.

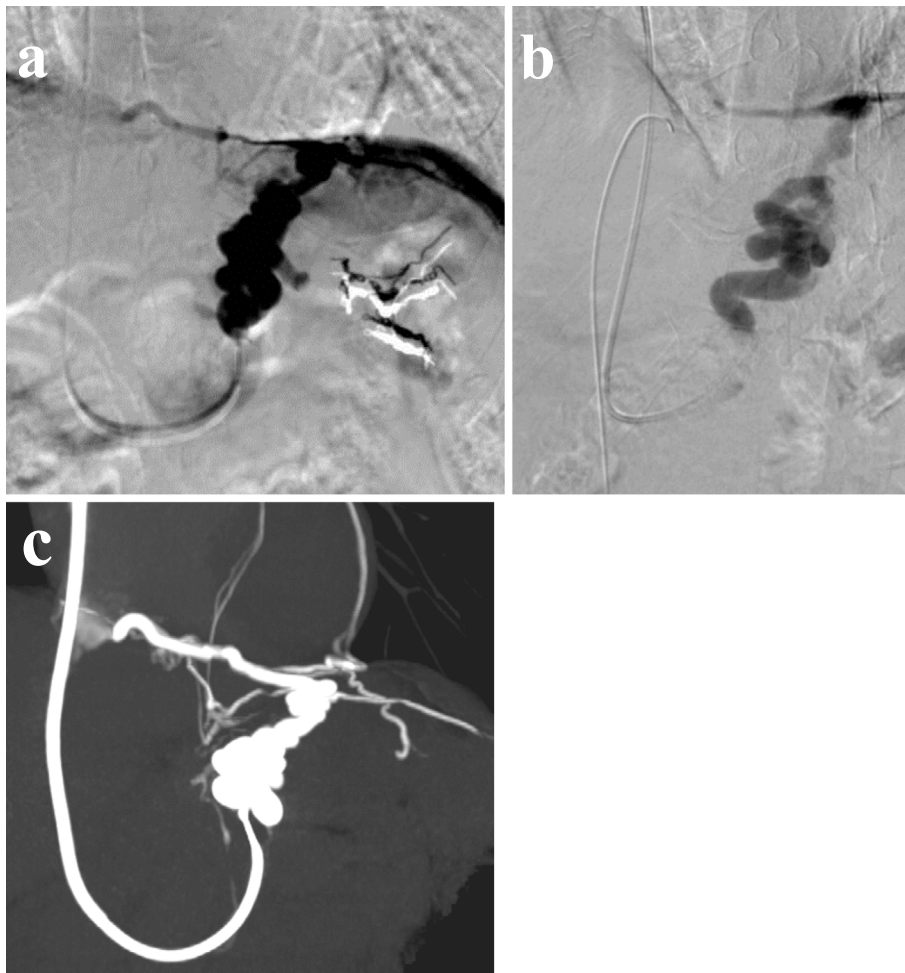


Figure 4. We punctured the right internal jugular vein and introduced an 8-Fr balloon catheter with a 20-mm diameter. We advanced it to the left renal vein and occluded the end of the efferent vein (a). We then tried to cannulate the inferior phrenic vein from the inferior vena cava (IVC). We injected contrast medium via the balloon catheter and performed CT to determine where the end of the inferior phrenic vein was located (b, c). Although we used various types of catheter, such as Cobra, Multipurpose, and Michaelson types, we were unable to cannulate due to indentation.

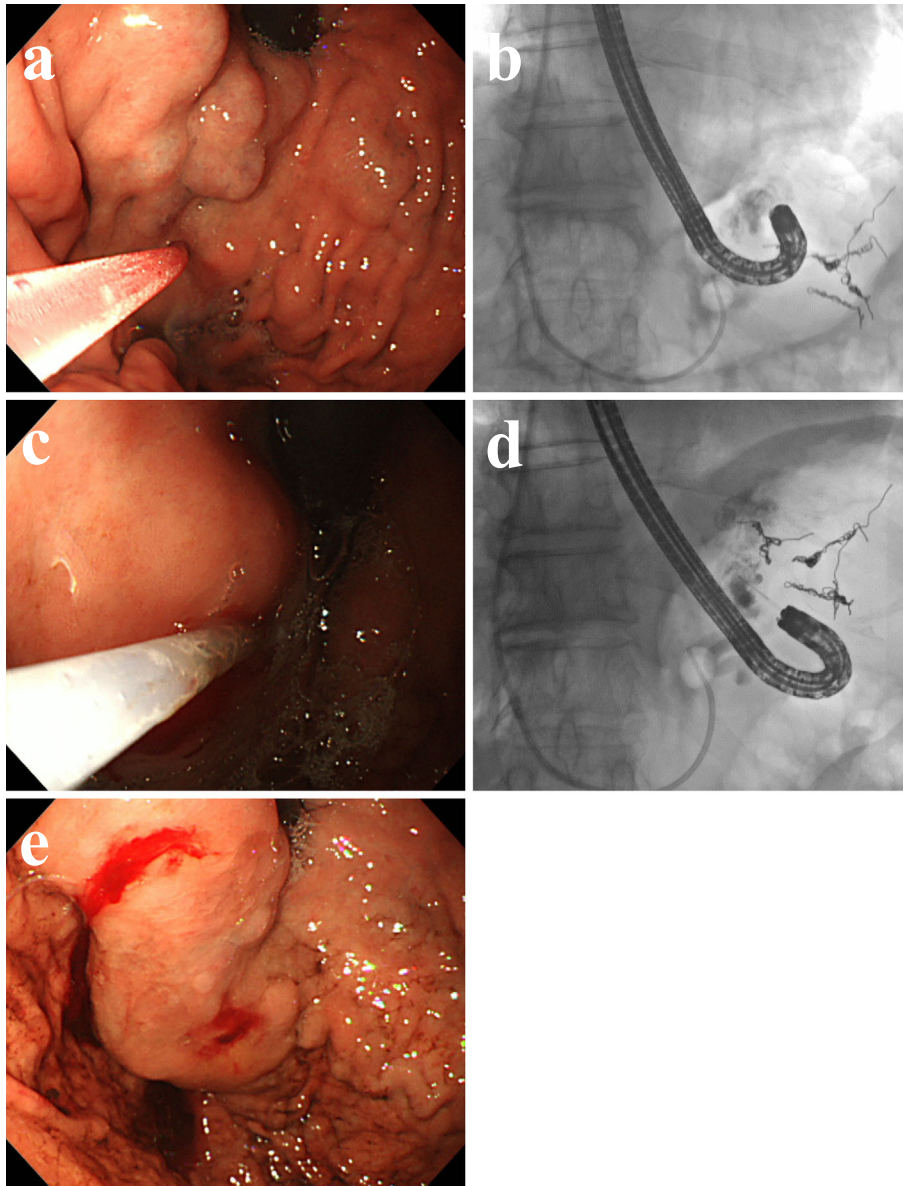


Figure 5. Shunt-occluded endoscopic injection sclerotherapy (SO-EIS) procedure. (a, b) First puncture. (c, d) Second puncture. (e) Just after the treatment.

alone has been reported to range from 44-100% in previous studies (6, 19, 23), which is lower than that of BRTO. Furthermore, the technical success rate of PTO combined with BRTO is 100%, which is better efficacy in the short term (6), but the number of cases is small, and the complication rate, rate of recurrence of IGVs, and overall survival have not yet been fully clarified. As such, further investigations are needed.

The other secondary treatment is endoscopic cyanoacrylate injection, which is an established treatment for patients with emergency bleeding from gastric varices (16). The rate of rebleeding with endoscopic cyanoacrylate injection is significantly higher than that of rebleeding treated with BRTO in the long term (18). Cyanoacrylate, which polymerizes almost instantly on contact with blood, causes rapid hemostasis. Cyanoacrylate must therefore be injected rapidly before it polymerizes in the injection needle. D'Imperio et al. reported that undiluted

cyanoacrylate caused the injection needle to become stuck in the newly formed polymer, and fatal hemorrhaging occurred due to forced needle extraction (24). As such, a mixture of cyanoacrylate and lipiodol is now widely used to prevent the tissue adhesive from hardening too rapidly (18, 25, 26). It has also allowed for radiographic monitoring while preventing the migration of cyanoacrylate into the systemic circulation and leakage into the extravascular areas. In addition, cyanoacrylate injection also carries a risk of pulmonary embolization, multiple systemic embolization such as splenic infarction, and cerebral infarction, all of which rarely occur but can be fatal (27-30). Such complications may be related to major shunt or porto-pulmonary venous anastomosis (PPVA) (31, 32), which flow into the pulmonary vein.

We chose SO-EIS as a second-line treatment in the present case for two reasons. First, SO-EIS does not seem to increase the portal pressure, helping prevent the deterioration of the esophageal varices and the occurrence of ascites. A

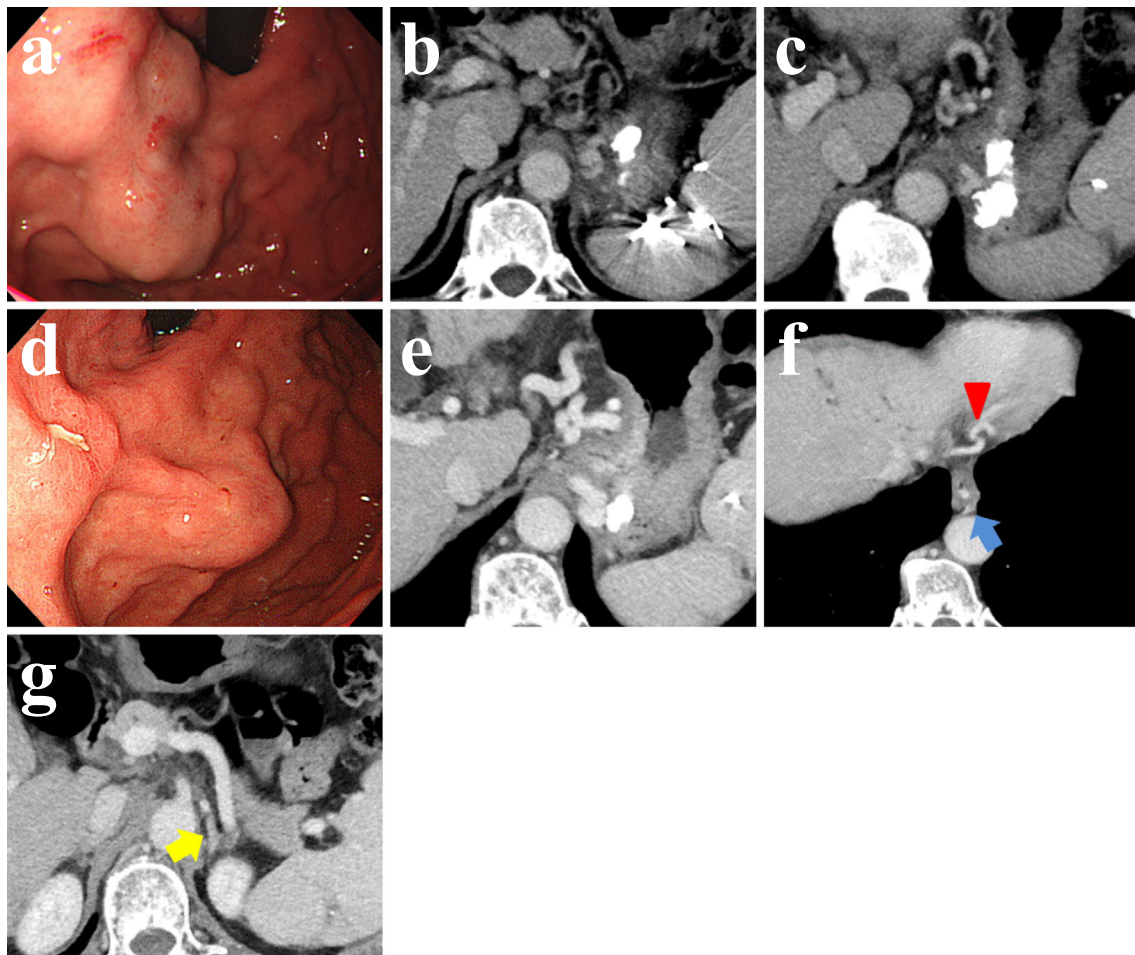


Figure 6. One week after shunt-occluded endoscopic injection sclerotherapy (SO-EIS), esophago-gastroduodenoscopy (EGD) and enhanced computed tomography (CT) showed complete thrombosis of the isolated gastric varices (IGVs) and afferent vein (a-c). Three months after SO-EIS, EGD showed that the IGVs had shrunk (d).

previous study reported that the rate of deterioration of the esophageal varices after SO-EIS is lower than after BRTO (11). By forming thromboses of the IGVs themselves and the efferent vein and preserving the flow of the afferent vein, SO-EIS helps preserve the portosystemic shunt and inhibits any increase in the portal pressure. For this reason, we did not perform PTO+BRTO combination therapy, which is a variant of BRTO and increases the portal pressure. The second reason we chose SO-EIS was that we did not notice a porto-systemic shunt, including PPVA, on CT of splenic arterial portography. A porto-systemic shunt is thought to be related to systemic embolic complications when endoscopic cyanoacrylate injection is performed. After evaluating the precise hemodynamics of IGVs by CT of splenic arterial portography, we concluded that we could safely perform SO-EIS in the present patient.

In the present case, we punctured the IGVs and injected EOI a second time. We attempted to opacify not only the IGVs themselves but also the left gastric vein by EOI. It is best to fill up the IGVs and the left gastric vein in a single procedure. However, we were alert to the risk of inflow of EOI into the systemic circulation. Injecting a large amount of EOI at once without confirmation of the whole status of

the IGVs can cause complications due to the inflow of EOI into the systemic circulation. As a result, we stopped the first injection at 5 mL of 5% EOI because we could not confirm the whole status of the IGVs. We then re-punctured and confirmed the whole status. Finally, we successfully injected 10 mL of 5% EOI until the IGVs and left gastric vein were also opacified.

One advantage of SO-EIS over BRTO is the preservation of drainage routes such as the inferior phrenic vein and pericardiacophrenic vein. As a result, the risks of esophageal varices recurrence and ascites were decreased. We therefore did not occlude the drainage routes, including the inferior phrenic vein and pericardiacophrenic vein, in this case. Enhanced CT at 15 months after SO-EIS showed that the inferior phrenic vein, para-esophageal vein, and left renal shunt were also enhanced, indicating that they had been preserved as collateral veins. There was no recurrence of esophageal varices or ascites.

In conclusion, SO-EIS may be an alternative treatment for IGVs refractory to BRTO. However, it is important to assess the hemodynamics of IGVs before performing SO-EIS treatment.

The authors state that they have no Conflict of Interest (COI).

References

- Watanabe K, Kimura K, Matsutani S, Ohto M, Okuda K. Portal hemodynamics in patients with gastric varices. A study in 230 patients with esophageal and/or gastric varices using portal vein catheterization. *Gastroenterology* **95**: 434-440, 1988.
- Sarin SK, Lahoti D, Saxena SP, Murthy NS, Makwana UK. Prevalence, classification and natural history of gastric varices: a long-term follow-up study in 568 portal hypertension patients. *Hepatology (Baltimore, Md)* **16**: 1343-1349, 1992.
- Garcia-Tsao G, Bosch J. Management of varices and variceal hemorrhage in cirrhosis. *N Engl J Med* **362**: 823-832, 2010.
- Kanagawa H, Mima S, Kouyama H, Gotoh K, Uchida T, Okuda K. Treatment of gastric fundal varices by balloon-occluded retrograde transvenous obliteration. *J Gastroenterol Hepatol* **11**: 51-58, 1996.
- Akahoshi T, Hashizume M, Tomikawa M, et al. Long-term results of balloon-occluded retrograde transvenous obliteration for gastric variceal bleeding and risky gastric varices: a 10-year experience. *J Gastroenterol Hepatol* **23**: 1702-1709, 2008.
- Arai H, Abe T, Takagi H, Mori M. Efficacy of balloon-occluded retrograde transvenous obliteration, percutaneous transhepatic obliteration and combined techniques for the management of gastric fundal varices. *World J Gastroenterol* **12**: 3866-3873, 2006.
- Arai H, Abe T, Shimoda R, Takagi H, Yamada T, Mori M. Emergency balloon-occluded retrograde transvenous obliteration for gastric varices. *J Gastroenterol* **40**: 964-971, 2005.
- Kitamoto M, Imamura M, Kamada K, et al. Balloon-occluded retrograde transvenous obliteration of gastric fundal varices with hemorrhage. *AJR Am J Roentgenol* **178**: 1167-1174, 2002.
- Fukuda T, Hirota S, Sugimura K. Long-term results of balloon-occluded retrograde transvenous obliteration for the treatment of gastric varices and hepatic encephalopathy. *J Vasc Interv Radiol* **12**: 327-336, 2001.
- Matsumoto A, Hamamoto N, Kayazawa M. Balloon endoscopic sclerotherapy, a novel treatment for high-risk gastric fundal varices: a pilot study. *Gastroenterology* **117**: 515-516, 1999.
- Shiba M, Higuchi K, Nakamura K, et al. Efficacy and safety of balloon-occluded endoscopic injection sclerotherapy as a prophylactic treatment for high-risk gastric fundal varices: a prospective, randomized, comparative clinical trial. *Gastrointest Endosc* **56**: 522-528, 2002.
- Hamamoto N, Matsumoto A, Nomura T, et al. Treatment of gastric fundal varices by balloon endoscopic sclerotherapy. *Gastrointest Endosc* **49**: 115-118, 1999.
- Shiba M, Higuchi K, Nakamura K, et al. A case of huge gastric varices successfully treated with endoscopic injection sclerotherapy with occlusion of both supplying and draining veins with balloons. *Gastrointest Endosc* **52**: 104-107, 2000.
- Sato W, Kamada K, Goto T, et al. Efficacy of combined balloon-occluded retrograde transvenous obliteration and simultaneous endoscopic injection sclerotherapy. *Intern Med* **54**: 261-265, 2015.
- Hirota S, Matsumoto S, Tomita M, Sako M, Kono M. Retrograde transvenous obliteration of gastric varices. *Radiology* **211**: 349-356, 1999.
- Garcia-Tsao G, Sanyal AJ, Grace ND, Carey W. Prevention and management of gastroesophageal varices and variceal hemorrhage in cirrhosis. *Hepatology (Baltimore, Md)* **46**: 922-938, 2007.
- Cho SK, Shin SW, Lee IH, et al. Balloon-occluded retrograde transvenous obliteration of gastric varices: outcomes and complications in 49 patients. *AJR Am J Roentgenol* **189**: W365-W372, 2007.
- Hong CH, Kim HJ, Park JH, et al. Treatment of patients with gastric variceal hemorrhage: endoscopic N-butyl-2-cyanoacrylate injection versus balloon-occluded retrograde transvenous obliteration. *J Gastroenterol Hepatol* **24**: 372-378, 2009.
- Ninoi T, Nakamura K, Kaminou T, et al. TIPS versus transcatheter sclerotherapy for gastric varices. *AJR Am J Roentgenol* **183**: 369-376, 2004.
- Ninoi T, Nishida N, Kaminou T, et al. Balloon-occluded retrograde transvenous obliteration of gastric varices with gastrosplenic shunt: long-term follow-up in 78 patients. *AJR Am J Roentgenol* **184**: 1340-1346, 2005.
- Pomier-Layrargues G, Bouchard L, Lafortune M, Bissonnette J, Guerette D, Perreault P. The transjugular intrahepatic portosystemic shunt in the treatment of portal hypertension: current status. *Int J Hepatol* **2012**: 167868, 2012.
- Boyer TD, Haskal ZJ. The role of transjugular intrahepatic portosystemic shunt in the management of portal hypertension. *Hepatology (Baltimore, Md)* **41**: 386-400, 2005.
- Araki T, Hori M, Motosugi U, et al. Can balloon-occluded retrograde transvenous obliteration be performed for gastric varices without gastrosplenic shunts? *J Vasc Interv Radiol* **21**: 663-670, 2010.
- D'Imperio N, Piemontese A, Baroncini D, et al. Evaluation of undiluted N-butyl-2-cyanoacrylate in the endoscopic treatment of upper gastrointestinal tract varices. *Endoscopy* **28**: 239-243, 1996.
- Huang YH, Yeh HZ, Chen GH, et al. Endoscopic treatment of bleeding gastric varices by N-butyl-2-cyanoacrylate (Histoacryl) injection: long-term efficacy and safety. *Gastrointest Endosc* **52**: 160-167, 2000.
- Kang EJ, Jeong SW, Jang JY, et al. Long-term result of endoscopic Histoacryl (N-butyl-2-cyanoacrylate) injection for treatment of gastric varices. *World J Gastroenterol* **17**: 1494-1500, 2011.
- Turler A, Wolff M, Dorlars D, Hirner A. Embolic and septic complications after sclerotherapy of fundic varices with cyanoacrylate. *Gastrointest Endosc* **53**: 228-230, 2001.
- Tan YM, Goh KL, Kamarulzaman A, et al. Multiple systemic embolisms with septicemia after gastric variceal obliteration with cyanoacrylate. *Gastrointest Endosc* **55**: 276-278, 2002.
- Saracco G, Giordanino C, Roberto N, et al. Fatal multiple systemic embolisms after injection of cyanoacrylate in bleeding gastric varices of a patient who was noncirrhotic but with idiopathic portal hypertension. *Gastrointest Endosc* **65**: 345-347, 2007.
- Sato T, Yamazaki K. Evaluation of therapeutic effects and serious complications following endoscopic obliteration therapy with Histoacryl. *Clin Exp Gastroenterol* **3**: 91-95, 2010.
- Sano A, Nishizawa S, Sasai K, et al. Contrast echocardiography in detection of portopulmonary venous anastomosis. *AJR Am J Roentgenol* **142**: 137-140, 1984.
- Ellman BA, Curry TS 3rd, Glotzbach RE, Simpson PR. Systemic embolization as a complication of transhepatic venography. *Radiology* **141**: 67-71, 1981.

The Internal Medicine is an Open Access article distributed under the Creative Commons Attribution-NonCommercial-NoDerivatives 4.0 International License. To view the details of this license, please visit (<https://creativecommons.org/licenses/by-nc-nd/4.0/>).