

Morton Neuroma: Evaluated with Ultrasonography and MR Imaging

Mi-Jung Lee, MD¹
Sungjun Kim, MD^{1,2}
Yong-Min Huh, MD¹
Ho-Taek Song, MD¹
Sung-Ah Lee, MD³
Jin Woo Lee, MD⁴
Jin-Suck Suh, MD¹

Index terms:

Neuroma
Foot, MR
Nervous system, US

Korean J Radiol 2007; 8: 148-155

Received October 19, 2005; accepted after revision February 9, 2006.

¹Department of Diagnostic Radiology and the Research Institute of Radiological Science, Yonsei University College of Medicine, Seoul 120-752, Korea;

²Department of Diagnostic Radiology, Hanyang University College of Medicine, Kuri City, Kyunggi-do 426-791, Korea;

³Department of Diagnostic Radiology, Seoul Medical Center, Seoul 135-090, Korea; ⁴Department of Orthopedics, Yonsei University College of Medicine, Seoul 120-752, Korea

Address reprint requests to:

Jin-Suck Suh, MD, Department of Diagnostic Radiology and the Research Institute of Radiological Science, Yonsei University College of Medicine, 134 Sincheon-dong, Seodaemun-gu, Seoul 120-752, Korea.
Tel. (822) 2228-7400
Fax. (822) 393-3035
e-mail: jss@yumc.yonsei.ac.kr

Objective: The purpose of this study was to compare the diagnostic accuracy of both ultrasonography (US) and magnetic resonance imaging (MRI) for the assessment of Morton neuroma.

Materials and Methods: Our study group was comprised of 20 neuromas from 17 patients, and the neuromas were confirmed on surgery following evaluation with US, MRI, or both US and MRI. The diagnostic criterion for Morton neuroma, as examined by US, was the presence of a round or ovoid, well-defined, hypoechoic mass. The diagnostic criterion, based on MR imaging, was a well defined mass with intermediate to low signal intensity on both the T1- and T2-weighted images. The retrospective comparison between the sonographic and MR images was done by two experienced radiologists working in consensus with the surgical and pathologic correlations.

Results: The detection rate of Morton neuroma was 79% for 14 neuromas from 11 patients who had undergone US followed by an operation. The detection rate was 76% for 17 neuromas from 15 patients who had undergone MRI and a subsequent operation. The mean size of the examined neuromas was 4.9 mm on the US images and it was 5.1 mm on the MRI studies. Ten neuromas (71%) were 5 mm or less as measured by US, and three neuromas were not detected, whereas on the MRI analysis, 10 neuromas (59%) were 5 mm or less and four neuromas were not visualized. Among the patients examined during postoperative follow-up, symptoms were completely relieved in 85% and the symptoms were partially relieved in 15%.

Conclusion: US and MR imaging are comparable modalities with high detection rate for the evaluation of Morton neuroma.

Morton neuroma is a nonneoplastic condition characterized by neural degeneration and perineural fibrosis of the plantar nerve (1). This condition is a common cause of forefoot pain, especially in middle-aged women who frequently wear fashionable, high-heeled shoes that are not designed for the normal physiology of the foot (2). Previous studies have reported the prevalence of Morton neuroma to be about 30–33% (3, 4). Most neuromas are located in the second or third intermetatarsal space and they produce symptoms when they have reached a diameter of at least 5 mm (3–6).

Prior to surgical removal, the exact localization as well as the accurate diagnosis of Morton neuroma is prerequisite. Although clinical assessment can be accurate for the diagnosis of Morton neuroma, magnetic resonance imaging (MRI) and ultrasonography (US) have advantages for determining its localization (7, 8). Zanetti et al. showed that MR imaging has a major effect on the diagnosis and the therapeutic decisions by

orthopedic surgeons when Morton neuroma is suspected because MR imaging helps in determining the location and size of Morton neuroma (8). Both the US and MRI modalities have demonstrated sensitivities of 87–98% for the diagnosis of Morton neuroma (1, 5, 6, 9, 10).

There are few clinical studies that have performed both US and MRI for the assessment of Morton neuroma. In one study (11), neither modality was reported to be beneficial for the detection of Morton neuroma. However, the authors of that study did not fully discuss the drawbacks of the lack of the specificity when surgically confirmed neuromas were exclusively included in the study without a control group. They also stated that the pain caused by the neuroma was not size-dependent, which could be a controversial finding (3–6).

In addition, fat-suppressed T1-weighted imaging after intravenous injection of gadolinium contrast is part of our institute's routine protocol for examining potential Morton neuromas. In our experience with interpreting Morton neuroma, we consider that the use of contrast enhanced T1-weighted imaging is equivocal. To the best of our knowledge, there has been only one published report showing that the contrast-enhanced fat-suppressed image significantly increased lesion conspicuity (12). However, other investigations did not demonstrate any superiority of the contrast enhanced sequence (1, 13).

Hence, the purpose of this study is to evaluate the diagnostic accuracy of US and MRI for detecting Morton neuroma, and to evaluate whether or not the gadolinium contrast enhanced T1-weighted image increases the conspicuity of the lesion.

MATERIALS AND METHODS

Patients

From March 2001 to February 2005, we performed US in 58 patients, MRI in 24 patients, and both MRI and US in 10 patients for a total of 72 patients (63 women and 9 men, age range: 19–70 years, average age: 50 years) who were clinically suspected of having Morton neuroma. By review of the pathologic and surgical reports on the medical records, the final study group of this report was comprised of twenty confirmed Morton neuromas in 17 patients among the 72 patients: 12 neuromas (in 11 patients) were pathologically confirmed by partial neurectomy; the remaining eight neuromas (in 6 patients) were confirmed by gross inspection at the time of surgery, and these were remedied by neurolysis.

Surgical Data and Assessing the Therapeutic Outcome

All the surgery was performed by one experienced

orthopedic surgeon. The surgical decision for surgery was based on the clinical findings and the pre-operative MRI and/or US reports. Therapeutic success was assessed at the post-operative, 2-month follow-up. Patients were asked to access their satisfaction with the operation results according to the system advocated by Johnson et al. (14) as follows: 1) Completely satisfied (essentially pain free, no restrictions in activity and only minor restrictions in footwear), 2) Satisfied with minor reservations (occasional mild pain, minor restrictions in activity and minor restrictions in foot wear), 3) Satisfied with major reservations (mild or moderate pain, moderate restrictions in activity and major restrictions in footwear, but overall improvement), 4) Dissatisfied (no improvement in pain or worse pain, major restrictions in activity and footwear, or worse symptoms).

The grades of the patients' satisfaction and the difference of the grades according to the methods of treatment were analyzed.

Imaging Protocols, Diagnostic Criteria and Analysis of the Imaging Findings

The US evaluation was performed by one of four experienced musculoskeletal radiologists with using 9-MHz linear array transducers (HDI 5000, Advanced Technology Laboratories, Bothell, WA). The US images were obtained from the plantar aspect of the foot in the transverse and longitudinal planes, relative to the metatarsal shafts, with each patient in a sitting position with their feet in slight plantar flexion. The diagnostic criterion for Morton neuroma, as assessed by US, was a well-defined, round or ovoid, hypoechoic (relative to the adjacent muscle) mass located just proximal to the metatarsal heads in the plantar aspect of the intermetatarsal space (5).

All the MR imaging studies were performed on a 1.5-T scanner (Signa Horizon, GE Medical Systems, WI). The patients were examined in the supine position with the foot placed in plantar flexion within a transmit-receive extremity coil. The imaging protocol consisted of a T1-weighted spin-echo sequence (T1WI; TR/TE, 550/9), a fast spin echo (FSE) T2-weighted sequence (T2WI; TR/TE, 4000/96) and a T1-weighted fat-suppressed spin-echo sequence (contrast-enhanced fat-saturated [CEFS] T1WI; TR/TE, 617/12) that was obtained after the intravenous injection of 0.2 ml/kg gadopentetate (Magnevist, Schering, Berlin, Germany). The imaging plane was oblique coronal, and this was perpendicular to the metatarsal bones. The section thickness was 3–5 mm without an intersection gap, the image matrix was 256 × 192 or 256 × 256 and the field of view was 10–14 cm (mostly 12 cm); this resulted in in-plane resolution of 0.220–0.292 mm² (pixel size). The

diagnostic criterion for MR imaging was a well-demarcated ovoid or dumbbell-shaped intermetatarsal mass at the plantar aspect near the metatarsal heads, and the mass had intermediate to low signal intensity on both T1WI and T2WI (1, 15, 16).

The comparison of the US and MR imaging findings was performed retrospectively by a consensus of two experienced radiologists, and then each image was correlated with the surgical and pathologic findings. The size of the lesion was measured as the largest transverse diameter on both US and MRI. The fluid between the metatarsal bones (the inter-metatarsal bursa) was excluded during the measurement of the lesion on MRI. In addition, we compared the T1WI with the CEFS T1WI for lesion conspicuity and for detecting Morton neuroma.

RESULTS

Surgical Data and Assessment of the Therapeutic Outcome

Among the 20 neuromas (in 17 patients), 12 neuromas

(12/20, 60%) were found in the third intermetatarsal space and the other eight neuromas (8/20, 40%) were in the second intermetatarsal space (Table 1) upon operation.

Therapeutic success was assessed at the post-operative 2-month follow-up in 13 patients because four patients who underwent excision were unfortunately lost during follow up. Eleven out of the 13 patients (11/13, 85%) had near complete relief from pain, two (2/13, 15%) had moderate improvement with some remaining pain, and none of the patients became worse. Complete relief or marked improvement of the pain was seen in six patients (6/7, 86%) treated by excision and in five patients (5/6, 83%) treated by neurolysis (Table 1).

General Information and the Result of Imaging Analysis

Among the confirmed 20 Morton neuromas (in 17 patients), US was performed for 14 neuromas (11 patients), MRI was performed for 17 neuromas (15 patients), and both US and MRI were performed for 11 neuromas (9 patients). The typical appearance of Morton

Table 1. US and MRI Findings Correlated with Treatment and the Clinical Outcome

Operation Name	Patient No.	Gender	Age	Operation Site (web space)	US Finding (size, mm)	MRI Finding (size, mm)	Better MR Sequence Visualizing Neuroma	Clinical Outcome
Excision	1	F	56	left 2nd	mass (4)	mass (4)	T1WI	3
	2	F	43	left 3rd	⊙	mass (6)	T1WI	3
	3	F	59	right 3rd	⊙	*	*	FL
	4	F	43	left 3rd	⊙	mass (4)	T1WI	FL
	5	M	19	right 3rd	⊙	mass (5)	ND	2
	6	F	63	right 2nd	mass (5)	⊙	⊙	FL
	7	F	46	left 2nd	mass (4)	mass (5)	ND	FL
	8	F	49	left 3rd	mass (5)	⊙	⊙	4
	9 _τ	F	55	right 3rd	mass (5)	⊙	⊙	4
				left 3rd	mass (5)	mass (5)	ND	
		10	F	46	left 3rd	mass (5)	mass (5)	ND
	11	F	67	left 2nd	mass (4)	mass (4)	ND	4
Neurolysis	12	M	37	left 3rd	⊙	*	*	4
	13 _τ	F	66	right 2nd	mass (9)	mass (8)	ND	3
				right 3rd	*	mass (5)	ND	
	14	F	43	right 2nd	mass (4)	*	*	3
	15	F	31	right 3rd	⊙	mass (7)	ND	4
	16 _τ	F	55	left 2nd	*	mass (5)	ND	3
				left 3rd	mass (4)	*	*	
	17	F	48	right 2nd	*	mass (3)	CE-FS	2

Note. — τ = the patients who underwent operation at 2 sites,

* = not visualized (false negative),

⊙ = not done,

ND = no difference,

clinical outcome : 4, completely satisfied; 3, satisfied with minor reservation; 2, satisfied with major reservation; 1 dissatisfied; FL, follow-up loss.

Imaging Findings of Morton Neuroma

neuroma on the US and MR images is shown in Figure 1. US depicted 11 out of 14 neuromas correctly, but the remaining three neuromas were not detected. Hence, the detection rate of US was 79% (11/14). On the other hand, MRI detected 13 out of 17 neuromas correctly, but the remaining four neuromas were not detected. Hence, the detection rate of MRI for Morton neuroma was 76% (13/17).

Figure 2 shows the true positive and false negative lesions in the patients who underwent both US and MR imaging. US demonstrated a mass in only the third intermetatarsal space, while the MR imaging revealed a mass in only the second intermetatarsal space.

Three patients had false negative results on the US imaging analysis, and four patients had false negative

results on the MRI analysis (Table 1). Among them, five patients underwent neurolysis and only one patient underwent excision. Figure 3 shows the case confirmed by excision and pathologically proven, but it was false negative on MR.

On US, the mean size of the measured neuromas was 4.9 ± 1.45 mm (range: 4–9 mm). On MRI, the mean size of the neuroma was 5.1 ± 1.32 mm (range: 3–8 mm). Most of the neuromas were 5 mm or less (10 of the 14 neuromas [71%] detected on US and 10 of the 17 neuromas [59%] detected on MRI). The maximum difference in size for the same masses measured by US and MR imaging was less than 1 mm.

Of the 13 neuromas depicted by MR imaging, three were visualized only on T1WI, while one was noted only on the

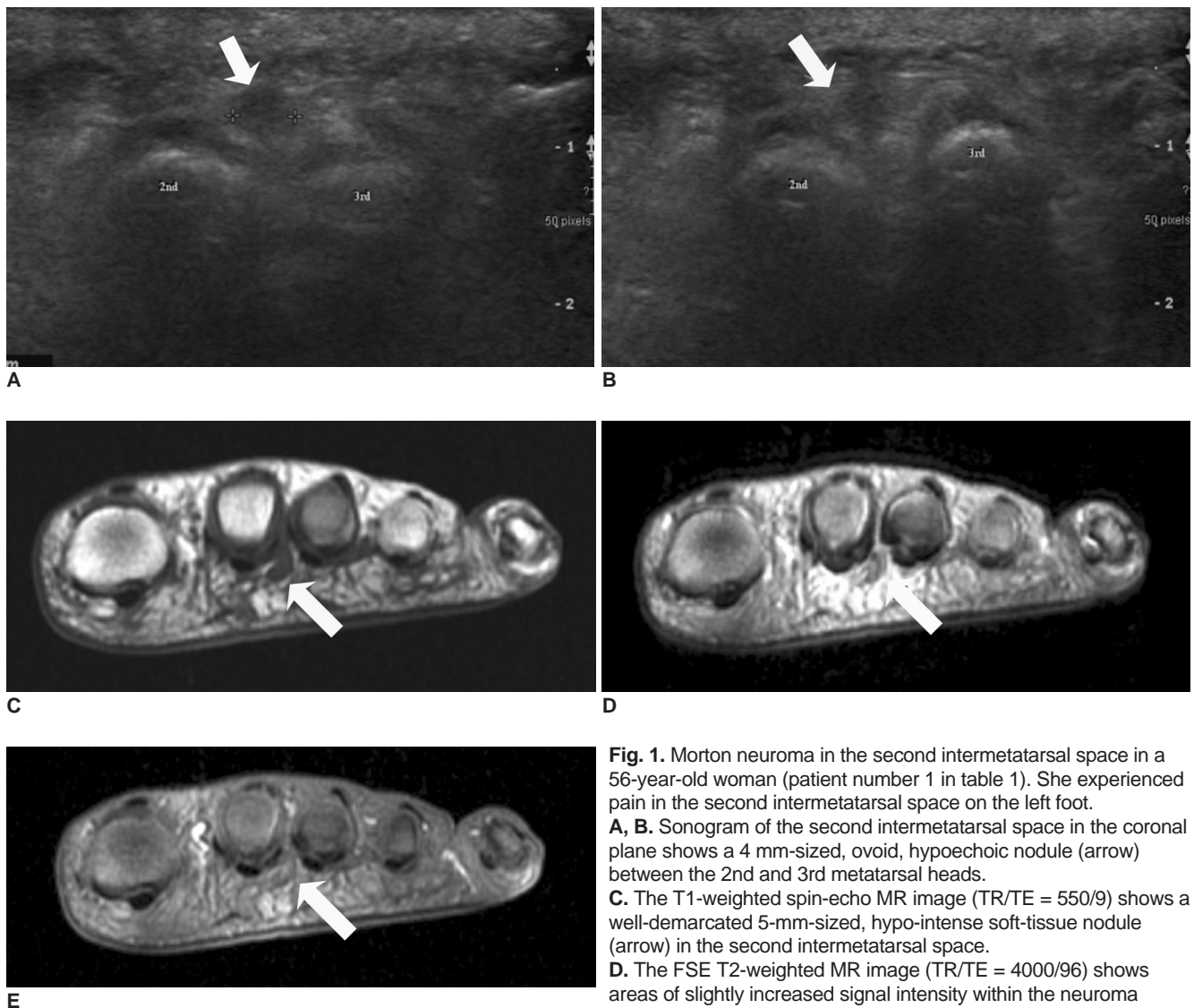


Fig. 1. Morton neuroma in the second intermetatarsal space in a 56-year-old woman (patient number 1 in table 1). She experienced pain in the second intermetatarsal space on the left foot. **A, B.** Sonogram of the second intermetatarsal space in the coronal plane shows a 4 mm-sized, ovoid, hypoechoic nodule (arrow) between the 2nd and 3rd metatarsal heads. **C.** The T1-weighted spin-echo MR image (TR/TE = 550/9) shows a well-demarcated 5-mm-sized, hypo-intense soft-tissue nodule (arrow) in the second intermetatarsal space. **D.** The FSE T2-weighted MR image (TR/TE = 4000/96) shows areas of slightly increased signal intensity within the neuroma (arrow). **E.** The T1-weighted fat-suppressed contrast-enhanced spin-echo MR image (TR/TE = 617/12) shows mild enhancement in the nodule (arrow).

CEFS T1WI. The remaining nine neuromas were detected on both sequences. Accordingly, the neuromas detected on T1WI (12/13, 92%) outnumbered those on the contrast-enhanced images (10/13, 77%) (Table 1).

DISCUSSION

Morton neuroma was first described by Thomas Morton in 1876 as “a peculiar and painful affection of the fourth metatarsophalangeal articulation” (17). However, subsequent studies have shown that the third and second

spaces are the more common sites for neuroma (5). Our study has also demonstrated that the third space is the most common site of involvement.

The exact pathogenesis of Morton neuroma remains controversial. It is generally accepted that the development of Morton neuroma may be induced by repetitive compression of the plantar nerve against the deep transverse intermetatarsal ligament, with subsequent perineural fibrosis (18).

A tentative diagnosis of Morton neuroma can be made at the time of clinical assessment, but imaging correlation is

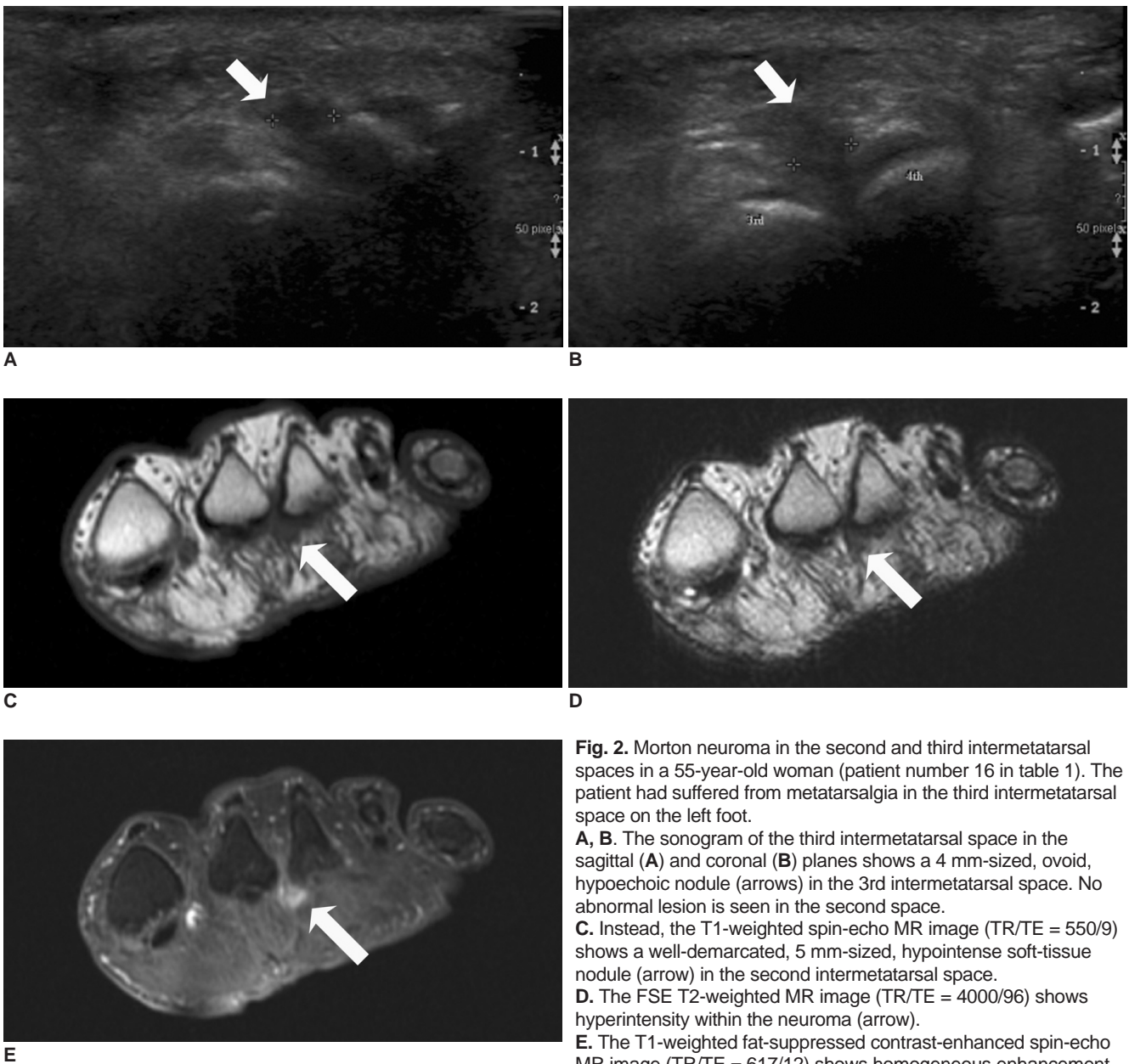


Fig. 2. Morton neuroma in the second and third intermetatarsal spaces in a 55-year-old woman (patient number 16 in table 1). The patient had suffered from metatarsalgia in the third intermetatarsal space on the left foot.
A, B. The sonogram of the third intermetatarsal space in the sagittal (A) and coronal (B) planes shows a 4 mm-sized, ovoid, hypoechoic nodule (arrows) in the 3rd intermetatarsal space. No abnormal lesion is seen in the second space.
C. Instead, the T1-weighted spin-echo MR image (TR/TE = 550/9) shows a well-demarcated, 5 mm-sized, hypointense soft-tissue nodule (arrow) in the second intermetatarsal space.
D. The FSE T2-weighted MR image (TR/TE = 4000/96) shows hyperintensity within the neuroma (arrow).
E. The T1-weighted fat-suppressed contrast-enhanced spin-echo MR image (TR/TE = 617/12) shows homogeneous enhancement of the nodule (arrow). No abnormal finding is seen in the third intermetatarsal space. At operation, both the 2nd and 3rd plantar nerves were thickened and neurolysis was performed on these two nerves. The patient's pain was relieved after the operation.

Imaging Findings of Morton Neuroma

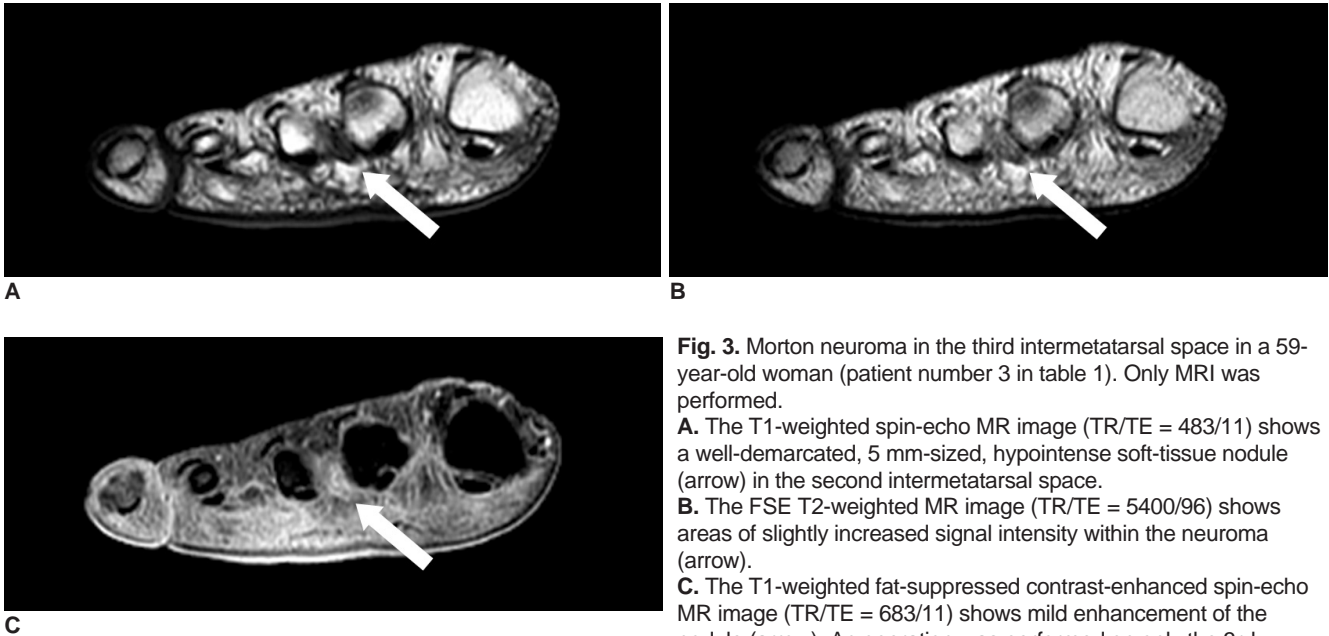


Fig. 3. Morton neuroma in the third intermetatarsal space in a 59-year-old woman (patient number 3 in table 1). Only MRI was performed.
A. The T1-weighted spin-echo MR image (TR/TE = 483/11) shows a well-demarcated, 5 mm-sized, hypointense soft-tissue nodule (arrow) in the second intermetatarsal space.
B. The FSE T2-weighted MR image (TR/TE = 5400/96) shows areas of slightly increased signal intensity within the neuroma (arrow).
C. The T1-weighted fat-suppressed contrast-enhanced spin-echo MR image (TR/TE = 683/11) shows mild enhancement of the nodule (arrow). An operation was performed on only the 3rd intermetatarsal space because of metatarsalgia in this area, and a thick 1-cm-sized neuroma was excised. The second intermetatarsal space was not confirmed as containing neuroma during the operation.

required for the exact localization of neuroma and for the detection of multiple lesions, and especially when the clinical findings are indeterminate. This can prevent patients from undergoing rather avoidable surgical exploration at the wrong sites, which may lead to inadvertent complications (5, 17). In addition, other causes of metatarsalgia can also be excluded via imaging modalities. The possible clinical differential diagnoses that can cause metatarsalgia include intermetatarsal bursitis, stress fractures, necrosis of the sesamoid bones, synovitis of the metatarsophalangeal joint, infection and true neoplasm (3, 8).

Some differential diagnoses should be considered during the imaging analysis. These include intermetatarsal bursitis, ganglion cyst, synovial cyst, giant cell tumor (GCT) of the adjacent tendon sheath, fibromatosis, nodular fasciitis, pigmented villonodular synovitis and physiologic fluid distention of the intermetatarsal bursa when examining by using US and MRI (4, 17). An investigation using US suggested that if a mass in the interdigital space is greater than 20 mm in length, then it is an abnormality other than neuroma such as a ganglion cyst, a synovial cyst or a GCT of the adjacent tendon sheath (17).

Several sonographic study results have disclosed a prospective sensitivity of 95–98% for Morton neuromas and a retrospective sensitivity of up to 100% (5, 6, 9). However, a recent study by Quinn et al. (17) revealed that

85% of neuromas with an average width of 6 mm, an average height of 9 mm and an average length of 13 mm were identified prospectively. Analysis by US in our study showed a relatively low detection rate (79%) of Morton neuroma. There are multiple reasons for the various reported detection rates with using sonography. Sonography is a very operator-dependent technique, for instance, the sonographer's experience is quite important, and so erroneous detection does factor into US examinations. The size of the Morton neuroma is considered as another factor contributing to the variability of detection. The diameter of the normal plantar digital nerve is 1–2 mm at the level of the intermetatarsal heads and the normal nerve is not readily identifiable on sonography (5, 9). In our study, the mean sizes of the masses were 4.9 mm with using US and 5.1 mm with using MRI, and these values were smaller than those reported in a previous study (6.5 mm for US and 7.4 mm for MRI) (11).

MR imaging is a highly sensitive modality (87%) for the detection of Morton neuroma (1). Our MR imaging evaluation (detection rate: 76%) did not show a better detection result than that expected at the beginning of the study. Four out of 17 neuromas were not detected. In these cases, two neuromas were as small as 4 mm in transverse diameter (one of these is the case presented in Figure 2). That these lesions were missed was possibly due to their smaller size, and it was possibly due to the surgeon's

subjective diagnosis in the cases of surgical neurolysis in our study.

We should again consider the matter of the lesions' size. In our study, most of the neuromas that were operated upon were 5 mm or less. There was no lesion less than 3 mm detected by either the US or MRI modalities. In this aspect, the size of the lesions that were operated in our study was relatively smaller as compared with previous studies (1, 3, 7, 17). The measurement of Morton neuroma on the transverse MR image is dependent on the placement of the foot in the scanner. In addition, the size of the Morton neuroma is significantly larger in the prone position with plantar flexion of the ankle than in the supine and upright weight-bearing positions, in which the ankle is dorsiflexed (15). Our study was done with the foot placed in the supine position, which possibly caused a decreased diameter of the neuroma, although plantar flexion was applied to the ankle. Furthermore, sonographic measurement and patient position are examiner-dependent. The transverse diameter can be affected by the patient's position or by the compression pressure during sonography.

Previous studies have demonstrated that neuromas larger than 5 mm in diameter are more symptomatic than the smaller ones (3, 5, 6). Biasca et al. (7) showed that a more favorable clinical outcome can be expected after surgical intermetatarsal neurectomy when a Morton neuroma has a transverse measurement larger than 5 mm on MRI scans; 77% of the patients in that study had a good outcome when the neuroma was greater than 5 mm, compared with only 17% of the patients had a good outcome when their neuromas measured 5mm or less. On the other hand, Sharp et al. (11) demonstrated that symptoms were not dependent on the size of the neuroma. Moreover, the MR imaging diagnosis of Morton neuroma does not always imply symptomatology; thus, careful correlation between the clinical and MR imaging findings is mandatory (4). The fluid distention of the intermetatarsal bursa may mimic that of neuromas, but it may not manifest symptoms and it is typically less than 3 mm in transverse dimension (3).

There are different opinions regarding the best MR imaging sequences for detecting Morton neuroma (12, 15, 16). Erickson et al. (16) reported that T1WI was the most useful sequence because neuromas with decreased signal intensity were well demarcated from the adjacent fat tissue. On the other hand, Zanetti et al. (3) suggested that T2WI was beneficial in order to exclude other diseases that mimic neuroma, such as intermetatarsal bursitis, because the latter revealed high signal intensities. Terk et al. (12) stressed that sequences with fat-suppression and contrast-

enhancement were reliable sequences for showing high-contrast images, and their study revealed that T1WI alone failed to demonstrate the presence of 50% (3 of 6) of the neuromas. In our study, the T1WI revealed better results for the detection of Morton neuroma than the CEFS T1WI did. In particular, the rarely enhanced neuroma cases shown in Figures 1 and 3 were better discriminated on T1WI than on CEFS T1WI. However, the opposite was also true in Figure 2 when the neuroma was well enhanced. We think that CEFS T2WI is not obligatory for the purpose of detection alone, although it can be necessary for differentiation of neuroma from other possible lesions.

There are several limitations in our study. The false-positive and true-negative rates could not be obtained because our study group consisted of only surgically proven Morton neuromas (including cases of neurolysis that might have been related to the surgeon's subjectivity). In addition, performing surgical exploration in the asymptomatic intermetatarsal spaces in clinical settings is not ethically possible whether or not a suspected Morton neuroma is found on imaging studies. The second limitation is the retrospective analysis of the US findings, is that, sonography is an operator-dependent method. The third limitation is that the double lesions in one patient were not separately evaluated in the clinical outcome.

In summary, US and MR imaging are compatible modalities for the evaluation of Morton neuroma, and both modalities have relatively high detection rates. Both imaging studies can provide information on the location and size of the neuroma prior to surgery. In addition, the contrast enhanced sequence does not seem essential for the detection of neuroma.

References

- Zanetti M, Ledermann T, Zollinger H, Hodler J. Efficacy of MR imaging in patients suspected of having Morton's neuroma. *AJR Am J Roentgenol* 1997;168:529-532
- Wu KK. Morton neuroma and metatarsalgia. *Curr Opin Rheumatol* 2000;12:131-142
- Zanetti M, Strehle JK, Zollinger H, Hodler J. Morton neuroma and fluid in the intermetatarsal bursae on MR images of 70 asymptomatic volunteers. *Radiology* 1997;203:516-520
- Bencardino J, Rosenberg ZS, Beltran J, Liu X, Marty-Delfaut E. Morton's neuroma: is it always symptomatic? *AJR Am J Roentgenol* 2000;175:649-653
- Redd RA, Peters VJ, Emery SF, Branch HM, Rifkin MD. Morton neuroma: sonographic evaluation. *Radiology* 1989;171:415-417
- Pollak RA, Bellacosa RA, Dornbluth NC, Strash WW, Devall JM. Sonographic analysis of Morton's neuroma. *J Foot Surg* 1992;31:534-537
- Biasca N, Zanetti M, Zollinger H. Outcomes after partial neurectomy of Morton's neuroma related to preoperative case histories, clinical findings, and findings on magnetic resonance

Imaging Findings of Morton Neuroma

- imaging scans. *Foot Ankle Int* 1999;20:568-575
8. Zanetti M, Strehle JK, Kundert HP, Zollinger H, Hodler J. Morton neuroma: effect of MR imaging findings on diagnostic thinking and therapeutic decisions. *Radiology* 1999;213:583-588
 9. Shapiro PP, Shapiro SL. Sonographic evaluation of interdigital neuromas. *Foot Ankle Int* 1995;16:604-606
 10. Kaminsky S, Griffin L, Milsap J, Page D. Is ultrasonography a reliable way to confirm the diagnosis of Morton's neuroma? *Orthopedics* 1997;20:37-39
 11. Sharp RJ, Wade CM, Hennessy MS, Saxby TS. The role of MRI and ultrasound imaging in Morton's neuroma and the effect of size of lesion on symptoms. *J Bone Joint Surg Br* 2003;85:999-1005
 12. Terk MR, Kwong PK, Suthar M, Horvath BC, Colletti PM. Morton neuroma: evaluation with MR imaging performed with contrast enhancement and fat suppression. *Radiology* 1993;189:239-241
 13. Williams JW, Meaney J, Whitehouse GH, Klenerman L, Hussein Z. MRI in the investigation of Morton's neuroma: which sequences? *Clin Radiol* 1997;52:46-49
 14. Johnson JE, Johnson KA, Unni KK. Persistent pain after excision of an interdigital neuroma. Results of reoperation. *J Bone Joint Surg Am* 1988;70:651-657
 15. Weishaupt D, Treiber K, Kundert HP, Zollinger H, Vienne P, Hodler J, et al. Morton neuroma: MR imaging in prone, supine, and upright weight-bearing body positions. *Radiology* 2003;226:849-856
 16. Erickson SJ, Canale PB, Carrera GF, Johnson JE, Shereff MJ, Gould JS, et al. Interdigital (Morton) neuroma: high-resolution MR imaging with a solenoid coil. *Radiology* 1991;181:833-836
 17. Quinn TJ, Jacobson JA, Craig JG, van Holsbeeck MT. Sonography of Morton's neuromas. *AJR Am J Roentgenol* 2000;174:1723-1728
 18. Wu KK. Morton's interdigital neuroma: a clinical review of its etiology, treatment, and results. *J Foot Ankle Surg* 1996;35:112-119; discussion 187-188