


## RESEARCH LETTER

# An incidental finding of maternal multiple myeloma by non invasive prenatal testing

Marion Imbert-Bouteille<sup>1,2</sup>  | Jean Chiesa<sup>1</sup> | Jean-Baptiste Gaillard<sup>1</sup> |  
Véronique Dorvaux<sup>3</sup> | Lucille Altounian<sup>4</sup> | Vincent Gatinois<sup>2</sup> | Eve Mousty<sup>5</sup> | Sanae Finge<sup>6</sup> |  
Pascal Bourquard<sup>7</sup> | Joris Robert Vermeesch<sup>8</sup> | Eric Legius<sup>8</sup> | Peter Vandenberghe<sup>8</sup>

<sup>1</sup>Medical Genetics and Cytogenetics Department, Carémeau University Hospital Center, Nîmes, France

<sup>2</sup>Medical Genetics and Cytogenetics Department, University Hospital Center, Montpellier, France

<sup>3</sup>Hematology Department, Mercy Hospital Center of Metz-Thionville, Metz, France

<sup>4</sup>Cytogenetics Department, Mercy Hospital Center of Metz-Thionville, Metz, France

<sup>5</sup>Multidisciplinary Prenatal Diagnosis Department, Carémeau University Hospital Center, Nîmes, France

<sup>6</sup>Biology and Immunology Department, Carémeau University Hospital Center, Nîmes, France

<sup>7</sup>Clinical Hematology Department, Carémeau University Hospital Center, Nîmes, France

<sup>8</sup>Department of Human Genetics, Center for Human Genetics, and Department of Hematology, University Hospitals Leuven, Leuven, Belgium

## Correspondence

Marion Imbert-Bouteille, Centre Hospitalo-Universitaire de Montpellier, Hôpital Arnaud de Villeneuve, Département de Génétique Médicale, 371 avenue du Doyen Gaston Giraud, 34 295 Montpellier, France.

Email: m-imbertybouteille@chu-montpellier.fr

## 1 | INTRODUCTION

Within recent years, robust genome wide approaches have been introduced for non invasive prenatal testing (NIPT) on maternal plasma samples. While these tests are strictly designed to detect fetal trisomies 13, 18, and 21, they also allow detection of subchromosomal fetal imbalances or mostly acquired copy number variations (CNV) in the mother. Over the past 3 years, several case-series have reported rare incidental findings (IFs) of unique patterns in NIPT of nonspecific multiple chromosomal CNV leading to the diagnosis of previously occult maternal malignancies by NIPT (lymphoma, leukaemia, ovarian, colorectal, anal, and neuroendocrine carcinoma and leiomyosarcoma) during the pregnancy or the weeks following the pregnancy.<sup>1-3</sup>

Controversy remains over whether such an early diagnosis and treatment in a presymptomatic or early stage lead to better survival.<sup>4</sup> Management of unexpected findings of NIPT is a critical issue which is just starting to be addressed by scientific societies.

We report the case of a 40-year-old pregnant woman, without any medical history, offered NIPT because of her age at 12 weeks

gestational age (WGA). Her regular gynecologist provided pretest counseling during a routine first-trimester prenatal consultation. This consisted of oral background information about NIPT without mentioning potential IFs. The patient was provided with a detailed written factsheet developed by the Hospital Genetics Center which performed the test. She signed an informed consent form stating that NIPT can also rarely detect fetal chromosomal abnormalities other than trisomies 21 and 18 and maternal chromosomal anomalies.

The NIPT procedure used a protocol of massive parallel sequencing of cell-free DNA (cfDNA), enabling genome-wide identification of segmental aneuploidies (of fetal or maternal origin).<sup>2,5</sup>

A strongly abnormal genome-wide representation (GR) profile was detected with several subchromosomal imbalances (gains and losses) involving 7 autosomal chromosomes (Figure 1, left panel). These extensive CNVs were suggestive of maternal acquired chromosomal imbalances, in particular multiple myeloma (MM), based on gain of 1q, 3, 15, and loss of 13.<sup>6</sup> The patient did not have signs or symptoms suggestive of disease at that time (15 WGA). The gynecologist announced the incidental maternal cancer suspicion to the patient, and further diagnostic and staging investigations were undertaken

This is an open access article under the terms of the Creative Commons Attribution-NonCommercial-NoDerivs License, which permits use and distribution in any medium, provided the original work is properly cited, the use is non-commercial and no modifications or adaptations are made.

© 2017 The Authors. Prenatal Diagnosis published by John Wiley & Sons Ltd.

(hematological and biochemical serum assays, urinary assays, and imaging (Additional Supporting Information: Table 1)). Free Light Chain Lambda/Kappa ratio was more than 100; thus, the diagnosis of MM type light chain lambda was made.<sup>7</sup> Five medical specialist consultations (gynecologist, onco-haematologist, and geneticist), and 2 psychological consultations were needed before diagnosis of MM was made. A bone marrow (BM) biopsy (performed 1 month after delivery) showed 8% plasma cells (PC), with areas with up to 22% PC.

aCGH and FISH on CD138+ sorted BM PC revealed somatic acquired CNVs, replicating those detected by NIPT, and loss of chromosome X (sex chromosome abnormalities were excluded from NIPT report to comply with national best practice). FISH and cytogenetic examination on CD138+ sorted BM PC confirmed amplification of segment 1q21 in 87% cell nuclei (Figure 1) and in addition revealed the translocation t(4;14)(p16;q32) involving *FGFR3* and *IGH* genes in 77% cell nuclei.

In the absence of hypercalcemia, renal failure, anemia or osteolytic lesions, close clinical, hematological, and biological follow-up was scheduled. At last examination (19 months elapsed from diagnosis), no clinical evolution had occurred, and whole-body PET-CT scanning was negative.

In addition to consultations specifically dedicated to malignancy investigation, post-test counseling about the risk of fetal chromosomal abnormalities required multidisciplinary reflection, involving hospital prenatal diagnosis center (HPNDC) staff with obstetrician/gynaecologist, biologist, and medical geneticist. Options were explained and discussed with the pregnant patient. Second trimester maternal serum screening (MSS) performed after NIPT at 16 WGA lead to a 1/150 calculated risk (Additional Supporting Information: Table 2). Fetal ultrasound screening was performed by a HPNDC practitioner at 16 and 18 WGA and detected no fetal growth or morphological abnormality.

Amniocentesis for fetal karyotyping was performed at 18 WGA and proved to be normal [46,XY]. The patient gave birth at 38 WGA to a healthy boy.

From being first informed of the abnormal GR profile and the possibility of a maternal malignancy, the patient developed a psychological disorder comparable to general anxiety disorders and required psychological assistance.

Three exceptional NIPT cases have previously been reported revealing abnormalities that led to a diagnosis of maternal cancer.<sup>1-3</sup> To the best of our knowledge at the time of writing, this is the first NIPT result leading to a diagnosis of MM in the mother. The expected cancer rate is 1 in 1000 pregnancies with hematological malignancies ranked second in tumor type distribution, and given that more than two million NIPTs have been carried out so far, it may be surprising that more cases have not been reported.<sup>8</sup> Nevertheless, MM was highly unexpected in this pregnant woman as the MM incidence in 40 to 49-year-old people is around 2 per 100 000 person-years.

According to the latest revision of guidelines stating criteria for the diagnosis and management of MM,<sup>9</sup> this case should be diagnosed as MM requiring therapy. The FLC Lambda/Kappa ratio of more than 100 is a myeloma defining event because it is regarded as a strong predictive factor of imminent progression to organ damage (in particular renal failure) and to active MM, particularly given the high

### What is already known about this subject?

- Non invasive prenatal testing for fetal trisomies 13, 18, and 21 occasionally identifies maternal cancer.

### What does this study add?

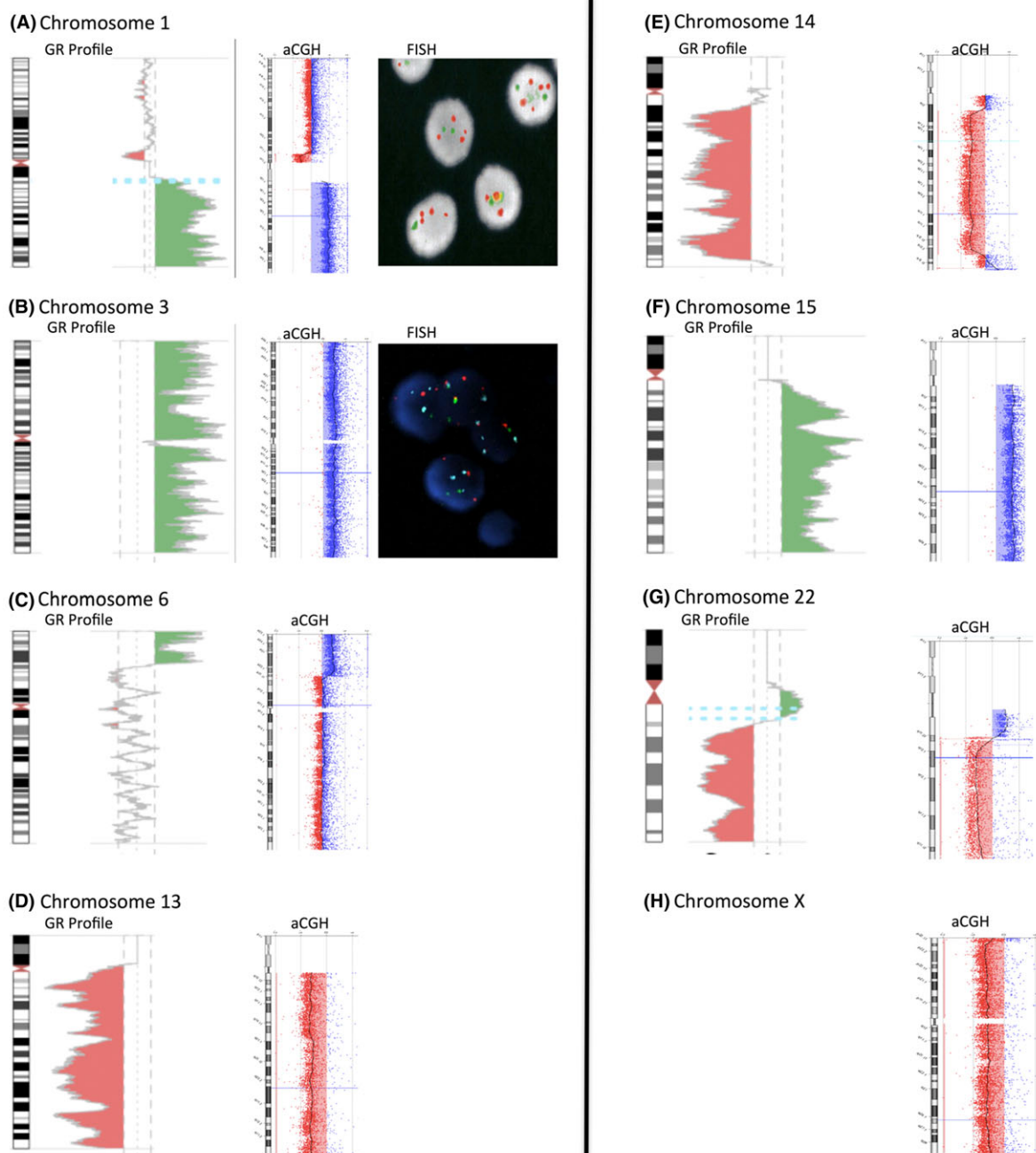
- A further case of maternal cancer incidentally diagnosed by routine NIPT.
- Extensive NIPT abnormalities are unlikely to be of fetal origin.
- Information given to patients should also adequately advise patients on potential incidental findings and might offer the option to opt out of receiving results beyond the trisomy report.
- International guidelines would improve patient counseling.

risk factors such as translocation t(4;14). Therefore, this IF is medically relevant as this condition at least constitutes a strong indication for close monitoring.

The issues of potential lead-time bias and of potential harm to the patient, as well as potential harm to the fetus, are important when the diagnosis of malignancy is made during pregnancy. These issues are still highly contentious, and the decision whether to treat or not will depend on the expected natural history of the disease and the therapy required. Recent data suggest that certain therapies can be given safely during pregnancy, that the maternal outcome can improve, and that the neonatal outcome is normal.<sup>7</sup>

This report highlights 2 issues. First, as NIPT is performed to rule out fetal trisomies, abnormal NIPT results almost routinely lead to amniocentesis before a malignant maternal cause is considered. However, strongly abnormal GR profiles with multiple abnormalities are considered incompatible with normal fetal development. Hence, a normal fetal development for gestational age likely points to a non-fetal origin. In this respect, the amniocentesis performed as the follow-on step could be considered as medically unnecessary. However, in this situation, the presence of large amounts of "malignant cell" derived cfDNA in the plasma may dilute the fetal cfDNA and obscure a fetal trisomy. Therefore, in this case, even though the results were likely due to a maternal reason, an amniocentesis should be considered.

Second, it is crucial to provide thorough, prior information to patients about the possible IFs. As recently recommended in the literature,<sup>10</sup> we advocate enrichment of this information, enabling pregnant patients undergoing NIPT to choose whether they want to be informed of abnormal unexpected results or not after appropriate pre-test counseling. We suggest that pre-test counseling specifically discuss the points detailed in Table 1.



**FIGURE 1** Genome representation (GR) profile, microarray-based comparative genomic hybridization (aCGH), and fluorescent in situ hybridization (FISH) on CD138+ sorted bone marrow (BM) plasma cells of patient. A – G. All panels present both chromosome GR profiles (chromosomes 1, 3, 6, 13, 14, 15, 22; left panel halves) and confirmation by aCGH performed on CD138+ sorted bone marrow plasma cells (right panel halves). In the GR profiles, the dotted lines on either side of the axis indicate plus or minus 3x (ie, Z-score = -3 or +3 thresholds); red areas, likely deleted regions; and green areas, likely duplicated or amplified regions. In aCGH graphs, vertical light grey lines indicate, from left to right, -2, -1, 0, +1, and +2 Log<sub>2</sub> ratios; red rectangle areas highlighting red dots indicate deleted regions; and blue rectangle areas highlighting blue dots duplicated or amplified regions. A, B. FISH analyses performed on CD138+ sorted bone marrow plasma cells (far right side of the panel). The illustrated FISH probes include the following: A, *CKS1B* (1q21.3) probe (red), and *CDKN2C* (1p32) probe (green); B, chromosome 3 centromeric (D3Z1) probe (red), chromosome 15 centromeric (D15Z1) probe (blue) and chromosome 16 centromeric (D16Z3) probe (green) as a control. Note numerous and amplified signals of *CKS1B*, D3Z1, and D15Z1, evidencing gain of these regions in tumor plasma cells detected by GR profiling. H. aCGH performed on CD138+ sorted bone marrow plasma cells revealed a deletion of chromosome X, not reported on NIPT GR profiling to comply with national best practice

It could be argued that strictly limiting testing to main fetal aneuploidies would prevent detection of difficult-to-manage discordant results. However, incidental detection of maternal diseases is almost unavoidable. With a targeted test, for instance, loss of

chromosome 13 alone would have been sufficient to raise concern and probably have led to an amniocentesis. Genome-wide profiling may distinguish a tumor profile from a false positive fetal aneuploidy.

**TABLE 1** Pre-test counseling points to specifically discuss concerning incidental findings with pregnant women contemplating NIPT for main fetal aneuploidies (trisomies 21, 18, and 13)

1. What is meant by “unexpected finding”, that is to say any finding, unintentionally obtained, which is not one of the main fetal trisomies.
2. Unexpected findings estimated frequency: Between 1 in 1000 and 1 in 10 000
3. Possibility of several types of unexpected findings, some relating to the fetus, some relating to the mother, or both.
4. Unexpected findings relating to the fetus may lead to the diagnosis of segmental aneuploidies and sex chromosome aneuploidies.
5. Unexpected findings relating to the mother may lead to the diagnosis of segmental aneuploidies, sex chromosome aneuploidies, or occult malignancies.
6. An unexpected finding normally requires further maternal or fetal or both testing to be confirmed and accurately characterized.
7. Because medical relevance and impact on health vary depending on the type of unexpected finding, the patient is asked to opt in or out of being informed about each of the 5 types of incidental finding listed above (points 4 and 5).

MSS for fetal aneuploidies also leads to IFs (ie, maternal hepatocellular carcinoma, hepatoid ovarian carcinoma, or germ cell tumor revealed by unusually elevated alpha-foetoprotein or human choriongonadotrophin serum levels), similarly to how routine prenatal obstetrical sonography (POS) can reveal placental, ovarian, renal, bladder, pancreatic, or intestinal occult malignancies. A search of PubMed highlights approximately 20 cases of IFs of maternal cancer in MSS and 10 cases of incidental sonographic findings between 1983 and 2017. Under the assumption that the number of MSS and POS procedures performed within this time span is more than one hundred million, the estimated frequency of IFs with MSS or POS is smaller than one in one million. Whereas IF of maternal cancer with NIPT frequency is expected to be in the range of one in a thousand to one in ten thousand.<sup>2,3</sup> Hence, IFs of maternal cancer by NIPT might be more frequent than those by MSS and/or POS. Furthermore, it potentially encompasses a broader spectrum of tumor types.

As NIPT is taking the center stage in prenatal testing, thoughtful guidelines should be implemented, together with better practitioner and patient education. Without guidelines, NIPT might lead to inappropriate medical practice, disrespectful of the priority duties not to harm and to maintain patients' informed and free choice.

## ACKNOWLEDGEMENTS

We would like to thank Sarah Kabani for valuable editorial assistance.

## CONFLICT OF INTEREST DISCLOSURE

None.

## ORCID

Marion Imbert-Bouteille  <http://orcid.org/0000-0002-8967-7004>

## REFERENCES

1. Osborne CM, Hardisty E, Devers P, et al. Discordant noninvasive prenatal testing results in a patient subsequently diagnosed with metastatic disease. *Prenat Diagn*. 2013;33(6):609-611.

2. Amant F, Verheecke M, Wlodarska I, et al. Presymptomatic identification of cancers in pregnant women during noninvasive prenatal testing. *JAMA Oncol*. 2015;1(6):814-819.
3. Bianchi DW, Chudova D, Sehnert AJ, et al. Noninvasive prenatal testing and incidental detection of occult maternal malignancies. *JAMA* 2015;314(2):162-9.
4. Prasad V. Non-invasive, serum DNA pregnancy testing leading to incidental discovery of cancer: a good thing? *Eur J Cancer Oxf Engl* 1990. 2015;51(16):2272-2274.
5. Vandenberghe P, Wlodarska I, Tousseyn T, et al. Non-invasive detection of genomic imbalances in Hodgkin/Reed-Sternberg cells in early and advanced stage Hodgkin's lymphoma by sequencing of circulating cell-free DNA: a technical proof-of-principle study. *Lancet Haematol*. 2015;2(2):e55-e65.
6. Fonseca R, Debes-Marun CS, Picken EB, et al. The recurrent IgH translocations are highly associated with nonhyperdiploid variant multiple myeloma. *Blood*. 2003;102(7):2562-2567.
7. Amant F, Vandembroucke T, Verheecke M, et al. For the international network on cancer, infertility, and pregnancy (INCIP). Pediatric outcome after maternal cancer diagnosed during pregnancy. *N Engl J Med*. 2015;373:1824-1834.
8. Iwarsson E, Jacobsson B, Dagerhamn J, Davidson T, Bernabé E, Heibert Arnlin M. Analysis of cell-free fetal DNA in maternal blood for detection of trisomy 21, 18 and 13 in a general pregnant population and in a high risk population—a systematic review and meta-analysis. *Acta Obstet Gynecol Scand*. 2016. <https://doi.org/10.1111/aogs.13047>
9. Engelhardt M, Terpos E, Kleber M, et al. European myeloma network recommendations on the evaluation and treatment of newly diagnosed patients with multiple myeloma. *Haematologica*. 2014;99(2):232-242.
10. Bianchi DW. Pregnancy: prepare for unexpected prenatal test results. *Nature*. 2015;522(7554):29-30.

## SUPPORTING INFORMATION

Additional Supporting Information may be found online in the supporting information tab for this article.

**How to cite this article:** Imbert-Bouteille M, Chiesa J, Gaillard J-B, et al. An incidental finding of maternal multiple myeloma by non invasive prenatal testing. *Prenatal Diagnosis*. 2017;37:1257–1260. <https://doi.org/10.1002/pd.5168>