

Anju Arora  
Sandeep Arora

## Spontaneous splenic infarction associated with sumatriptan use

Received: 16 April 2006  
Accepted in revised form: 18 May 2006  
Published online: 15 June 2006

A. Arora (✉) · S. Arora  
Department of Internal Medicine,  
Western Pennsylvania Hospital  
Temple University Program,  
4800 Friendship Avenue,  
Pittsburgh, PA 15224, USA  
e-mail: anjuarora27@hotmail.com  
Tel.: +1-412-578-6929  
Fax: +1-412-578-6804

**Abstract** Triptans are specific agonists of the serotonergic 5-HT<sub>1B/1D</sub> receptors that have increasingly been used in the treatment of migraine and cluster headaches. Though they are generally considered safe, there have been a few reports of myocardial infarction and stroke associated with triptan use. We report a patient who developed spontaneous splenic infarction after the use of sumatriptan for the treatment of migraine headache.

**Key words** Triptan · Spleen · Infarction

### Introduction

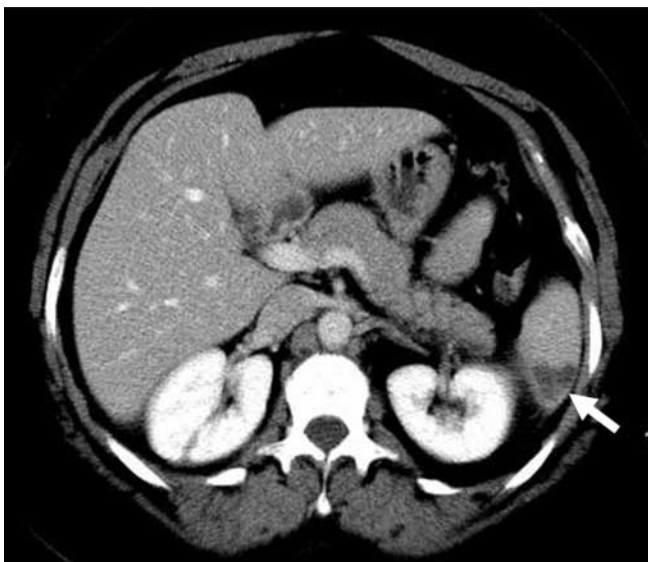
Triptans are highly selective agonists of the 5-HT<sub>1B/1D</sub> serotonergic receptors and they have revolutionised the treatment of migraine in the past decade. Commonly used triptans include sumatriptan, zolmitriptan, eletriptan, rizatriptan and naratriptan. All these agents seem to have similar clinical efficacy and safety profiles. In view of their selective affinity for 5-HT<sub>1B/1D</sub> receptors, they are usually well tolerated and have few adverse effects. A few authors have reported myocardial ischaemia and stroke in association with triptan use [1, 2] and there is an isolated report of spontaneous splenic infarction following use of zolmitriptan [3]. We report a patient who developed a spontaneous infarction of the spleen after treatment with sumatriptan.

### Case report

A 52-year-old female with a history of migraine headaches and depression presented to the hospital with sudden onset, sharp, left-sided chest pain located just below the breast. She denied any fever, cough, dyspnoea, abdominal pain, trauma, recent surgery, travel or oral contraceptive use. Her headaches began at the age of 17 years and were usually unilateral, throbbing in nature and were associated with nausea, vomiting and photophobia. They used to last for a day or two and were treated with ibuprofen. These episodes were not accompanied by preceding aura, sensory or visual symptoms. Frequency of the headaches was 1–2 times/month and she had never been on any preventive therapy. She had been using sumatriptan

tan 50 mg for acute therapy for the last 4–5 years. A few weeks prior to hospitalisation, the frequency of her migraines increased (1–2 episodes/week), which she attributed to work-related stress. She had consumed 2 tablets of sumatriptan (50 mg) on 3 occasions in the week prior to hospitalisation with the last dose being around 6 h before the onset of symptoms. She had been diagnosed with depression 2 years previously when she started having symptoms of anhedonia, lack of energy, decreased appetite and sleep disturbances and had been taking escitalopram 10 mg/day for the last 18 months. She was a chronic smoker and denied any family history of hypercoagulable state, stroke or heart disease.

Physical examination was unremarkable except for mild left upper quadrant tenderness without splenomegaly. Laboratory investigations including complete blood counts with peripheral smear, coagulation studies, basic metabolic panel, liver and thyroid function tests were within normal limits. EKG, chest X-ray and cardiac enzymes were normal. D-dimer was mildly elevated at 0.83 ng/l (0–0.5 ng/l). CT scan of chest and abdomen was negative for pulmonary embolism and showed a wedge-shaped opacity in the spleen suggestive of acute infarction (Fig. 1). Screening tests for connective tissue disorders and hypercoagulable states including antinuclear antibody, antineutrophil cytoplasmic antibodies (ANCA), rheumatoid factor, complement levels, antiphospholipid antibodies, factor V Leiden and prothrombin mutations, protein C and S, antithrombin III deficiencies and hyperhomocysteinaemia were negative. Haemoglobin electrophoresis, 2D echocardiogram and venous Dopplers were unremarkable. Her symptoms gradually improved



**Fig. 1** Contrast-enhanced CT scan of abdomen showing wedge-shaped splenic infarct (*arrow*)

with non-steroidal anti-inflammatory medications. She was discharged home in a stable condition with the advice to avoid triptans and ergotamines.

## Discussion

Splenic infarction is usually encountered in association with haematological diseases, thromboembolic states and vasculitides, especially systemic lupus erythematosus with lupus anticoagulant or antiphospholipid antibodies [4]. Splenic infarction has also been known to occur in patients with moderate to severe splenomegaly, falciparum malaria, sickle cell disease, rupture of splenic artery aneurysm, Kawasaki's disease, Wegener's granulomatosis and in patients with cocaine abuse. We describe here a patient who developed spontaneous splenic infarction after sumatriptan use. Though it is difficult to establish a causal relationship, there are certain features that suggest possible association of splenic infarct with sumatriptan use. First, there was a clear and close temporal association between ingestion of the drug and development of symptoms. Second, extensive work-up failed to reveal an alternate cause such as haematological malignancy, hypercoagulable state or any atherothrombotic risk factors. Finally, triptans may potentially cause vasoconstriction in extra-cerebral sites, which could have a role to play in the development of splenic infarction in our patient.

5HT<sub>1B</sub> receptors are present in abundance on vascular endothelium and meningeal vessels and mediate triptan-induced contraction of vascular smooth muscle [5]. Triptans help in relieving migraine headache and associated symptoms by causing selective constriction of pain-producing intracranial extra-cerebral blood vessels, decreasing trigeminal sensory nerve activation and inhibition of vasoactive neuropeptide release. Vasoactive peptides found in the trigeminal neurons that innervate intracranial blood vessels include calcitonin gene-related peptide (CGRP), substance P and neurokinin A. Both CGRP and substance P have endothelium-dependent vasodilatory actions on the cerebral vasculature [6]. Other possible mechanisms of triptans include modulation of nitric oxide (NO)-dependent signal transduction pathways, NO scavenging and modulation of sodium-dependent cell metabolic activity [7]. This is based on the assumption that NO may have a role in production of migraine headaches as administration of nitroglycerine in patients with underlying migraine can cause dose-dependent migraine-like headaches [7].

The optimum dose of triptans for migraine headaches is not clearly defined. Results from a clinical trial of sumatriptan have shown that an initial dose of 50 mg is as

effective as 100 mg and may have lesser incidence of adverse reactions [8]. It is recommended that total dose of sumatriptan should not exceed 200 mg/day. Triptans are usually well tolerated but occasionally may cause fatigue, dizziness, a "warm" sensation after subcutaneous injection and "tightness" in the throat and chest. The major concern with the use of triptans has been the potential for vasoconstriction, especially of the coronary and intracerebral vessels. There are a few case reports of patients developing cardiovascular complications including myocardial infarction, arrhythmias and strokes secondary to use of triptans [1, 2]. Isolated cases of mesenteric infarction [9] and a case of spinal cord infarction have also been reported [10]. In one study, invasive haemodynamic monitoring in ten patients undergoing coronary angiogram revealed that subcutaneous injection of sumatriptan caused significant increase in systemic and pulmonary artery pressures and a significant reduction in mean coronary artery diameter [11]. In view of these concerns, triptans are contraindicated in patients with established cardiac and cerebrovascular disease.

The probable pathogenic mechanisms responsible for splenic infarction with triptan use in our patient include

splenic ischaemia secondary to vasospasm of the splenic artery either by a direct effect on vascular smooth muscles and/or inhibition of release of vasoactive peptides. Our hypothesis is supported by previous observations of development of mesenteric ischaemia and ischaemic colitis with triptan use. A case similar to our patient with spontaneous splenic infarction following the use of zolmitriptan has also been described [3]. Though not reported in the literature, it is possible that splenic and mesenteric vasculature may also have 5HT<sub>1B/1D</sub> receptors, as seen in meningeal vessels, resulting in triptan-induced vasoconstriction and ischaemia.

## Conclusions

In conclusion, our case emphasises the need to recognise the possible association of triptans with intra-abdominal ischaemic complications. As triptans are the mainstay of acute management of migraine headaches, they should be used judiciously, especially in patients with a risk of atherothrombotic diseases and hypercoagulable states.

## References

- Mueller L, Galagher RM, Ciervo CA (1996) Vasospasm-induced myocardial infarction with sumatriptan. *Headache* 36:329–331
- Jayamaha JEL, Street MK (1995) Fatal cerebellar infarction in a migraine sufferer whilst receiving sumatriptan. *Intensive Care Med* 21:82–83
- Bellaiche G, Radu B, Boucard M, Ley G, Slama J-L (2002) Infarctus splénique associé à la prise de zolmitriptan. *Gastroenterol Clin Biol* 26:299
- Nores M, Phillips EH, Morganstern L, Hiatt JR (1998) The clinical spectrum of splenic infarction. *Am Surg* 64:182–188
- Goadsby PJ (1998) Serotonin receptors and the acute attack of migraine. *Clin Neurosci* 5:18–23
- Hanko J, Hardebo JE, Kahrstrom J, Owman C, Sundler F (1985) Calcitonin gene-related peptide is present in mammalian cerebrovascular nerve fibres and dilates pial and peripheral arteries. *Neurosci Lett* 57:91–95
- Read SJ, Manning P, McNeil CJ, Hunter AJ, Parsons AA (1999) Effects of sumatriptan on nitric oxide and superoxide balance during glyceryl trinitrate infusion in the rat: implications for antimigraine mechanisms. *Brain Res* 847:1–8
- Plaffenrath V, Cunin G, Sjonell MD, Prendergast S (1998) Efficacy and safety of sumatriptan tablets (25 mg, 50 mg and 100 mg) in the acute treatment of migraine: defining the optimum doses of sumatriptan. *Headache* 38:184–190
- Knudsen JF, Friedman B, Chen M, Goldwasser JE (1998) Ischemic colitis and sumatriptan use. *Arch Intern Med* 158:1946–1948
- Vijayan N, Peacock JH (2000) Spinal cord infarction during the use of zolmitriptan: a case report. *Headache* 40:57–60
- MacIntyre PD, Bhargava B, Gemmill JD, Hillis WS (1993) Effect of subcutaneous sumatriptan, a selective 5-HT<sub>1</sub> agonist, on the systemic, pulmonary and coronary circulation. *Circulation* 87:401–405