



# Therapeutic Effects of Amnion-Conjugated Chitosan-Alginate Membranes on Diabetic Wounds in an Induced Diabetic Swine Model: An In Vitro and In Vivo Study

Woonhyeok Jeong, MD, PhD<sup>1</sup> Jamin Hong, MD<sup>1</sup> Minho Jung, MS<sup>2</sup> Mijin Jang, MS<sup>3</sup>  
Sanghyun An, PhD<sup>3</sup> Taehee Jo, MD, PhD<sup>1</sup> Sunyoung Kwon, MD, PhD<sup>4</sup> Daegu Son, MD, PhD<sup>1</sup>

<sup>1</sup>Department of Plastic and Reconstructive Surgery, Dongsan Medical Center, Keimyung University School of Medicine, Daegu, Korea

<sup>2</sup>Department of Research and Development, Endovision, Daegu, Korea

<sup>3</sup>Laboratory Animal Center, Daegu Gyeongbuk Medical Innovation Foundation, Daegu, Korea

<sup>4</sup>Department of Pathology, Keimyung University School of Medicine, Daegu, Korea

Address for correspondence Daegu Son, MD, PhD, Department of Plastic and Reconstructive Surgery, Dongsan Medical Center, Keimyung University School of Medicine, 1000-2 Shindang-dong, Dalseo-gu, Daegu, Korea (e-mail: handson@dsmc.or.kr).

Arch Plast Surg 2022;49:258–265.

## Abstract

**Background** Chitosan (CS) is a well-known antimicrobial dressing material. Moreover, widely used amniotic membranes contain growth factors beneficial for wound healing. Herein, we created a novel amnion-conjugated CS-alginate membrane dressing and tested its wound healing potency in a diabetic swine model.

**Methods** The bovine amniotic powder growth factor contents were evaluated by protein assay, and the powder's wound healing effects were assessed in vitro by HaCaT cell scratch closure. In vivo, two minipigs developed streptozotocin-induced diabetes. Serial serum glucose measurements and intravenous glucose tolerance tests were performed to confirm their diabetic status. Twelve square-shaped wounds created on each pig's back were randomly divided into control ( $n = 4$ ), CS ( $n = 4$ ), and amnion-CS (AC;  $n = 4$ ) groups and treated accordingly with different dressings. Wound healing in each group was assessed by measuring wound contraction over time, capturing wound perfusion with indocyanine green (ICG) angiography, and histologically analyzing inflammatory markers.

**Results** Amniotic powder elution promoted HaCaT cell migration in the scratch wound model, suggesting its beneficial in vitro wound healing effects. In vivo, the CS and AC groups showed earlier wound contraction initiation and reepithelialization and earlier wound perfusion improvement by ICG angiography than the control group. Additionally, the wound size of the AC group at week 3 was significantly smaller than those in the control group. There was no significant difference in the numbers of acute and chronic inflammatory cells between the groups.

**Conclusion** The amnion-conjugated CS-alginate membrane, as well as CS dressing alone, could be a favorable dressing option for diabetic wounds.

## Keywords

- ▶ amnion
- ▶ chitosan
- ▶ wound healing
- ▶ diabetes
- ▶ swine

DOI <https://doi.org/10.1055/s-0042-1744429>.  
ISSN 2234-6163.

© 2022. The Korean Society of Plastic and Reconstructive Surgeons. All rights reserved.

This is an open access article published by Thieme under the terms of the Creative Commons Attribution-NonDerivative-NonCommercial-License, permitting copying and reproduction so long as the original work is given appropriate credit. Contents may not be used for commercial purposes, or adapted, remixed, transformed or built upon. (<https://creativecommons.org/licenses/by-nc-nd/4.0/>)

Thieme Medical Publishers, Inc., 333 Seventh Avenue, 18th Floor, New York, NY 10001, USA

Diabetes mellitus is a life-long disease accompanied by several complications. In 2019, the prevalence of diabetes was estimated to be 9.3% (430 million) among 20- to 79-year-olds.<sup>1</sup> Diabetes mellitus is an important cause of chronic wounds, particularly diabetic foot ulcers, which are a major public health issue. There is up to a 25% risk of developing diabetic foot ulcers in one's lifetime, and limb amputation occurs every 30 seconds.<sup>2</sup> Furthermore, diabetic foot ulcers lead to economic problems to both patients and to society.<sup>2</sup> Notably, the global chronic wound dressing market was valued at USD 9.91 billion in 2017 and is still growing due to the increasing prevalence of diabetic foot ulcers, pressure ulcers, and other types of chronic wounds.

Chitosan (CS) is a deacetylated form of chitin, which is the second most abundant biopolymer after cellulose.<sup>3</sup> The shells of crustaceans are a major source of chitin and a main problem in marine litter. Therefore, CS not only has wound-healing properties but also has the benefit of reducing waste problems. More importantly, CS is a well-known dressing material with antimicrobial and pain-killing effects that shows fast wound recovery.<sup>4</sup> The amniotic membrane, on the other hand, is the inner layer of the placenta that has been widely used as a dressing material because it contains several growth factors, such as keratinocyte growth factor (KGF), vascular endothelial growth factor (VEGF), epidermal growth factor (EGF), and fibroblast growth factor-2 (FGF-2).<sup>5</sup>

In diabetic patients, wound healing is impaired due to neuropathy, ischemia, and infection. Growth factors, including EGF, VEGF, FGF-2, and transforming growth factor  $\beta$ , are promising therapeutic candidates to augment diabetic wound healing.<sup>6</sup> We hypothesized that an amniotic membrane containing diverse growth factors and CS as an antimicrobial carrier for the amniotic membrane could create a synergistic effect on the healing of diabetic wounds. To test this idea, we created an amnion-conjugated CS-alginate membrane and investigated its healing effects on diabetic wounds in a swine model.

## Methods

First, on the backs of two experimentally induced diabetic model minipigs, we made square-shaped wounds. We then applied our amnion-conjugated CS-alginate membranes to the defects to observe the therapeutic effects. The outcomes were evaluated by comparing the amount of wound contraction and reepithelialization, the level of wound perfusion, and histological evaluation of inflammatory level. The membranes were created using bovine amniotic powder after verifying growth factor content levels, which generally represent the wound-restoring potential of a material.

### Measurements of Growth Factors Eluted from Bovine Amniotic Powders

To evaluate the elution of growth factors from amniotic powder, 100 mg of bovine amniotic powder diluted with 100 mL of normal saline was incubated at 37°C for 24 hours. Then, the mixture was centrifuged at 15,000 revolutions

per minute for 20 minutes at 4°C. The supernatant was measured for its total protein and growth factor contents.

We measured the total protein content of each batch of amniotic powder with a BCA Protein Assay kit (Thermo Scientific, MA). The concentrations of bovine EGF, FGF-2, and KGF were measured by commercially available enzyme-linked immunosorbent assay kits (Genorise Scientific, PA) according to the manufacturer's protocol at different time points of preservation and at different storage temperatures.

### Effects of Amniotic Powder on HaCaT Cell Migration

To demonstrate the benefits of amniotic membrane elution (AME) on wound healing process, we tested its effects on HaCaT cell migration via scratch closure test. Briefly, HaCaT cells were seeded into 6-well plates, cultured to confluence, and scratched by scraping with a 1-mL pipette tip. After washing with phosphate-buffered saline, we reincubated the test cultures with different concentrations (0.1, 0.3, 1.0, 3.0, 10.0, and 30.0 mg/mL) of AME in serum-free culture medium. Negative control groups were cultured in serum-free medium without AME, and positive control wells were cultured in complete culture medium without AME.


At 0, 3, 6, and 24 hours after scratching, digital images of the HaCaT cells were captured with Olympus CKX41 Cell Sense software equipped with a digital camera. The percent of scratch closure was calculated as follows: Wound closure % =  $(At_0 - At_x) / At_0 \times 100\%$ , where  $At_0$  is the scratch area at time 0 and  $At_x$  represents the scratch area at 3, 6, or 24 hours. The experiments were repeated three times, and the mean value was regarded as the final outcome.

### Synthesis of the Amnion-Conjugated Chitosan-Alginate Membrane

CS solution (Endovision, Daegu, Korea) was diluted to a concentration of 1 ~ 4 g/cm<sup>3</sup> in distilled water at room temperature over 3 hours. Then, the CS solution was mixed with a glycerin solution (DUKSAN, Gyeong-gi, Korea) at 0.1 ~ 0.4 v/v% to form a homogeneous solution. Alginate (Sigma-Aldrich, MO) and amniotic membrane solution (Hundai Bioland, Chung-buk, Korea) were each dissolved in distilled water to a concentration of 0.5 ~ 1 and 0.1 ~ 0.7 g/cm<sup>3</sup>, respectively, at room temperature over 4 hours. The CS solution was frozen at 10 stepwise temperatures of 4 ~ -35°C over 15 hours using a freeze-dryer (LP 20; IIShinBio-Base, Gyeong-gi, Korea). Then, the alginate and amniotic membrane solution were put into contact with the frozen CS to freeze at -35°C for over 6 hours. Finally, the frozen CS-alginate-amnion membrane was vacuum-dried at 10 stepwise temperatures of -35 ~ 35°C for over 85 hours to complete the shaping and then heated at 80 ~ 120°C for 2 hours to induce the cross-bridging of CS, completing the formation of membrane (→ Fig. 1).

### Diabetic Minipigs with Mechanically Created Chronic Wounds

After approval from the Institutional Animal Care and Use Committee (DGMIF-16102001-00), we used two male minipigs (Apures, Gyeong-gi, Korea) that were at least 6 months



**Fig. 1** Amnion-conjugated chitosan-alginate membrane.

old and weighed less than 20 kg. Minipigs are generally considered to be sufficiently mature after secondary sexual development at 6 months of age. Hence, we determined that 6-month-old pigs were suitable for our experiments. The pigs did not have any apparent skin diseases or any noticeable soft tissue abnormalities. To control excessive growth and facilitate convenient examination of the wound contraction process, we controlled the diet of the pigs throughout the experiment. During the experiment, each pig was housed in a separate cage and fed 400 g of standardized gamma-irradiated diet and 3 L of water per day. The housing facilities and laboratory were maintained at  $22 \pm 3^\circ\text{C}$  with a relative humidity of  $50 \pm 20\%$ .

To create a diabetic swine model, we induced hyperglycemia in the minipigs by administering an intravenous injection of streptozotocin (STZ; 150 mg/kg; Sigma-Aldrich, MO) after 12 hours of fasting. The serum glucose level of each pig was measured regularly after STZ administration and the pigs were treated with subcutaneous injection of insulin as needed. An intravenous glucose tolerance test (IVGTT) (0.5 g glucose/kg) was used to confirm glucose intolerance 14 days before wound creation.<sup>7</sup>

To create wounds, the pigs were anesthetized by intramuscular administration of 5 mg/kg tiletamine-zolazepam (Zoletil; Virbac S.A., Carroscedex, France) and 2 mg/kg xylazine hydrochloride (Rumpun; Bayer HealthCare, Leverkusen, Germany), intubated and maintained under anesthesia with 1.5 to 2.0% isoflurane (Foran; Choongwae Pharmaceutical Corporation, Gyeong-gi, Korea). After shaving, twelve  $3 \times 3 \text{ cm}^2$  sized square-shaped wounds were created on the backs of the pigs at the muscle fascia level. Each wound was positioned 5 cm from the next closest wound. The 12 wounds were randomly grouped into the control group ( $n=4$ ), CS group ( $n=4$ ), and amnion-CS (AC) group ( $n=4$ ). Each group was dressed with gauze only, CS membrane with gauze on top, and AC membrane with gauze on top, respectively. Identical wound groupings and dressings were performed on both pigs ( $\rightarrow$  Fig. 2). There were 8 wounds in each group, and each wound was dressed every 3 days. The dressing material was reapplied every 3 days.

### Measurement of Wound Contraction

Clinical photographs were taken every 7 days with a metric ruler for calibration. The edge of epithelialization was defined as the wound margin and was used to calculate wound size. Each photograph was calibrated to the actual metric size using Adobe Photoshop software (Adobe Systems Inc., CA). The outline of the wound was drawn along the edge of epithelialization, and the area of the wound surface was calculated.

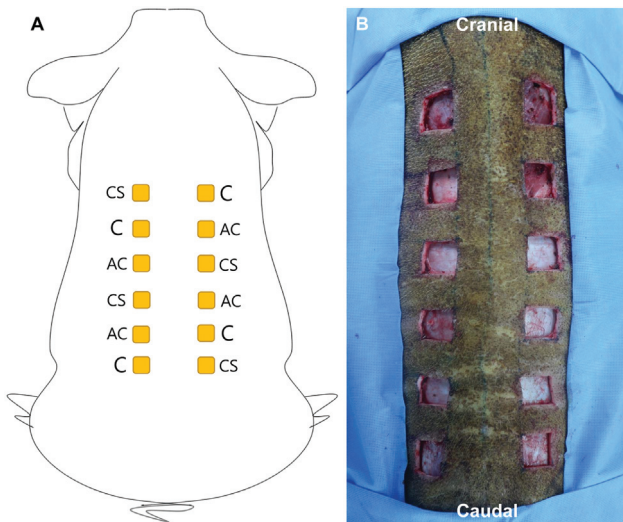
### Analysis of Wound Perfusion Using Indocyanine Green Dye Angiography

We measured granulation tissue perfusion every 7 days using indocyanine green (ICG) dye angiography (LifeCell SPY-Elite, NJ). Upon intravenous administration of 1 mL dose of ICG diluted to 2.5 mg/mL with normal saline provided by the IC-Green pack (LifeCell, NJ), ICG binds quickly and strongly to plasma proteins. The scanning head of the angiography device emits light at the near-infrared wavelength of 806 nm, causing ICG to fluorescence at 830 nm, which is recorded in real time with an ICG camera. The distance between the scanning head and the wound bed was standardized by the 2-laser focus system. The laser was positioned 50 to 100 cm from each wound area. As indicated by the device manufacturer, fluorescence recording began immediately before administration of the dye. The recording was performed at the rate of 7.5 frames per second, with a total scan time of 90 seconds per wound bed.

The degree of tissue perfusion was determined as the median value of three measurements at hottest spot of each wound. These values were then normalized to the percentage of normal perfusion, which was determined by taking an average of 10 measurements of normal perfusion along the proximal paramedian margin of each wound.

### Histological Analysis

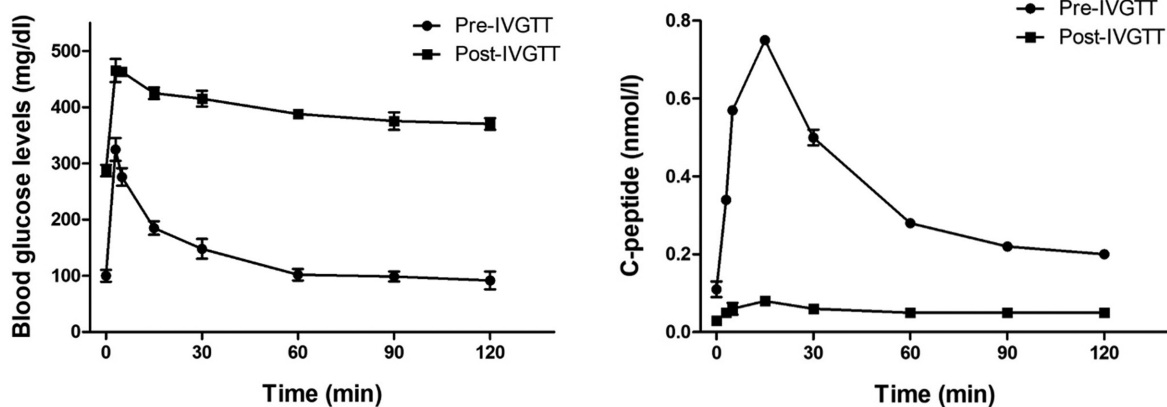
Tissue biopsy was performed every 7 days for up to 4 weeks after the creation of the wound. For each wound, four  $5 \times 5 \text{ mm}$  sized full-thickness skin biopsies were obtained from the center of each sides of the square-shaped wound. Samples were fixed using 10% neutral-buffered formalin, embedded in



**Fig. 2** Wound group design. (A) Twelve  $3 \times 3 \text{ cm}^2$  sized square-shaped wounds (yellow boxes) were created on the backs of the minipigs at the muscle fascia level. AC, amnion-chitosan group; C, control group; CS, chitosan group. (B) A clinical photo was taken after the initial creation of the wound.

paraffin, and cut into  $4\text{-}\mu\text{m}$  sections. Tissue sections were stained with hematoxylin and eosin for general histological analysis. To identify neovascularization in the specimens, immunohistochemistry was performed using standard methods with anti-CD31 antibodies (ab28364, Abcam, USA).

Histological analysis was performed by a pathologist who was blinded to the experimental protocol. The severity of acute and chronic inflammation was graded using light microscope at  $50\times$ ,  $100\times$ , and  $200\times$  magnifications (mild, 1; moderate, 2; severe, 3). The numbers of neutrophils and eosinophils were used as markers for the severity of acute inflammation, and the numbers of lymphocytes, plasma cells, and giant cells were used as markers for the severity of chronic inflammation. The extent of inflammation was determined by proportional estimates visible at  $50\times$  magnification: 0 (0%), 1 (10–50%), 2 (50–80%), and 3 (80–100%).



**Fig. 3** Intravenous glucose tolerance test. Blood glucose levels before and after streptozotocin administration (left). C-peptide levels before and after streptozotocin administration (right).

Inflammation scores were then calculated by multiplying severity and extent.

### Statistical Analysis

The results were analyzed by the Kruskal–Wallis test with Dunn's post hoc test using GraphPad Prism 5 (GraphPad Software Inc., CA) and are presented as the median with interquartile range. Values of  $p < 0.05$  were considered statistically significant.

## Results

### Serum Glucose Levels of Streptozotocin-Induced Diabetic Minipigs

Both of our diabetic minipigs maintained their diabetic metabolic state throughout the observation period. Pigs 1 and 2 showed the expected hypoglycemia on day 1 after STZ administration, with serum glucose levels of 43 and 74 mg/dL, respectively. From then on, the serum glucose levels showed a marked increase in both pigs, reaching 591 mg/dL on day 50 and 600 mg/dL on day 49. Serum glucose and C-peptide levels before and after STZ administration showed markedly distinct values after IVGTT (►Fig. 3). After STZ administration, fasting blood glucose level measured near 300 mg/dL and maintained around 400 mg/dL for 120 minutes after glucose administration. Likewise, no marked increase in C-peptide level was observed in pigs treated with STZ upon glucose administration.

### Concentrations of Growth Factors Eluted from Bovine Amniotic Powder

EGF, FGF-2, and KGF are the major growth factors that are crucial to wound contraction and reepithelialization.<sup>8</sup> The mean concentrations of EGF, FGF-2, and KGF in the amniotic powder elution were  $52.24 \pm 4.59$ ,  $411.57 \pm 37.43$ , and  $45.18 \pm 2.23 \text{ pg}/\mu\text{g}$ , respectively. Similar to previous investigations, the amniotic membrane, in the form of a powder, had the ability to elute growth factors in our experiment.



**Table 1** The result of HaCaT cell scratch closure test at different concentrations of amniotic powder

Concentration (mg/mL)	0.0	0.1	0.3	1.0	3.0	10.0	30.0
Cell gap distance ( $\mu\text{m}$ )	437.5	500	437.5	312.5	437.5	406.3	437.5
Cell-free gap closure rate (%)	12.5	0	12.5	37.5	12.5	18.7	12.5

Note: The data presented above is the result at 6 hours after scratching.

### Bovine Amniotic Powder Promotes the Migration of HaCaT Cells

To evaluate the effects of bovine growth factors on HaCaT cells, we performed a scratch assay. The cell-free gap was completely closed after 24 hours of incubation in the control and all AME-treated plates. After 6 hours of incubation, the narrowest cell-free gap was observed in cells cultured with 1.0  $\mu\text{g/mL}$  AME, indicating greatest migration of HaCaT cells. The results of the scratch test assay are detailed in **Table 1**.

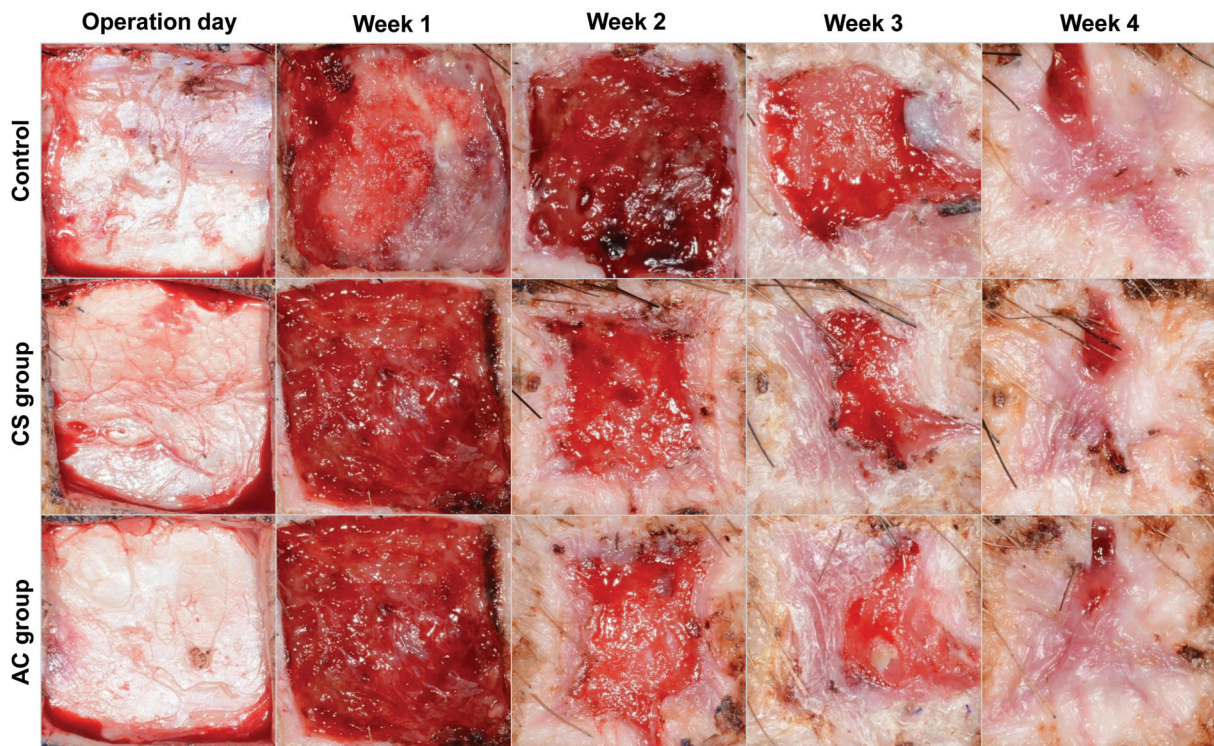
### Wound Contraction and Reepithelialization

Wound contraction and reepithelialization began 2 weeks after wound creation in the CS and AC groups, which was in contrast to the control group, which had delayed wound contraction and reepithelialization. In week 3, there was a gross difference in the reepithelialization of the CS and AC groups compared with the control group, which demonstrated the beginning of reepithelialization at week 3. Wound contraction and reepithelialization were nearly complete in all groups by week 4 (**Fig. 4**).

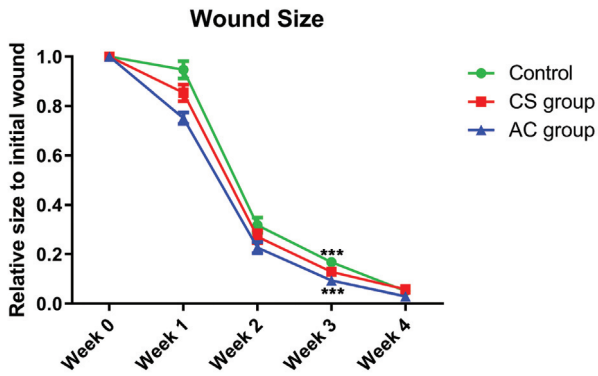
The relative size of the wound each week compared with the initial wound is shown in **Fig. 5**. All groups demonstrated an obvious decrease in wound size between week 1 and week 2. At week 3, the AC group wounds were significantly smaller than the control group wounds ( $p < 0.001$ ). Although the wound size was significantly different between the CS and AC groups at week 4 ( $p < 0.05$ ), this result was not worthwhile because all wounds demonstrated nearly complete wound healing.

### Histological Results

The degree of inflammation was determined by the number of infiltrating inflammatory cells. The AC group showed a slight decrease in the degree of acute and chronic inflammation at week 2. Nevertheless, we could not find a significant difference between each group regarding acute and chronic inflammation. There was slightly increased observation of vascular structures and endothelial cells in the AC and CS group, in comparison to the control group, in week 2 and 3 (**Fig. 6**). The median scores of acute and chronic



**Fig. 4** Wound contraction and reepithelialization. A wound photo was taken every week after the initial creation of the wound. The CS group was treated with chitosan and a secondary gauze dressing; the AC group was treated with an amnion-conjugated chitosan-alginate membrane and a secondary gauze dressing; and the control group was dressed with a gauze dressing only. Wound healing initiated earlier in the CS and AC groups than in the control group, as observed in week 2. The degree of wound contraction and reepithelialization was visibly different between the groups in week 3. By week 4, all three groups had nearly completed wound contraction and reepithelialization. AC, amnion-chitosan; CS, chitosan.



**Fig. 5** Relative wound size. The size of the wound was measured by measuring the surface area of the wound as outlined by the edge of epithelialization. The average surface areas of all wounds in each group were measured and compared between the groups. The size of the wound is demonstrated as a relative value to the initial wound size. At week 3, the amnion-chitosan (AC) group showed a smaller wound size than the control group (\*\* $p < 0.001$ ).

inflammation were not significantly different between the groups (► **Table 2**).

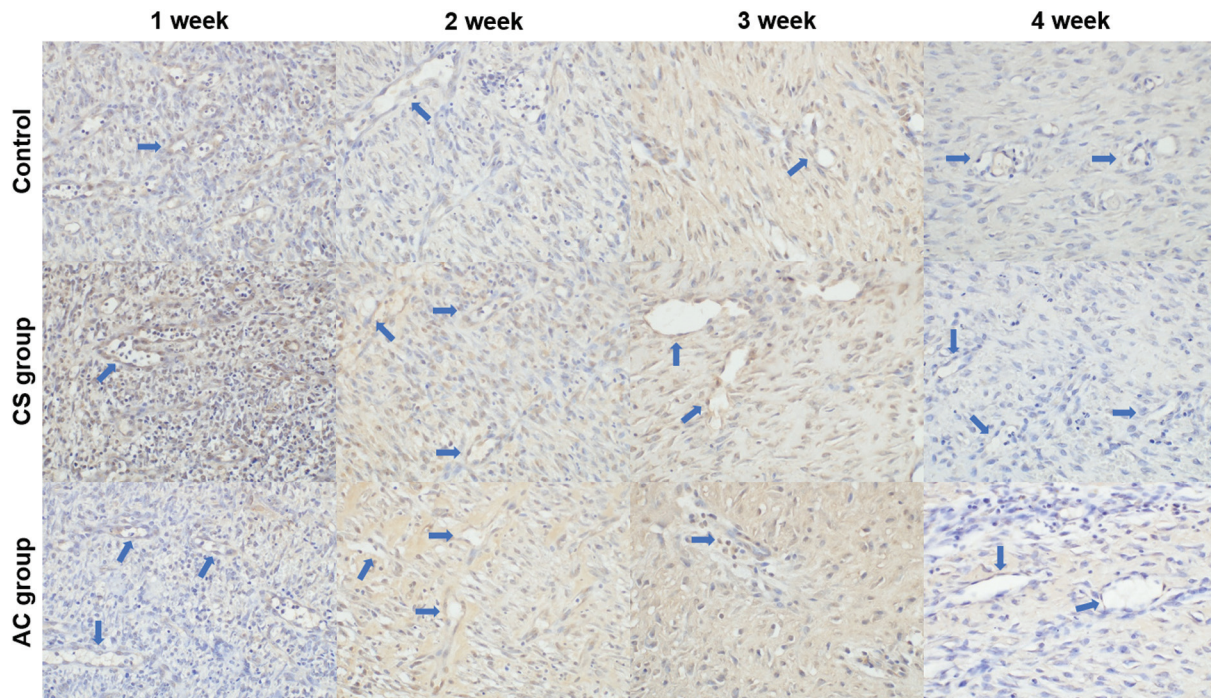
### Wound Perfusion

Wound perfusion was determined with an ICG angiography device, and the amount of fluorescence calculated by SPY-Q software is demonstrated in ► **Fig. 7**. At week 1, the AC group showed 152% normal tissue perfusion, while the control and CS groups showed 75 and 68%, respectively. At week 2, the CS group showed the highest perfusion of all three groups, which

was 151% that of normal tissue perfusion. By week 3, the AC group caught up, showing 227% normal tissue perfusion. At week 4, both the control and CS groups showed a slight decrease in tissue perfusion, while the AC group was further elevated to 302% normal perfusion.

### Discussion

Diabetic wounds demonstrated delayed wound healing from hyperglycemia, a prolonged inflammatory response, impaired vascularity, and tissue hypoxia.<sup>9</sup> In particular, diabetic foot infections are a challenging issue because infected diabetic wounds have an increased risk of amputation compared with noninfected diabetic foot ulcers.<sup>10,11</sup> Physicians should assess the presence of infection when managing diabetic wounds and treat them with the appropriate antibiotics, debridement, and dressing materials.<sup>12</sup> CS has been proven to be a material that has antimicrobial effects and activates polymorphonuclear leukocytes to produce several growth factors that accelerate wound healing.<sup>13</sup> In a previous clinical study, CS was found to be a promising dressing material for faster wound healing in patients with chronic wounds, such as diabetic foot, pressure ulcers, and vascular ulcers.<sup>14,15</sup> Acylated CS fibers demonstrate a high absorbency ability of wound exudate, a faster healing time, and an increased pain relief effect in chronic wounds.<sup>14</sup> Our material was based on a woven CS fiber membrane that was additionally compounded with alginate to augment the absorbency of the wound exudate. Our results showed that wound healing in the CS and AC groups was faster than that of the control group through week 3, although only the AC group demonstrated a significant



**Fig. 6** Immunohistochemical staining of CD31 in each wound group ( $\times 200$  magnification). More vascular structures and endothelial cells were observed in both amnion-chitosan (AC) and chitosan (CS) groups in comparison to the control group. Blue arrows indicate vessel structures observed in each photo.

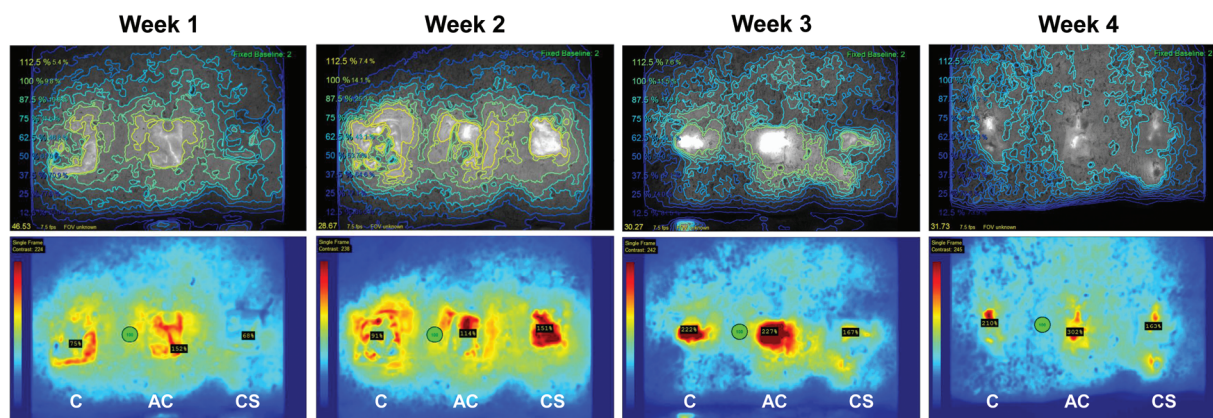


**Table 2** The acute and chronic inflammation score

Acute	Control	CS group	AC group
1 wk	3 (3 to 3)	3 (2 to 3)	3 (3 to 3)
2 wk	2 (2 to 3)	2 (2 to 2)	2 (1 to 2)
3 wk	0 (0 to 0.75)	0 (0 to 0.75)	0 (0 to 1)
4 wk	0 (0 to 0)	0 (0 to 0)	0 (0 to 0)
Chronic	Control	CS group	AC group
1 wk	2.5 (2 to 3)	2.5 (2 to 3)	3 (2 to 3)
2 wk	2 (2 to 2)	3 (2 to 3)	2 (1.25 to 2)
3 wk	1 (1 to 1.75)	1 (1 to 1)	1 (1 to 1)
4 wk	1 (1 to 1)	1 (1 to 1)	1 (1 to 1)

Abbreviations: AC, amnion-chitosan; CS, chitosan.

Note: The score is presented in median, first, and third quartile value.



**Fig. 7** Wound perfusion. The AC group showed a continuous increase in tissue perfusion compared with the control group. While the CS group showed the highest tissue perfusion at week 3, tissue perfusion was similar to that of the control group at weeks 3 and 4. AC, amnion-chitosan group; C, control group; CS, chitosan group.

difference compared with the control group at week 3. The CS group had reduced inflammation and an augmented healing rate in the gross and histological evaluations; nevertheless, we could not find a competent wound healing effect compared with the control group.

Human amniotic membranes have been used to manage various diseases, such as severe ocular injury, nerve injury, burns, and chronic wounds.<sup>16–19</sup> The wound healing potency of the human amniotic membrane is derived from its high concentration of various growth factors, including EGF, FGF-2, and KGF.<sup>20</sup> Despite their promising benefits for wound healing, there are many issues with human amniotic membranes, including limited donors and the dissemination of infectious diseases. To address these issues, a bovine amniotic membrane was introduced that has an analogous wound healing effect and EGF concentration compared with the human amniotic membrane according to previous research.<sup>21</sup> Recently, the freeze-dried bovine amniotic membrane used in the current study was reported to have a beneficial effect on reepithelialization in ablative wounds.<sup>22</sup> In our study, we used a powder form of a bovine amniotic membrane that was minced immediately after the freeze-drying process. We evaluated the elution level of growth factors from the amniotic powder because changes in

physical properties could influence the elution degree of the growth factors. The majority of the growth factors EGF, FGF, and KGF were also successfully eluted from amniotic powder in this study. Amniotic powder was spread on the CS-alginate membrane and contacted the wound surface to provide growth factors during the healing process. Our amnion-conjugated CS-alginate dressing material was designed to promote the wound healing rate from amniotic growth factors with the antibacterial effects of CS and the exudate absorptive effects of alginate. Therefore, the AC group demonstrated a faster wound healing rate after 3 weeks and improved angiogenesis on ICG angiography compared with the control group.

Momeni et al recently reported an amnion-based CS dressing that enhances epidermal and dermal regeneration.<sup>23</sup> An amnion-mixed CS gel was used in their investigation. Gel-type dressings can be difficult to handle during dressing and have the disadvantage of needing a secondary dressing. The difference in our investigation was that we used a diabetic wound on pigs as a typical chronic wound, while the previous investigation used burn wounds on rats as a typical acute wound. While the rodent demonstrated marked wound contraction during wound healing on the panniculus carnosus, the pigs demonstrate similar wound

healing compared with humans because of the analogous anatomical and physiological structure of the skin.<sup>24</sup> Furthermore, a new point in our research was that the amnion-conjugated CS-alginate dressing demonstrated a favorable effect on diabetic wounds. Our dressing material was also produced as a membrane structure that is easy to handle and does not require a secondary dressing.

In conclusion, we reported, for the first time, the application of an amnion-conjugated CS-alginate membrane dressing in a pig diabetic wound model. Our dressing material enhanced both the wound healing rate and angiogenesis compared with the control group. According to our results, this amnion-conjugated CS-alginate dressing could be a favorable dressing option for diabetic wounds. However, future clinical studies will need to strengthen the results of the current study.

#### Author Contributions

W.J. conceived the study, performed the experiments, provided the experimental design, analyzed the data, and wrote the manuscript. J.H. conceived the study, analyzed the data, edited figures, and wrote part of the manuscript. M.J. designed and manufactured the experimental materials. M.J. and S.A. performed the animal experiments and analyzed the data of wound perfusion. T.J. wrote part of the manuscript. S.K. performed and analyzed the histologic experiments and revised the manuscript. D.S. provided the concept of the experiment, analyzed the data, and wrote the manuscript.

#### Ethical Approval

The animal experiments in the study were approved by the Institutional Animal Care and Use Committee (DGMIF-16102001-00).

#### Prior Presentation

This study was presented at PRS KOREA 2020 held online on November 13, 2020.

#### Funding

This work was supported by a research-promoting grant from Keimyung University Dongsan Medical Center, in 2013.

#### Conflict of Interest

None declared.

#### References

- Saeedi P, Petersohn I, Salpea P, et al; IDF Diabetes Atlas Committee. Global and regional diabetes prevalence estimates for 2019 and projections for 2030 and 2045: results from the International Diabetes Federation Diabetes Atlas, 9th edition. *Diabetes Res Clin Pract* 2019;157:107843
- Boulton AJ, Vileikyte L, Ragnarson-Tennvall G, Apelqvist J. The global burden of diabetic foot disease. *Lancet* 2005;366(9498):1719–1724
- Hosseinnejad M, Jafari SM. Evaluation of different factors affecting antimicrobial properties of chitosan. *Int J Biol Macromol* 2016; 85:467–475
- Singh R, Shitiz K, Singh A. Chitin and chitosan: biopolymers for wound management. *Int Wound J* 2017;14(06):1276–1289
- Bischoff M, Stachon T, Seitz B, et al. Growth factor and interleukin concentrations in amniotic membrane-conditioned medium. *Curr Eye Res* 2017;42(02):174–180
- Qi M, Zhou Q, Zeng W, et al. Growth factors in the pathogenesis of diabetic foot ulcers. *Front Biosci* 2018;23:310–317
- Grüssner R, Nakhleh R, Grüssner A, Tomadze G, Diem P, Sutherland D. Streptozotocin-induced diabetes mellitus in pigs. *Horm Metab Res* 1993;25(04):199–203
- Bae JE, Kim CK, Kim SP, Yang EK, Kim IS. Process development of a virally-safe acellular bovine amniotic membrane for biological dressing. *Microbiol Biotechnol Lett.* 2010;38(04): 420–427
- Mesa MG, Duarte HÁ, Carretero JH, López MM, Vilas MM. De Marco Formula effectiveness as an adjunctive therapy to prevent infected ischemic diabetic foot amputation and reduce plasma fibrinogen. *J Tissue Viability* 2011;20(02):67–72
- van Battum P, Schaper N, Prompers L, et al. Differences in minor amputation rate in diabetic foot disease throughout Europe are in part explained by differences in disease severity at presentation. *Diabet Med* 2011;28(02):199–205
- Lipsky BA. Medical treatment of diabetic foot infections. *Clin Infect Dis* 2004;39(Suppl 2):S104–S114
- Baltzis D, Eleftheriadou I, Veves A. Pathogenesis and treatment of impaired wound healing in diabetes mellitus: new insights. *Adv Ther* 2014;31(08):817–836
- Sahana TG, Rekha PD. Biopolymers: applications in wound healing and skin tissue engineering. *Mol Biol Rep* 2018;45(06): 2857–2867
- Mo X, Cen J, Gibson E, Wang R, Percival SL. An open multicenter comparative randomized clinical study on chitosan. *Wound Repair Regen* 2015;23(04):518–524
- Totsuka Sutto SE, Rodríguez Roldan YI, Cardona Muñoz EG, et al. Efficacy and safety of the combination of isosorbide dinitrate spray and chitosan gel for the treatment of diabetic foot ulcers: a double-blind, randomized, clinical trial. *Diab Vasc Dis Res* 2018; 15(04):348–351
- Zhang ZY, Yang J, Fan ZH, et al. Fresh human amniotic membrane effectively promotes the repair of injured common peroneal nerve. *Neural Regen Res* 2019;14(12):2199–2208
- Eslani M, Baradaran-Rafii A, Cheung AY, Djalilian AR, Holland EJ. Amniotic membrane transplantation in acute severe ocular chemical injury: a randomized clinical trial. *Am J Ophthalmol* 2019;205:203
- Ilic D, Vicovac L, Nikolic M, Lazic Ilic E. Human amniotic membrane grafts in therapy of chronic non-healing wounds. *Br Med Bull* 2016;117(01):59–67
- Adly OA, Moghazy AM, Abbas AH, Ellabban AM, Ali OS, Mohamed BA. Assessment of amniotic and polyurethane membrane dressings in the treatment of burns. *Burns* 2010;36(05):703–710
- Koizumi NJ, Inatomi TJ, Sotozono CJ, Fullwood NJ, Quantock AJ, Kinoshita S. Growth factor mRNA and protein in preserved human amniotic membrane. *Curr Eye Res* 2000;20(03):173–177
- Park M, Kim S, Kim IS, Son D. Healing of a porcine burn wound dressed with human and bovine amniotic membranes. *Wound Repair Regen* 2008;16(04):520–528
- Min S, Yoon JY, Park SY, Kwon HH, Suh DH. Clinical effect of bovine amniotic membrane and hydrocolloid on wound by laser treatment: prospective comparative randomized clinical trial. *Wound Repair Regen* 2014;22(02):212–219
- Momeni M, Zarehaghghi M, Hajimiri M, et al. In vitro and in vivo investigation of a novel amniotic-based chitosan dressing for wound healing. *Wound Repair Regen* 2018;26(01):87–101
- Seaton M, Hocking A, Gibran NS. Porcine models of cutaneous wound healing. *ILAR J* 2015;56(01):127–138