



# The Effect of Customized and Silicon Insoles on Mid- and Hindfoot in Adult Flexible Pes Planovalgus

Amit Kumar Vimal<sup>1</sup> · Shivani Sharma<sup>1</sup> · Bindu Gahlawat<sup>2</sup> · G. Pandian<sup>1</sup> · Sumit Sural<sup>3</sup>

Received: 1 December 2021 / Accepted: 2 July 2022 / Published online: 20 July 2022  
© Indian Orthopaedics Association 2022

## Abstract

**Background** Flexible flat foot or pes planovalgus is a common foot deformity, and silicone and customized insole are commonly used as a non-operative treatment modality of flexible planovalgus. However, there are inadequate data and limited evidence available regarding the immediate effects of their use in midfoot and hindfoot of adults. The aim of this study is to quantify and compare the radiological parameters immediately on weightbearing with silicon and customized insoles and without them to assess the effect on midfoot and hindfoot of the flexible planovalgus in adults.

**Methods** A total number of 11 (8 females and 3 males) subjects with flexible pes planovalgus deformity without any other foot deformity were included in the study. Each patient was assessed three times in a random sequence without and with use of either silicon insoles or customized insole. The radiographic parameters without insole, with silicon insole, and with customized insole conditions were calculated using online available computer software Kinovea.

**Results** One-way ANOVA analysis was performed between groups (without insole, with silicone insole and with customized insole). The hindfoot parameters depicted that calcaneal inclination angle (CIA) was significant increased ( $P=0.000$ ) and talar declination angle (TDA) was significantly decreased ( $P=0.003$ ) only with the use of customized insole compared to without insole. The midfoot parameters depicted that the first metatarsal angle (FMA) and talonavicular coverage angle (TCA) were significantly lower with customized insole ( $P=0.00$ ) as compared to other two groups and significantly lower with silicone insole ( $P=0.00$ ) as compared to without insole group.

**Conclusion** The results imply that the compressibility of the insole material affects the forefoot and hindfoot biomechanics differently. This study concludes that silicone insole affects only the midfoot which bears 45% of bodyweight and customized insole affects both midfoot and more importantly the hindfoot which bears 55% of bodyweight.

**Keywords** Customized insole · Silicon insole · Flat foot · Pes planus

---

Amit Kumar Vimal and Shivani Sharma contributed equally.

✉ Amit Kumar Vimal  
akvimalpo@gmail.com

- <sup>1</sup> Department of Orthotics and Prosthetics, Pt. Deendayal Upadhyaya National Institute for Persons With Physical Disabilities (Divyangjan), 4-Vishnu Digambar Marg, New Delhi 110002, India
- <sup>2</sup> Student at Department of Orthotics and Prosthetics, Pt. Deendayal Upadhyaya National Institute for Persons With Physical Disabilities (Divyangjan), New Delhi, 110002, India
- <sup>3</sup> Department of Orthopedic, Maulana Azad Medical College and Lok Nayak Hospital, New Delhi, India

## Introduction

The foot is a complex structure that plays an important role in support, balance and propulsion. Pes planus (flatfoot) is one of the most common foot's deformities observed in adult health persons. The true prevalence of flatfoot is unknown, primarily because there is no consensus on the strict clinical or radiographic criteria for defining a flatfoot. In a study of 3619 Royal Canadian Army subjects, 15% were reported to have a simple hypermobile flatfoot, 6% had a simple hypermobile flatfoot with a tight heel cord, and 2% had a tarsal coalition [1]. Flexible flatfoot is defined as a foot deformity, in which the medial longitudinal arch becomes flat during standing and weight bearing position where the foot is in valgus, external rotation and dorsiflexion relative to the talus [2, 3]. Flatfoot deformity is classified into two subtypes,

rigid and flexible [4]. Flexible flatfoot is characterized by a normal arch during non-weight bearing and a flattening of the arch during stance. Conversely, a rigid flatfoot is characterized by a stiff, flattened arch on and off weightbearing positions [5].

Various non-surgical procedures have been performed for the treatment of symptomatic flexible flatfoot [6]. The non-operative options include various exercises such as towel curl exercises, short foot exercises and also neuromuscular electrical stimulation [7, 8]. Foot orthoses are also frequently prescribed in non-operative treatment for the flexible flatfoot. The insoles with arch supports are available in both silicon or customized form made of various materials. Silicon arch supports are a commonly used treatment option as it is readily available and cost-effective. Some of these are medially posted silicon arch supports [9], Sofsole insoles [10], Orthofeet Biothotics [11] and commercially available silicon-filled arch supports. The different materials used for fabricated customized arch supports include ethyl vinyl acetate (EVA), polypropylene, and polyurethane. Hsieh reported that children with flexible flatfoot who wore customized EVA insoles with arch support for 12 weeks exhibited significantly improved pain/comfort, physical health, stair ascent time, upper extremity and physical function, and transfer and basic mobility [12]. Various other studies report that insoles with medial arch supports promote radiographic improvement in pediatric flexible flat foot [13] as well as other beneficial effects [14–16].

There are various diagnostic techniques used for assessment of flatfoot. These include various visual means like the tiptoe examination and shoe inspection test and documentation by wet footprint test. Magnetic resonance imaging (MRI) and computed tomography (CT) [17] also help in the diagnosis of flatfoot but these are unfortunately quite expensive as compared to other easily available methods. Radiographs of the foot are commonly used to evaluate adult foot deformities with specific radiographic indices to quantify them. The reliability of these indices in normal subjects or subjects with specific diseases has been reported by Evans et al. [18]. The lateral and anteroposterior radiographic views in weightbearing conditions help to assess arch collapse. Radiographic indices such as navicular index, calcaneal inclination angle, talar declination angle, first metatarsal angle and talonavicular coverage angle are standard methods to determine the magnitude of pes planus [19]. As compared to other investigations, radiological assessment of the foot is continued to be used universally [20] due to its low cost and ease of availability.

During the gait cycle when bodyweight is transferred on the foot, the pressure is distributed more on the hindfoot bones of talus and calcaneus (approximately 55%) compared to the midfoot tarsal and forefoot metatarsal bones [21]. There is a paucity of data regarding the evaluation

of differential distribution of body weight on the foot in people having flexible pes planovalgus with the use of different types of insoles. There is a lacuna in the literature regarding analysis of the immediate effect of weight bearing using customized and silicone insoles on the midfoot and hindfoot kinematics in flexible pes planus. The calcaneal inclination angle and talar declination angle are measured to analyze hindfoot kinematics, while the first metatarsal angle and talonavicular coverage angle assess the midfoot kinematics on weight bearing with and without insoles. This study was designed to determine the quantitative kinematic comparison of the immediate effect of weight bearing using customized and silicone insoles on the midfoot and hindfoot in persons with flexible pes planovalgus deformity for better treatment options. Based on previous studies that report a positive effect in the pes planovalgus [9, 12, 14–16], this study hypothesizes that both types of insoles would show the positive effect in order to correct the midfoot and hindfoot angles in the pes planovalgus. The silicon insole used in this study was an off the shelf commercially available insole, with the material composed entirely of silicon. In contrast, the customized insoles were fabricated with polypropylene sheet, covered with ethaflex sheet. This study employed a modified casting procedure for customized insole, which is explained in “Methods”.

## Methods

### Participants

The institutional review board approved this study. The study group members included an orthopedic surgeon who marked the appropriate points on the radiographs for subsequent calculation of various angles using a computer software Kinovea (0.8.15) version in degree. Kinovea is a video player used for sports analysis, available as an open source and is entirely free of cost. It provides tools to capture, slow down, study, compare, annotate, and measure technical performances. It is organized around four core missions related to studying human motion: capture, observation, annotation and measurement. The software easily measures distances and angles using line, angle and goniometer tools.

After informed consent, adult subjects who visited the study center with flexible pes planus were selected in whom the medial longitudinal arch of their foot in a non-weight bearing sitting position disappeared on weight bearing standing position [22]. Among them, the inclusion criteria were restricted to cases where the navicular index [23], had a value of more than 6.7407 [19]. Subjects excluded from the study were those with a history of foot injury or surgery; foot abnormalities affecting locomotion or foot mobility;

developmental delays such as developmental coordination disorder and neurological deficits, and rigid flat foot.

A total number of 11 subjects (10 bilateral and 1 unilateral) were included in the study, out of which 3 were male and 8 female, between the age of 18 to 38 years with an average age of  $20.63 \pm 2.69$  years and a mean body weight of  $62.09 \pm 3.13$  kg as shown in Table 1. The silicon and customized insoles were given to the subjects randomly (Fig. 1). A commercially available silicon insole was selected based on the patient's foot size, which consisted of a flat silicone insole and an appropriate sized silicone piece pasted at the site of the medial arch. The customized insole was made using a specific casting procedure (explained in subsection fabrication of customized insoles) and draping the

polypropylene sheet (2 mm) and ethaflex foam (3 mm) over the modified mould of the foot. Each subject was assessed in a random sequence under three different conditions; with the use of silicone insole, customized insole and without any insole. A prospective parallel group design was conducted to analyze the difference in radiographic parameters between these three groups.

### Protocol of Study

Radiographs (X-ray) were taken, both anteroposterior and medial–lateral views in weight bearing position. Each individual performed all the three steps (without insole, with silicone insole and with customized insole) under constant supervision, and the data were recorded vigilantly. The data collection was carried out in a safe visual and acoustic environment. Before carrying out the process, the subjects were given 4–8 min to be prepared for the radiographs. The required radiographic views (anteroposterior and medial–lateral) were thoroughly explained to the subjects for acquiring accurate information. The subjects were not under any stress or anxiety during the entire process. The radiographs were taken after proper shielding of the torso with a lead apron.

### Fabrication of Customized Insoles

The standard casting procedure consists of an initial negative mould made of plaster of Paris bandages on the plantar surface of the foot in the non-weight bearing position with the hindfoot locked in a neutral subtalar position with the midtarsal joint pronated [24]. The negative mould is subsequently used to create a 'positive mould' of the foot with

**Table 1** Demographical data of subjects with flat foot

S. no. of subject	Age (years)	Gender	Weight (Kg)	Navicular index
1	21	Male	60	8.3705
2	17	Female	63.5	8.4341
3	24	Female	61	7.3201
4	25	Female	59	11.0606
5	21	Male	62	8.4241
6	21	Female	67	8.5361
7	19	Female	65	7.7983
8	21	Female	60	6.7794
9	23	Female	62	8.9531
10	17	Female	66.5	8.3990
11	18	Male	57	7.8691
<b>Mean <math>\pm</math> SD</b>	<b><math>20.63 \pm 2.69</math></b>		<b><math>62.09 \pm 3.13</math></b>	<b><math>8.35 \pm 1.08</math></b>



**Fig. 1** Left, silicon insole and, right, customized insole

plaster of Paris and the medial arch is carved by removing the plaster at the site of the arch. The distance between the proximal edge of the first metatarsal head to the medial process of calcaneus represents the length of the arch. The distance from the most inferior aspect of the navicular bone to the horizontal supporting surface represents the height of the medial longitudinal arch [19]. This standard technique of carving of the medial arch is subject to error.

To reduce this error while creating a positive mould, a modified casting procedure was employed for the fabrication of a customized insole. This procedure is based on the knowledge of the ‘windlass mechanism’ that occurs during the late stance phase of the gait cycle due to the dorsiflexion of the metatarsophalangeal joint, which produces winding of the plantar fascia around the metatarsal head (or drum of the windlass). This winding of the plantar fascia pulls on the calcaneus, shortens and raises the arch [25]. A similar windlass mechanism was created during the casting procedure and the metatarsophalangeal joint was dorsiflexed during casting to create an arch along with plantar flexion of ankle joint (Fig. 2). Plantarflexion supinates the subtalar joint, which reduces the navicular drop and raises the arch [25]. This casting procedure generates an appropriate arch within the negative mould and reduces human error for carving the arch on a positive mould. Finally, the malted polypropylene sheet was draped on the positive mould to fabricate the insole and covered with an ethafoam sheet.

## Parameters

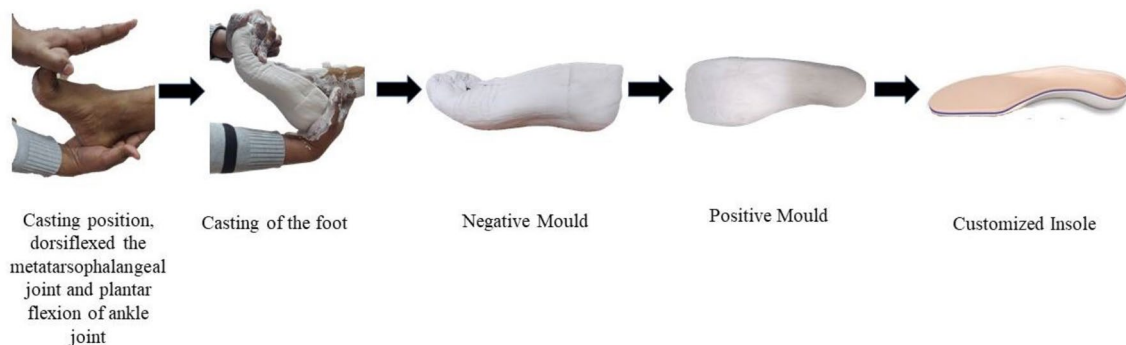
The data were analyzed for determining the value of the following parameters, i.e., without the insole, with silicon insole and with customized insole:

1. Navicular index (NI) [19]: navicular index is equal to the truncated foot length divided by the longitudinal distance of the inferior surface of the navicular from

the horizontal line of truncated foot length, as shown in Fig. 3. The navicular index below 6.7407 up to 5.48 defines a normal arch and above 6.7407 defines a pathological arch of flatfoot [19]:

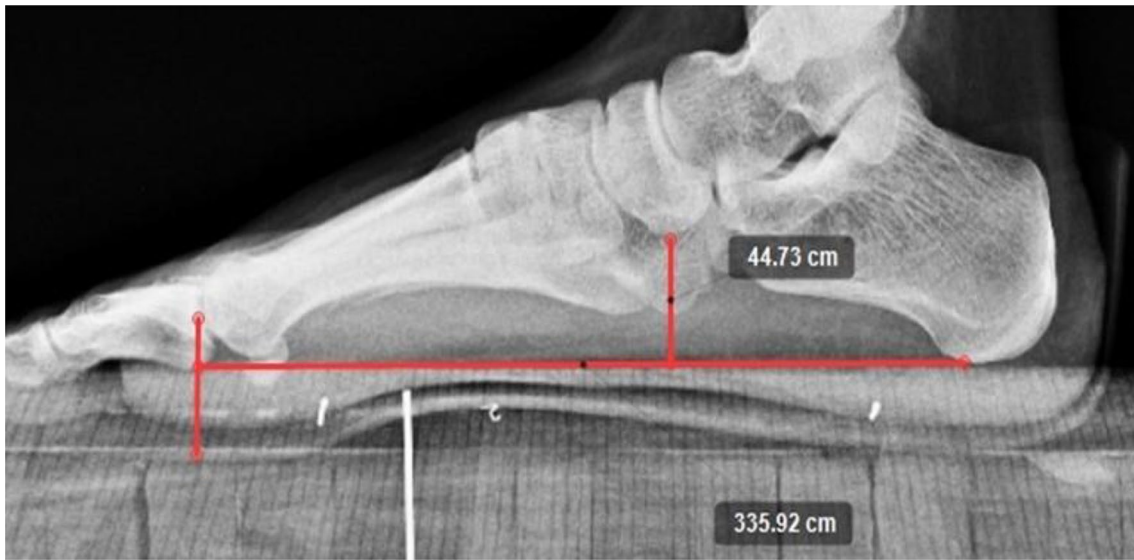$$\text{Navicular Index} = \frac{\text{Truncated foot length (TFL)}}{\text{Longitudinal distance of the navicular (LDN)}}$$

2. Calcaneal inclination angle or calcaneal pitch angle (CIA) [26]: CIA is an angle measured in the lateral view of a radiograph between the calcaneal inclination axis and the supporting surface and reflects the height of the foot framework and is also known as calcaneal pitch angle, as shown in Fig. 4a. In a normal arch of a foot, the CIA is 20–30° and this angle is increased in pes cavus, while it is decreased in pes planus.
3. Talar declination angle (TDA) [27]: TDA is the angle measured in the lateral view of a radiograph between a line bisecting through the body and neck of the talus and the supporting surface (normal approximately 21°), as shown in Fig. 4b. TDA is increased in pes planus and decreased in pes cavus.
4. First metatarsal angle or Meary’s Angle (FMA) [28]: FMA is the angle between a line drawn from the centers of longitudinal axes of the talus and the first metatarsal, in the lateral view of a radiograph as shown in Fig. 5a. The angle would be approximately 0° in a normal foot and an angle of up to 15° is considered to represent a mild pes planus; 15–30°, a moderate pes planus.
5. Talonavicular coverage angle (TCA) [29]: TCA is defined as the angle created by a line connecting the most medial and most lateral aspect of the articular surface of the navicular and a line connecting the most medial and most lateral articular surface of the talar head at the talonavicular joint in the anteroposterior view of a radiograph as shown in Fig. 5b. An angle of greater than 7° indicates lateral talar subluxation.

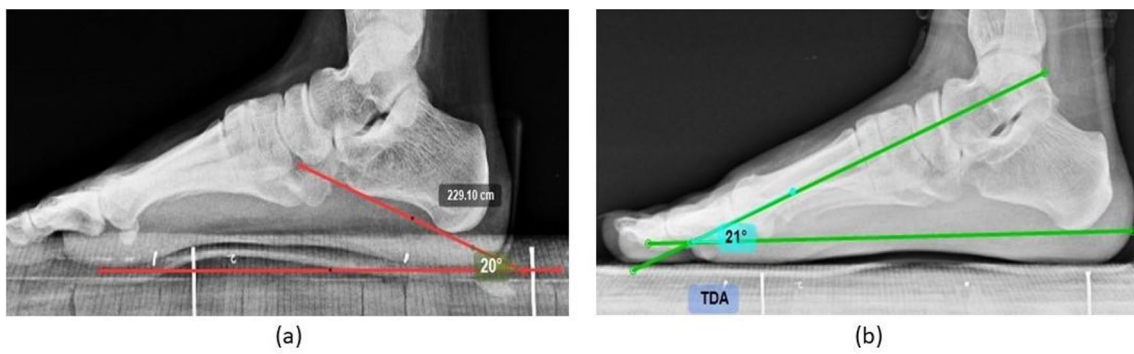


**Fig. 2** Procedure for fabrication of customized insole

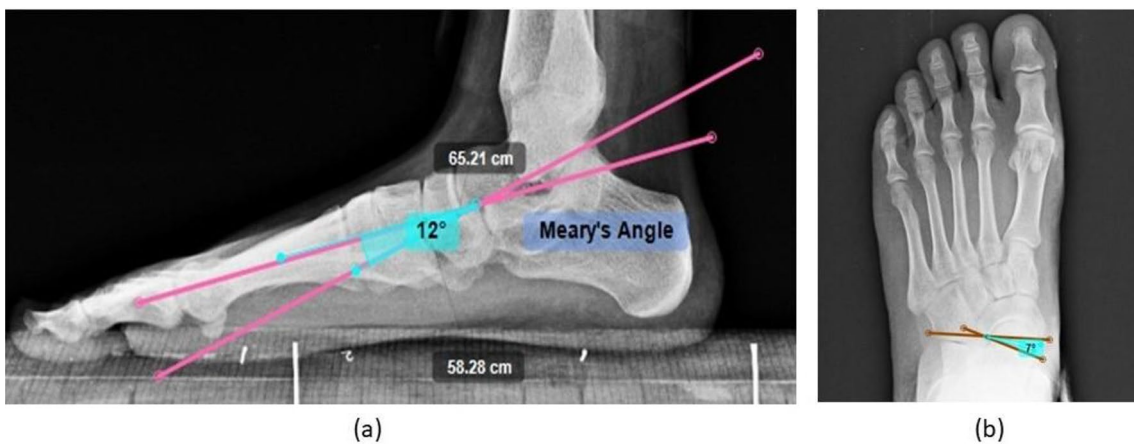




**Fig. 3** Medio-lateral view of the radiograph showing navicular index (navicular distance/truncated foot length)



**Fig. 4** Hind foot parameters: **a** medio-lateral view of the radiograph showing calcaneal inclination angle (CIA). **b** Medio-lateral view of the radiograph showing talar declination angle (TDA)



**Fig. 5** Mid-foot parameters: **a** medio-lateral view of the radiograph showing Meary's angle (first metatarsal angle). **b** Antero-posterior view of the radiograph showing talonavicular coverage angle (TCA)

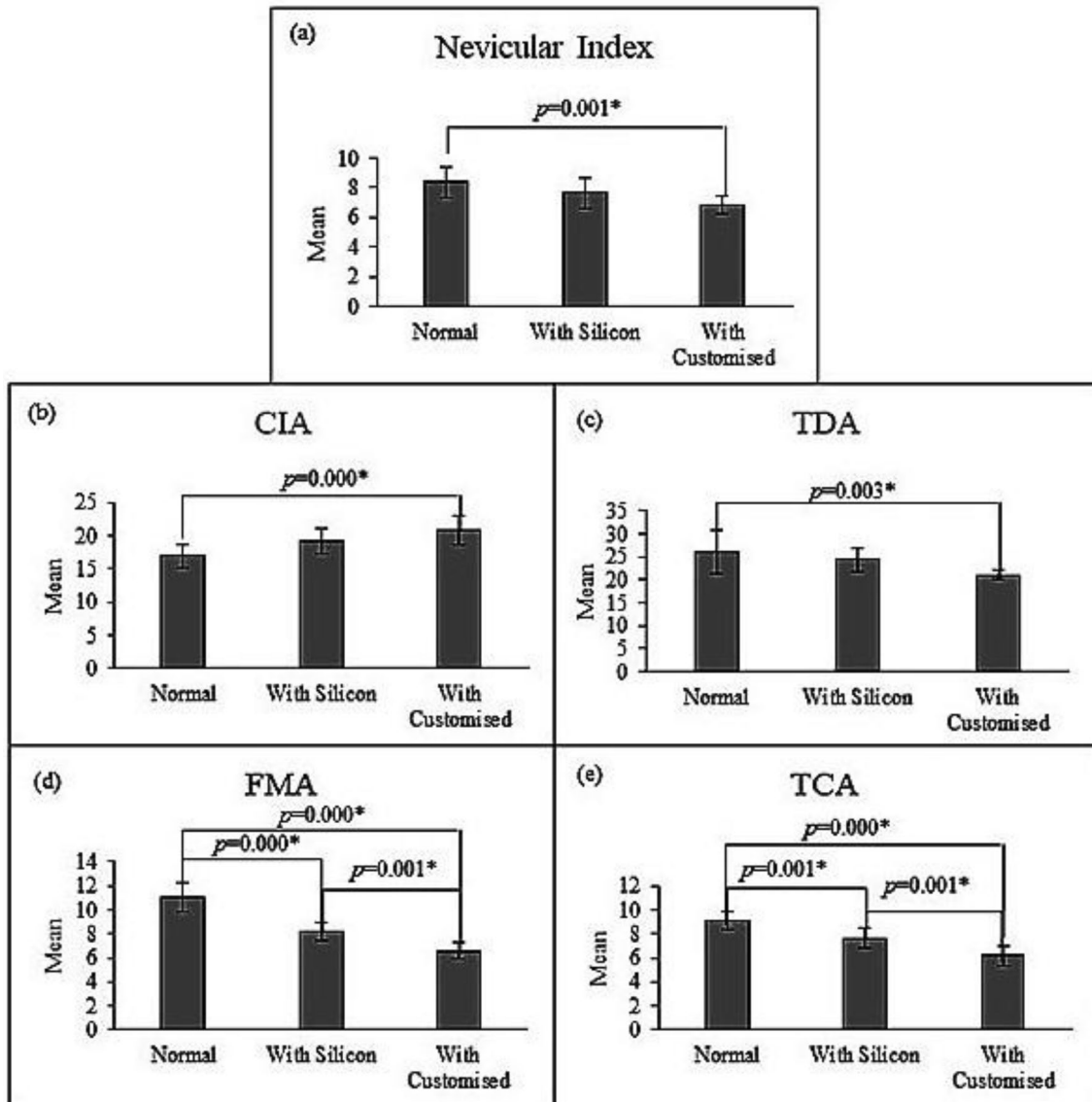
## Statistical Analysis

The statistical analysis was conducted using SPSS software (Version 21). One-way ANOVA analysis was performed between groups (without the insole, with silicone insole and with customized insole) compression, and the post hoc Bonferroni test was also performed within the group comparison.

## Results

### Navicular Index (NI)

The mean  $\pm$  SD value of the navicular index was found  $8.35 \pm 1.08$  in without insole group, whereas  $7.64 \pm 1.05$  in silicone insole group, and  $6.78 \pm 0.61$  in the customized



**Fig. 6** Comparison result of post hoc Bonferroni test between without insole, with silicon and with customized insole. **a** Navicular index, **b** calcaneal inclination angle (CIA), **c** talar declination angle (TDA), **d** first metatarsal angle (FMA), and **e** talonavicular coverage angle (TCA)

insole group. The ANOVA showed a significant difference [ $F(2,30) = 8.447, P = 0.001$ ] between the navicular index of the groups. Post hoc (Bonferroni) test showed that the navicular index was significantly lower with customized insoles than without insole ( $P = 0.001$ ), as shown in Fig. 6a.

### Calcaneal Inclination Angle (CIA)

The mean  $\pm$  SD value of the calcaneal inclination angle was found  $16.90 \pm 1.81^\circ$  in without insole group, whereas  $19.18 \pm 1.94^\circ$  in silicone insole group, and  $20.90 \pm 2.16^\circ$  in the customized insole group. The ANOVA showed a significant difference [ $F(2,30) = 11.308, P = 0.000$ ] between the CIA of the groups. Post hoc (Bonferroni) test showed that the CIA angle was significantly higher with silicone insole ( $P = 0.03$ ) and with customized insole ( $P = 0.00$ ) than without the insole, as shown in Fig. 6b.

### Talar Declination Angle (TDA)

The mean  $\pm$  SD value of the talar declination angle was found  $26.00 \pm 4.69^\circ$  in without insole group, whereas  $24.36 \pm 2.54^\circ$  in the silicone insole group, and  $21.09 \pm 1.04^\circ$  in the customized insole group. The ANOVA showed a significant difference [ $F(2,30) = 6.978, P = 0.003$ ] between the TDA of the groups. Post hoc (Bonferroni) test showed that the TDA was significantly lower with customized insole ( $P = 0.003$ ) than without the insole, as shown in Fig. 6c.

### First Metatarsal Angle (FMA)

The mean  $\pm$  SD value of the first metatarsal angle was found  $11 \pm 1.18^\circ$  in without insole group, whereas  $8.18 \pm 0.75^\circ$  in the silicone insole group, and  $6.54 \pm 0.68^\circ$  in the customized insole group. The ANOVA showed a significant difference [ $F(2,30) = 68.769, P = 0.000$ ] between the FMA of the groups. Post hoc (Bonferroni) test showed that the FMA was significantly lower with customized insole ( $P = 0.000$ ) than with silicone insole and without the insole, as shown in Fig. 6d.

### Talonavicular Coverage Angle (TCA)

The mean  $\pm$  SD value of the talonavicular coverage angle was found  $9.0 \pm 0.9^\circ$  in without insole group, whereas  $7.63 \pm 0.80^\circ$  in the silicone insole group, and  $6.18 \pm 0.87^\circ$  in the customized insole group. The ANOVA showed a significant difference [ $F(2,30) = 36.571, P = 0.000$ ] between the TCA of the groups. Post hoc (Bonferroni) test showed that TCA was significantly lower with customized insole ( $P = 0.000$ ) than with silicone insole and without the insole, as shown in Fig. 6e.

## Discussion

The purpose of this study was to evaluate the immediate effect of weight bearing on the arch of subjects using insoles (customized and silicon) in subjects having flexible pes planovalgus and compare the difference without insole and with each of the two insoles using radiographic parameters. This study found that customized insoles provide better corrective changes to pes planovalgus angles than silicon insole. This indicates that using a customized foot insole influences the radiological parameter in weightbearing better than a silicon insole.

The immediate effect of weight bearing on the navicular index (NI), calcaneal inclination angle (CIA), talar declination angle (TDA), first metatarsal angle (FMA) and talonavicular coverage angle (TCA) with customized insole showed positive changes as reported by Sinha et al. [30]. The CIA increased, while the NI, TDA, FMA and TCA decreased when the medial arch support was placed under the flat foot. The customized insole significantly increased the CIA and decreased the NI and TDA compared to without insole. The FMA and TCA were significantly decreased with both silicon and customized insoles. The result shows that the silicone and customized insole improve the arch height [31–35] by correcting the midfoot and hindfoot radiological parameters. The finding of this study implies that the medial arch support made of flexible material like silicone improves the medial arch by altering midfoot's radiological parameters (enhancing the 1st metatarsal height and increasing the talonavicular coverage area), which correspond to 45% weight of body [21]. However, the customized rigid insole improves the medial arch by altering hindfoot's radiological parameters (increasing CIA and decreasing TDA) along with midfoot's radiological parameters, which correspond to 55% weight of body [21]. Thus, to summarize, silicone insoles affect only the midfoot whereas customized insoles affect both mid and hindfoot. This result rejects the hypothesis that both insoles affect mid and hindfoot angles.

According to Hsieh [12] study, children with flexible flat-foot who wore customized arch support insoles for 12 weeks to maintain the subtalar joint in the neutral position exhibited significantly improved pain/comfort, physical health, stair ascent time, upper extremity and physical function, and transfer and basic mobility. Our study was conducted in adults due to the ethical issue of radiation exposure in children. Our study was designed to study the kinematic effect of weight bearing with different insoles which is likely to relieve foot pain, and a longitudinal study in future would need to be designed to assess the pain factor. Sinha et al. [30] correlated various foot angles and their respective American Orthopaedic Foot and Ankle Society (AOFS) scores for pain and their effectiveness of a medial arch insole and concluded

that medial arch support orthosis significantly improved AOFS scores.

A systematic review by Banwell [32] on foot orthoses for adults with flexible pes planus showed that in 59 studies, relevant outcome measures were reported with 17 calculated as statistically significant large or medium effects with the use of foot orthoses compared without them. The review also showed low-level evidence that foot orthoses improve pain, reduce rearfoot eversion, alter loading and impact forces and reduce rearfoot inversion and eversion moments in flexible pes planus. Our study contributes to evidence of altering loading and rearfoot inversion and eversion moments.

Overall, the availability of different commercially available silicon material in the rigid and flexible forms may differ the result. Generally, the pediatric population is the focus group for evaluating the changes in flexible pes planus rather than the adult population [13]. In addition, it is easier to choose silicon insoles or off the shelf orthoses because they are easily available and less expensive than customized insoles that take longer to fabricate and are more expensive. Therefore, there is less evidence of comparing the silicon and customized insoles through radiographical foot angles. The limitation of this study is: (i) children were excluded due to radiation exposure; (ii) subjects were not blinded during the complete evaluation process; hence, they were aware of what kind of insoles they were tested; (iii) since the X-ray generator is a stationary machine limited to a certain room, only static radiographs were taken; and (iv) the sample size is small due to COVID-19 pandemic.

Though radiographical angles were used to determine the immediate changes during weight bearing using different insoles, other factors such as pain, comfort, subject preference, and availability may also be needed to be considered in future studies. The comparison between insoles of different materials other than silicon can also be carried out in future. Rather than immediate changes, a long-term effect may be assessed in future.

## Conclusion

This study implies that the rigidity of the insole is also a factor in the effect of foot orthosis for pes planus. The results indicate that the compressibility of the insole material affects the forefoot and hindfoot biomechanics differently. Flexible medial arch support (silicone insole) increases the first metatarsal height with enhanced talonavicular coverage area, which is likely to alter the normal 45% of the weightbearing forces which occur in forefoot and midfoot. The customized rigid insole increases the CIA and decreases the TDA providing additional improvement of the hindfoot biomechanics where normally 55% of bodyweight is distributed. There

was a radiological improvement on immediate weightbearing with the use of customized insole compared to silicone insole, particularly in the hindfoot. This study concludes that the medial arch of the foot is not equally maintained by silicone and customized insole, since silicone insole affects only the midfoot and customized insole affects both midfoot and more importantly the hindfoot which bears 55% of bodyweight.

**Funding** The author(s) received no financial support for the research, authorship, and/or publication of this article.

## Declarations

**Conflict of Interest** The authors declare that they have no known competing financial interests or personal relationships that could have appeared to influence the work reported in this paper. The author(s) declared no potential conflicts of interest with respect to the research, authorship, and/or publication of this article. ICMJE forms for all the authors are available online.

**Ethical Approval** This study has been ethically approved by the institutional ethical board (Ref No: IEC9/2020/PGPO3).

**Informed Consent** For this study, informed consent was received from subject.

## References

1. Bonnet, W. L., & Baker, D. R. (1946). Diagnosis of pes planus by X-ray. *Radiology*, 46(1), 36–45. <https://doi.org/10.1148/46.1.36>
2. Volpon, J. B. (1994). Footprint analysis during the growth period. *Journal of Pediatric Orthopedics*, 14(1), 83–85. <https://doi.org/10.1097/01241398-199401000-00017>
3. Kadhim, M., Holmes, L. J., Church, C., Henley, J., & Miller, F. (2012). Pes planovalgus deformity surgical correction in ambulatory children with cerebral palsy. *Journal of Children's Orthopaedics*, 6(3), 217–227. <https://doi.org/10.1007/s11832-012-0413-3>
4. Luhmann, S. J., Rich, M. M., & Schoenecker, P. L. (2000). Painful idiopathic rigid flatfoot in children and adolescents. *Foot and Ankle International*, 21(1), 59–66. <https://doi.org/10.1177/107110070002100111>
5. Harris, E. J., et al. (2004). Diagnosis and treatment of pediatric flatfoot. *The Journal of Foot and Ankle Surgery*, 43(6), 341–373. <https://doi.org/10.1053/j.jfas.2004.09.013>
6. Baker, J. R., Klein, E. E., Weil, L., Weil, L. S., & Knight, J. M. (2012). Retrospective analysis of the survivability of absorbable versus nonabsorbable subtalar joint arthroereisis implants. *Foot & Ankle Specialist*, 6(1), 36–44. <https://doi.org/10.1177/1938640012470712>
7. Kim, E. K., & Kim, J. S. (2016). The effects of short foot exercises and arch support insoles on improvement in the medial longitudinal arch and dynamic balance of flexible flatfoot patients. *Journal of Physical Therapy Science*, 28(11), 3136–3139. <https://doi.org/10.1589/jpts.28.3136>
8. Namsawang, J., Eungpinichpong, W., Vichiansiri, R., & Rattana-thongkom, S. (2019). Effects of the short foot exercise with neuromuscular electrical stimulation on navicular height in flexible



- flatfoot in Thailand: a randomized controlled trial. *Journal of Preventive Medicine and Public Health*, 52(4), 250–257. <https://doi.org/10.3961/jpmp.19.072>
9. Jafarnezhadgero, A., Madadi Shad, M., & Ferber, R. (2018). The effect of foot orthoses on joint moment asymmetry in male children with flexible flat feet. *Journal of Bodywork and Movement Therapies*, 22(10), 83–89. <https://doi.org/10.1016/j.jbmt.2017.04.007>
  10. Hurd, W. J., Kavros, S. J., & Kaufman, K. R. (2010). Comparative biomechanical effectiveness of over-the-counter devices for individuals with a flexible flatfoot secondary to forefoot varus. *Clinical Journal of Sport Medicine*, 20(6), 428–435. <https://doi.org/10.1097/JSM.0b013e3181fb539f>
  11. Johanson, M. A., Donatelli, R., Wooden, M. J., Andrew, P. D., & Cummings, G. S. (1994). Effects of three different posting methods on controlling abnormal subtalar pronation. *Physical Therapy*, 74(2), 149–161. <https://doi.org/10.1093/ptj/74.2.149>
  12. Hsieh, R. L., Peng, H. L., & Lee, W. C. (2018). Short-term effects of customized arch support insoles on symptomatic flexible flatfoot in children. *Medicine (United States)*. <https://doi.org/10.1097/MD.00000000000010655>
  13. Choi, J. Y., Lee, D. J., Kim, S. J., & Suh, J. S. (2020). Does the long-term use of medial arch support insole induce the radiographic structural changes for pediatric flexible flat foot?—A prospective comparative study. *Foot and Ankle Surgery*, 26(4), 449–456. <https://doi.org/10.1016/j.fas.2019.05.017>
  14. Jafarnezhadgero, A., Madadi-Shad, M., Alavi-Mehr, S. M., & Granacher, U. (2018). The long-term use of foot orthoses affects walking kinematics and kinetics of children with flexible flat feet: A randomized controlled trial. *PLoS ONE*, 13(10), e0205187. <https://doi.org/10.1371/journal.pone.0205187>
  15. Güner, S., Haghari, S., Alsancak, S., Uluğ, N., & İnanıcı, F. (2018). Effect of insoles with arch support on gait pattern in patients with multiple sclerosis. *Turkish Journal of Physical Medicine and Rehabilitation*, 64(3), 261–267. <https://doi.org/10.5606/tftrd.2018.2246>
  16. Zafar, A. Q., Zamani, R., & Akrami, M. (2020). The effectiveness of foot orthoses in the treatment of medial knee osteoarthritis: A systematic review. *Gait & Posture*, 76, 238–251. <https://doi.org/10.1016/j.gaitpost.2019.12.016>
  17. Kido, M., et al. (2014). Effect of therapeutic insoles on the medial longitudinal arch in patients with flatfoot deformity: a three-dimensional loading computed tomography study. *Clinical Biomechanics (Bristol, Avon)*, 29(10), 1095–1098. <https://doi.org/10.1016/j.clinbiomech.2014.10.005>
  18. Evans, A. M., Copper, A. W., Scharfbillig, R. W., Scutter, S. D., & Williams, M. T. (2003). Reliability of the foot posture index and traditional measures of foot position. *Journal of the American Podiatric Medical Association*, 93(3), 203–213. <https://doi.org/10.7547/87507315-93-3-203>
  19. Roth, S., Roth, A., Jotanovic, Z., & Madarevic, T. (2013). Navicular index for differentiation of flatfoot from normal foot. *International Orthopaedics*, 37(6), 1107–1112. <https://doi.org/10.1007/s00264-013-1885-6>
  20. Younger, A. S., Sawatzky, B., & Dryden, P. (2005). Radiographic assessment of adult flatfoot. *Foot and Ankle International*, 26(10), 820–825. <https://doi.org/10.1177/107110070502601006>
  21. Ohlendorf, D., et al. (2020). Standard reference values of weight and maximum pressure distribution in healthy adults aged 18–65 years in Germany. *Journal of Physiological Anthropology*, 39(1), 1–11. <https://doi.org/10.1186/s40101-020-00246-6>
  22. Houghton, K. M. (2008). Review for the generalist: Evaluation of pediatric foot and ankle pain. *Pediatric Rheumatology*, 6, 1–10. <https://doi.org/10.1186/1546-0096-6-6>
  23. Toullec, E. (2015). Adult flatfoot. *Orthopaedics & Traumatology, Surgery & Research*, 101(1 Suppl), S11–S17. <https://doi.org/10.1016/j.otsr.2014.07.030>
  24. Doxey, G. E. (1985). Clinical use and fabrication of molded thermoplastic foot orthotic devices. Suggestion from the field. *Physical Therapy*, 65(11), 1679–1682. <https://doi.org/10.1093/ptj/65.11.1679>
  25. Levangie, P. K., & Norkin, C. C. (2011). *Joint structure and function: A comprehensive analysis*. FA Davis, 5th edn
  26. Şahin, N., Öztürk, A., & Atici, T. (2010). Foot mobility and plantar fascia elasticity in patients with plantar fasciitis. *Acta Orthopaedica et Traumatologica Turcica*, 44(5), 385–391. <https://doi.org/10.3944/AOTT.2010.2348>
  27. Shibuya, N., Ramanujam, C. L., & Garcia, G. M. (2008). Association of tibialis posterior tendon pathology with other radiographic findings in the foot: A case-control study. *The Journal of Foot and Ankle Surgery*, 47(6), 546–553. <https://doi.org/10.1053/j.jfas.2008.08.010>
  28. Pedowitz, W. J., & Kovatis, P. (1995). Flatfoot in the adult. *Journal of the American Academy of Orthopaedic Surgeons*, 3(5), 293–302. <https://doi.org/10.5435/00124635-199509000-00005>
  29. Podolnick, J. D., Donovan, D. S., DeBellis, N., & Pino, A. (2017). Is pes cavus alignment associated with lisfranc injuries of the foot? *Clinical Orthopaedics and Related Research*, 475(5), 1463–1469. <https://doi.org/10.1007/s11999-016-5131-6>
  30. Sinha, S., Song, H. R., Kim, H. J., Park, M. S., Chool Yoon, Y., & Song, S. H. (2013). Medial arch orthosis for paediatric flatfoot. *Journal of Orthopaedic Surgery (Hong Kong)*, 21(1), 37–43. <https://doi.org/10.1177/230949901302100111>
  31. Huang, Y. P., Te Peng, H., Wang, X., Chen, Z. R., & Song, C. Y. (2020). The arch support insoles show benefits to people with flatfoot on stance time, cadence, plantar pressure and contact area. *PLoS ONE*. <https://doi.org/10.1371/journal.pone.0237382>
  32. Banwell, H. A., Mackintosh, S., & Thewlis, D. (2014). Foot orthoses for adults with flexible pes planus: A systematic review. *Journal of Foot and Ankle Research*, 7(1), 23. <https://doi.org/10.1186/1757-1146-7-23>
  33. Saeedi, H., et al. (2014). The evaluation of modified foot orthosis on muscle activity and kinetic in a subject with flexible flat foot: Single case study. *Prosthetics and Orthotics International*, 38(2), 160–166. <https://doi.org/10.1177/0309364613492170>
  34. Flores, D. V., Gómez, C. M., Hernando, M. F., Davis, M. A., & Pathria, M. N. (2019). Adult acquired flatfoot deformity: Anatomy, biomechanics, staging, and imaging findings. *Radiographics*, 39(5), 1437–1460. <https://doi.org/10.1148/rg.2019190046>
  35. Gould, N. (1982). Graphing the adult foot and ankle. *Foot & Ankle*, 2(4), 213–219. <https://doi.org/10.1177/107110078200200407>

**Publisher's Note** Springer Nature remains neutral with regard to jurisdictional claims in published maps and institutional affiliations.