

Accidental placement of central venous catheter tip into internal mammary vein

Sir,

Central venous catheter (CVC) plays an important role in the management of critically ill patients in terms of central venous pressure (CVP) monitoring, administration of vasopressors, inotropes, blood products, and parenteral nutrition. The ultrasound guided central venous cannulation has become a routine practice in recent years due to its lower complication rates and lesser errors during insertion. The ultrasound-guided catheter insertion does not prevent or help in the detection of misplaced catheter tips.

We present a case of a 25-year-old male, known case of fungal sinusitis and mycotic aneurysm of right internal carotid artery admitted to our tertiary care Intensive Care Unit following surgery (craniotomy) at an outside hospital. He was shifted for evaluation and management of shortness of breath and sepsis. It was decided to remove his old left subclavian central line in view of sepsis and replace it with a new left internal jugular vein (IJV) cannulation with the help of ultrasound guidance. Left internal jugular site was selected as all other sites were cannulated previously. The CVC on chest X-ray looked as if the catheter was entering the left atrium [Figure 1]. Flush tests on two-dimensional echo with agitated saline through the left jugular catheter showed that the catheter was draining into right atrium [Figure 2]. When patient was taken for computed tomography cerebral angiography,

the neck vessel angiography was also done which on venous reconstruction showed that there were no anomalies in the venous system, but the catheter tip was seen entering the left internal mammary vein (IMV) [Figure 3]. Later the central line was removed and replaced at a different location (since it was not showing CVP trace, and there was no backflow of blood through the port).

The incidence of CVC malposition during IJV cannulation is around 2%.^[1] There have been very few reported cases of accidental left IMV cannulation in the past.^[2] CVC, which are misdirected into tributaries of central veins, are more common during central venous cannulation of the left side.^[3] Reason may be due to the left brachiocephalic vein, which is anatomically longer and left smaller tributaries anastomose with the brachiocephalic vein opposite to the orifice of the left jugular vein.^[4]

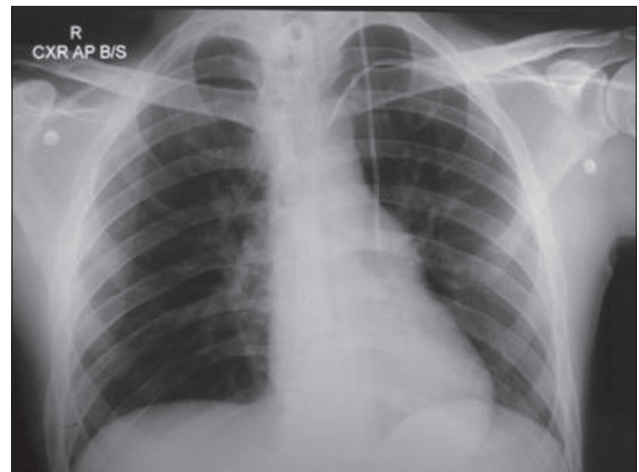


Figure 1: Central venous catheter in the left internal jugular vein appears to be entering left atrium

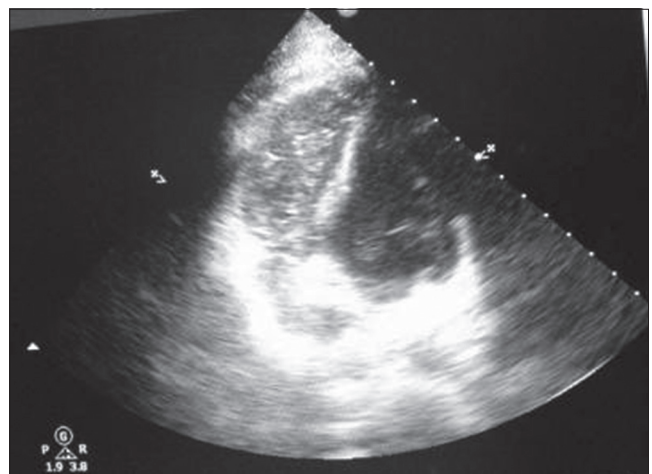


Figure 2: Agitated saline flush through the central port of the catheter showing bubbles in the right atrium

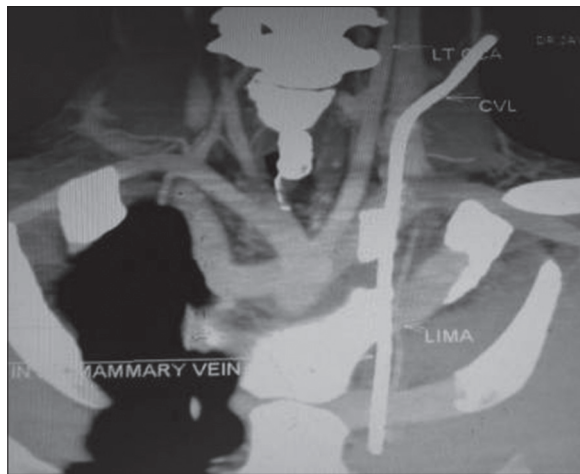


Figure 3: Angiogram of neck showing left central venous catheter entering into left internal mammary vein

Internal mammary vein receives the anterior intercostal veins and some abdominal branches, later drain into the brachiocephalic vein behind the sternal end of the clavicle and the first costal cartilage. Portal hypertension and portal to systemic collateral circulation dilates the IMV causing a higher risk of malpositioning of the catheter, which in our patient did not have any of these complaints. Complication related to IMV placement includes laceration of IMV with massive hemothorax and altered patency of the vein.^[2,5]

Ultrasound might reduce the complications associated with insertion, but chest X-ray would be needed to confirm the tip of catheter positioning.

**Kartik Munta, Pradeep M. Venkategowda,
Jaydeep Ray Chaudhary¹,
S. Manimala Rao, Rahul Amte**

Departments of Critical Care Medicine and ¹Neurology, Yashoda Multi-Speciality Hospital, Shantishikara Apartments, D4, #124, Behind Enadu Bld, Rajbhavan Road, Somajiguda, Hyderabad, Telangana, India

Correspondence:

Dr. S. Manimala Rao,
Department of Critical Care Medicine,
Yashoda Multi-Speciality Hospital, Somajiguda,
Hyderabad, Telangana, India.
E-mail: manimalarao@hotmail.com

Acknowledgment

We gratefully acknowledge the management of the hospital for their valuable support.

References

1. Zaman MH, Mitra P, Bondi E, Gintautas J, Abadir AR. A rare malposition of the central venous catheter. *Chest* 1990;98:768-70.
2. Angral R, Sabesan P, Natarajan K, Ninan B. Inadvertent placement of left central venous catheter into left internal thoracic vein: A case

report. *Ann Card Anaesth* 2012;15:165-6.

3. Bankier AA, Mallek R, Wiesmayr MN, Fleischmann D, Kranz A, Kontrus M, *et al.* Azygos arch cannulation by central venous catheters: Radiographic detection of malposition and subsequent complications. *J Thorac Imaging* 1997;12:64-9.
4. Webb JG, Simmonds SD, Chan-Yan C. Central venous catheter malposition presenting as chest pain. *Chest* 1986;89:309-12.
5. Eulmesekian PG, Pérez A, Minces PG, Lobos P, Moldes J, García Mónaco R. Internal mammary artery injury after central venous catheterization. *Pediatr Crit Care Med* 2007;8:489-91.

Access this article online

Quick Response Code:



Website:

www.ijccm.org

DOI: 10.4103/0972-5229.158290