

CASE REPORT

Suicidal attempt by disinfectant solution ingestion in case of opioid dependence

Kiana Koulaei Nejad^{1,2} | Mahboobeh Ghasemzadeh Rahbardar³ 

¹Faculty of Psychology and Educational Sciences, Allameh Tabataba'i University, Tehran, Iran

²Toxicology Clinic, Besat General Hospital, Tehran, Iran

³Pharmaceutical Research Center, Pharmaceutical Technology Institute, Mashhad University of Medical Sciences, Mashhad, Iran

Correspondence

Mahboobeh Ghasemzadeh Rahbardar, Pharmaceutical Research Center, Pharmaceutical Technology Institute, Mashhad University of Medical Sciences, Mashhad, Iran.
Emails: Ghasemzadeh_mahboobeh@yahoo.com; ghasemzadehrm962@mums.ac.ir

Funding information

The authors have no relevant affiliations or financial involvement with any organization or entity with a financial interest in or financial conflict with the subject matter or materials discussed in the manuscript

Abstract

The current study presents a rare case of an opioid dependence (46-year-old man) ingesting a disinfectant solution (Wavicide-01; 2.65% glutaraldehyde solution, pH:6). The doctor intubated the patient and ordered bicarbonate for systemic acidosis, anti-proton-pump inhibitors (PPIs), and mechanical ventilation because the patient's breathing was irregular and the endoscopy revealed grade 1 and grade 2 burns all the way through the gastrointestinal tract up to the duodenum. As a result, ingestion of glutaraldehyde compounds should be closely monitored for laryngeal edema and metabolic acidosis, which can result in upper airway obstruction requiring immediate airway stabilization. Furthermore, a better understanding of the clinical epidemiology of suicide attempts could aid in the early identification of people that use opioids and are at high risk of suicide, as well as the development of suicide prevention strategies for this vulnerable population.

KEYWORDS

disinfectants, gastrointestinal tract, opioid-related disorders, poisoning, suicide, toxicology

1 | INTRODUCTION

People that use heroin and other opioids are more likely to die prematurely, with suicide accounting for a significant portion of the overall increased mortality reported among opioid users.¹ A new suicide trend known as "detergent suicides" has been recorded in industrialized countries. The approach was initially detailed in Japan in 2007 and has become prevalent in the United States and other countries.² In the industrial, scientific, and biological domains, glutaraldehyde is widely employed. It

is also normally used as a disinfectant in many hospitals (2%–3.5% aqueous glutaraldehyde solution is used for cold sterilization). The use of glutaraldehyde in biomedical applications has been linked to a number of adverse health effects in people. Glutaraldehyde is extensively metabolized to CO₂, but its urinary excretion is low. Endoscopy nurses, medical radiation technologists, and other individuals that used glutaraldehyde have reported sensory irritant effects, sensitization of skin and respiratory organs, gastrointestinal symptoms (nausea/vomiting), and kidney injury.^{3–5}

This is an open access article under the terms of the [Creative Commons Attribution-NonCommercial-NoDerivs](https://creativecommons.org/licenses/by-nc-nd/4.0/) License, which permits use and distribution in any medium, provided the original work is properly cited, the use is non-commercial and no modifications or adaptations are made.

© 2022 The Authors. *Clinical Case Reports* published by John Wiley & Sons Ltd.

This paper describes a rare case described in the literature of a case of opioid dependence attempting suicide by using a disinfectant solution (Wavicide-01 (2.65% glutaraldehyde solution, pH:6)).

2 | CASE PRESENTATION

The patient, a 46-year-old man with a history of opioid dependence, was admitted to the hospital after losing consciousness due to an opium overdose. Because this case was an opioid dependence, he developed withdrawal symptoms, agitation, and restlessness after receiving naloxone and attempted to flee the hospital's emergency department. The nurses then sedated him and admitted him to the emergency room.

At the time of the doctor's visit, the patient was alert, calm, and had stable vital signs, but he was admitted to the intensive care unit (ICU) because he had been poisoned with a long-acting drug. Furthermore, the patient's wife stated that he had attempted suicide on multiple occasions, so the doctor insisted on admitting the patient to the ICU for further care, and he was referred for psychiatric counseling. The next morning, the doctor received a phone call informing him that the patient was fine and had eaten. The doctor was told, however, that the patient wanted to be discharged from the hospital, but because he was dependant and had a high risk of suicide, he was kept in the hospital for a psychiatrist's examination and opinion.

The patient informed the ICU care assistant that he needed to use the restroom while on complete bed rest and should not be able to get out of bed under any circumstances. Instead of taking him to the patients' restrooms, the care assistant took him to the toilet where the chemicals were stored. When the care assistant returned to the

toilet, she discovered that the patient had consumed a cup of surface disinfectant solution (Wavicide-01 (2.65% glutaraldehyde solution, pH:6)) with the intent of attempting suicide, as evidenced by nausea and vomiting. The patient was admitted again. He had gastric lavage and activated charcoal applied to him. The doctor arrived at the hospital almost immediately. Despite the fact that the patient was awake, his breathing rhythm was irregular. Although the anesthesiologist determined that the patient was fine, the doctor ordered intubation and an emergency endoscopy. During an endoscopy, burns of grades 1 and 2 were discovered throughout the gastrointestinal tract up to the duodenum. In addition, corrosive esophagitis, severe edema of the larynx and oropharynx, mucosal sloughing with superficial, circumferential ulcer, and bullous development throughout the esophagus, severe erythema and exudation, patulous pylorus in the stomach, severe erythema, and congestion in the duodenum were also illustrated (Figure 1). The doctor prescribed anti-proton-pump inhibitors (PPI) medications, mechanical ventilation, and bicarbonate for systemic acidosis. The patient was admitted to the ICU for two weeks and was re-examined by computed tomography (CT) scan and endoscopy two weeks later.

The patient was released from the psychiatric hospital after two months with no complications and a normal endoscopy and CT scan. The patient was examined after two months and again after a year and a half. CT scans and endoscopies were both normal on both occasions.

It is critical to note that the patient's history reveals a history of opioid dependence, an unspecified type of neurological disease, and the use of psychiatric drugs. The patient stated that his recent hospital suicide was caused by his emotional state and arousal as a result of opioid dependence and unemployment, and he regretted what he had done.

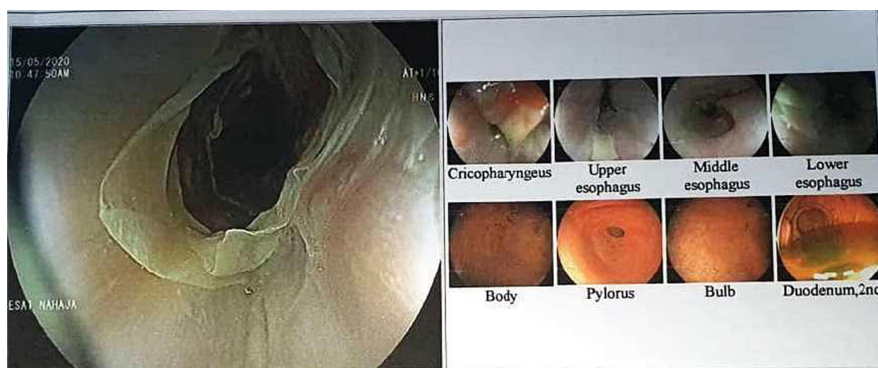


FIGURE 1 Results from an upper gastrointestinal endoscopy. Reason for endoscopy: Caustic ingestion. Findings: Corrosive esophagitis. Esophagus: Laryngeal and oropharyngeal severe edema. Mucosal sloughing with superficial, circumferential ulcer and bullous formation entire of the esophagus. No bleeding and necrosis. Stomach: Severe erythema and exudation, patulous pylorus. Duodenum: Severe erythema and congestion

3 | DISCUSSION

Suicide is a major public health issue that has long-term negative consequences for people, families, and society.⁶ Suicide is linked to a number of causes, including genetics, psychological states, psychiatric diseases, drug abuse, and social and cultural circumstances.^{6,7} Suicide death, suicide attempt, and suicide ideation are all closely linked to substance use disorders. As a result, illegal drugs might be considered significant predictors of suicide and consequently a major cause of premature death.⁶

Furthermore, opioid use is an issue that warrants investigation due to its potential impact on suicide capability and link to increased suicide risk. There is additional evidence that opioid usage, in comparison with other substances, may facilitate suicide behavior among people with suicidal ideation. Suicide is intrinsically frightening, and those that attempt suicide must confront and overcome significant pain and fear.^{8,9}

For ages, chemicals have been used to attempt suicide. Toxic substances are a typical means of taking one's own life due to their quick action, accessibility, and lack of mutilation of the body. A self-poisoning suicide is described as an individual's self-exposure (by ingesting or another method of administration) to an amount of substance that has a high probability of death.¹⁰

Glutaraldehyde is a bactericide with a long history of use.¹¹ In the healthcare sector, it is a routinely used disinfectant in the form of a 2% solution.¹² The National Institute for Occupational Safety and Health issued a National Hazard Survey in 1980, citing 35,083 workplace glutaraldehyde exposures.¹³ In the healthcare setting, glutaraldehyde poisoning is restricted to a small number of cases, most of which are unintentional.¹⁴⁻¹⁸ Only a few case reports of suicide attempts involving glutaraldehyde-containing solutions were found.^{5,19}

In our case, nausea, vomiting, corrosive esophagitis, laryngeal and oropharyngeal severe edema, mucosal sloughing with superficial, circumferential ulcer, and bullous formation throughout the esophagus, severe erythema and exudation, patulous pylorus in the stomach, severe erythema, and congestion in the duodenum were observed. A case report claimed that multiple episodes of spontaneous nonblood emesis and two episodes of loose stools occurred shortly after ingesting 500 ml of concentrated Kohrsolin TH[®] (containing glutaraldehyde (10%)), which was consistent with our findings.⁵ In our situation, metabolic acidosis and gastrointestinal symptoms were treated with PPI medications, bicarbonate, sufficient nutritional support, and supportive care with no long-term debilitating side effects.

In the current patient, irregular breathing was noticed, and the patient was intubated and mechanical ventilation

was employed for him, which is consistent with a case report that said the patient (ingesting 500 ml of concentrated Kohrsolin TH[®] (containing glutaraldehyde (10%))) suffered respiratory tract irritation, inflammation, and stridor, implying both inhalation and ingestion exposure. Prior to surgical tracheostomy, bronchoscopy revealed significant airway edema with no erosions.⁵ Moreover, humans that are accidentally exposed to glutaraldehyde exhibit comparable symptoms.^{20,21} Healthcare personnel are also more likely than non-exposed people to develop glutaraldehyde hypersensitivity.^{22,23}

In summary, glutaraldehyde is a local stimulant that affects the gastrointestinal tract and disrupts the metabolic state. It is widely available, particularly in healthcare settings, but it is a rare cause of poisoning. Even if the patient appears to be asymptomatic at the time of presentation, careful observation is required. Early airway management, gastric lavage, gastrointestinal health examination, and appropriate supportive care, including nutritional support, are critical for the individual's recovery.

ACKNOWLEDGEMENT

N/A.

CONFLICTS OF INTEREST

The authors declare that they have no conflicts of interest.

DATA AVAILABILITY STATEMENT

On reasonable request, the authors will provide the data that support the conclusions of this study.

ETHICAL APPROVAL

Ethics approval is not necessary for anonymized case reports in studies involving human subjects.

CONSENT

The participant presented their written informed consent for the publication of their medical case and any related photographs.

ORCID

Mahboobeh Ghasemzadeh Rahbardar  <https://orcid.org/0000-0002-5491-572X>

REFERENCES

1. Zhong B-L, Xie W-X, Zhu J-H, Lu J, Chen H. Prevalence and correlates of suicide attempt among Chinese individuals receiving methadone maintenance treatment for heroin dependence. *Sci Rep*. 2019;9(1):1-9.
2. Papadodima S, Papoutsis I, Nikolaou P, Spiliopoulou C, Stefanidou M. "Detergent suicide" by adolescent as instructed by internet: a case report. *World*. 2010;1999:1.

3. Takigawa T, Endo Y. Effects of glutaraldehyde exposure on human health. *J Occup Health*. 2006;48(2):75-87.
4. Thumtecho S, Sriapha C, Tongpoo A, Udomsubpayakul U, Wanankul W, Trakulsrichai S. Poisoning of glutaraldehyde-containing products: clinical characteristics and outcomes. *Clin Toxicol*. 2021;59(6):480-487.
5. Hakkeem B, Abraham SV, Kandiyil KC, et al. Laryngeal edema, metabolic acidosis, and acute kidney injury associated with large-volume Kohrsolin TH[®] ingestion. *J Emerg Med*. 2020;59(6):900-905.
6. Poorolajal J, Haghtalab T, Farhadi M, Darvishi N. Substance use disorder and risk of suicidal ideation, suicide attempt and suicide death: a meta-analysis. *J Public Health (Oxf)*. 2016;38(3):e282-e291.
7. Poorolajal J, Rostami M, Mahjub H, Esmailnasab N. Completed suicide and associated risk factors: a six-year population based survey. *Arch Iran Med*. 2015;18(1):39-43.
8. Anestis MD, Tull MT, Butterworth SE, et al. The role of opioid use in distinguishing between suicidal ideation and attempts. *Suicide Life Threat Behav*. 2019;49(6):1680-1692.
9. Ribeiro JD, Witte TK, Van Orden KA, et al. Fearlessness about death: the psychometric properties and construct validity of the revision to the acquired capability for suicide scale. *Psychol Assess*. 2014;26(1):115.
10. Dumbrava DP, Radu CC, Tabian D, Vesa SC, Fulga I, Chiroban O. The relation between suicide by chemical substances and the level of education. *Rev Chim(Bucharest)*. 2016;70:2643-2646.
11. Russell A, Hopwood D. 4 The biological uses and importance of glutaraldehyde. *Prog Med Chem*. 1976;13:271-301.
12. Ayliffe G, Collins B, Babb J. Disinfection with glutaraldehyde. *Br Med J*. 1979;1(6169):1019.
13. Calvert JG, Albright L, Brennan E. *Formaldehyde and other aldehydes*. Natl Academy Press; 1981.
14. Ahishali E, Uygur-Bayramiçli O, Dolapçioğlu C, et al. Chemical colitis due to glutaraldehyde: case series and review of the literature. *Dig Dis Sci*. 2009;54(12):2541-2545.
15. Nazik H, Bodur S, Api M, Aytan H, Narin R. Glutaraldehyde-induced bowel injury during gynecologic laparoscopy. *J Minim Invasive Gynecol*. 2012;19(6):756-757.
16. Hsu C-W, Lin C-H, Wang J-H, Wang H-T, Ou W-C, King T-M. Acute rectocolitis following endoscopy in health check-up patients—glutaraldehyde colitis or ischemic colitis? *Int J Colorectal Dis*. 2009;24(10):1193-1200.
17. Karpelowsky JS, Maske CP, Sinclair-Smith C, Rode H. Glutaraldehyde-induced bowel injury after laparoscopy. *J Pediatr Surg*. 2006;41(6):e23-e25.
18. Krishna PD, Statham MM, Rosen CA. Acute glutaraldehyde mucosal injury of the upper aerodigestive tract due to damage to the working channel of an endoscope. *Ann Otol Rhinol Laryngol*. 2010;119(3):150-154.
19. Perera P, Kularathne K, Gawarammana I. Laryngeal edema and metabolic acidosis after Omnicide[®] ingestion. *Clin Toxicol*. 2008;46(9):858-860.
20. Copeland S, Nugent K. Persistent and unusual respiratory findings after prolonged glutaraldehyde exposure. *J Occup Environ*. 2015;6(3):177.
21. Carder M, Seed MJ, Money A, Agius RM, Van Tongeren M. Occupational and work-related respiratory disease attributed to cleaning products. *Occup Environ Med*. 2019;76(8):530-536.
22. Ong T, Tan K, Lee H, Eng P. A case report of occupational asthma due to glutaraldehyde exposure. *Ann Acad Med Singap*. 2004;33(2):275-278.
23. Shaffer MP, Belsito DV. Allergic contact dermatitis from glutaraldehyde in health-care workers. *Contact dermatitis*. 2000;43(3):150-156.

How to cite this article: Koulaei Nejad K, Ghasemzadeh Rahbardar M. Suicidal attempt by disinfectant solution ingestion in case of opioid dependence. *Clin Case Rep*. 2022;10:e05907. doi:[10.1002/ccr3.5907](https://doi.org/10.1002/ccr3.5907)