



Case Report

A combined approach for stabilization and endoscopic/endonasal odontoid and clivus resection for treatment of basilar invagination

Lance Michael Villeneuve¹, Zoya Voronovich¹, Alexander Evans¹, Edward T. El Rassi², Ian F. Dunn¹, Zachary A. Smith¹

Departments of ¹Neurosurgery, ²Otolaryngology, Oklahoma University Health Science Center, Oklahoma City, United States.

E-mail: *Lance Michael Villeneuve - lance-villeneuve@ouhsc.edu; Zoya Voronovich - zoya-voronovich@ouhsc.edu; Alexander Evans - alexander-evans@ouhsc.edu; Edward T. El Rassi - edward-t-elrassi@ouhsc.edu; Ian F. Dunn - ian-dunn@ouhsc.edu; Zachary A. Smith - zachary-a-smith@ouhsc.edu



*Corresponding author:

Lance Michael Villeneuve,
Department of Neurosurgery,
Oklahoma University Health
Science Center, Oklahoma City,
United States.

lance-villeneuve@ouhsc.edu

Received : 01 July 2021
Accepted : 10 August 2021
Published : 11 October 2021

DOI
10.25259/SNI_658_2021

Quick Response Code:



ABSTRACT

Background: Basilar invagination (BI) is a complex condition characterized by prolapse of the odontoid into the brain stem/upper cervical cord. This lesion is often associated with Chiari malformations, and rheumatoid arthritis (RA). Treatment options for BI typically include cervical traction, an isolated anterior transoral odontoidectomy, anterior endonasal odontoidectomy, an isolated posterior fusion, or combined anterior/posterior surgical approach.

Case Description: A 45-year-old female with a Chiari I malformation and RA underwent a combined posterior C0-C5 posterior decompression/fusion, followed by an anterior odontoidectomy (i.e. endoscopic/endonasal under neuronavigation). Postoperatively, the patient's symptoms and neurological signs resolved.

Conclusion: BI in was successfully managed with a combined posterior C0-C5 decompression/fusion followed by an anterior endoscopic/endonasal odontoidectomy performed under neuronavigation.

Keywords: Basilar invagination, Endoscopic endonasal approach, Intraoperative 3D fluoroscopy, Odontoidectomy

INTRODUCTION

Basilar invagination (BI) resulting in cord compression is often associated with rheumatoid arthritis (RA), Chiari malformations (CM), Down syndrome, Klippel-Feil syndrome, or osteogenesis imperfecta.^[6] The operative surgical options include a transoral versus endonasal odontoidectomy, and occipital/cervical posterior decompression and fusion.^[4] Here, a 45-year-old female with BI, RA and a CM, successfully underwent a C0-C5 posterior decompression/fusion, followed by an anterior endoscopic/endonasal odontoidectomy.

CASE PRESENTATION

A 45-year-old female presented with a Chiari I malformation (CM) and RA presented with 7-months of progressive suboccipital headaches [Table 1]. The brain MRI showed brainstem/

upper cervical cord compression attributed to a Chiari I malformation (i.e., with 4-mm of tonsillar descent), with BI/platybasia (i.e., defined based >3-mm extension cranial to Chamberlain's line, extension cranial to McRae's line, and with a nasion/clival angle >143 degrees) [Figures 1-3]. Cervical X-rays also confirmed odontoid instability with anterolisthesis of C2 over C3 and C3 over C4 on flexion which reduces on extension [Figure 4].

Table 1: Patient characteristics.

Medical history	Surgical history	Congenital abnormalities
Chiari I malformation	Cleft palate repair	C2/C3 lateral masses fused
Rheumatoid arthritis	Multiple sinus surgeries (last surgery 2016)	No genetic abnormalities
Webbed-feet Cleft palate Recurrent sinusitis (resolved after surgery)		

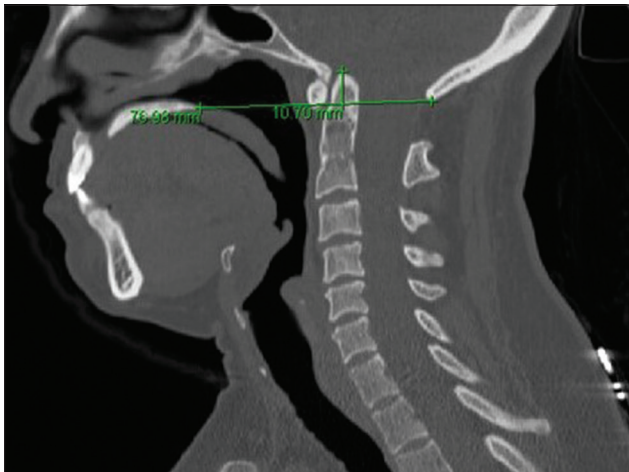


Figure 1: Preoperative radiograph demonstrating the Chamberlain line suggestive of basilar invagination.

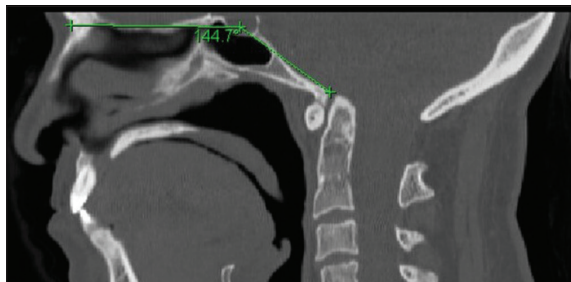


Figure 3: Preoperative lateral cervical spine radiograph demonstrating the angle of the nasion to the pituitary to the anterior margin of the foramen magnum. The angle of >143-degrees is suggestive of platybasia.

Surgery

As 48 h of halo ring traction (i.e. secured to a halo vest) resulted in minimal odontoid reduction (i.e. movement of ~2-mm), the patient required posterior followed by anterior cervical surgery [Figure 5].

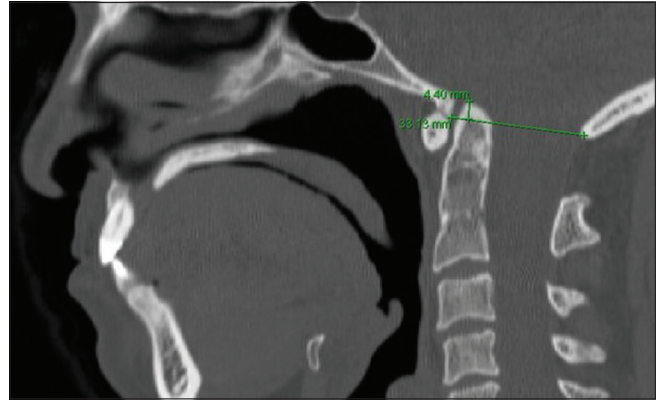


Figure 2: Preoperative lateral cervical spine radiograph demonstrating the McRae line connecting the basion and opisthion.

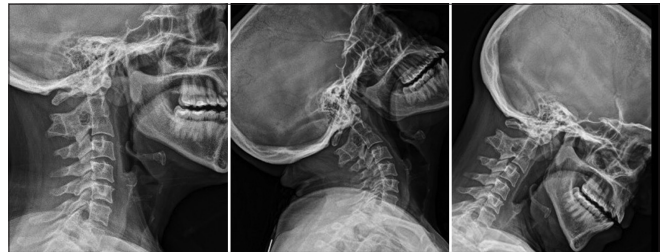

Figure 4: Preoperative lateral cervical spine X-rays in neutral, extension, and flexion.

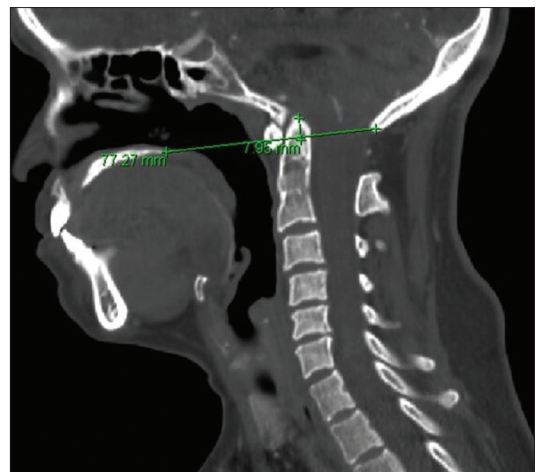


Figure 5: Preoperative lateral CT scan of the cervical spine with 12 lbs of traction demonstrating ~2-mm of reduction when compared to Chamberlain line.

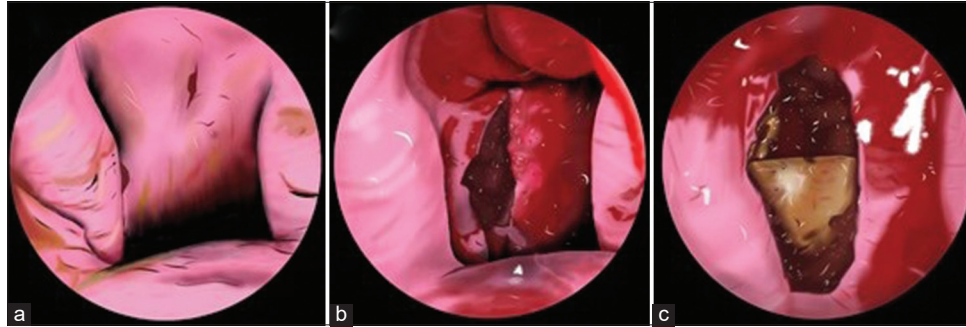


Figure 6: Illustrations of key steps of endoscopic endonasal odontoidectomy. (a) Localization of the proper area of the posterior oropharynx. (b) Midline incision. (c) Localization and identification of the anterior tubercle of C1.

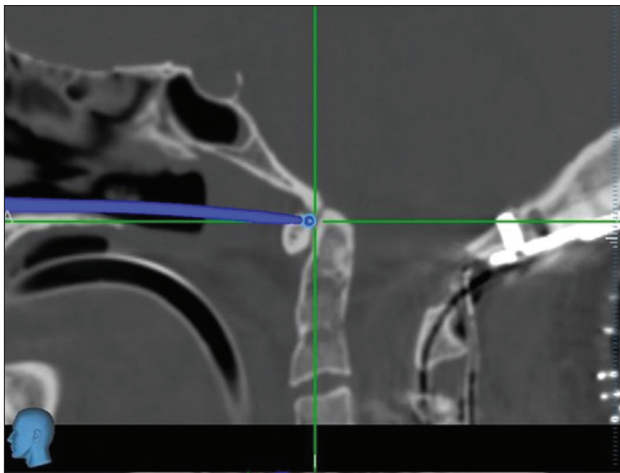


Figure 7: Intraoperative imaging showing the initial approach to the odontoid. Imaging was obtained with an O-Arm.

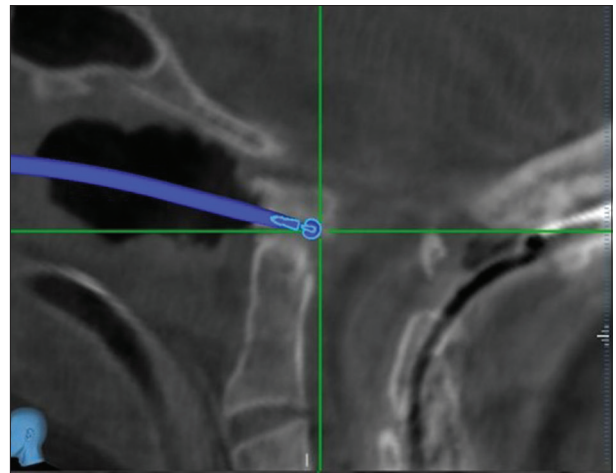


Figure 9: Intraoperative imaging demonstrating a small remnant of odontoid before final resection. Imaging was obtained with an O-Arm. The navigated drill model is in blue.

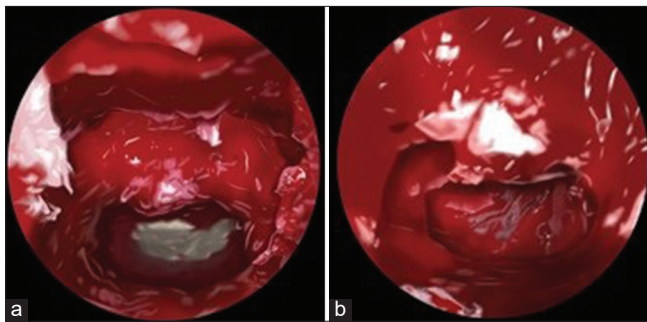


Figure 8: Illustrations of key steps of endoscopic endonasal odontoidectomy (a) Removal of the odontoid. (b) Identification of the thecal sac.

The C0-C5 decompression and fusion revealed underdeveloped lateral masses (i.e., analogous to pediatric lateral masses) and confirmed a congenital C2/3 lateral mass fusion. Despite this finding, 14-mm screws were effectively placed for lateral mass fixation. The second procedure, an endoscopic/endonasal odontoidectomy utilized neuronavigation. A small incision was made in the soft palate, and the posterior portion of the hard palate was removed

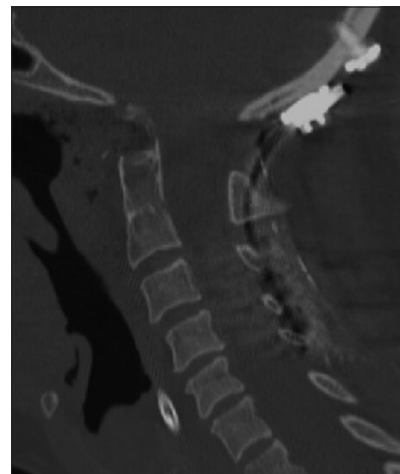

Figure 10: Postoperative lateral CT scan of the cervical spine demonstrating removal of the odontoid and reduction of compression on the cervical spinal cord.

using the zero-degree endoscope allowing access to remove the inferior odontoid [Figures 6a and b]. In addition, soft

Table 2: Comparison of transoral versus endonasal approach for odontoidectomy.

	Pros	Cons	Modifications
Transoral	Odontoid base visualization	Dysphonia Prolonged intubation Prolonged hospitalization Dysphagia Infection rates	
Endonasal	Less invasive Shorter intubation period Shorter hospitalization Less dysphagia Lower infection rates	Odontoid base visualization Limited by nasopalatine line	Hard palate resection Navigated instruments

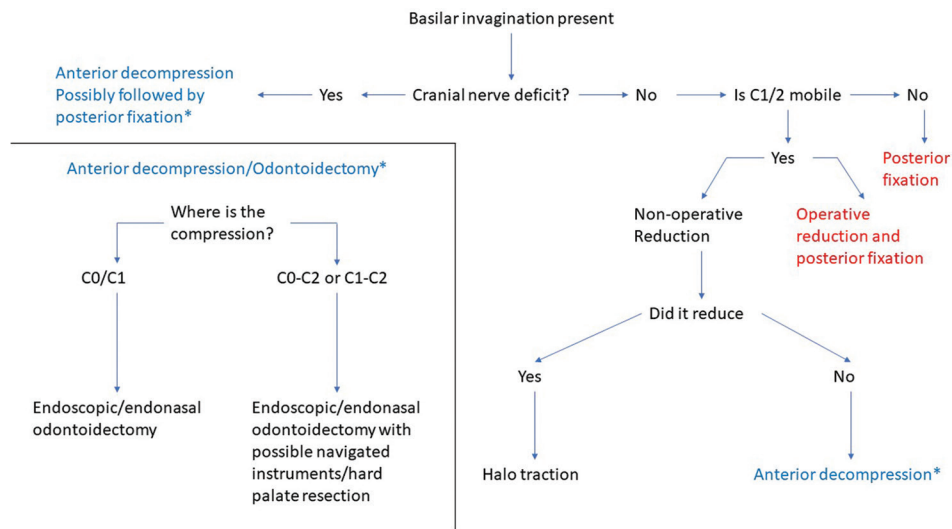


Figure 11: Flow chart for the determination of the approach for basilar invagination.

tissue from the anterior arch of C1 and the small intervening portion of the clivus between C1 and C2 were removed [Figures 6c and 7]. As stereotactic navigation appeared to be inaccurate, 3D fluoroscopy was additionally employed to complete the endoscopic/endonasal odontoidectomy [Figures 8a and b]. A second O-arm spin demonstrated a small residual portion of the left lateral base of odontoid, which was then removed [Figure 9]. The patient tolerated the procedure well. Further, the final post-operative CT of confirmed good decompression [Figure 10]. Her headaches resolved postoperative at 4-weeks and the neck stiffness was improving.

DISCUSSION

There are a variety of surgical options for treating craniocervical junctional abnormalities. Indications for surgery include cranial nerve deficits, brainstem/spinal cord compression, craniocervical instability/ligamentous laxity, and autofusion anomalies. Symptomatic BI may be treated with cervical

traction, an anterior odontoidectomy, a posterior C0-C2 fusion, or a combination of these approaches [Figure 11]. Here, our patient required a combination of C0-C5 posterior decompression/fusion with an anterior endoscopic/endonasal odontoidectomy [Table 2].^[1,3,5,7] Notably, in one small series, four out of 11 patients (38%) undergoing anterior odontoidectomies required further decompression after utilizing an O-arm for an endoscope/endonasal approach without neuronavigation.^[2] In our case, the resection of the posterior hard palate increased the operative corridor to complete the odontoid resection utilizing neuronavigation. Nevertheless, further verification of the extent of decompression should be confirmed with additional fluoroscopic imaging.

CONCLUSION

Here, we presented a 45-year-old female with BI, a CM, and RA who was successfully treated with a posterior decompression/fusion from C0-C5 followed by an anterior endoscopic/endonasal odontoidectomy.

Disclosures

The authors report no disclosures or conflicts of interest.

Declaration of patient consent

Patient's consent not required as patients identity is not disclosed or compromised.

Financial support and sponsorship

Nil.

Conflicts of interest

There are no conflicts of interest.

REFERENCES

1. Chaudhry NS, Ozpinar A, Bi WL, Chavakula V, Chi JH, Dunn IF. Basilar invagination: Case report and literature review. *World Neurosurg* 2015;83:1180.e7-11.
2. Gande A, Tormenti MJ, Koutourousiou M, Paluzzi A, Fernandez-Miranda JC, Snyderman CH, *et al.* Intraoperative computed tomography guidance to confirm decompression

- following endoscopic endonasal approach for cervicomedullary compression. *J Neurol Surg B Skull Base* 2013;74:44-9.
3. Joaquim AF, Osorio JA, Riew KD. Transoral and endoscopic endonasal odontoidectomies-surgical techniques, indications, and complications. *Neurospine* 2019;16:462-9.
4. Joseph V, Rajshekhar V. Resolution of syringomyelia and basilar invagination after traction. Case illustration. *J Neurosurg* 2003;98 Suppl 3:298.
5. Kassam AB, Gardner P, Snyderman C, Mintz A, Carrau R. Expanded endonasal approach: Fully endoscopic, completely transnasal approach to the middle third of the clivus, petrous bone, middle cranial fossa, and infratemporal fossa. *Neurosurg Focus* 2005;19:E6.
6. Menezes AH, VanGilder JC, Graf CJ, McDonnell DE. Craniocervical abnormalities. A comprehensive surgical approach. *J Neurosurg* 1980;53:444-55.
7. Shriver MF, Kshetry VR, Sindwani R, Woodard T, Benzel EC, Recinos PF. Transoral and transnasal odontoidectomy complications: A systematic review and meta-analysis. *Clin Neurol Neurosurg* 2016;148:121-9.

How to cite this article: Villeneuve LM, Voronovich Z, Evans A, El Rassi ET, Dunn IF, Smith ZA. A combined approach for stabilization and endoscopic/endonasal odontoid and clivus resection for treatment of basilar invagination. *Surg Neurol Int* 2021;12:511.