

# TOTAL HIP ARTHROPLASTY WITH BIOMECH PROSTHESIS: 20-YEAR FOLLOW-UP

Rodrigo Benedet Scheidt<sup>1</sup>, Ricardo Rosito<sup>2</sup>, Carlos Alberto de Souza Macedo<sup>3</sup>, Carlos Roberto Galia<sup>4</sup>

## ABSTRACT

**Objective:** To analyze the clinical and radiological outcomes from total hip arthroplasty using the Biomech prosthesis over a 20-year period (1988 to 2009). **Methods:** The patients were evaluated clinically in accordance with the Merle d'Aubigné and Postel functional classification, and underwent anteroposterior (AP) radiography of the pelvis and the operated joint in lateral view. The variables evaluated were acetabular and femoral osteolysis, polyethylene wear, nail migration, follow-up and clinical

outcomes. **Results:** The mean follow-up was 10.6 years (range 4 to 21 years). The sample consisted of 84 patients (32 men and 52 women) and the mean preoperative age was 47 years. We found that 88% of the results from the clinical evaluation were good or excellent. In relation to the radiological findings, 92.5% of the results were good. The mean wear on the polyethylene was 1.4 mm. **Conclusion:** The use of the Biomech prosthesis in this cohort showed good clinical and radiographic results.

**Keywords** – Hip/surgery; Arthroplasty, hip; Biomechanics

## INTRODUCTION

Total hip arthroplasty (THA) was popularized by Charnley in the 1960s<sup>(1)</sup>. At that time, metal-on-polyethylene joints fixed with surgical cement (polymethyl methacrylate, PMMA) became standard. As the use of cemented THA spread, the number of complications also increased, especially cases of aseptic loosening and osteolysis. Initially, it was thought that the problem was in the cement and, at that time, the term “cement disease” started to be investigated<sup>(2)</sup>. The results from such studies showed that the reason for the failures was not just the cement, but rather, a set of factors. Whatever the cause, these events stimulated the search for biological solutions (without cement), as alternatives for performing THA<sup>(3,4)</sup>.

Thus, at the end of the 1970s, the number of indications for THA using biological fixation increased. This period was marked by the emergence of a series of new types of implant based on a wide variety of concepts regarding materials, format, type of covering and

fixation<sup>(5)</sup>. Among these, the Spotorno<sup>®</sup> prosthesis, which has become established worldwide, is an example of an implant with biological fixation and a wedge-shaped quadrangular format, made of titanium (Ti6Al7Nb), which served as a model for developing the prosthesis examined in the present study (Biomech)<sup>(6)</sup>. Analysis on the preliminary results from various designs for uncemented implants, compared with the results achieved using adequately cemented prostheses, suggested that not all the concepts put forward could be sustained over medium-term follow-up, and this is well demonstrated by the variations in the models made by various companies that were formed at that time<sup>(7,8)</sup>.

All of this motivated us to present our experience over 20 years of performing THA using the Biomech uncemented wedge-shaped quadrangular prosthesis.

The aim of this study was to show the clinical and radiographic results from the use of the Biomech uncemented prosthesis, with a mean length of follow-up of 10.6 years.

1 – Orthopedist R4 in the Hip Surgery Group of the Orthopedics Service, Hospital de Clínicas de Porto Alegre (HCPA), Porto Alegre, RS.

2 – Substitute Professor in the Department of Surgery, Federal University of Rio Grande do Sul (UFRGS); Contracted Physician at Hospital de Clínicas de Porto Alegre (HCPA) and Preceptor of the Hip Surgery Group at HCPA.

3 – Professor in the Department of Surgery, Federal University of Rio Grande do Sul (UFRGS); Head of the Orthopedics Service, Hospital de Clínicas de Porto Alegre (HCPA) and Head of the Hip Surgery Group at HCPA.

4 – Professor in the Postgraduate Program on Surgery, Federal University of Rio Grande do Sul (UFRGS); Contracted Physician and Preceptor of the Hip Surgery Group at Hospital de Clínicas de Porto Alegre (HCPA).

Work performed in the Department of Surgery, Federal University of Rio Grande do Sul (UFRGS), Porto Alegre, RS.

Correspondence: Ricardo Rosito, Rua Ramiro Barcelos 2350, Largo Eduardo Faracco, 90035-903 Porto Alegre, RS, Brazil – E-mail: ricardo@rosito.com.br

We declare that there is no conflict of interests in this article

## METHODS

The present study consisted of a cohort of 84 patients (93 hips) who underwent THA using the Biomec uncemented prosthesis between 1988 and 2005, with follow-up until 2008. The clinical evaluation was performed before the radiographic evaluation and was done by different examiners, with the aim of diminishing the measurement bias. The patients were called in for assessment; they gave responses according to a preestablished protocol; and they underwent radiography on the pelvis (anteroposterior view), and on the coxofemoral joint on the side affected (lateral view). The patients underwent operations consisting of an anterolateral or posterolateral approach according to the decision made by the chief surgeon and the Hip Surgery Group of our hospital.

With regard to design, the femoral component of the Biomec prosthesis is made of titanium (Ti6Al7Nb), with a cervical-diaphyseal angle of 145° and a wedge-shaped format in the three planes. It is fixed to the bone under pressure (*pressfit*) in the metaphyseal region. Proximally, the nail has anterior and posterior grooves to avoid rotational movements and favor osseointegration. The Biomec acetabulum consists of a cupola made of titanium, of hemispherical format with six expandable fins. The interchangeable head used was made of chromium-cobalt-molybdenum (CoCrMo) of diameter 28 mm.

For the clinical evaluation, the criteria proposed by D'Aubigné and Postel<sup>(9)</sup> were used. Pain, gait and hip mobility were assessed, with a maximum score of six for each item, such that the total of 18 points represented the best result. For the purposes of statistical analysis, the results were considered good if the patients obtained scores graded as good or very good (greater than or equal to 15 points), and other results were considered unsatisfactory.

The radiographic evaluation on acetabular osteolysis was based on the criteria of Zicat *et al*<sup>(10)</sup>, regarding expansive or linear type, and on De Lee and Charnley zones<sup>(11)</sup> regarding localization. For evaluations on femoral osteolysis, the criteria of Turíbio were used<sup>(12)</sup>.

Other variables were also assessed radiographically, such as the wear on the polyethylene, migration of the femoral component (subsidence) and femoral morphocortical index. All these were measured with a transparent plastic ruler divided into millimeters.

To describe the variables, we took into consideration the arithmetic mean, standard deviation (SD), median and maximum and minimum values. In the statistical analysis on non-parametric variables, Spearman's correlation test was used, while the Mann-Whitney test was used for parametric variables. Both of these were calculated using the SPSS software for Windows, version 14.0 (SPSS Inc, Chicago, IL, USA). We took P values less than 0.05 to be significant.

Statistical correlations were investigated in relation to the following outcomes: acetabular osteolysis versus clinical outcome; clinical outcome versus follow-up, femoral migration, polyethylene wear, femoral osteolysis and acetabular osteolysis; acetabular osteolysis versus follow-up, polyethylene wear and follow-up.

## RESULTS

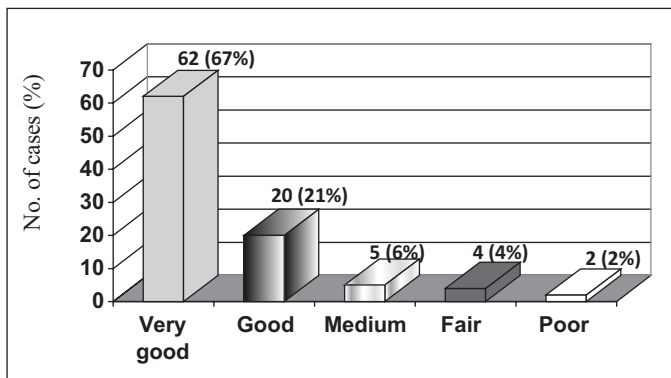
The Biomec prosthesis was used for 100 patients between 1988 and 2001. Of these, seven died during the later postoperative period for reasons unrelated to the surgical procedure. Because there was no recent assessment for these patients, they were excluded from the study. Another nine patients could not be located for reassessment. Thus, 84 patients and 93 hips were evaluated, i.e. there were nine cases of bilateral arthroplasty. Thirty-two of the patients (38%) were men and 52 (62%) were women. The mean age before the operation was 47 years (range 19 to 77 years). The right side was operated in 49 cases (58%) and the left side in 35 cases (42%).

The mean duration of follow-up was 10 years and six months. The shortest follow-up was four months and the longest was 20 years, with a median of nine years and SD of 4.8 years.

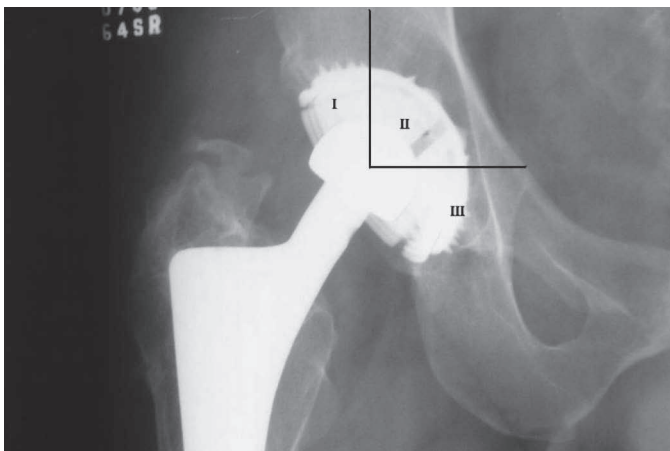
There were three cases of failure of both components (3.2%) and four cases of failure of the acetabular component alone (4.3%).

From analysis on the clinical results in accordance with the classification of D'Aubigné and Postel<sup>(9)</sup>, 82 hips (88%) presented good or very good results, as illustrated in Figure 1.

Osteolysis was present in 66 acetabula (75%) and was most frequently seen in the DeLee and Charnley zones two and three<sup>(11)</sup>, as presented in Figure 2, according to their location.

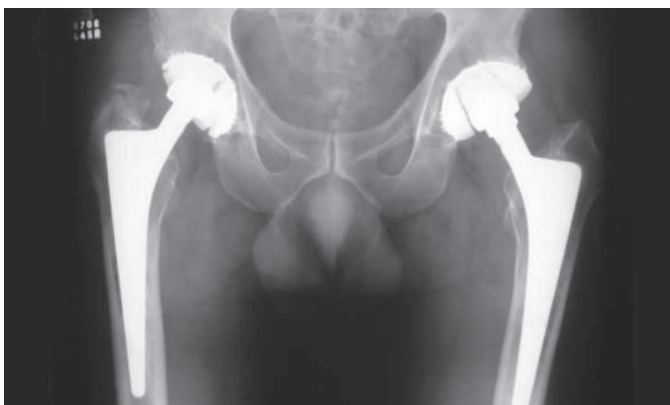

**Figure 1** – Sample distribution in accordance with the functional evaluation proposed by D'Aubigné and Postel<sup>(9)</sup>



**Figure 2** – Sample distribution according to the presence of osteolysis and location in accordance with the DeLee and Charley zones<sup>(11)</sup>. In this case, we considered that osteopenia was present in area II.

In Figure 3, we present a radiograph from a case with 17 years of follow-up on the right side and 16 years on the left side, without any signs of loosening of the implants. It shows signs of acetabular osteolysis, but without clinical repercussions.



**Figure 3** – Anteroposterior radiograph of the pelvis on a patient with 17 years of follow-up on the right side and 16 years on the left side.

Femoral osteolysis was present in 83 cases (98.8%), and it was classified in accordance with the criteria of Turíbio, as illustrated in Table 1 according to its location:

**Table 1** – Sample distribution in relation to femoral osteolysis, in accordance with the criteria of Turíbio

Turíbio grade	Cases	Percentage (%)
0	1	1.20
1	29	34.50
2	42	50.00
3	10	11.90
4	2	2.40

0 – absence of osteolysis

1 – osteolysis restricted to the region of the greater trochanter

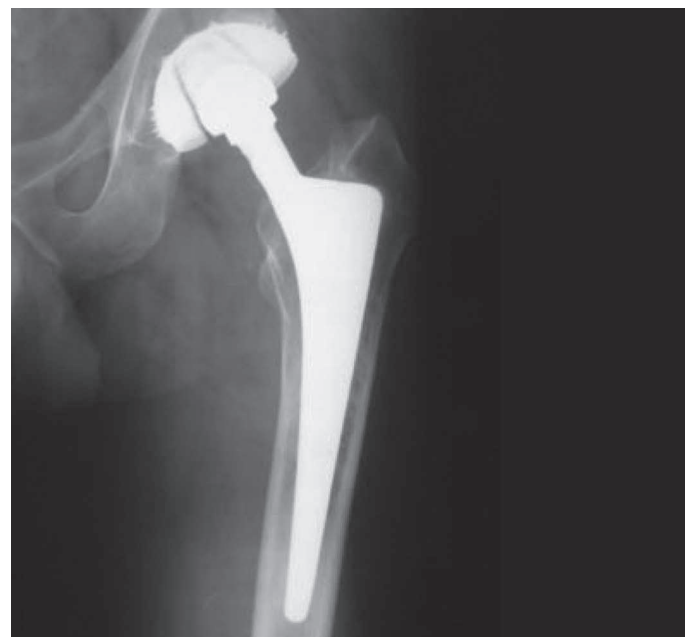2 – osteolysis extending from the region of the greater trochanter towards the lesser trochanter

3 – osteolysis affecting both the greater and the lesser trochanter and extending to the middle third of the diaphysis

4 – osteolysis throughout the region of the femoral implant.

In Figure 4, we present an example of femoral osteolysis affecting the regions of the greater and lesser trochanter (Turíbio 2), without compromising the stability of the femoral component.

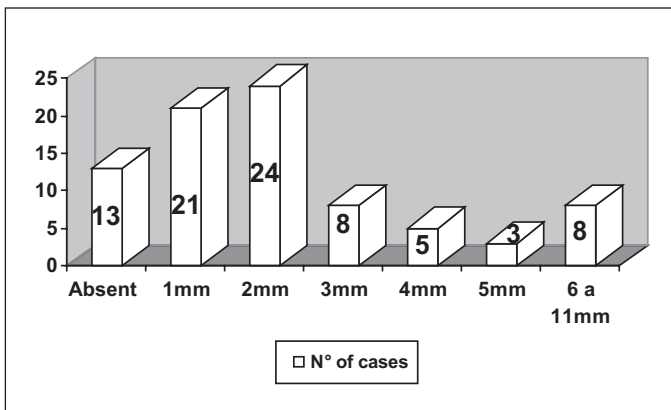
Polyethylene wear was present in 69 cases (82%), with a mean of 1.4 mm (range 0 to 5). Taking the mean duration of follow-up of 10 years and six months, the mean rate of polyethylene wear was 0.13 mm per year. The statistical analysis demonstrated that the occurrences of acetabular osteolysis were related to polyethylene wear



**Figure 4** – Radiograph on the left hip demonstrating femoral osteopenia affecting the regions of the greater and lesser trochanters, without compromising the stability and fixation of the femoral implant.

( $P = 0.04$ ). The wear on the polyethylene was also correlated with worsened clinical outcomes ( $P = 0.036$ ).

Femoral nail migration or “subsidence” was present in 67 cases (79.7%) and absent in 17 cases (20.3%), with a mean migration distance of 2.33 mm and median of 2 mm. Figure 5 provides a better illustration of the frequency of migration. The statistical analysis did not show any worsening of the clinical outcome through femoral migration ( $P = 0.009$ ).



**Figure 5** – Sample distribution according to the frequency and magnitude of migration of the femoral nail.

## DISCUSSION

The sex distribution in our sample (38% men and 62% women) was in accordance with other reports in the literature<sup>(13-15)</sup>. The mean age in our study (47 years) was also similar to reports in the literature, which describe mean ages ranging from 51 to 53 years<sup>(13-18)</sup>.

The clinical assessment showing that 80% of the results were good and very good was similar to what was found in a study using the Spotorno<sup>®</sup> prosthesis, a foreign model that formed the basis for the development of the prosthesis under examination here<sup>(13,14,18,19)</sup>. In the statistical analysis on the clinical outcome over the follow-up period, it was observed that there was a gradual decrease in functional grade as the length of follow-up increased, with  $P = 0.008$ . This can be explained in terms of wear on the implant with the passage of the years, thereby leading to a gradual decrease in the clinical score.

We did not find any statistical significance with regard to analyzing the prevalence of acetabular osteolysis (75%) in relation to the clinical outcome ( $P = 0.001$ ). This explains the finding of very good functional results despite the high prevalence of acetabular osteolysis. It is in line with what was reported by other authors, who did

not find any relationship between acetabular osteolysis and the clinical outcome<sup>(15,18)</sup>.

Femoral osteolysis presented even greater prevalence, such that it was observed in 98.8% of the cases. However, in around 85% of the cases, it only affected the regions of the greater and lesser trochanters and did not compromise the fixation and/or stability of the implant. This was demonstrated in a prospective study with evaluation of the bone mineral density around the prosthesis following Spotorno<sup>®</sup> arthroplasty, in which a significant decline in bone mass (21%) was found in the region of the trochanters over the first two years after the operation<sup>(20)</sup>. In the statistical analysis between femoral osteolysis and the clinical outcome, we also did not find any statistical significance ( $P = 0.124$ ).

Acetabular osteolysis presented a correlation with femoral osteolysis, with greater prevalence as the femoral osteolysis became more marked ( $P = 0.014$ ). This was very likely due to the accumulation of debris and penetration at the bone-implant interface.

The correlation between wear on the polyethylene and greater prevalence of acetabular osteolysis found in our study was statistically significant ( $P = 0.04$ ), and this had already been demonstrated by previous studies<sup>(21,22)</sup>.

The mean wear of 1.4 mm found in our series and the wear rate of 0.13 mm/year considering the mean follow-up of ten years and six months overlapped with the mean wear reported in the literature for cemented prostheses and was a smaller amount than shown in studies on uncemented (non-expansive) acetabula with shorter follow-up<sup>(23)</sup>.

The migration and accommodation of the femoral nail (subsidence) in 67 cases (80%), with a mean of 2.33 mm, was in line with the biomechanical theory put forward many years ago by Spotorno for wedge-shaped nails, which is now greatly valued by advocates of cemented and polished wedge-shaped nails without collars<sup>(24)</sup>. This makes us believe that until secondary fixation through osseointegration has been established, adjustments to the wedge-shaped quadrangular nail within the bone case.

## CONCLUSION

THA using the Biomec uncemented prosthesis presented good results in 88.2% of the cases, over a mean follow-up of ten years and six months among this cohort.

Although we found significant numbers of cases of femoral and acetabular osteolysis among our sample, these did not have any significance regarding modification of the clinical outcome.

## REFERENCES

1. Charnley J. The long-term results of low-friction arthroplasty of the hip performed as a primary intervention. *J Bone Joint Surg Br.* 1972;54(1):61-76.
2. Jones LC, Hungerford DS. Cement disease. *Clin Orthop Relat Res.* 1987;(225):192-206.
3. Chandler HP, Reineck FT, Wixson RL, McCarthy JC. Total hip replacement in patients younger than thirty years old. A five-year follow-up study. *J Bone Joint Surg Am.* 1981;63(9):1426-34.
4. Judet R, Siguier M, Brumpt B, Judet T. A noncemented total hip prosthesis. *Clin Orthop Relat Res.* 1978;(137):76-84.
5. Spotorno L, Romagnoli S, Ivaldo N, Grappiolo G, Bibbiani E, Blaha DJ, Guen TA. The CLS system. Theoretical concept and results. *Acta Orthop Belg.* 1993;59(Suppl 1):144-8.
6. Macedo CAS, Scheidt RB, Palma HM, Rosito R, Weissheimer W, Galia CR. Artroplastia total de quadril de spotorno: resultados clínicos e radiográficos. *Acta Ortop Bras.* 2008;16(1):17-22.
7. Zweymüller K, Semlitsch M. Concept and material properties of a cementless hip prosthesis system with Al<sub>2</sub>O<sub>3</sub> ceramic ball heads and wrought Ti-6Al-4V stems. *Arch Orthop Trauma Surg.* 1982;100(4):229-36.
8. Zweymüller K. A cementless titanium hip endoprosthesis system based on press-fit fixation: basic research and clinical results. *Instr Course Lect.* 1986;35:203-25.
9. D'Aubigné RM, Postel M. Functional results of hip arthroplasty with acrylic prosthesis. *J Bone Joint Surg Am.* 1954;36(3):451-75.
10. Zicat B, Engh CA, Gokcen E. Patterns of osteolysis around total hip components inserted with and without cement. *J Bone Joint Surg Am.* 1995;77(3):432-9.
11. DeLee JG, Charnley J. Radiological demarcation of cemented sockets in total hip replacement. *Clin Orthop Relat Res.* 1976;(121):20-32.
12. Turíbio FM. Alterações radiográficas do fêmur nas artroplastias totais do quadril com prótese não cimentada de Parhofer-Monch [tese]. São Paulo: Escola Paulista de Medicina, Universidade Federal de São Paulo; 1996.
13. Spotorno L, Schenk RK, Dietschi C, Romagnoli S, Mumenthaler A. [Personal experiences with uncemented prostheses]. *Orthopade.* 1987;16(3):225-38.
14. Bulow JU, Scheller G, Arnold P, Synatschke M, Jani L. Follow-up (6-9 years) results of the uncemented CLS Spotorno stem. *Arch Orthop Trauma Surg.* 1996;115(3-4):190-4.
15. Aldinger PR, Breusch SJ, Lukoschek M, Mau H, Ewerbeck V, Thomsen M. A ten- to 15-year follow-up of the cementless spotorno stem. *J Bone Joint Surg Br.* 2003;85(2):209-14.
16. Schramm M, Keck F, Hohmann D, Pitto RP. Total hip arthroplasty using an uncemented femoral component with taper design: outcome at 10-year follow-up. *Arch Orthop Trauma Surg.* 2000;120(7-8):407-12.
17. Vidyadhara S, Rao SK. Uncemented primary press-fit total hip arthroplasty: a 3 to 6 years of experience. *J Orthop Surg (Hong Kong).* 2007;15(1):50-5.
18. Tauber C, Kidron A. Total hip arthroplasty revision using the press-fit CLS Spotorno cementless stem. Twenty-four hips followed between 1987 and 1998. *Arch Orthop Trauma Surg.* 2000;120(3-4):209-11.
19. Macedo CAS, Scheidt RB, Palma HM, Rosito R, Weissheimer W, Galia CR. Artroplastia total do quadril de Spotorno. *Acta Ortop Bras.* 2008;16(4):217-22.
20. Zerahn B, Lausten GS, Kanstrup IL. Prospective comparison of differences in bone mineral density adjacent to two biomechanically different types of cementless femoral stems. *Int Orthop.* 2004;28(3):146-50.
21. Mallory TH, Head WC, Lombardi AV Jr. Tapered design for the cementless total hip arthroplasty femoral component. *Clin Orthop Relat Res.* 1997;(344):172-8.
22. Robinson RP, Deysine GR, Green TM. Uncemented total hip arthroplasty using the CLS stem: a titanium alloy implant with a corundum blast finish. Results at a mean 6 years in a prospective study. *J Arthroplasty.* 1996;11(3):286-92.
23. Joshi RP, Eftekhari NS, McMahon DJ, Nercessian OA. Osteolysis after Charnley primary low-friction arthroplasty. A comparison of two matched paired groups. *J Bone Joint Surg Br.* 1998;80(4):585-90.
24. Engh CA, Massin P, Suthers KE. Roentgenographic assessment of the biologic fixation of porous-surfaced femoral components. *Clin Orthop Relat Res.* 1990;(257):107-28.