



Research article

Impact of type III collagen on monosodium iodoacetate-induced osteoarthritis in rats

Gehad A. Abdel Jaleel^a, Dalia O. Saleh^a, Sally W. Al-Awdan^a, Azza Hassan^b, Gihan F. Asaad^{a,*}^a Pharmacology Department, National Research Centre, 33 El Buhouth st-Dokki, Cairo Governorate 12622 Egypt^b Department of Pathology, Faculty of Veterinary Medicine, Cairo University Egypt

ARTICLE INFO

Keywords:

Monosodium iodoacetate
Osteoarthritis
Cartilage
Rats
Type III collagen
Nutrition
Musculoskeletal system
Pharmacology
Toxicology
Radiology

ABSTRACT

Osteoarthritis (OA) is a degenerative chronic disease that affects various tissues surrounding the joints, such as the subchondral bone and articular cartilage. The purpose of the study was to investigate the impact of collagen type III (CIII; 10 mg/kg; p.o.) on OA evidenced by restoration of articular cartilage structural changes as well as inflammatory responses using an established rat model of OA. OA was induced in rats by a single intra-articular injection of monosodium iodoacetate (MIA) through the right knee of the rats. Oral administration of CIII was undergone for 14 consecutive days. Changes in joint volume were measured throughout the experiment period with one-week intervals. At the end of the experiment, the rats were placed in the activity cage, and their activities were counted. Oxidative stress and nitrosative biomarkers were assessed by measuring the serum levels of malondialdehyde (MDA), reduced glutathione (GSH) and nitric oxide (NOx). Moreover, inflammatory markers viz. interleukin-6 (IL-6), interleukin-1 β (IL-1 β) and tumor necrosis nuclear factor-alpha (TNF- α) were measured. In addition, radiographic analysis and histopathological examination of the rat's knee were performed. The results of the current study revealed that oral treatment of MIA-induced osteoarthritic rats with CIII (10 mg/kg) for two weeks showed a marked decrease in the joint volume which led eventually to a prominent increase in the motor activity. Furthermore, treatment with CIII restored the serum levels of MDA, GSH, NOx, IL-6, IL-1 β and the TNF- α . Furthermore, CIII succeeded to ameliorate the detrimental effect of MIA on radiographic images and histopathological alterations of the joint. From these findings, it can be concluded that CIII has regenerative and anti-inflammatory properties, thus has the ability to counteract MIA-induced OA in rat. Finally, CIII is said to be a potential anti-osteoarthritic candidate.

1. Introduction

Osteoarthritis (OA) is a progressive joint disease that arises as a consequence of a multifaceted system of mechanical, genetic, chemical and molecular interaction [1]. Despite the normal bone remodelling enhanced by osteoclast and osteoblast cells under the control of parathyroid hormone, this complex system gives rise to destruction of the chondrocyte matrix leading to degeneration of the joint cartilage which is a characteristic of OA. However, synovitis is also participating in the installation of the pathology [2]. Radiography images of OA show synovial membrane thickening and articular surface erosions in degenerative arthritis. It can be used effectively in the detection of degenerative arthritis lesions [3,4].

Reactive oxygen species (ROS) are formed at low level in articular chondrocytes maintaining cartilage homeostasis where they control

chondrocyte apoptosis, gene expression, and inflammatory cytokine production. Conversely, high ROS production have been observed in patients with OA [5]. Thus, oxidative and nitrosative stress are well thought-out to be the hallmark in OA pathogenesis demonstrated by the presence of lipid peroxidation products, and nitrated products in the biological fluids and the cartilage of OA and in animal models of OA [1]. Besides, degradation of the joint cartilage as a result of OA is mediated by extreme release of inflammatory cytokines viz. interleukin-6 (IL-6), interleukin-1 β (IL-1 β), and tumor necrosis factor- α (TNF- α) [6]. Consequently, oxidative status and inflammatory cytokines are realistic indices for estimating the repair of OA upon treatment.

Some indications showed that articular chondrocytes can recapitulate the collagen network architecture if the articular cartilage is degenerated, which explains the synthesis of collagen as a regenerative response to OA in patients. Unfortunately, it was found that the turnover

* Corresponding author.

E-mail address: dr_g.asaad@yahoo.com (G.F. Asaad).

of endogenous collagen is very slow, especially in mature articular cartilage [7]. Moreover, different species of collagen have been chosen to fight the joint degeneration depending on the fact that collagen is a normal constituent of the joint and can also be easily absorbed after oral administration from intestinal wall and accumulate in cartilage [8].

Collagen type I and II were previously the major products *in vivo*, but possible contribution of other types of collagen were left open [9]. Recent research also reported a therapeutic effect of collagen type V as well [10]. However, type III collagen (CIII) is a fibrillar collagen consisting of high level of glycine; an essential amino acid, and proline; a non-essential amino acid, formed from glycine and both are important for the function of joints and tendons. CIII is secreted by fibroblasts and other mesenchymal cells [11].

Finally, our study was designed to assess the promising effect of CIII as a new therapeutic approach for treatment of OA induced experimentally by intra-articular injection of MIA in rats. This promising anti-osteoarthritic effect is evidenced by repair of articular cartilage structure and amelioration of the inflammatory responses. To achieve this goal, the rats' joint volume and their motor activity were measured and the serum oxidative stress and inflammatory biomarkers were also evaluated. Furthermore, radiographic analysis and histopathological examination of the rats' knee were done.

2. Material and methods

2.1. Drugs and chemicals

Porcine collagen type III (Sigma-Aldrich, USA) administered (10 mg/kg) orally for 14 successive days after single intra-articular injection of MIA (60 mg/ml in 0.9% sterile saline).

2.2. Animals

Thirty mature Wistar rats (150–200grams) provided by the animal breeding unit at the National Research Centre -Dokki- Giza – Egypt were randomly allocated to three groups (10 rats/group) for this study. Animals were provided water and food ad libitum, the room temperature was kept at 20 ± 1 °C on a 12-hour light/12-hour dark cycle. Suitable procedures were taken to diminish pain or distress of the animals, and all experimental measures were approved by an ethics committee of the

National Research Centre and adhered to the Principles of Laboratory Animal Care (NIH publication #85–23, revised in 1985).

2.3. Osteoarthritis induction

Intra-articular injection of MIA (60 mg/ml in 0.9% sterile saline) with total volume of 50 μ l through the patellar ligament. The left control knee was injected with physiological saline water [12].

2.4. Study design

Rats were randomly allocated to three groups (10 rats/group). Group I serves as normal control group injected with saline, however groups II (OA group) and III (CIII group) were injection of MIA through the intrapatellar ligament of the right knee of the rats. Group III (CIII group) orally received type III collagen (CIII; 10 mg/kg bwt) for 14 consecutive days. Changes in joint volume were measured throughout the experiment period with one-week interval. At the end of the experiment, motor activities were determined as score/5 s using activity cage. Serum was used for determination of oxidative stress and inflammatory biomarkers. Radiographic imaging and histopathological examination of the rats' knee were also performed. A flowchart showing the study design is presented in Figure 1.

2.4.1. Measuring joint volume

Change in knee joint volume was measured throughout the experiment period with one-week interval by using a digital plethysmometer [13].

2.4.2. Evaluation of motor activity by activity cage test

Spontaneous exploratory activity is measured as a way to evaluate continuing algia [14,15]. Animals are tested in clean, clear vivarium plastic cages ($42 \times 25 \times 20$ cm) enclosed in a cage stand. Photobeam Activity System (San Diego Instruments, San Diego, CA). Adjacent beams are 5 cm apart and beam intermissions are automatically noted. One set of photo-beams is established at foot level to measure ambulation, and an upper set of photo-beams is set 11 cm above ground to measure rearing. Activity is monitored in a low-lit room for a 60-minute period.

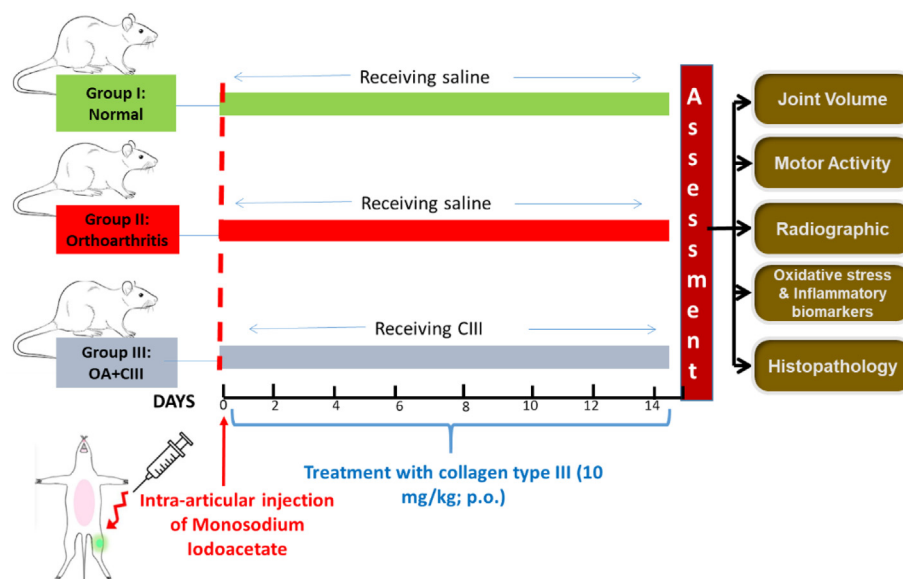


Figure 1. A flowchart showing the methodology of the study.

2.4.3. Blood sampling

Blood samples were collected from retro-orbital plexus after being lightly anesthetized with diethyl ether, sera were extracted by means of a high-speed centrifuge (VS-600CFi, Korea) at 3500 rpm for 20 min.

2.4.4. Oxidative and nitrosative stress markers

Estimation of Reduced glutathione (GSH) is based on the reduction of 5,5-dithiobis (2-nitrobenzoic acid) to yield a yellow compound. The reduced chromogen absorbance is measured at 405 nm using a commercial kit that was used (Biodiagnostic, Egypt) [16].

The nitric oxide (NO) [17,18] was detected by measuring the nitrate/nitrite (NO_x) in serum, the stable degradation products of NO based on the Griess reaction, in which a chromophore absorbance is measured at 540 nm.

Malondialdehyde (MDA) is a measure of lipid peroxidation, was examined using spectrophotometer according to Uchiyama and Mihara 1979. The absorbance of the thiobarbituric-MDA adduct was measured spectrophotometrically at 532 nm [19].

2.4.5. Measuring cytokine markers

Interleukin-6, TNF- α and IL-1 β were assessed using a rat ELISA kit (Invitrogen, USA). The absorbance of all samples were measured using a Spectramax (M2, Molecular Devices, USA) at 450 nm.

2.4.6. Radiographic analysis of knee cartilage

The X-ray source was established at a voltage of 50 kV and a current of 200 μ A, and the beam was filtered using a 0.5-mm aluminum filter. The scanning angular rotation was 180° with an angular step of 0.5° [20]. The voxel size was fixed at 8.9 μ m. The morphometric indices of the bone region were determined using CTAn software (SkyScan 1076; SkyScan, Belgium).

The X-ray imaging were exposed to quantitative evaluation and the profundity of erosion was sorted on a scale of 0–4, as follows: grade 0, surface normal in appearance; grade 1, minimal erosion; grade 2, erosion spreading into the superficial or middle layers only; grade 3, erosion extending into the deep layers; grade 4, erosion extending to subchondral bone [21].

2.4.7. Histopathological analysis and mean pathological scoring

Histopathological examination was achieved according to Gerwin et al 2010 [22], where the whole knee joints were removed after anaesthesia and fixed overnight with 4% paraformaldehyde (Sigma-Aldrich) at 4 °C on a shaker. The knee joints were decalcified in 14% EDTA for 5 days. Later, joints were dehydrated by gradient alcohol and infiltrated by xylene and paraffin. Lastly, samples were fixed in paraffin, split at 6 μ m on a sagittal plane and stained with H&E using standard protocols. Mean pathological scoring was processed by evaluating cartilage destruction, inflammation and pannus formation using the OARSI score on a scale of 0–5 points.

2.5. Statistical analysis

All the values are presented as means \pm standard error. Comparisons between different groups were done using One-Way ANOVA followed by Tukey's multiple comparison post hoc tests. Kruskal-Wallis ANOVA test followed by Mann-Whitney *U* test was performed for non-parametric scoring. *P* < 0.05 was considered significant. GraphPad prism® software (version 6 for Windows, San Diego, California, USA) was used to perform these statistical tests.

3. Results

3.1. Measuring joint volume

The baseline of the knee joint volume was measured for all the groups before induction of the OA via MIA. The change in the knee joint volume

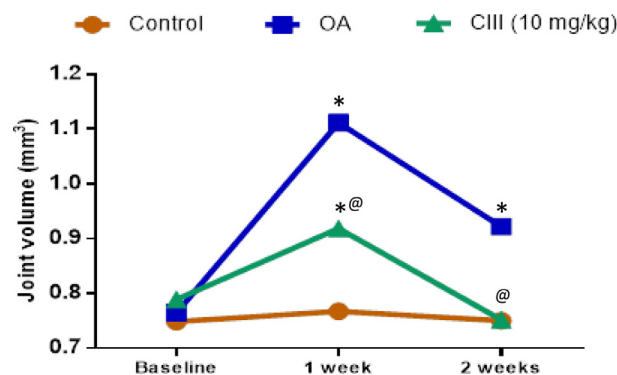


Figure 2. Effects of CIII on the knee joint swelling volume in a monosodium iodoacetate (MIA)-induced rat model of osteoarthritis. Unilateral OA was induced in rats by a single intra-articular injection of MIA through the intrapatellar ligament of the right knee of the rats. Oral administration of CIII was undergone for consecutive 14 days. Twenty-four hours after the last dose of the drug, joint volume was measured. Data is presented as mean \pm S.E. (n = 6–10). Comparisons between different groups were carried out using one-way analysis of variance (ANOVA) followed by Tukey's multiple comparison post hoc tests. The values are expressed (mean \pm standard error, n = 8/group. *p* < 0.05 indicates a significant difference from the osteoarthritic and control group. **p* < 0.05 indicates a significant difference from the control group. @*p* < 0.05 indicates a significant difference from the osteoarthritic group.

was recorded for two weeks with one-week interval for all the animal groups. Results obtained in Figure 2 showed a significant (*P* < 0.05) swelling of the knee joint volume reaching up to 0.92 ± 0.023 mm in osteoarthritic group as compared to the normal control group (0.75 ± 0.024 mm). Oral administration of CIII (10 mg/kg) to osteoarthritic rats exhibited a significant decrease in joint volume after two weeks of treatment (0.75 ± 0.02 mm) as compared to the osteoarthritic group. Our results also revealed that CIII succeeded to normalize the rats' knee volume after two weeks of treatment.

3.2. Evaluation of motor activity by activity cage test

Results obtained in Figure 3 showed a marked decrease in motor activity of the osteoarthritic group after two weeks of induction (59.3 ± 5.2 score/5min) as compared to the normal group (162.3 ± 10.8 score/5min). A notable increase in motor activity was observed in the group

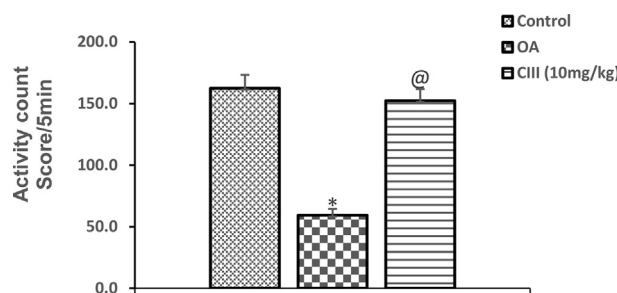


Figure 3. Effects of CIII on the motor activity in a monosodium iodoacetate (MIA)-induced rat model of osteoarthritis. Unilateral OA was induced in rats by a single intra-articular injection of MIA through the intrapatellar ligament of the right knee of the rats. Oral administration of CIII was undergone for consecutive 14 days. Twenty-four hours after the last dose of the drug, rats were placed in the activity cage and their activity was counted. Results recorded as (Score/5min). The values are expressed (mean \pm standard error, n = 10/group. OA showed activity count of 59.33 ± 5.2 vs 162.33 ± 10.82 however, CIII showed activity count of 152.33 ± 9.45 vs 59.33 ± 5.2 . Comparisons between different groups were carried out using one-way analysis of variance (ANOVA) followed by Tukey's multiple comparison post hoc tests. **p* < 0.05 indicates a significant difference from the control group. @*p* < 0.05 indicates a significant difference from the osteoarthritic group.

treated with CIII for two weeks (152.3 ± 9.5 score/5min) as compared to the osteoarthritic group. It is also worthy to mention that there was no significant difference between treated and normal control group which indicates the restoration of the rats' normal activity.

3.3. Oxidative and nitrosative stress biomarkers

Oxidative stress biomarkers were estimated in the sera and the obtained results in Figure 4 showed a prominent decrease in GSH in osteoarthritic induced group (3.69 ± 0.09 mmol/L) when compared to the normal control one (5.23 ± 0.07 mmol/L). Oral treatment of osteoarthritic rats with CIII causes an elevation in GSH level (4.35 ± 0.09 mmol/L) as compared to osteoarthritic one (Figure 4a). Moreover, a significant

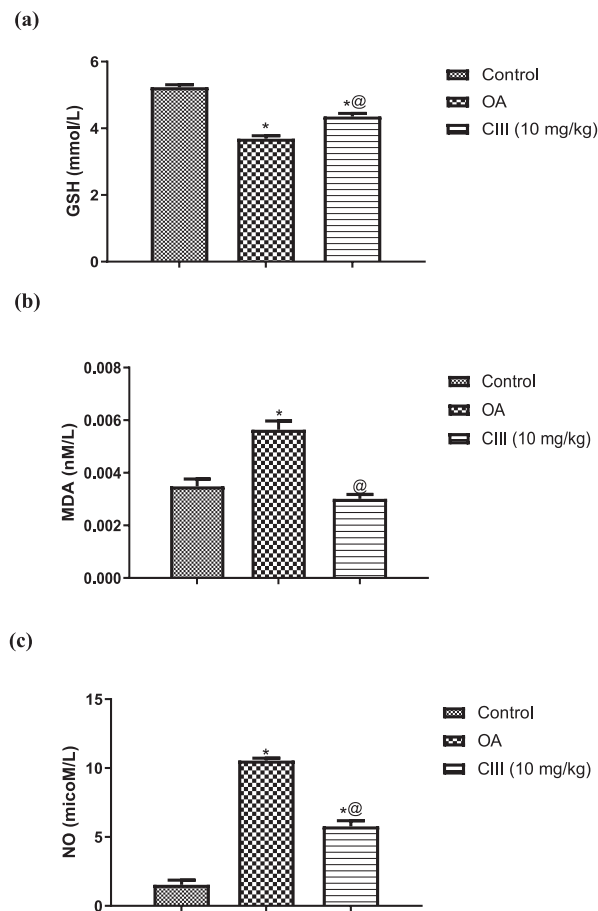


Figure 4. Effects of CIII on the serum level of oxidative and nitrosative stress biomarkers in a monosodium iodoacetate-induced rat model of osteoarthritis. Unilateral OA was induced in rats by a single intra-articular injection of MIA through the intrapatellar ligament of the right knee of the rats. Oral administration of CIII was undergone for consecutive 14 days. Twenty-four hours after the last dose of the drug, blood samples were collected and serum was separated for determination of oxidative and nitrosative stress biomarkers. Spectrophotometric assay was used to measure the serum levels of reduced glutathione (GSH) (a), malondialdehyde (MDA) (b), and nitric oxide (NO) (c). The measured levels were expressed as (mean \pm standard error, $n = 10$ /group). OA shows GSH, MDA, and NO values of 3.68 ± 0.09 vs 5.23 ± 0.07 mmol/L, 0.00563 ± 0.00033 vs 0.00348 ± 0.00028 nmol/L and 10.54 ± 0.17 vs 1.53 ± 0.33 mmol/L, respectively. However, CIII shows values of 4.35 ± 0.09 vs 3.68 ± 0.09 mmol/L, 0.00394 ± 0.00017 vs 0.00563 ± 0.00033 nmol/L and 5.76 ± 0.41 vs 10.54 ± 0.17 mmol/L, respectively. Comparisons between different groups were carried out using one-way analysis of variance (ANOVA) followed by Tukey's multiple comparison post hoc tests. * $p < 0.05$ indicates a significant difference from the control group. @ $p < 0.05$ indicates a significant difference from the osteoarthritic group.

increase in MDA level and NO concentrations were observed in the osteoarthritic induced group (5.64 ± 0.33 and 10.54 ± 0.17 mmol/mL) when compared to the normal control one (3.48 ± 0.28 and 1.53 ± 0.33 mmol/L) mmol/mL respectively. CIII showed a marked decrease in MDA and NO levels (3.95 ± 0.17 and 5.76 ± 0.41 mmol/mL) as compared to osteoarthritic one (Figures 4b, c). These results indicate that CIII might have anti-oxidant effects by inhibiting oxidative stress biomarkers in the osteoarthritic rat model.

3.4. Inflammatory cytokines

We investigated the effects of CIII on serum levels of IL-6, TNF- α and IL-1 β as the inflammatory factors help in maintaining tissue damage and chronic inflammation throughout the progression of OA. Results obtained in Figure 5 showed an elevated serum level of IL-6, TNF- α and IL-1 β in osteoarthritic group (112.87 ± 3.71 , 144.47 ± 4.37 and 132.9 ± 4.07 pg/mL, respectively), compared with the normal control group (15.6 ± 0.66 , 26.57 ± 0.83 and 17.93 ± 0.82 pg/mL, respectively). Treatment with CIII for two weeks exhibited significantly ($p < 0.05$) decreased serum levels of IL-6, TNF- α and IL-1 β (24.92 ± 0.66 , 50.73 ± 1.85 and 28.45 ± 0.89 pg/mL, respectively). These results indicate that

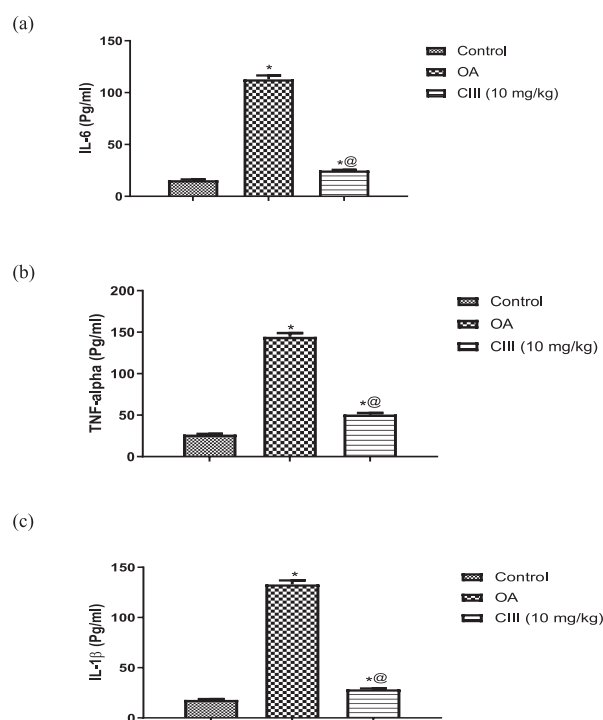


Figure 5. Effects of CIII on the serum level of inflammatory cytokine biomarkers in a monosodium iodoacetate-induced rat model of osteoarthritis. Unilateral OA was induced in rats by a single intra-articular injection of MIA through the intrapatellar ligament of the right knee of the rats. Oral administration of CIII was undergone for consecutive 14 days. Twenty-four hours after the last dose of the drug, blood samples were collected and serum was separated for determination of inflammatory cytokine biomarkers. Enzyme-linked immunosorbent assays was used to measure the serum levels of IL-6 (a), TNF- α (b), and IL-1 β (c). The measured levels were expressed as (mean \pm standard error, $n = 10$ /group). OA shows IL-6, TNF- α , and IL-1 β values of 112.86 ± 3.71 vs 15.60 ± 0.66 pg/mL, 114.46 ± 4.37 vs 26.56 ± 0.83 pg/mL and 132.90 ± 4.07 vs 17.93 ± 0.82 pg/mL, respectively. However, CIII shows values of 24.91 ± 0.009 vs 112.86 ± 3.71 pg/mL, 50.73 ± 1.84 vs 114.46 ± 4.37 pg/mL and 5.76 ± 0.41 vs 28.45 ± 0.88 vs 132.90 ± 4.07 pg/mL, respectively. Comparisons between different groups were carried out using one-way analysis of variance (ANOVA) followed by Tukey's multiple comparison post hoc tests. * $p < 0.05$ indicates a significant difference from the control group. @ $p < 0.05$ indicates a significant difference from the osteoarthritic group.

CIII might have a powerful anti-inflammatory effects by inhibiting inflammatory factors in the osteoarthritic rat model.

3.5. Radiographic analysis of knee cartilage

Twenty-four hours after administration of the last dose of the drug, animals were anesthetized. Injury of the articular cartilage surface was assessed using India ink at after the MIA injection. Totally, ventrodorsal radiographs of the knee joint (red circle) are shown in Figure 6. The normal joint (Figure 6A) showed no distension with normal joint space radiodensity. The femoral condyles and proximal tibia are with normal surface (white arrow). The osteoarthritic changes (Figure 6B) reveal an increase in the joint radiodensity and narrowing in the joint space with distension. The femoral condyles and proximal tibia are with rough surface with new osteophytic formation (red arrow). The knee joint (Figure 6C) showed almost normal joint space with slight osteophytic reactivity at the femoral condyles and the proximal tibia surface nearly normal (yellow arrow). Our results revealed that CIII may have a good ameliorating effect against MIA-induced OA. The quantitative evaluation of X-ray imaging has shown a reduced score in the group treated with CIII as presented in Figure 6D.

3.6. Histopathological analysis

The photomicrograph of joint is illustrated in Figure 7. There was no histopathological variation in the joint of normal rats which showed normal histological structure of the cartilaginous articular surface and synovial membrane (Figures 7a,b). However, noticeable resorption of the articular cartilaginous structure with presence of numerous osteoclasts on resorption sites of eroded subchondral bone (Figure 7c) were demonstrated in the joint of arthritic group. In addition, hyperplasia with fibrosis (pannus formation) was detected in the synovial membrane (Figure 7d) associated with peri-articular edema and inflammatory cells infiltration as well as congested blood vessels (Figure 7e). Treatment with CIII induced mild hyperplasia of the lining synovial cell membrane (Figure 7f).

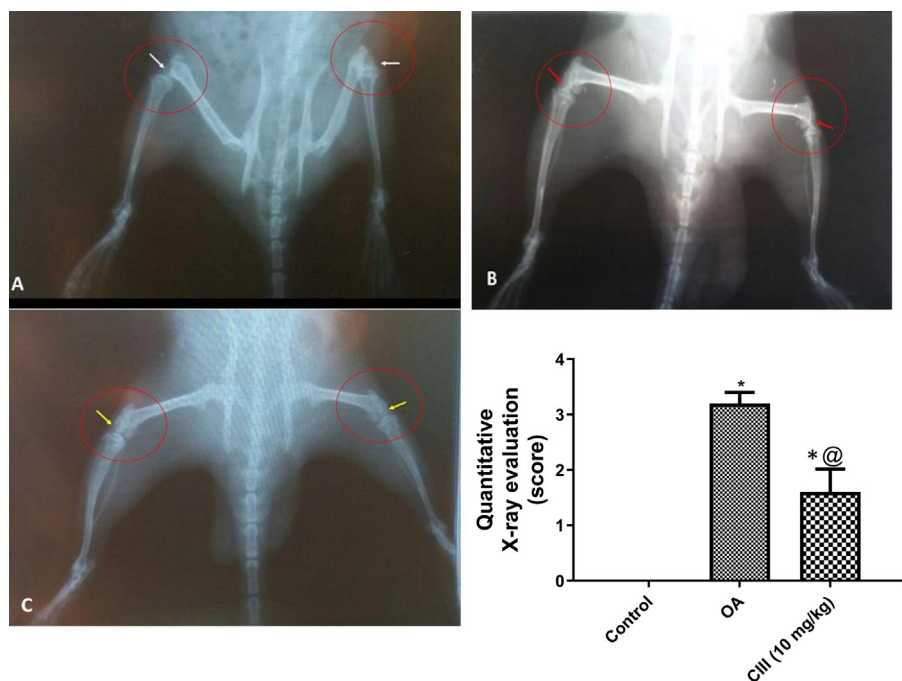


Figure 6. Effects of CIII as quantitatively assessed by X-ray imaging in a monosodium iodoacetate-induced rat model of osteoarthritis. Ventrodorsal radiographs of the knee joint (red circle) showing: the normal joint (A) without distension and normal joint space radiodensity. The femoral condyles and proximal tibia are with normal surface (white arrow). The osteoarthritic changes (B) reveals increase joint radiodensity and narrowing in joint space with distension. The femoral femoral condyles and proximal tibia are with rough surface with new osteophytic formation (Red arrow). The knee joint (C) showed almost normal joint space with slight osteophytic reactivity at the femoral condyles and the proximal tibia surface nearly normal (yellow arrow). Quantitative assessment of X-ray imaging was performed according to score from 1-4 (D). The measured levels were expressed as (mean \pm standard error, n = 10/group). Comparisons between different groups were carried out using Kruskal-Wallis non-parametric ANOVA test followed by Mann-Whitney U test. *p < 0.05 indicates a significant difference from the control group. @p < 0.05 indicates a significant difference from the osteoarthritic group.

3.7. The mean pathologic score of various histopathological parameters

The mean pathologic score of various histopathological parameters estimated in the joints of different treated groups were illustrated in Table 1. Results obtained in Table 1 showed a significant increase OARSI scores ($2.8^* \pm 0.20$, $4.40^* \pm 0.00$ and 0.2 ± 0.20 respectively), compared with the normal control group Treatment with CIII for two weeks showed significantly (p < 0.05) lower OARSI scores ($1.6^{\textcircled{a}} \pm 0.4$, $2.2^{\textcircled{a}} \pm 0.2$ and $2.4^{\textcircled{a}} \pm 0.4$ respectively). These results indicate that CIII might have anti-inflammatory effects and can protect the knee joint structure of the osteoarthritic rat model.

4. Discussion

Treatment of OA is an attempt to reduce symptoms such as pain associated with the degenerative disease, also the therapists are trying to improve the condition of the articular joint and restoring its normal function. Available drugs are synthetic aiming to decrease pain. Nowadays discovering treatments from natural sources is a global trend to reduce the adverse effect of synthetic compounds. This study is an attempt to simulate human OA by articular injection of MIA in rats. Previous studies have proved that both collagen type II and type III are covalently cross linked at the surface of the knee joint [23]. To our knowledge, the current investigation is the first to evaluate the therapeutic effect of CIII against induced OA, hence the aforementioned results are novel compared to pre-existing treatments.

In the current study, local injection of MIA, disrupts chondrocyte metabolism due to its role as an inhibitor of glycolysis, causing cartilage deterioration. The histopathology of the collapsed joint simulates the human state which is the main advantage of this model [24]. At later stages, exposed subchondral bone and damaged synovium is associated with joint pain. The use of the MIA chemical model in compound development allows for the use of preventative and therapeutic protocols over the development and maintenance of OA-like pain [25].

The current results revealed that induction of MIA cause a prominent swelling of the knee joint evidenced by elevation of the joint volume compared to control group injected with saline. This increase reached its

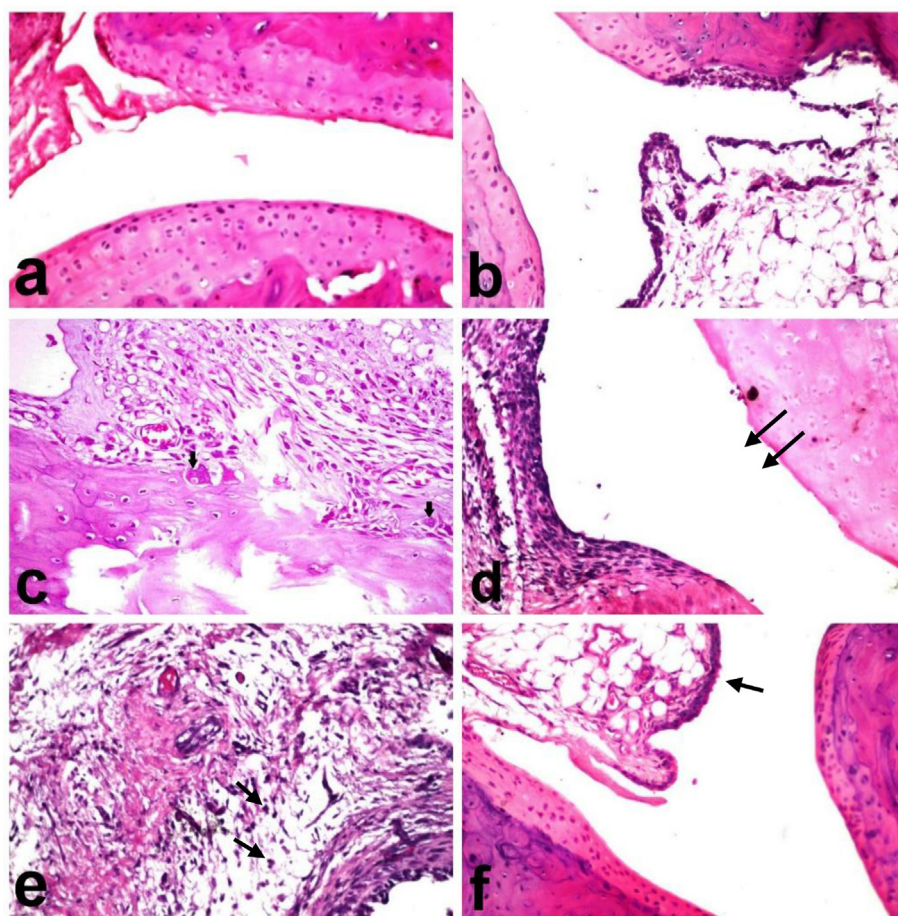


Figure 7. Effects of CIII on the histopathological alterations in a monosodium iodoacetate-induced rat model of osteoarthritis. Photomicrograph of joint of (a, b) normal rats showing normal histological structure of the cartilaginous articular surface (a) and normal synovial membrane (b); (c, d, e) arthritic group showing marked resorption of the articular cartilaginous structure with presence of numerous osteoclasts (arrows) on resorption sites of eroded subchondral bone (c) and pannus formation (arrow) (d) as well as peri-articular edema and inflammatory cells infiltration (arrow) (e); (f) CIII-treated group showing mild hyperplasia of the lining synovial cell membrane (arrow) (stain:H&E, 40X).

Table 1. Effects of CIII on Mean pathologic score of various histopathological parameters in a monosodium iodoacetate-induced rat model of osteoarthritis.

Parameter/group	Cartilage degeneration	Inflammation	Pannus formation
Normal	0.20 ± 0.20	0.00 ± 0.00	0.20 ± 0.20
Osteoarthritic	2.80* ± 0.20	4.40* ± 0.40	4.80* ± 0.20
OA + CIII	1.60 [@] ± 0.40	2.20 [@] ± 0.20	2.40 [@] ± 0.40

Table 1 Represents the quantitative data pertaining to histopathological changes of the cartilaginous structures of the knee joints (Figure 7).

Unilateral OA was induced in rats by a single intra-articular injection of MIA through the intrapatellar ligament of the right knee of the rats. Oral administration of CIII was undergone for consecutive 14 days. Twenty-four hours after the last dose of the drug, rats were sacrificed, the knee joints were decalcified in 14% EDTA for 5 days. Later, the joints were dehydrated by gradient alcohol and infiltrated by xylene and paraffin. Finally, samples were embedded in paraffin, sectioned at 6 μm on a sagittal plane and stained with H&E using standard protocols.

The measured levels were expressed as (mean ± standard error, n = 10/group).

Mean pathological scoring was processed by evaluating cartilage degeneration, inflammation and pannus formation using the OARS score on a scale of 0–5 points. Results obtained in **Table 1** showed a significant increase in mean pathological score of cartilage damage, inflammation and pannus formation (2.8* ± 0.20, 4.40* ± 0.00 and 0.2 ± 0.20 respectively), compared with the normal control group. Treatment with CIII for two weeks exhibited significantly (p < 0.05) decreased mean pathological score of cartilage damage, inflammation and pannus formation (1.6[@] ± 0.4, 2.2[@] ± 0.2 and 2.4[@] ± 0.4 respectively). Comparisons between different groups were carried out using Kruskal-Wallis non-parametric ANOVA test followed by Mann-Whitney U test.

*p < 0.05 indicates a significant difference from the control group.

[@]p < 0.05 indicates a significant difference from the osteoarthritic group.

peak at day seven after MIA injection and was sustained till the termination of the study. These results are aligned with those of Young *et al* [26] who found that the knee joint diameters significantly increased after MIA injections.

Swelling in the joint can be attributed to the inflammatory exudation and synovial infiltration after injection of MIA [27]. This elevation in the joint volume was confirmed microscopically where joint of osteoarthritic rats showed hyperplasia with fibrosis of the synovial membrane with resorption of the articular cartilage surface and edema with

inflammatory cells infiltration in the surrounding cartilage with congested blood vessels. Our histopathological studies are similar to those observed previously [28] by Nwosu *et al* who recorded the presence of abnormal chondrocyte morphology, increased number of blood vessels that crossed the osteochondral junction, synovitis and inflammatory cells infiltration into the synovium after MIA injection.

Administration of CIII (10 mg/kg) has shown a significant reduction in joint volume as compared to the osteoarthritic group, but difference in size remained between osteoarthritic and treated rats. It has suggested

that oral collagen is absorbed via intestinal epithelial cells [29]. Thus, blood supply of the synovial membrane and capsule of joints and with the circulation to tendons [30] can be incorporated to repair the joint using CIII. The effect of CIII was also confirmed by histological studies which showed mild hyperplasia in synovial lining cell membrane probably due to reducing the inflammation. Therefore, CIII has succeeded to attenuate the marked hyperplasia of osteoarthritic rats. According to molecular analysis, CIII was found to be strongly linked to collagen type II in the joints' cartilage. Although CIII is a component of the extracellular matrix of the articular joints, no data was obtained about its ameliorative role as stated for collagen type I, II and V against induced OA [8,12]. The protective effect observed may be similar to the wound-healing role of CIII in skin and connective tissues based on collagen type I [31].

The motor activity of osteoarthritic rats induced with MIA had been assessed using activity cage method at day 14 after MIA injection, and it was observed that osteoarthritic rats showed significant decrease in motor activity as compared to the normal group. Our findings are aligned with the results obtained previously by Kumari *et al.*, which recorded a significant decrease in movement on day 14 in MIA-induced OA [32]. This decrease in spontaneous movement may be due to the progressive loss of bone cartilage [33], significant pain related behaviour [34] and neuropathic pain [35] induced by MIA.

In patients with osteoarthritic cartilage, ROS-induced DNA damage has been elevated in comparison with normal groups. This damage was mediated by inflammatory cytokines which was found also to be elevated [36]. The implication of ROS in the degraded cartilage was confirmed by the presence of lipid peroxidation products in both cartilage and biological fluids in OA animal models [37]. On the other hand, antioxidants as GSH decreased in OA cartilage. These findings confirmed the pivotal role of oxidative and nitrosative stress in OA pathogenesis [1,5]. In accordance with other studies, the current investigation revealed that osteoarthritic group showed significant decline in GSH concomitant with significant increase in the levels of MDA and NO when compared to normal control rats [38,39]. Rats treated with CIII had shown significant elevation in serum GSH level concomitant with prominent decline in the serum levels of MDA and NO as compared to OA rats.

Osteoarthritis as an inflammatory disease displays an initial inflammatory response that is characterized as synovial membrane expansion by protein-rich edema fluid and fibrin with infiltrating neutrophils, macrophages, lymphocytes and plasma cells [40]. The release of cytokines following intra-articular injection of MIA as IL-6, TNF- α and IL-1 β from deteriorated chondrocytes after injection of MIA enhance the development of inflammatory process in OA cartilage. Furthermore, these cytokines contribute to OA pathogenesis due to increasing cartilage degradation [41]. It was also reported that TNF- α activated the sensory neurons, thus initiating a cascade of inflammatory responses by enhancing the production of interleukins *viz.* IL-6 and IL-1 β [42]. Results of the present study also indicate an increase in the inflammatory mediators IL-6, TNF- α and IL-1 β in osteoarthritic rats. On the other hand, administration of CIII (10 mg/kg) has decreased those inflammatory biomarkers as compared to OA rats. This protective effect may refer to suppressing effect of CIII to cartilage degeneration which is confirmed by decreasing MDA, NO, IL-6, TNF- α and IL-1 β and increasing GSH as compared to OA rats. The cartilage regeneration may be attributed to CIII due to its high content of glycine and proline formed from glycine and both are important for the function of joints and tendons [43].

Finally, the degeneration of the knee joint using radiographic analysis had been examined, whereas, the knee joint of OA rats showed bone injury with degeneration of the cartilage of the knee joint, narrow joint space and joint instability. These findings were in accordance with Morais *et al.* (2016) [44]. The effect of MIA was decreased and the X-ray image showed smoother articular surfaces after treatment of OA rats with CIII (10 mg/kg) for 14 days. The x-ray investigation showed a direct regenerative effect of CIII by repairing the wear of the knee joint cartilage due to beneficial effect on the cartilage after absorption from the small intestine.

From all results obtained, it can be declared that CIII may have regenerative, analgesic and anti-inflammatory effects against MIA induced OA in rat. CIII can perform as a collagen grid glue expressed by articular chondrocytes, which is an attempt to restore the current collagen network of the articular cartilage from additional impairment. This response may be triggered by mechanical or molecular signals, due to the joint trauma. The role of CIII in ameliorating OA may be due to its wound-healing capability and its response to damage in tissues as skin and tendon.

5. Conclusion

Type III collagen succeeded to ameliorate the oxidative and nitrosative stress, as well as inflammation, which have been boosted as a consequence of OA. Likewise, the radiographic analysis showed a direct regenerative effect of CIII by treatment of the wear of the knee joint cartilage which is probably due to its accumulation in the cartilage after absorption from small intestine. Furthermore, the histopathological examination confirmed the therapeutic role of CIII in counteracting OA. From all these results, it can be declared that CIII have regenerative, anti-inflammatory and anti-oxidant properties against MIA-induced OA in rats. Thus, CIII supplementation can be proposed to be a promising anti-osteoarthritic agent recommended in elderly patients susceptible to OA.

Declarations

Author contribution statement

G. Asaad, G.A. Abdel Jaleel, D.O. Saleh, S.W. Al-Awdan, A. Hassan: Conceived and designed the experiments; Performed the experiments; Analyzed and interpreted the data; Contributed reagents, materials, analysis tools or data; Wrote the paper.

Funding statement

This research did not receive any specific grant from funding agencies in the public, commercial, or not-for-profit sectors.

Competing interest statement

The authors declare no conflict of interest.

Additional information

No additional information is available for this paper.

References

- [1] P. Lepetsos, A.G. Papavassiliou, ROS/oxidative stress signaling in osteoarthritis, *Biochim. Biophys. Acta (BBA) - Mol. Basis Dis.* 1862 (4) (2016 Apr 1) 576–591.
- [2] J. Martel-Pelletier, J.P. Pelletier, Is osteoarthritis a disease involving only cartilage or other articular tissues, *Eklek Hastalik Cerrahisi* 21 (2010) 2–14.
- [3] A.A. Razek, S.R. El-Basyouni, Ultrasound of knee osteoarthritis: interobserver agreement and correlation with Western Ontario and McMaster Universities Osteoarthritis, *Clin. Rheumatol.* 35 (2016) 997–1001.
- [4] A.A. Razek, N.S. Fouda, N. Elmetwaley, E. Elbogdady, Sonography of the knee joint, *J. Ultrasound* 12 (2009) 53–60.
- [5] N.N. Pathak, V. Balaganur, M.C. Lingaraju, V. Kant, D. Kumar, D. Kumar, A.K. Sharma, S.K. Tandan, Effect of atorvastatin, a HMG-CoA reductase inhibitor in monosodium iodoacetate-induced osteoarthritic pain: implication for osteoarthritis therapy, *Pharmacol. Rep.* 67 (3) (2015 May) 513–519.
- [6] Y.J. Jeong, I. Kim, J.H. Cho, D.W. Park, J.E. Kwon, M.W. Jung, X. Meng, S.M. Jo, H.S. Song, Y.M. Cho, S.M. Song, Anti-osteoarthritic effects of the *Litsea japonica* fruit in a rat model of osteoarthritis induced by monosodium iodoacetate, *PLoS One* 10 (8) (2015).
- [7] V.M. Monnier, W. Sun, X. Gao, D.R. Sell, P.A. Cleary, J.M. Lachin, S. Genuth, DCCT/EDIC Research Group, Skin collagen advanced glycation endproducts (AGEs) and the long-term progression of sub-clinical cardiovascular disease in type 1 diabetes, *Cardiovasc. Diabetol.* 14 (1) (2015 Dec 1) 118.
- [8] Q.A. Dar, E.M. Schott, S.E. Catheline, R.D. Maynard, Z. Liu, F. Kamal, C.W. Farnsworth, J.P. Ketz, R.A. Mooney, M.J. Hilton, J.H. Jonason, Daily oral

- consumption of hydrolyzed type 1 collagen is chondroprotective and anti-inflammatory in murine posttraumatic osteoarthritis, *PLoS One* 12 (4) (2017).
- [9] S. Ricard-Blum, The collagen family, *Cold Spring Harbor Perspect. Biol.* 3 (1) (2011 Jan 1) a004978.
- [10] S.R. Atayde, A.P. Velosa, S. Catanozi, V. Del Bianco, P.C. Andrade, J.E. Rodrigues, A. dos Santos Filho, L. Antonangelo, S.B. de Mello, V.L. Capelozzi, W.R. Teodoro, Collagen V oral administration decreases inflammation and remodeling of synovial membrane in experimental arthritis, *PLoS One* 13 (7) (2018), e0211106.
- [11] S.W. Volk, S.R. Shah, A.J. Cohen, Y. Wang, B.K. Brisson, L.K. Vogel, K.D. Hankenson, S.L. Adams, Type III collagen regulates osteoblastogenesis and the quantity of trabecular bone, *Calcif. Tissue Int.* 94 (6) (2014 Jun 1) 621–631.
- [12] P. Chandran, M. Pai, E.A. Blomme, G.C. Hsieh, M.W. Decker, P. Honore, Pharmacological modulation of movement-evoked pain in a rat model of osteoarthritis, *Eur. J. Pharmacol.* 613 (1–3) (2009 Jun 24) 39–45.
- [13] B. Gui, J. Zhang, S. Wang, G. Rong, Anti-osteoarthritic and anti-inflammatory activities of diazine: in vitro and in vivo studies, *Med. Sci. Mon. Int. Med. J. Exp. Clin. Res.: Int. Med. J. Exp. Clin. Res.* 24 (2018) 76.
- [14] A.F. Domenichiello, B.C. Wilhite, G.S. Keyes, C.E. Ramsden, A dose response study of the effect of prostaglandin E2 on thermal nociceptive sensitivity, *Prostagl. Leukot. Essent. Fat. Acids* 126 (2017 Nov 1) 20–24.
- [15] C.B. Hamilton, M.A. Pest, V. Pitelka, A. Ratneswaran, F. Beier, B.M. Chesworth, Weight-bearing asymmetry and vertical activity differences in a rat model of post-traumatic knee osteoarthritis, *Osteoarthritis Cartilage* 23 (7) (2015 Jul 1) 1178–1185.
- [16] G.L. Ellman, Tissue sulfhydryl groups, *Arch. Biochem. Biophys.* 82 (1959) 70–77.
- [17] L.C. Green, D.A. Wagner, J. Glogowski, P.L. Skipper, J.S. Wishnok, S.R. Tannenbaum, Analysis of nitrate, nitrite, and [15N]nitrate in biological fluids, *Anal. Biochem.* 126 (1) (1982) 131–138.
- [18] C.S. Drapaca, Mathematical modeling of a brain-on-a-chip: a study of the neuronal nitric oxide role in cerebral microaneurysms, *Emerg. Sci. J.* 2 (6) (2018 Dec 13) 366–382.
- [19] M. Uchiyama, M. Mihara, Determination of malonaldehyde precursor in tissues by thiobarbituric acid test, *Anal. Biochem.* 86 (1978) 271–278.
- [20] H.J. Chung, L. Cho, J.S. Shin, J. Lee, I.H. Ha, H.J. Park, Effects of JSOG-6 on protection against bone loss in ovariectomized mice through regulation of osteoblast differentiation and osteoclast formation, *BMC Compl. Alternative Med.* 14 (2014) 184.
- [21] N.D. Hsieh-Bonassera, I. Wu, J.K. Lin, B.L. Schumacher, A.C. Chen, K. Masuda, W.D. Bugbee, R.L. Sah, Expansion and redifferentiation of chondrocytes from osteoarthritic cartilage: cells for human cartilage tissue engineering, *Tissue Eng. Part A* 15 (11) (2009 Nov 1) 3513–3523.
- [22] N. Gerwin, A.M. Bendele, S. Glasson, C.S. Carlson, The OARS histopathology initiative recommendations for histological assessments of osteoarthritis in the rat, *Osteoarthritis Cartilage* 18 (2010) 24–34.
- [23] S. Hosseininia, M.A. Weis, J. Rai, L. Kim, S. Funk, L.E. Dahlberg, D.R. Eyre, Evidence for enhanced collagen type III deposition focally in the territorial matrix of osteoarthritic hip articular cartilage, *Osteoarthritis Cartilage* 24 (6) (2016 Jun 1) 1029–1035.
- [24] I.H. Joo, G.Y. Min, H.J. Choi, B.Y. Sim, H.Y. Kim, J. Kim, J.G. Ji, J.H. Kim, D.H. Kim, Effects of chondroitin sulfate on modulation of MMPs and TIMP-1 in a monosodium iodoacetate-induced osteoarthritis model, *Int. J. Clin. Exp. Med.* 11 (10) (2018 Jan 1) 10749–10757.
- [25] T. Pitcher, J. Sousa-Valente, M. Malcangio, The monosodium iodoacetate model of osteoarthritis pain in the mouse, *JoVE-J. Visual. Exp.* (111) (2016 May 16), e53746.
- [26] K.K. Young, H.K. Eun, S.L. Kyu, L. Koeun, H.P. Sung, H.N. Sook, K. Cheolwoong, K. Junesun, W.Y. Young, The effects of intra-articular resiniferatoxin on monosodium iodoacetate-induced osteoarthritic pain in rats, *KOREAN J. PHYSIOL. PHARMACOL.* 20 (1) (2016) 129–136.
- [27] Y. Kim, E.H. Kim, K.S. Lee, K. Lee, S.H. Park, S.H. Na, C. Ko, J. Kim, Y.W. Yoon, The effects of intra-articular resiniferatoxin on monosodium iodoacetate-induced osteoarthritic pain in rats, *KOREAN J. PHYSIOL. PHARMACOL.* 20 (2016) 129–136.
- [28] L.N. Nwosu, P.I. Mapp, V. Chapman, D.A. Walsh, Relationship between structural pathology and pain behaviour in a model of osteoarthritis (OA), *Osteoarthritis Cartilage* 24 (11) (2016) 1910–1917.
- [29] T. Woo, L. Lau, N. Cheung, P. Chan, K. Tan, A. Gardner, Efficacy of oral collagen in joint pain—osteoarthritis and rheumatoid arthritis, *J. Arthritis* 6 (233) (2017) 2.
- [30] Abramson DI, Miller DS. Circulation to joints and associated structures. In *Vascular Problems in Musculoskeletal Disorders of the Limbs 1981* (pp. 41–47). Springer, New York, NY.
- [31] A. Rangaraj, K. Harding, D. Leaper, Role of collagen in wound management, *Wounds U. K.* 7 (2011) 54–63.
- [32] R.R. Kumari, A.S. More, G. Gupta, M.C. Lingaraju, V. Balaganur, P. Kumar, D. Kumar, A.K. Sharma, S.K. Mishra, S.K. Tandan, Effect of alcoholic extract of *Entada pursaetha* DC on monosodium iodoacetate-induced osteoarthritis pain in rats, *Indian J. Med. Res.* 141 (2015) 454.
- [33] J.J. Burston, P.I. Mapp, S. Sarmad, D.A. Barrett, M.J. Niphakis, B.F. Cravatt, D.A. Walsh, V. Chapman, Robust anti-nociceptive effects of monoacylglycerol lipase inhibition in a model of osteoarthritis pain, *Br. J. Pharmacol.* 173 (21) (2016 Nov) 3134–3144.
- [34] S. Orita, T. Ishikawa, M. Miyagi, N. Ochiai, G. Inoue, Y. Eguchi, H. Kamoda, G. Arai, T. Toyone, Y. Aoki, T. Kubo, Pain-related sensory innervation in monosodium iodoacetate-induced osteoarthritis in rat knees that gradually develops neuronal injury in addition to inflammatory pain, *BMC Musculoskel. Disord.* 12 (2011) 134.
- [35] J. Lu, T. Zhang, H. Sun, S. Wang, M. Liu, Protective effects of dioscin against cartilage destruction in a monosodium iodoacetate (MIA)-induced osteoarthritis rat model, *Biomed. Pharmacother.* 108 (2018 Dec 1) 1029–1038.
- [36] S. Jimbo, Y. Terashima, A. Teramoto, T. Takebayashi, I. Ogon, K. Watanabe, T. Sato, N. Ichise, N. Tohse, T. Yamashita, Antinociceptive effects of hyaluronic acid on monosodium iodoacetate-induced ankle osteoarthritis in rats, *J. Pain Res.* 12 (2019) 191.
- [37] C. Rathakrishnan, K. Tikku, A. Raghavan, M.L. Tikku, Release of oxygen radicals by articular chondrocytes: a study of luminol-dependent chemiluminescence and hydrogen peroxide secretion, *J. Bone Miner. Res.* 7 (2009) 1139–1148.
- [38] J.H. Jeong, S.J. Moon, J.Y. Jhun, E.J. Yang, M.L. Cho, J.K. Min, Eupatilin exerts antinociceptive and chondroprotective properties in a rat model of osteoarthritis by downregulating oxidative damage and catabolic activity in chondrocytes, *PLoS One* 10 (6) (2015).
- [39] Z.M. Wang, Y.C. Chen, D.P. Wang, Resveratrol, a natural antioxidant, protects monosodium iodoacetate-induced osteoarthritic pain in rats, *Biomed. Pharmacother.* 83 (2016 Oct 1) 763–770.
- [40] Q. Xu, Z.F. Zhang, W.X. Sun, Effect of naringin on monosodium iodoacetate-induced osteoarthritis pain in rats, *Med. Sci. Mon. Int. Med. J. Exp. Clin. Res.: Int. Med. J. Exp. Clin. Res.* 23 (2017) 3746.
- [41] K.M. Lee, S.M. Jeon, H.J. Cho, Tumor necrosis factor receptor 1 induces interleukin-6 upregulation through NF-kappaB in a rat neuropathic pain model, *Eur. J. Pain* 13 (2009) 794–806.
- [42] A. Finn, K. Ångeby Möller, C. Gustafsson, S. Abdelmoaty, G. Nordahl, M. Ferm, C. Svensson, Influence of model and matrix on cytokine profile in rat and human, *Rheumatology* 53 (12) (2014 Dec 1) 2297–2305.
- [43] O. Korotkyi, A. Vovk, O. Blokhina, K. Dvorshchenko, T. Falalyeyeva, L. Abenavoli, L. Ostapchenko, Effect of chondroitin sulfate on blood serum cytokine profile during carrageenan-induced edema and monosodium iodoacetate-induced osteoarthritis in rats, *Rev. Recent Clin. Trials* 14 (1) (2019) 50–55.
- [44] S.V.D. Moraes, N.G. Czeckzo, O. Malafaia, J.M. Ribas-Filho, J.B.S. Garcia, M.T. Miguel, C. Zini, A.G. Massignan, Osteoarthritis model induced by intra-articular monosodium iodoacetate in rats knee, *Acta Cir. Bras.* 31 (2016) 765–773.