


## ORIGINAL ARTICLE

# Successful treatment of seminal vesicle calculi and prostatic utricle calculi by transurethral seminal vesiculoscopy

Liming Song | Hu Han  | Hongen Lei | Yun Cui | Sujuan Feng | Xiaodong Zhang | Long Tian

Department of Urology, Institute of Urology, Beijing Chao-Yang Hospital, Capital Medical University, Beijing, China

**Correspondence**

Hu Han, Department of Urology, Beijing Chao-Yang Hospital, Capital Medical University, Gong Ti Nan Lu 8, Chaoyang District, Beijing 100020, China.  
Email: lyghanhu@sina.com

**Abstract**

To investigate the outcomes of transurethral seminal vesiculoscopy (TSV) for the treatment of seminal vesicle calculi (SVC), prostatic utricle calculi (PUC) and combination of them, a retrospective review on 27 patients with SVC and/or PUC who complained of intractable haematospermia was conducted. Patient demographics, disease duration, operation time, stone location and complications were recorded. The calculi in the seminal vesicle and/or prostatic utricle were removed by holmium laser lithotripsy and/or basket extraction. The stone composition was determined in 19 of 27 patients using Infrared spectroscopy. The average age and disease duration of patients were 39.4 years and 23.1 months respectively. The mean operative time was 78.5 min. We detected SVC, SVC and PUC, and PUC in 59.3% (16/27), 33.3% (9/27) and 7.4% (2/27) patients respectively. The stones were mainly composed of calcium oxalate dehydrate (COD), carbonate apatite (CA), COD and calcium oxalate monohydrate (COM), CA and magnesium ammonium phosphate, CA and COM, and COD and uric acid in 42.1% (8/19), 21.1% (4/19), 15.8% (3/19), 15.8% (3/19), 5.3% (1/19) and 5.3% (1/19) cases respectively. No intraoperative and post-operative complications were noted. These results suggested that SVC and PUC can be diagnosed and treated using TSVs.

**KEYWORDS**

haematospermia, prostatic utricle calculi, seminal vesicle calculi, stone composition, transurethral seminal vesiculoscopy

## 1 | INTRODUCTION

Seminal vesicle calculi (SVC) are rare; hence, they are commonly misdiagnosed in clinical practice (Zaidi et al., 2019). The aetiology of SVC is unclear, with limited literature, mostly in the form of case reports (Miao et al., 2020; Zaidi et al., 2019). With the development of imaging technologies and the introduction of

transurethral seminal vesiculoscopy (TSV), an increasing number of patients with SVC are being diagnosed and treated successfully by clinicians (Yang, Rha, Byon, & Kim, 2002; Tian, Han, Lei, & Zhang, 2018).

The clinical manifestations of SVC and prostatic utricle calculi (PUC) are intractable or persistent haematospermia. However, the aetiology of SVC and PUC and their best treatment methods remain

This is an open access article under the terms of the Creative Commons Attribution-NonCommercial-NoDerivs License, which permits use and distribution in any medium, provided the original work is properly cited, the use is non-commercial and no modifications or adaptations are made.

© 2020 The Authors. *Andrologia* published by Wiley-VCH GmbH

largely unknown. Therefore, we present a large case series of SVC and PUC managed by TSV.

## 2 | MATERIALS AND METHODS

### 2.1 | Patients

In this retrospective study, we included a total of 27 patients with SVC and/or PUC who were admitted to our centre for intractable haemospermia between June 2014 and January 2020. Patient demographics, symptomatology, disease duration, operation time, hospitalisation days, stone location and complications were recorded. A detailed medical history including main symptoms, concomitant symptoms, semen colour, effect of antibiotic treatment, urine analysis, imaging results, long-term post-operative efficacy and post-operative complications was collected. The study was performed in accordance with the principles of the Declaration of Helsinki, and all participants signed informed consent forms.

First, to assess the degree of haemospermia, patients were asked if they experienced any ejaculatory pain, were using anti-coagulants and had any history of haemophilia, prostate biopsy and/or vasectomy. Second, all patients underwent a detailed physical examination to check for external genital malformations and haemangiomas at the urethral orifice. Third, and most importantly, transrectal ultrasound (TRUS) and/or seminal vesicle magnetic resonance imaging (MRI) were performed pre-operatively to explore the cause of intractable haemospermia. Additionally, patients over 40 years of age underwent prostate-specific antigen tests and digital rectal examination.

### 2.2 | Methods

The indications for TSV included intractable haemospermia unresponsive to conservative treatment. Pre-operatively, TRUS was used to screen for abnormal signal intensity in the seminal vesicle or MRI of the seminal vesicle was performed to detect haematocoles. The operations were performed using a 4.5/6.5 F ureteroscope.

Currently, the following three surgical approaches are used for TSV in clinical practice: the natural approach (entry through the ejaculatory duct orifices), the pathological opening or fenestration of the posterolateral wall of the prostatic utricle, and transurethral resection of the ejaculatory ducts.

The calculi in the seminal vesicle and/or prostatic utricle were removed by holmium laser lithotripsy and/or basket extraction. To determine the composition of stones, an automatic analysis of the calculi was performed using infrared spectroscopy (Lambda Scientific).

Patients were followed up at 2 weeks, 1, 3 and 6 months post-operatively at outpatient clinics and over telephone to enquire about the change in semen colour, time course of symptom disappearance, and the presence or absence of dysuria and testicular swelling. Every

**TABLE 1** Clinical characteristics of seminal vesicular calculi (SVC) and prostatic utricle calculi (PUC)

Variable	n = 27
Age (years), mean $\pm$ SD	39.4 $\pm$ 14.3
Disease duration (months), mean $\pm$ SD	23.1 $\pm$ 22.4
Hospitalisation day (days), mean $\pm$ SD	6.1 $\pm$ 1.5
operative time (min), mean $\pm$ SD	78.5 $\pm$ 27.3
Location of stone, % (n)	
Seminal vesicle	59.3 (16/27)
Prostatic utricle	7.4 (2/27)
Seminal vesicle and prostatic utricle	33.3 (9/27)
Seminal vesicle calculi, % (n)	
Left	32 (8/25)
Right	64 (16/25)
Bilateral	4 (1/25)
Stone composition analysis, % (n)	
Completed	70.4 (19/27)
Incomplete	29.6 (8/27)

patient with SVC and/or PUC received post-treatment follow-up for an average of 15.1 months (range, 1–37 months).

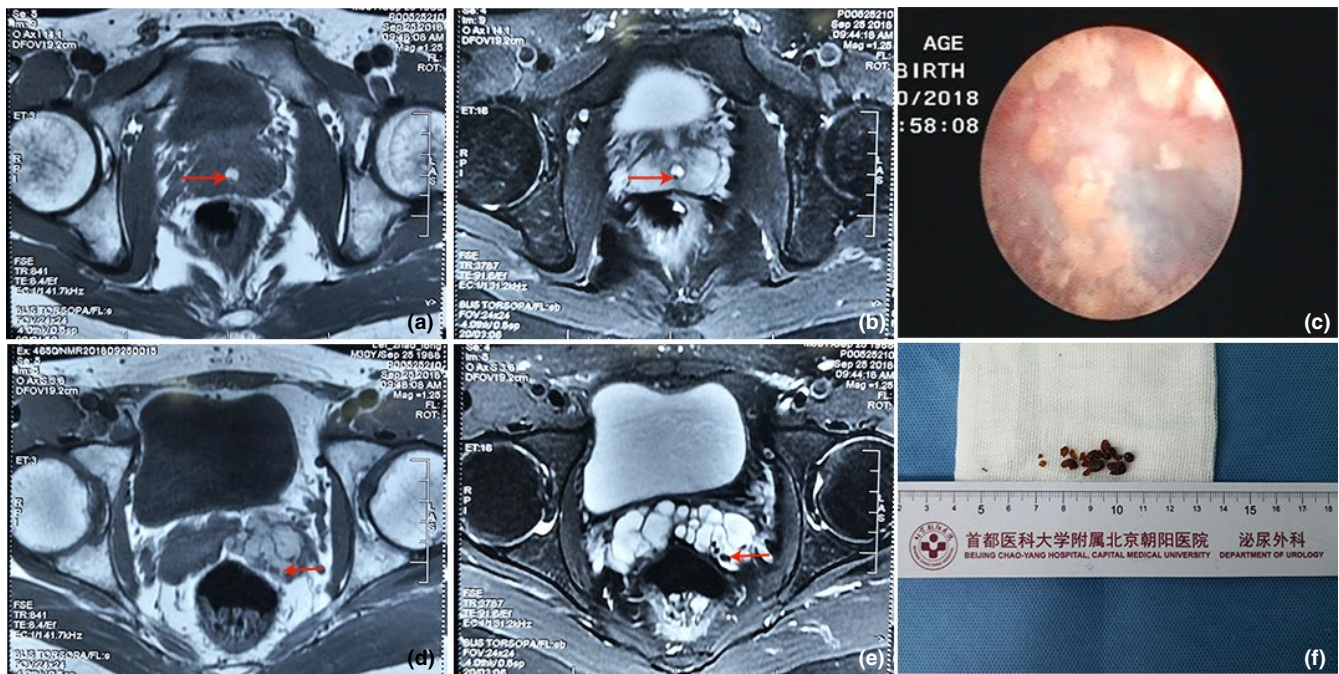
## 3 | RESULTS

All patients successfully underwent TSV, under either general anaesthesia or combined spinal-epidural anaesthesia. The average age of patients involved in this study was 39.4 years (range, 16–69 years). The mean disease duration of intractable haemospermia, operative time and hospitalisation time was 23.1 months (range, 2–72 months), 78.5 min and 6.1 days respectively. The average follow-up time was 15.1  $\pm$  9.8 months (range, 1–37 months). Table 1 summarises clinical characteristics of patients. Figure 1 presents MRI of SVC and PUC.

Patients with SVC and/or PUC mainly complained of intractable haemospermia and presented with a dark red blood-semen mixture with ejaculation pain/discomfort, but no blood clots. The results of urinalysis were normal. However, haemospermia recurred even after initial improvements due to antibiotic treatment.

Of 27 patients, 2 underwent TSV via the ejaculatory duct orifices and 25 underwent TSV via the posterolateral wall of the prostatic utricle. The haematocoles were flushed out with saline; holmium laser lithotripsy and/or basket extraction were used for the stone removal during TSV. A combination of holmium laser lithotripsy and basket extraction was used in four cases with larger stones, whereas direct stone extraction with a basket was performed in the remaining cases.

Stones in the seminal vesicle, seminal vesicle and prostatic utricle, and prostatic utricle were detected in 59.3% (16/27), 33.3% (9/27) and 7.4% (2/27) cases respectively. Stone composition analysis was performed in 19 of 27 patients because some patients provided fewer samples. In these 19 patients, the stones were mainly



**FIGURE 1** Magnetic resonance imaging findings and the appearance of stone during and after the operation in a 30-year-old man presented with intractable haematospermia that lasted for 6 months. High signal intensity and low signal intensity at the punctate area (red arrow) in the prostatic utricle cyst on both (a) T1WI and (b) T2WI. (c) Image showing a yellow stone after flushing out a haematocoele in the prostatic utricle cyst during transurethral seminal vesiculoscopy. High signal intensity and low signal intensity at the punctate area (red arrow) in the left seminal vesicular on both (d) T1WI and (e) T2WI. (f) Image showing dark brown stone fragment after the operation. T1WI, T1-weighted image; T2WI, T2-weighted image

composed of calcium oxalate dehydrate (COD), carbonate apatite (CA), COD and calcium oxalate monohydrate (COM), CA and magnesium ammonium phosphate (MAP), CA and COM, and COD and uric acid in 42.1% (8/19), 21.1% (4/19), 15.8% (3/19), 15.8% (3/19), 5.3% (1/19) and 5.3% (1/19) patients respectively. Among 27 patients with SVC and/or PUC, three had ejaculatory duct cysts and four had PUCs, which could be diagnosed by MRI pre-operatively.

All patients completed their follow-up examinations. Patients were suggested to discharge semen regularly (2–3 times a week). Post-operatively, there were two cases of recurrent haematospermia; however, the symptoms disappeared after conservative anti-inflammatory treatment. Haematospermia in the remaining patients disappeared approximately 4–6 weeks after their respective operations. No bleeding or rectal injury occurred during the operations. Clinical symptoms gradually disappeared during the follow-up, with no reported complications of urinary incontinence, urethral bleeding, urethral stricture, urination pain, ejaculation pain, orchitis or epididymitis.

## 4 | DISCUSSION

All patients successfully underwent TSV. During the operation, SVC, PUC, and a combination of SVC and PUC were confirmed in 16, two and nine cases respectively. There were no intraoperative or post-operative complications. The stones were mainly composed of COD and CA. The literature on SVC is relatively limited; we have reported

the largest number of SVC and/or PUC cases (Miao et al., 2020; Zaidi et al., 2019).

The clinical manifestations of SVC and PUC are intractable or persistent haematospermia, which are not relieved with active anti-inflammatory treatment. Patients can have multiple recurrences of SVC and PUC, and the majority of patients present with painful ejaculation (Liao et al., 2019; Tian et al., 2018; Zaidi et al., 2019). Patients with SVC also complained of lower abdominal pain, perineal discomfort or pain, and/or infertility (Miao et al., 2020; Li, 1991). Some patients with large SVC presented with a history of passing increasingly painful 'grit' in their ejaculate, and others complained of recurrent lower urinary tract infections (Williams, Christodoulidou, & Nigam, 2017; Hadidi, Hadidy, Alrabadi, Ahdul-Wahab, & Murshidi, 2011). Differential diagnoses included posterior urethral haemangioma (Han, Zhou, Fan, Tian, & Zhang 2015; Tian et al., 2018). All of our patients were admitted with a complaint of intractable haematospermia, and a few of them had accompanying ejaculation pain or discomfort. Due to similar clinical manifestations, SVC and PUC cannot be differentiated pre-operatively; they are diagnosed during the TSV itself.

Since SVC are usually small with a low level of hardness, computed tomography is not suitable for detecting intractable haematospermia caused by the stone itself, except for large stones. MRI not only determines the location of blood accumulation in the seminal vesicle, but also clearly shows if there is a low signal shadow in the seminal vesicle requiring further evaluation (Figure 1d,e). It seems to play an increasingly important role,

especially when surgery or TRUS is inconclusive or negative (Cho et al., 1997; Christodoulidou, Parnham, & Raj, 2017; Expert Panel on Urologic Imaging et al., 2017). MRI with an endorectal surface coil is a powerful modality for evaluating the seminal tracts of patients with haemospermia and can be performed clinically when TRUS results are not satisfactory (Prando, 2008; Cho et al., 1997). Pre-operative MRI results with low signal intensity on both T1- and T2-weighted images generally indicate that the stones in the seminal vesicle are of different sizes. Hence, holmium laser fibre, holmium laser and stone basket should be prepared in advance for the operation. If the pre-operative MRI indicates that only one side of the seminal vesicle has a haematocele, that side should be preferentially approached during the operation to avoid the failure of inserting the vesiculoscope into the pathological seminal vesicle due to haemorrhage. Xing et al. (2012) found that TSV was significantly superior to TRUS in detecting calculi and obstruction/stricture. Therefore, MRI and TSV are preferred for the diagnosis of SVC, whereas TRUS is not the most reliable choice for this purpose.

Transurethral seminal vesiculoscopy is a safe, minimally invasive and effective treatment for SVC (Miao et al., 2020; Christodoulidou et al., 2017; Liao et al., 2019; Zaidi et al., 2019). No recurrence of haemospermia was reported during the follow-up of our patients. Patients with small stones in the seminal vesicle who underwent TSV should not receive conservative treatment or undergo laparoscopic or open seminal vesicle resection. Open surgery or laparoscopic surgery could be an alternative for large stones in the seminal vesicle (Hadidi et al., 2011; Han, Yang, Zhang, & Wei, 2008). In our study, some patients were diagnosed with SVC pre-operatively by MRI, and some of them had small SVC that were confirmed by TSV after washing the blood off the seminal vesicles. Generally, the seminal vesicle has small stones, which can be easily removed with a stone basket. If the stone is large, a holmium laser is needed. In this study, four patients had large stones, which could not be directly removed using a stone basket. After breaking the stones with a holmium laser, the stone fragments were removed using a stone basket. In such cases, the fragments should be removed as thoroughly as possible because the opening of the ejaculatory duct is very small, and it is difficult to discharge the small fragments via that opening later on. In our study, the intraoperative holmium laser energy did not exceed 10 W, which is consistent with a previous report (Zhang et al., 2017). Because of the damage caused by high-power laser to the seminal vesicle mucosa, the ejaculatory duct may become narrow and the semen quantity may reduce post-operatively. During the follow-up of our study, no significant reduction in semen quantity was found. In order to prevent post-operative epididymitis caused by retrograde infection, low-pressure saline flushing should be used to remove the haematocele from the seminal vesicle. During the operation, the haematocele in the seminal vesicle should be rinsed repeatedly with saline under the vesiculoscope until the rinsed liquid is clear, so that the symptoms of haemospermia resolve quickly after the operation. Özgök et al. (2005) were the first to report the

endoscopic transurethral removal of SVC. Wang et al. (2012) reported five cases of seminal vesicle stones that were successfully managed with laser lithotripsy and basketing. Miao et al. (2020) confirmed that TSV is a simple and minimally invasive technique that can be used for the diagnosis and treatment of seminal vesiculitis with SVC.

Liu et al. (2018) reported the presence of struvite (MAP hexahydrate) in five SVC cases using an infrared calculus composition analyser and a mixture of COD, COM and CA in the other SVC cases. SVCs are most commonly composed of struvite, and an infection is the main aetiological factor in calculus-associated seminal vesiculitis. However, some studies cultured the collected seminal vesicle fluid to detect infections caused by *Ureaplasma urealyticum*, *Chlamydia trachomatis* and *Mycoplasma hominis*. Wang et al. (2016) revealed that one out of 63 seminal vesiculitis cases with haemospermia was positive for *Acinetobacter*, and the remaining cases were negative for *U. urealyticum*, *C. trachomatis* and *M. hominis*. Miao et al. (2020) found that SVC were mostly composed of hydroxyapatite and protein suggesting the presence of infections. We found that SVC were composed of COD and CA. In our study, the stones contained COD in 12 cases and CA in seven cases; in contrast to COD, CA could be related to infection. We speculated that if the stones are formed after the blood accumulation in the seminal vesicle, the secondary stones are caused by chronic inflammatory stimulation and their main component is CA. If the stones are formed first followed by blood accumulation in the seminal vesicle under the stimulation of stones, the primary stones are mainly composed of COD. Christodoulidou et al. (2017) found that the most likely aetiology of SVC was stasis of ejaculate secondary to impaired drainage of secretions from the seminal vesicles. Hadidi et al. (2011) also observed that the large stones in the bilateral seminal vesicles were composed of COM, which could be related to urine reflux. Using X-ray diffraction analysis of stone composition, Han et al. (2008) reported that SVC were composed of calcium fluorophosphates. These findings suggest that the composition of stones in the seminal vesicle varies greatly; hence, the aetiology of stone formation needs to be further explored.

Our study had certain limitations. First, this was a retrospective study; because the incidence rate of SVC and/or PUC is low, it was difficult to perform a prospective controlled study in the clinic. Second, we used only infrared spectroscopy-based methods for stone analysis. We expect that more methods of stone analysis will be introduced in the future. Third, we collected seminal vesicle washing fluid for microbiological analysis to understand the mechanism of stone formation; however, further research focusing on this aspect is required.

In conclusion, SVC and PUC can be diagnosed and treated using TSV. Moreover, the stones are mainly composed of COD or CA. The aetiology of SVC and PUC, which needs to be further explored, may be related to infection, stasis of the ejaculate and urine reflux.

#### ORCID

Hu Han  <https://orcid.org/0000-0002-3326-8615>

## REFERENCES

- Cho, I. R., Lee, M. S., Rha, K. H., Hong, S. J., Park, S. S., & Kim, M. J. (1997). Magnetic resonance imaging in hemospermia. *Journal of Urology*, *157*, 258–262. [https://doi.org/10.1016/s0022-5347\(01\)65340-0](https://doi.org/10.1016/s0022-5347(01)65340-0)
- Christodoulidou, M., Parnham, A., & Raj, N. (2017). Diagnosis and management of symptomatic seminal vesicle calculi. *Scandinavian Journal of Urology*, *51*, 237–244. <https://doi.org/10.1080/21681805.2017.1295398>
- Expert Panel on Urologic Imaging, Hosseinzadeh, K., Oto, A., Allen, B. C., Coakley, F. V., Friedman, B., ... Eberhardt, S. C. (2017). ACR appropriateness criteria hematospermia. *Journal of the American College of Radiology*, *14*, S154–S159. <https://doi.org/10.1016/j.jacr.2017.02.023>
- Hadidi, M., Hadidy, A., Alrabadi, A. F., Ahdul-Wahab, A. D., & Murshidi, M. M. (2011). Bilateral very large calcium oxalate stones in the seminal vesicles: Case report and literature review. *Urological Research*, *39*, 509–513. <https://doi.org/10.1007/s00240-011-0371-0>
- Han, H., Zhou, X. G., Fan, D. D., Tian, L., & Zhang, X. D. (2015). An unusual etiology for hematospermia and treatments that were successful. *Urology*, *86*(4), 740–743. <https://doi.org/10.1016/j.urology.2015.06.031>
- Han, P., Yang, Y.-R., Zhang, X.-Y., & Wei, Q. (2008). Laparoscopic treatment of a calcium fluorophosphate stone within a seminal vesicle cyst. *Asian Journal of Andrology*, *10*, 337–340. <https://doi.org/10.1111/j.1745-7262.2008.00341.x>
- Li, Y. K. (1991). Diagnosis and management of large seminal vesicle stones. *British Journal of Urology*, *68*, 322–323. <https://doi.org/10.1111/j.1464-410x.1991.tb15335.x>
- Liao, L.-G., Li, Y.-F., Zhang, Y., Li, K., Zhu, T., Li, B.-J., ... Jiang, J. (2019). Etiology of 305 cases of refractory hematospermia and therapeutic options by emerging endoscopic technology. *Scientific Reports*, *9*, 5018. <https://doi.org/10.1038/s41598-019-41123-2>
- Liu, G. L., Wang, G. Y., Wu, K. R., Yin, W. Q., & Wu, W. J. (2018). Etiological factors for calculus-associated seminal vesiculitis: Analysis of calculus composition in 6 cases. *Zhong Hua Nan Ke Xue = National Journal of Andrology*, *24*, 128–132.
- Miao, C., Liang, C., Wang, Y., Song, Z., Xu, A., Liu, B., ... Wang, Z. (2020). The management and composition of symptomatic seminal vesicle calculi: Aetiological analysis and current research. *BJU International*, *125*(2), 314–321. <https://doi.org/10.1111/bju.14758>
- Özgök, Y., Kilciler, M., Aydur, E., Sağlam, M., Cem Irkılata, H., & Erduran, D. (2005). Endoscopic seminal vesicle stone removal. *Urology*, *65*, 591. <https://doi.org/10.1016/j.urology.2004.09.015>
- Prando, A. (2008). Endorectal magnetic resonance imaging in persistent hematospermia. *International Brazilian Journal of Urology*, *34*(2), 171; discussion 177–179. <https://doi.org/10.1590/s1677-55382008000200007>
- Tian, L., Han, H., Lei, H.-E., & Zhang, X.-D. (2018). Clinical features of haematospermia associated with seminal vesicle calculi versus posterior urethral haemangioma. *Andrologia*, *50*, e13072. <https://doi.org/10.1111/and.13072>
- Wang, R., Zhang, W. X., Zhang, T. B., Li, R., Wang, C. L., Song, X. H., ... Li, X. Y. (2016). Transurethral seminal vesiculoscopy for the treatment of vesiculitis with hemospermia: A report of 64 cases. *Zhong Hua Nan Ke Xue = National Journal of Andrology*, *22*, 335–338.
- Wang, H., Ye, H., Xu, C., Liu, Z., Gao, X., Hou, J., ... Sun, Y. (2012). Transurethral seminal vesiculoscopy using a 6F vesiculoscope for ejaculatory duct obstruction: Initial experience. *Journal of Andrology*, *33*, 637–643. <https://doi.org/10.2164/jandrol.111.013912>
- Williams, S. A., Christodoulidou, M., & Nigam, R. (2017). Large bilateral seminal vesicle calculi presenting with spermolithiasis. *BMJ Case Reports*, 2017. <https://doi.org/10.1136/bcr-2017-219630>
- Xing, C., Zhou, X., Xin, L., Hu, H., Li, L., Fang, J., & Liu, Z. (2012). Prospective trial comparing transrectal ultrasonography and transurethral seminal vesiculoscopy for persistent hematospermia. *International Journal of Urology*, *19*(5), 437–442. <https://doi.org/10.1111/j.1442-2042.2011.02952.x>
- Yang, S. C., Rha, K. H., Byon, S. K., & Kim, J. H. (2002). Transutricular seminal vesiculoscopy. *Journal of Endourology*, *16*(6), 343–345. <https://doi.org/10.1089/089277902760261347>
- Zaidi, S., Gandhi, J., Seyam, O., Joshi, G., Waltzer, W. C., Smith, N. L., & Khan, S. A. (2019). Etiology, diagnosis, and management of seminal vesicle stones. *Current Urology*, *12*, 113–120. <https://doi.org/10.1159/000489429>
- Zhang, W., Xiao, G., Qin, S., Reed-Maldonado, A. B., Xu, J., Chen, G., ... Zhou, T. (2017). An innovative technique of transurethral seminal vesiculoscopy with ultrasonic lithotripter for severe, persistent hematospermia. *Journal of Endourology*, *31*, 1277–1282. <https://doi.org/10.1089/end.2017.0390>

**How to cite this article:** Song L, Han H, Lei H, et al. Successful treatment of seminal vesicle calculi and prostatic utricle calculi by transurethral seminal vesiculoscopy. *Andrologia*. 2020;52:e13804. <https://doi.org/10.1111/and.13804>