

Role of ultrasound-guided technique in the treatment of gynecologic diseases

A systematic review and meta-analysis

Min Xuan, MD, PhD^a, Chunyan Wu, BD^a, Jing Zhang, BD^a, Fengsheng Zhou, BD^{a,*}

Abstract

Background: The efficacy and safety of ultrasound-guided interventional procedures for gynecologic diseases have not been evaluated comprehensively. Therefore, we aimed to provide an evidence-based medical reference for clinical treatment in this meta-analysis.

Methods: The literature searches were conducted in databases of PubMed, Embase, and Web of Science for eligible studies published from 2002 to May 2022. All literature was searched, screened, and reviewed by 2 researchers separately. RevMan 5.3.0 was used to analyze the relevant data.

Results: A total of 12 articles consisting of 2854 patients were included. Compared with the control group, meta-analysis showed that ultrasound-guided technique in the experimental group was associated with a higher effective rate [risk ratio = 0.84, 95% confidence interval (CI) (0.84, 0.84)], a lower probability of recurrence [odds ratio = 0.13, 95% CI (0.13, 0.13), $P < .00001$], and a greater effective reintervention rate [odds ratio = 3.39, 95% CI (1.29, 8.86), $P = .01$]. However, it was not significantly associated with fewer adverse reactions.

Conclusions: Ultrasound-guided technique in treating gynecologic diseases exerted a positive effect and had fewer adverse reactions, which could be popularized and applied in clinical practice.

Abbreviations: CI = confidence interval, USGT = ultrasound-guided technique.

Keywords: gynecologic diseases, meta-analysis, ultrasound-guided technique

1. Introduction

As a disease treatment method, ultrasound-guided technique (USGT) has emerged with the development of medical technology. This technique is developed based on ultrasound imaging to further meet the needs of clinical diagnosis and treatment.^[1] Various needle biopsies, aspiration, intubation, and drug injection can be supervised or guided by ultrasound. The technique can avoid some surgical procedures and achieve the same effect as that of surgery.^[2] The principle of this technique is that ultrasound-guided fine-needle aspiration can directly reach the lesion area. Cyst fluid is then aspirated, or a drug is injected, causing the cyst to shrink and disappear. Subsequently, adenomyoma and fibroids immediately degenerate, shrink, and die. Therefore, clinical symptoms are relieved. The advantages of USGT are as follows: USGT requires no surgery and generally only requires local anesthesia, reducing the risk of general anesthesia^[3]; USGT induces slight damage, provides quick recovery, and exerts desirable effects, and it involves slight interference to the human body

but protects normal organs the most; and USGT in the treatment can reduce the influence of drugs on lesions and minimize side effects on the body and other organs. The technique has become one of the most important treatment methods for gynecologic diseases (such as adenomyosis/tumor, uterine fibroids, chocolate cysts, ovarian cysts, polycystic kidneys, and aneurysms). Besides, it has gradually replaced or eliminated surgery as the original method.^[4]

An ovarian cyst is a gynecologic disease that more commonly occurs in women of reproductive age. Laparoscopic surgery is the recommended approach for ovarian cyst removal. However, complications, such as pelvic adhesions, also occur after laparoscopic surgery, affecting sterile women. USGT is particularly advantageous in the puncture and sclerotherapy of ovarian cysts. The method extracts cyst fluid via a puncture and then injects sclerosing agents, such as absolute ethanol and 50% high-sugar solution, to destroy the cyst intima and render it sterile. Inflammation can be cured by closing the cyst cavity. This technique has several advantages, such as the simplicity of operation, repeatability,

The authors have no conflicts of interest to disclose.

All data generated or analyzed during this study are included in this published article [and its supplementary information files]. The data generated in the present study may be requested from the corresponding author.

^a Department of Ultrasound, Wuxi People's Hospital of Nanjing Medical University, Wuxi, Jiangsu Province, People Republic of China.

*Correspondence: Fengsheng Zhou, Department of Ultrasound, Wuxi People's Hospital of Nanjing Medical University, 299 Qingyang Road, Wuxi City 214023, Jiangsu Province, People Republic of China (e-mail: zhoulengsheng78@163.com).

Copyright © 2022 the Author(s). Published by Wolters Kluwer Health, Inc.

This is an open-access article distributed under the terms of the Creative Commons Attribution-Non Commercial License 4.0 (CCBY-NC), where it is permissible to download, share, remix, transform, and buildup the work provided it is properly cited. The work cannot be used commercially without permission from the journal.

How to cite this article: Xuan M, Wu C, Zhang J, Zhou F. Role of ultrasound-guided technique in the treatment of gynecologic diseases: A systematic review and meta-analysis. *Medicine* 2022;101:43(e31329).

Received: 13 August 2022 / Received in final form: 21 September 2022 / Accepted: 22 September 2022

<http://dx.doi.org/10.1097/MD.00000000000031329>

reduced trauma, economic benefits, absence of severe complications, definite curative effect, and a mild impact on ovarian function.

A tubo-ovarian abscess is a severe gynecologic condition. Ultrasonography shows that the cyst wall is thick, the internal sound transmission is poor, and specificity is often accompanied by separation. Failure to promptly provide effective treatment can lead to chronic pelvic inflammation and atresia of the fimbria or lumen of the fallopian tube, increasing the risk of ectopic pregnancy or infertility. Surgical treatment is often used in clinical practice, including excision of abscesses or incision and drainage. However, insufficient preoperative preparation, unclear diagnosis, or unclear anatomy of surrounding organs and abscesses during surgery leads to side injuries and severe complications after surgery. Studies have found that ultrasound-guided puncture and drainage, as well as the application of antibiotics in the abscess cavity, can achieve the same level of efficacy as those of incision and drainage.^[5]

Chocolate cysts, also known as endometriosis, have considerably high clinical incidence and are challenging to treat. Although similar to malignant tumors, such as plant growth and tissue invasion, ovarian chocolate cysts are benign lesions. Infertility and dysmenorrhea are the most common clinical symptoms of patients with ovarian chocolate cysts. The condition seriously affects the quality of life and reproductive function of the patient. Therefore, effective treatment of ovarian cysts bears excellent significance. Laparotomy and laparoscopic surgery yield satisfactory results and can effectively remove ovarian chocolate cysts. However, surgery has postoperative complications, such as pelvic inflammatory disease and intestinal adhesions. These complications can delay postoperative recovery, seriously damage the reproductive function, and reduce ovarian reserve, leading to severe consequences. As a new minimally invasive technique, interventional ultrasound can be easily performed on patients with ovarian chocolate cysts, provide benefits, and exhibit safety. In addition, the incidence of postoperative bleeding and infection is relatively low.^[6,7]

Uterine fibroids are the most common benign tumors in the female reproductive system. Surgical treatment has been frequently used in the past. However, with improved requirements for the quality of life of individuals and changes in medical models, various minimally invasive interventional procedures, such as uterine artery interventional embolization, microwave coagulation, radiofrequency ablation, high-intensity focused ultrasound, and other treatment methods, are also increasingly used in the minimally invasive treatment of uterine fibroids. Uterine artery interventional embolization requires exposure to X-ray radiation, resulting in various complications, which limit its clinical application.^[8] In some studies,^[9-11] ultrasound-guided radiofrequency ablation is used to treat uterine fibroids, which is suggested to cause less trauma, significantly reduce tumor size, and markedly improve clinical symptoms and quality of life without serious complications.

Gynecological cysts are a common gynecologic disease, with the cyst being too large, causing compression symptoms prone to torsion. USGT is an ideal, minimally invasive, simple, economical, and effective treatment for patients with gynecologic cysts, who have experienced postoperative recurrence, received ineffective drug treatment, and refused surgery. In clinical practice, USGT in the treatment of gynecologic diseases has been reported to exhibit satisfactory clinical efficacy. However, in the early stages, there are no meaningful references for clinical practice because of the small sample size, and no reports of comprehensive evaluation using meta-analysis are retrieved. Therefore, we aimed to use meta-analysis to systematically evaluate the efficacy and safety of USGT for gynecologic diseases and thus provide an evidence-based medical reference for clinical treatment.

2. Materials and Methods

2.1. Literature search

The literature searches were conducted in databases of PubMed, Embase, and Web of Science for eligible studies published from 2002 to May 2022. A full-text search was conducted based on related subject terms as follows: “ultrasound-guided,” “interventional therapy,” “gynecology,” “cyst,” “gynecological disease,” “chocolate cyst,” “endometriosis,” “ovarian cyst,” “ovarian abscess,” “pelvic mass,” and “uterine fibroids.” A combination of keywords and subject words appeared in the retrieval form.

2.2. Inclusion criteria

Inclusion criteria were as follows: the language of publication was limited to English; the experimental design was scientific and reasonable, and the research designs and statistical methods were similar; outcome indicators included the following items: total effective rate, recurrence rate, occurrence of adverse reactions, and re-intervention rate; self-awareness of patients; voluntary participation of patients and their families in the research; and informed consent signed by the patient; and approval by the hospital ethics committee.

2.3. Exclusion criteria

The exclusion criteria were as follows: subjects with a severe infection, respiratory system disease, liver and kidney disease, blood disease, endocrine system disease, and digestive tract disease; review, systematic review, case analysis, and meta-analysis; duplicate publication; and presence of difficulties in data extraction.

2.4. Literature screening

All literature was searched, screened, and reviewed by 2 researchers separately. Disagreements during the review were resolved by a discussion or expert judgment. The data extracted from the article mainly included: authors and publication time; sample size, number of cases in each group, and average age of gynecologic disease types; specific intervention measures; and outcome indicators.

2.5. Statistical analysis

RevMan 5.3.0 was used to analyze the relevant data in the included articles. When the outcome variable was dichotomous, the relative risk ratio was calculated. When the outcome was a continuous variable, the mean difference was calculated. The results were presented using 95% confidence interval (CI). I^2 was used to assess heterogeneity among studies, and χ^2 was used for testing. If no statistical heterogeneity was found among the results of each study ($I^2 < 50\%$, and $P > .1$), a fixed-effects model was used for meta-analysis. If statistical heterogeneity was indicated among the results of each study ($I^2 \geq 50\%$, or $P \leq .1$), a random-effects model was used for the meta-analysis after the influence of apparent clinical heterogeneity was excluded. Subgroup and sensitivity analyses, or only descriptive analyses, were performed for studies with significant clinical heterogeneity. The meta-analysis was tested at $\alpha = 0.05$. When the number of included studies exceeded 10, an inverted funnel plot was used for bias analysis.

3. Results

3.1. Literature search results

A total of 3748 articles were initially retrieved, among which 2673 duplicate articles, reviews, and abstracts were excluded,

and 1075 articles remained. The articles for inclusion were screened by reading the titles and abstracts. Moreover, 1023 articles were initially screened, and 52 articles remained. The full text was read to screen out 40 articles that failed to meet the requirements, and the final study included 12 articles. The specific screening process is presented in Figure 1.

3.2. Basic characteristics of the included studies

A total of 12 articles were included in the review,^[12-23] and Table 1 lists the basic characteristics of the included articles.

3.3. Meta-analysis results

3.3.1. Clinical efficacy. Among the 12 included articles, 3 articles^[19,20,22] used clinical efficacy to evaluate the effect of USGT in the treatment of related gynecologic diseases. None of these 3 articles included controlled experiments, and all were self-descriptive experiments. The heterogeneity test yielded $I^2 = 100\%$ and $P < .00001$. USGT was found to significantly affect related gynecologic diseases [risk ratio = 0.84, 95% CI 0.84–0.84] (Fig. 2).

3.3.2. Adverse reactions. Among the 12 included articles, 6 articles^[14,15,17,18,22,23] used adverse reaction status to assess the safety of USGT for related gynecologic diseases, and the articles provided a specific number of adverse reactions after treatment.

Among the 6 articles included, 3 articles^[14,15,17] were controlled studies, and 3^[18,22,23] were descriptive studies. The heterogeneity test for the controlled studies yielded $I^2 = 92\%$ and $P < .00001$. Therefore, a random-effects model was used to conduct a meta-analysis, and the results of the meta-analysis showed that the effect of USGT was more significant in the experimental group compared with the control group [OR = 0.21, 95% CI (0.14, 0.31), $P < .00001$]. The adverse reactions in the experimental group were significantly fewer compared with the control group (Fig. 3). The heterogeneity test for descriptive studies yielded $I^2 = 100\%$ and $P < .00001$. Therefore, a random-effects model was used to conduct a meta-analysis, showing that the therapeutic effect of ultrasound-guided interventional therapy on gynecologic diseases was significant [OR = 0.03, 95% CI (0.03, 0.03), $P < .00001$] (Fig. 3).

3.3.3. Recurrence rate. Among the 12 included articles, 4 articles^[12,17,18,21] used the recurrence rate to assess the effect of USGT on related gynecologic diseases, and these articles specified the number of adverse reactions after treatment. Among the 4 included articles, 2 articles^[12,17] were controlled studies, and the other 2 articles^[18,21] were descriptive studies. The heterogeneity test for the controlled studies yielded $I^2 = 0\%$ and $P = .60$. Therefore, a fixed-effect model was used for meta-analysis, showing that after ultrasound guidance, no significant difference in the probability of recurrence was found between the experimental group and control group [OR = 1.04, 95% CI (0.59,1.83), $P = .88$] (Fig. 4). The heterogeneity test for descriptive studies yielded $I^2 = 100\%$

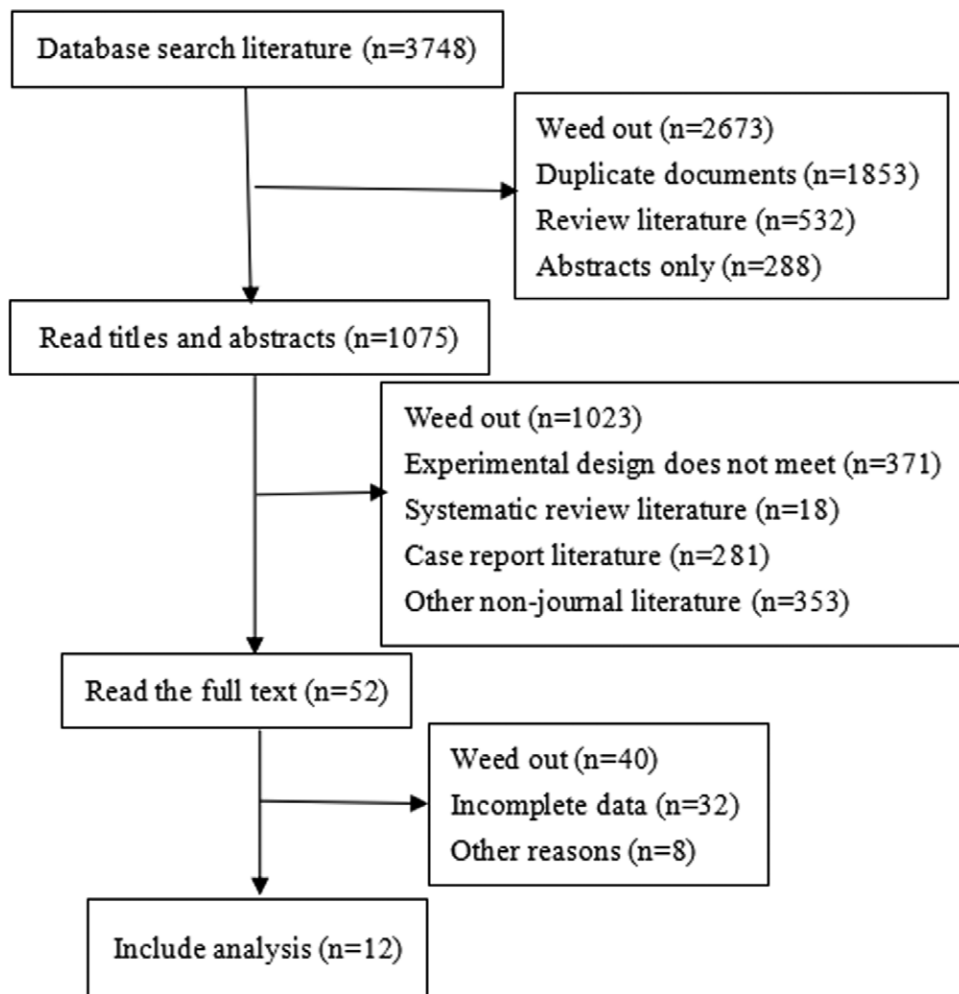


Figure 1. Literature search.

Table 1

Basic characteristics of the 20 included articles.

Author(s), publication time	Sample size (cases)	Group (cases)	Disease type	Average age (yr)	Intervention measures	Outcome indicators
Cai et al, 2016 ^[12]	79	Ultrasound intervention group (n = 37) Laparoscopic group (n = 42)	Ovarian cyst pediculotorsion	28.96 ± 3.59 29.25 ± 3.51	Patients underwent emergency ultrasound intervention Patients underwent laparoscopic surgery	b
Mohr–Sasson et al, 2018 ^[13]	132	Study group (n = 68)	Ovarian endometriomas	0.44 ± 0.77	5 mL of retention of ethanol transvaginal aspiration and sclerotherapy of endometrioma(s) > 5 mL of retention	d
Goharkhay et al, 2007 ^[14]	58	Control group 1 (n = 64) Ultrasound intervention group (n = 8)	– Tubo-ovarian abscess	31.1 (19–44) 32.5 (18–44)	Primary image-guided drainage with concomitant intravenous antibiotics. Treatment with intravenous antibiotics alone	c
Chen et al, 2018 ^[15]	1939	High-intensity focused ultrasound (HIFU) group (n = 1353) Control group (n = 586)	Uterine fibroids	–	HIFU myomectomy.	c, d
Barnard et al, 2017 ^[16]	83	Ultrasound intervention group (n = 43) Control group (n = 40)	Uterine fibroids	–	Focused ultrasound surgery	D
Shawki et al, 2011 ^[17]	86	Group I (n = 43) Group II (n = 43)	Ovarian endometriomas	(32 ± 12.24) (33 ± 45.30)	Transvaginal ultrasound aspiration and in situ methotrexate injection	b, c
Visus et al, 2015 ^[18]	50	50	Simple ovarian cysts	53.13 6 15.25	Ultrasound-guided fine-needle aspiration and ethanol sclerotherapy	b, c
Park et al, 2014 ^[19]	79	79	Symptomatic uterine fibroid tumors with an immediate nonperfused volume (NPV) ratio of 80% or more.	43.6 4.4	MR-guided high-intensity focused US ablation	a
Wang et al, 2011 ^[20]	68	68	For the ethanol short-time retention group, after washing with saline, the cyst was injected with 95% ethanol with a volume amounting to half of the fluid aspirated from the cyst. After 10 min, the remaining ethanol was aspirated.	–	Postoperative recurrent chocolate cysts	a
Kostrzewa, et al, 2019 ^[21]	84	84	Simple ovarian cysts	–	Transvaginal ultrasound-guided aspiration of SOC	b
De la Noval et al, 2020 ^[22]	156	156	Low-risk adnexal cyst	–	Transvaginal US-guided aspiration	a, c
Zhang et al, 2011 ^[23]	40	40	Symptomatic uterine fibroid	–	Percutaneous insertion of the microwave (MW) antenna into the fibroid, under US guidance, to perform the ablation.	c

a: total effective rate; b: recurrence rate; c: occurrence of adverse reactions; d: reintervention rate.

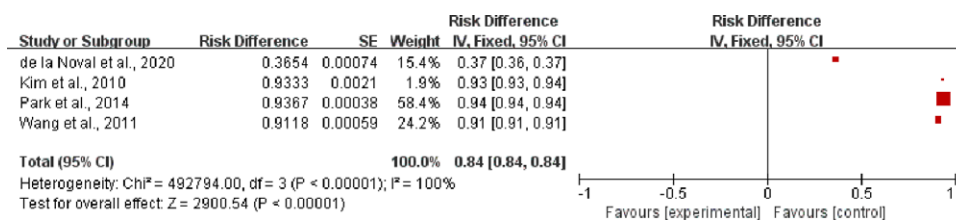


Figure 2. Meta-analysis results for clinical efficacy.

and $P < .00001$. Therefore, a random-effects model was used to conduct a meta-analysis, indicating that the therapeutic effect of USGT on gynecologic diseases was significant [OR = 0.13, 95% CI (0.13, 0.13), $P < .00001$] (Fig. 4).

3.3.4. Reintervention rate. Among the 12 included articles, 3 articles^[12–23] used the re-intervention rate to evaluate the effect

of USGT on related gynecologic diseases and specified the number of re-intervention treatments. The heterogeneity test of the studies yielded $I^2 = 2\%$ and $P = .36$. Therefore, a fixed-effect model was used for meta-analysis, revealing that the probability of re-intervention in the experimental group after ultrasound guidance was significantly higher compared with the control group [OR = 3.39, 95% CI (1.29, 8.86), $P = .01$] (Fig. 5).

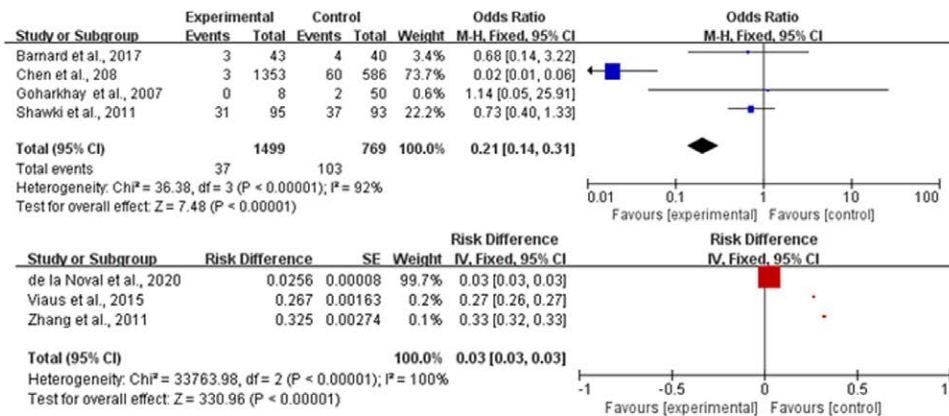


Figure 3. Meta-analysis results for adverse reactions.

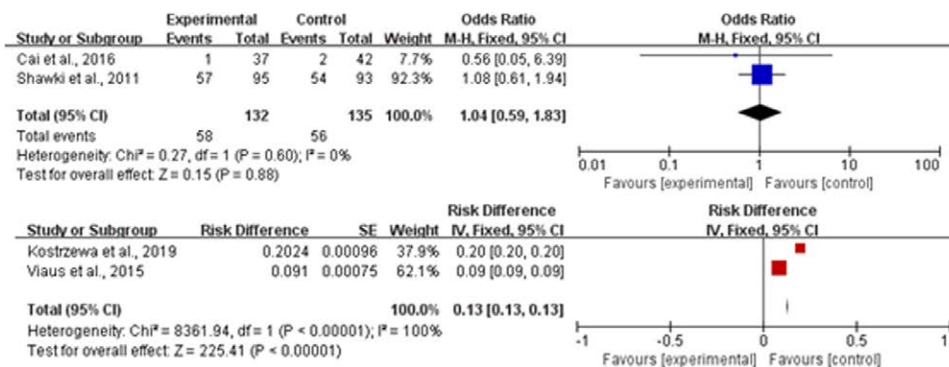


Figure 4. Meta-analysis results for recurrence rate.

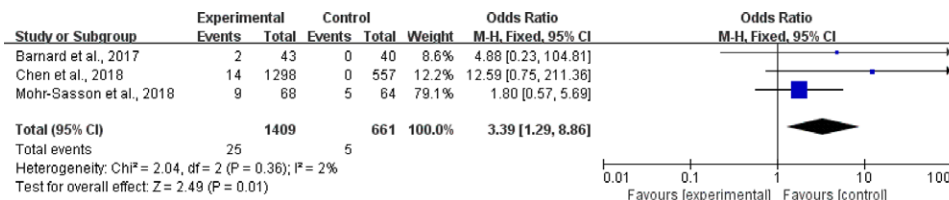


Figure 5. Meta-analysis results for the reintervention rate.

4. Discussion

USGT refers to the ultrasound-guided puncturing of catheters and puncture needles into the body and various minimally invasive procedures. The method has become an important means of diagnosis and treatment in modern obstetrics and gynecology, which can guide the selection of puncture sites, accurately evaluate the effect of treatment, and provide an objective basis for further treatment.

Ovarian cysts are a common disease in women, especially those of childbearing age. If the symptoms are not promptly treated, subsequent fertility problems may occur. Using USGT to treat women with ovarian cysts can effectively avoid complications, such as pelvic adhesion, and prevent any impact on the reproductive function of nulliparous women. When treating patients with ovarian cysts using ultrasound, the cyst fluid needs to be extracted from the patient's body first, usually by a puncture. After the extraction is completed, a sclerosing agent needs to be injected. Anhydrous ethanol is the most commonly used sclerosing agent, which destroys the cyst intima in the patient, inducing aseptic inflammation and finally reaching the

cyst. Theoretically, the use of USGT in the treatment of ovarian cyst disease is not expected to cause complications affecting the reproductive function of female patients. Hsieh et al^[24] have demonstrated that ultrasound-guided interventional sclerotherapy for ovarian chocolate cysts is a practical treatment approach, and retaining a small amount of ethanol is more effective than pure ethanol irrigation. Koutlaki et al^[25] have introduced the experience of ultrasound-guided transvaginal ovarian cyst puncture and indicated that transvaginal ovarian cyst puncture is safe and reliable. Cho et al^[26] have suggested that repeatedly using high-intensity focused ultrasound to treat uterine fibroids is harmless and effective. USGT minimally invasive treatment of uterine fibroids is simple, safe, less traumatic, and effective. It is also associated with fewer complications and can preserve the integrity of the uterus. The appropriate minimally invasive treatment method should be selected based on the size of fibroids, particularly for patients with fertility requirements. Therefore, it has a good treatment prospect.

The functions of these treatment options in various clinical scenarios should be realized to perform appropriate consultation. Patients should be informed of potential benefits

and harms and be actively involved in deciding on surgery. The treatment decision depends on the clinical symptoms, the desire of patients for subsequent fertility and pregnancy, as well as efficacy and the need for repeated interventions. In our systematic review, evidence for using interventional ultrasound is primarily available online in controlled and descriptive studies. In addition, evidence robustly assessing the comparative efficacy and safety of interventional ultrasound in these studies for the treatment of gynecologic disorders remains insufficient. However, randomized controlled trials are not always feasible in specific clinical settings. Therefore, descriptive studies are valuable for determining more accurate outcomes in clinical practice.

There were several limitations of this study as follows: we only included English literature reviews, and the influence of language factors could not be excluded; the literature included in this paper consisted of published literature reviews; unpublished related literature reviews, and reports, whereas other gray literature reviews were excluded, which might also affect the evaluation results. Therefore, high-quality clinical studies with large sample sizes and a long-term follow-up should be conducted to further evaluate the role of USGT in treating gynecologic diseases using advanced treatment protocols and equipment relative to other approaches.

Author contributions

Conceptualization: Fengsheng Zhou, Min Xuan.

Data curation: Chunyan Wu, Min Xuan.

Formal analysis: Chunyan Wu, Fengsheng Zhou, Jing Zhang, Min Xuan.

Funding acquisition: Fengsheng Zhou.

Project administration: Fengsheng Zhou, Min Xuan.

Resources: Chunyan Wu.

Software: Chunyan Wu, Jing Zhang, Min Xuan.

Supervision: Chunyan Wu.

Validation: Chunyan Wu, Fengsheng Zhou, Jing Zhang, Min Xuan.

Writing – original draft: Min Xuan.

Writing – review & editing: Fengsheng Zhou, Min Xuan.

References

- [1] Simons-Linares CR, Chahal P. Advances in interventional endoscopic Ultrasound (EUS): a technical review. *J Clin Gastroenterol*. 2020;54:579–90.
- [2] Cheng Z, Liang P. Advances in ultrasound-guided thermal ablation for symptomatic benign thyroid nodules. *Adv Clin Exp Med*. 2020;29:1123–9.
- [3] Gummadi MS, Eisenbrey J, Li MJ, et al. Advances in modern clinical ultrasound. *Adv Ultrasound Diag Ther*. 2018;2:51.
- [4] Naftalin J, Bean E, Saridogan E, et al. Imaging in gynecological disease (21): clinical and ultrasound characteristics of accessory cavitated uterine malformations. *Ultrasound Obstet Gynecol*. 2021;57:821–8.
- [5] García EG, de Miguel Manso S, Tejedor JG, et al. Transcervical drainage of abdominal-pelvic abscess after laparoscopic sacrocolpopexy. *Int Urogynecol J*. 2021;32:581–5.
- [6] Fei D, Li Y, Sui G. Clinical study of ultrasound-guided puncture lauro-macrogol sclerosis in the treatment of ovarian endometriosis cyst. In: *AIP Conference Proceedings*, 2018. AIP Publishing LLC, p 030009
- [7] Li Y, Dong X, Ultrasound DO. Ultrasound guided sclerotherapy with medical ethanol and polycinnamol for treatment of ovarian endometriosis cysts. *Chin J Med Ultrasound (Electronic Edition)*. 2019;16:438.
- [8] David M, Ebert AD. Treatment of uterine fibroids by embolization--advantages, disadvantages, and pitfalls. *Eur J Obstet Gynecol Reprod Biol*. 2005;123:131–8.
- [9] Kim CH, Kim SR, Lee HA, et al. Transvaginal ultrasound-guided radiofrequency myolysis for uterine myomas. *Hum Reprod*. 2011;26:559–63.
- [10] Guido RS, Macer JA, Abbott K, et al. Radiofrequency volumetric thermal ablation of fibroids: a prospective, clinical analysis of two years' outcome from the Halt trial. *Health Qual Life Outcomes*. 2013;11:139.
- [11] Giacomozzi AR, Vindas AP, Silva AA Jr, et al. Latin American consensus on guidelines for chronic migraine treatment. *Arq Neuropsiquiatr*. 2013;71:478–86.
- [12] Cai ZH, Wang WM, Shi JR, et al. Comparison of ultrasound interventional and laparoscopic surgeries for ovarian cyst pediculotorsion. *J Acute Dis*. 2016;5:458–61.
- [13] Mohr-Sasson A, Machtinger R, Mashiah R, et al. Long-term outcome of MR-guided focused ultrasound treatment and laparoscopic myomectomy for symptomatic uterine fibroid tumors. *Am J Obstet Gynecol*. 2018;219:375.e371–7.
- [14] Goharkhay N, Verma U, Maggiorotto F. Comparison of CT- or ultrasound-guided drainage with concomitant intravenous antibiotics vs. intravenous antibiotics alone in the management of tubo-ovarian abscesses. *Ultrasound Obstet Gynecol*. 2007;29:65–9.
- [15] Chen J, Li Y, Wang Z, et al. Evaluation of high-intensity focused ultrasound ablation for uterine fibroids: an IDEAL prospective exploration study. *BJOG*. 2018;125:354–64.
- [16] Barnard EP, AbdElmagied AM, Vaughan LE, et al. Periprocedural outcomes comparing fibroid embolization and focused ultrasound: a randomized controlled trial and comprehensive cohort analysis. *Am J Obstet Gynecol*. 2017;216:500.e501–11.
- [17] Shawki HE, Elmorsi M, Samir A, et al. In situ methotrexate injection after transvaginal ultrasound-guided aspiration of ovarian endometriomas: a randomized controlled trial. *Middle East Fertil Soc J*. 2011;16:224–31.
- [18] Castellarnau Visus M, Ponce Sebastia J, Carreras Collado R, et al. Preliminary results: ethanol sclerotherapy after ultrasound-guided fine needle aspiration without anesthesia in the management of simple ovarian cysts. *J Minim Invasive Gynecol*. 2015;22:475–82.
- [19] Park MJ, Kim YS, Rhim H, et al. Safety and therapeutic efficacy of complete or near-complete ablation of symptomatic uterine fibroid tumors by MR imaging-guided high-intensity focused US therapy. *J Vasc Interv Radiol*. 2014;25:231–9.
- [20] Wang LL, Dong XQ, Shao XH, et al. Ultrasound-guided interventional therapy for recurrent ovarian chocolate cysts. *Ultrasound Med Biol*. 2011;37:1596–602.
- [21] Kostrzewa M, Zając A, Wilczyński JR, et al. Retrospective analysis of transvaginal ultrasound-guided aspiration of simple ovarian cysts. *Adv Clin Exp Med*. 2019;28:1531–5.
- [22] Díaz de la Noval B, Rodríguez Suárez MJ, Fernández Ferrera CB, et al. Transvaginal ultrasound-guided fine-needle aspiration of adnexal cysts with a low risk of malignancy: our experience and recommendations. *J Ultrasound Med*. 2020;39:1787–97.
- [23] Zhang J, Feng L, Zhang B, et al. Ultrasound-guided percutaneous microwave ablation for symptomatic uterine fibroid treatment--a clinical study. *Int J Hyperthermia*. 2011;27:510–6.
- [24] Hsieh CL, Shiau CS, Lo LM, et al. Effectiveness of ultrasound-guided aspiration and sclerotherapy with 95% ethanol for treatment of recurrent ovarian endometriomas. *Fertil Steril*. 2009;91:2709–13.
- [25] Koutlaki N, Nikas I, Dimitraki M, et al. Transvaginal aspiration of ovarian cysts: our experience over 121 cases. *Minim Invasive Ther Allied Technol*. 2011;20:155–9.
- [26] Cho JY, Kim SH, Kim SY, et al. Efficacy and safety of daily repeated sonographically guided high-intensity focused ultrasound treatment of uterine fibroids: preliminary study. *J Ultrasound Med*. 2013;32:397–406.