

# Hemorrhagic bullous dermatosis caused by warfarin therapy



Annie Ferguson, MD, and Spring Golden, MD  
Portland, Oregon

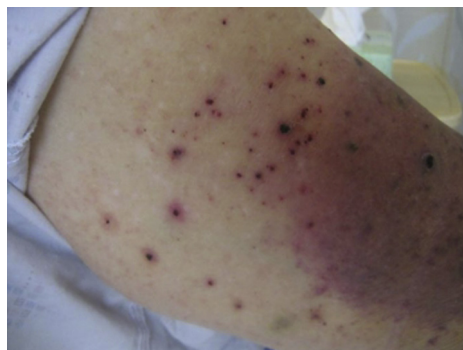**Key words:** blood thinners; bullous; drug reactions; hemorrhagic bullous dermatosis; heparin; warfarin.

## INTRODUCTION

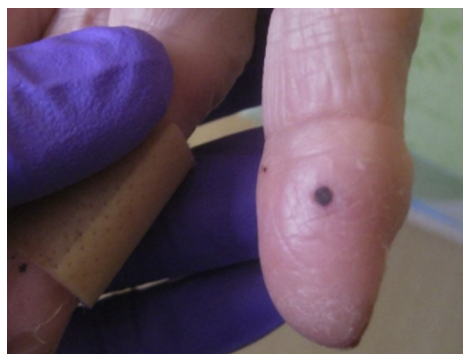
Hemorrhagic bullous dermatosis is a rare, generalized skin reaction with unknown pathogenesis, described in association with heparin therapy. Heparin is known to cause injection site reactions and ecchymosis but rarely causes global cutaneous reactions, making hemorrhagic bullous dermatosis an unusual clinical entity. The condition occurs within 5 to 21 days of the initiation of therapy at locations distant to the site of subcutaneous heparin injection. Characteristic lesions are painless, hemorrhagic papules on a background of uninvolved skin. The histologic findings are usually nonspecific but can help rule out thrombosis, vasculitis, or marked inflammatory changes. Skin lesions usually resolve after discontinuation of heparin. We present a case of hemorrhagic bullous dermatosis in an 82-year-old woman recently started on warfarin therapy and briefly review skin effects of anticoagulation.

## CASE REPORT

An 82-year-old woman with a medical history of congestive heart failure, myelodysplastic syndrome, thrombocytopenia, and discoid lupus erythematosus was started on warfarin therapy for new-onset atrial flutter. Ten days after initiation of treatment, she presented with a sudden outbreak of painless, nonpruritic, black papules on her extremities (Figs 1 and 2). Given the concern for warfarin-related skin necrosis, she was started on vitamin K and switched to a daily subcutaneous injection of enoxaparin as an alternative anticoagulation treatment. Subsequently, she had epistaxis, which required nasal packing. She was admitted to the hospital 7 days after starting enoxaparin, because of



**Fig 1.** Papules with overlying hemorrhagic crusting located on the proximal arm (underlying bruising is caused by recent trauma to the arm and is not a result of the patient's hemorrhagic bullous dermatosis).



**Fig 2.** Single hemorrhagic papule on the lateral fingertip.

her worsening skin condition, which now involved her mucous membranes.

Physical examination found several 2- to 3-mm discrete black, purpuric papules, some with overlying hemorrhagic crust, distributed on her face, arms, dorsal and palmar hands, and feet. Similar

From the Dermatology Department, the Oregon Health and Science University.

Funding sources: None.

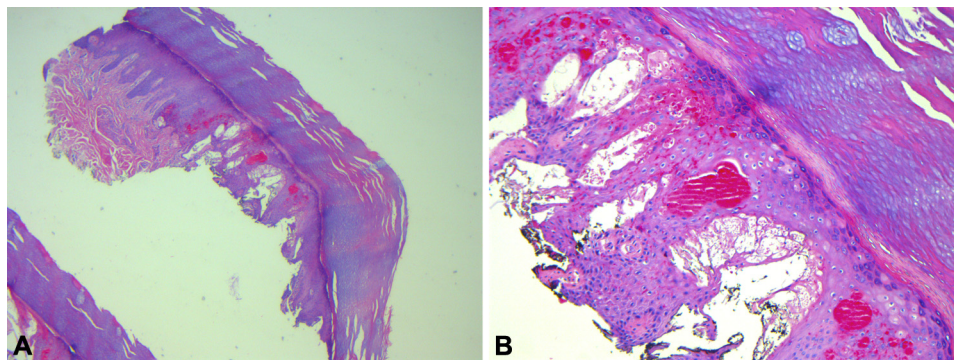
Conflicts of interest: None declared.

Correspondence to: Annie Ferguson, MD, Mail code: CH16D, 3303 SW Bond Ave, Portland, OR 97239-4501. E-mail: [fergusoa@ohsu.edu](mailto:fergusoa@ohsu.edu).

JAAD Case Reports 2016;2:156-8.  
2352-5126

© 2016 by the American Academy of Dermatology, Inc. Published by Elsevier, Inc. This is an open access article under the CC BY-NC-ND license (<http://creativecommons.org/licenses/by-nc-nd/4.0/>).

<http://dx.doi.org/10.1016/j.jidcr.2016.02.005>



**Fig 3.** Results of a punch biopsy showed epidermal hyperplasia (**A**) and dilated vessels and epithelial necrosis with fibrin deposition (**B**). (Hematoxylin-eosin stain; original magnifications: **A**,  $\times 40$ ; **B**,  $\times 100$ .)

lesions were noted on her tongue. Blood counts showed a chronic anemia related to her myelodysplastic syndrome (hemoglobin, 9.1 g/dL). She had acute on chronic thrombocytopenia, with a platelet count of 33 K/mm<sup>3</sup>. Results of a heparin-platelet factor 4 test were negative. Results of comprehensive metabolic panel, anti-double-stranded DNA, and C3 and C4 tests were all within normal limits. Coagulation studies were notable for mildly elevated international normalized ratio and partial thromboplastin time of 1.29 and 54.7 seconds, respectively. A 4-mm biopsy from the left big toe found focal parakeratosis overlying a hyperplastic epidermis, within which were dilated vessels, surrounded by a collarette of epithelium and epithelial necrosis with fibrin deposition, without evidence of vasculitis, capillary thrombosis, or significant inflammatory infiltrate (Fig 3). Discontinuation of anticoagulant therapy resulted in spontaneous regression of her lesions.

## DISCUSSION

Hemorrhagic bullous dermatosis is a blistering eruption associated with heparin therapy. A characteristic report of this entity came from Perrinaud et al<sup>1</sup> in 2006. Interestingly, the pathogenesis of this condition remains poorly understood.<sup>1</sup> Both unfractionated heparin and low-molecular-weight heparin have been implicated, and to our knowledge, as few as 14 cases have been reported in the literature.<sup>1-7</sup> This is an unusual case of hemorrhagic bullous dermatosis associated with warfarin monotherapy. In cases described with heparin initiation, this entity typically appears within 5 to 21 days and presents as numerous asymptomatic and tense, blood-filled bullae and papules on uninfamed skin. These lesions involve areas distant to the injection site. Laboratory studies are generally within normal limits. Histopathology often shows nonspecific intraepidermal or subcorneal vesicles

filled with red blood cells without evidence of vasculitis, capillary thrombosis, or significant inflammatory infiltrate. The condition resolves without sequelae after heparin is discontinued or may spontaneously resolve despite continued heparin use. Heparin skin reactions are normally confined to the site of injection, making the global distribution of hemorrhagic bullous dermatosis particularly unusual. Injection site reactions may be immune mediated or non-immune mediated and include skin necrosis, hematomas, ecchymoses, erythematous plaques, nodules, angioedema, dermatitis, and urticaria.<sup>3,8</sup> Heparin rarely causes generalized skin reactions, although diffuse necrosis may signify the cutaneous manifestation of heparin-induced thrombocytopenia, a serious paradoxical hypercoagulable state.

Cutaneous toxicities associated with warfarin, such as dermatitis and urticaria, are rare. The most dreaded complication, skin necrosis, is seen in about 0.01% to 0.1% of patients.<sup>8</sup> Like heparin-induced thrombocytopenia, warfarin-induced skin necrosis is a paradoxical hypercoagulable reaction, causing occlusive thrombi in cutaneous and subcutaneous venules. It occurs early on in treatment, usually within 3 to 10 days. The condition manifests suddenly as painful, erythematous plaques with predilection for adipose-rich areas such as the buttocks, hips, and breasts but may occur on extremities and the penis.<sup>8</sup> Plaques transform into bullae, which blister and develop into full-thickness skin necrosis. Affected patients often have a history of receiving an initial large loading dose of warfarin. Our patient's recent trial of warfarin raised concern for skin necrosis. However, her history was not consistent with skin necrosis, as she received a prophylactic dose of warfarin, and her skin lesions were painless.

Reports of hemorrhagic bullous dermatosis in patients receiving 2 or even 3 blood thinning agents, has led to speculation that the dermatosis may be a

result of overanticoagulation.<sup>1,2</sup> However, the literature does not fully support overanticoagulation as the primary pathogenesis, and there are numerous case reports of hemorrhagic bullous dermatosis presenting in patients on heparin monotherapy with coagulation studies and platelet levels within normal limits. It is unclear what role our patient's chronic thrombocytopenia or myelodysplastic syndrome played in the development of her skin condition. To our knowledge, thrombocytopenia has not been a reported laboratory abnormality among previous case reports of hemorrhagic bullous dermatosis. Our patient's cutaneous reaction to warfarin in the setting of chronic thrombocytopenia may be an idiosyncratic reaction or represent a previously unrecognized medication reaction in thrombocytopenic patients, although it is difficult to draw any conclusions from a single case report. Furthermore, the worsening of the patient's condition after discontinuation of warfarin and initiation of enoxaparin may be because of combined anticoagulant effects or represent a secondary and more severe reaction to enoxaparin.

#### REFERENCES

1. Perrinaud A, Jacobi D, Machet MC, Grodet C, Gruel Y, Machet L. Bullous hemorrhagic dermatosis occurring at sites distant from subcutaneous injections of heparin: three cases. *J Am Acad Dermatol*. 2006;54:5-7.
2. Maldonado Cid P, Moreno Alonso de Celada R, Herranz Pinto P, et al. Bullous hemorrhagic dermatosis at sites distant from subcutaneous injections of heparin: A report of 5 cases. *J Am Acad Dermatol*. 2012;67:e220-e222.
3. Choudhry S, Fishman PM, Hernandez C. Heparin-Induced Bullous Hemorrhagic Dermatitis. *Cutis*. 2013;91:93-98.
4. Gonzales UP, Scott GA, Briones AJ, Pentland AP. Remote hemorrhagic bullae occurring in a patient treated with subcutaneous heparin. *Arch Dermatol*. 2009;145:604-605.
5. Thullier D, Chaby G, Dadban A, et al. Low-molecular-weight heparin-induced bullous haemorrhagic dermatosis associated with cell-mediated hypersensitivity. *Ann Dermatol Venereol*. 2009;136:705-708.
6. Pena ZG, Suszko JW, Morrison LH. Hemorrhagic bullae in a 73-year-old man. Bullous hemorrhagic dermatosis related to enoxaparin use. *JAMA Dermatology*. 2013;149:871-872.
7. Villanueva CA, Nájeral L, Espinosa P, Borbujo J. Bullous hemorrhagic dermatosis at distant sites: A report of 2 new cases due to enoxaparin injection and a review of the literature. *Actas Dermosifiliogr*. 2012;103:816-819.
8. Bircher AJ, Harr T, Hohenstein L, Tsakiris DA. Hypersensitivity reactions to anticoagulant drugs: diagnosis and management options. *Allergy*. 2006;61:1432-1440.