

[ CASE REPORT ]

## Hemorrhagic Pericardial Cyst Complicated with Constrictive Pericarditis

Mitsutoshi Oguri<sup>1</sup>, Shiou Ohguchi<sup>1</sup>, Kunihiko Takahara<sup>1</sup>, Yoshihiro Kawamura<sup>1</sup>, Yuki Yokoi<sup>1</sup>, Kazuhiro Izumi<sup>1</sup>, Takashi Fujita<sup>2</sup>, Kei Yagami<sup>2</sup> and Masato Mutsuga<sup>3</sup>

### Abstract:

Pericardial cysts are rare abnormalities and are usually asymptomatic. Although several case reports on their diagnosis and treatment have been published, those on hemorrhagic pericardial cysts remain limited. We herein report the case of a 70-year-old man with a hemorrhagic pericardial cyst complicated with constrictive pericarditis 2 years after the initial diagnosis.

**Key words:** hemorrhagic pericardial cyst, constrictive pericarditis

(Intern Med 57: 3565-3568, 2018)

(DOI: 10.2169/internalmedicine.1047-18)

### Introduction

Pericardial cysts are rare clinical entities and account for 6% of mediastinal masses and 33% of mediastinal cysts (1). They are mostly asymptomatic and are detected incidentally (1). The initial diagnosis is generally established using chest radiography, and a further evaluation with echocardiography, computed tomography (CT), or magnetic resonance imaging is often performed for a definitive diagnosis (2). Treatment is generally not required in patients without symptoms or complications.

Pericardial cysts can be congenital or acquired (3). Among acquired cysts, inflammatory cysts comprise pseudocysts as well as encapsulated and loculated pericardial effusions; these are likely caused by a secondary infection, rheumatic pericarditis, trauma, or cardiac surgery (4). Only a few reports on rare complications, such as hemorrhaging, cardiac tamponade, and rupture (1, 5), have been published.

We herein report a case of inflammatory pericardial cyst with hemorrhaging into the cyst and constrictive pericarditis two years after the initial diagnosis.

### Case Report

A 70-year-old Japanese man complaining of appetite loss

and a low-grade fever was admitted to our hospital. He had a 10-year medical history of rheumatic arthritis. He had undergone primary coronary intervention for acute posterior myocardial infarction three years before this admission and had received aspirin 100 mg and clopidogrel 75 mg. Other medicines included apixaban 5 mg, losartan 25 mg, spironolactone 25 mg, bisoprolol 0.625 mg, methotrexate 8 mg, and salazosulfapyridine 500 mg. No pericardial effusion or an echolucent mass had been noted on transthoracic echocardiography at discharge.

Two years before the present admission, he had been admitted for the evaluation of a persistent fever and infection; contrast-enhanced chest computed tomography (CT) and transthoracic echocardiography were performed, showing a well-defined, non-enhanced mass adjacent to the right ventricle and pleural effusion (Fig. 1A and B) and an echolucent space with a few loculated lesions next to the right atrium and ventricle (Fig. 1C), respectively. These findings were consistent with those of a pericardial cyst. Given the clinical presentation, infection or malignancy was suspected; aspiration was therefore performed, which revealed exudative fluid, low pericardial fluid sugar, and no microorganisms or malignant cells. Because the clinical signs improved spontaneously, no particular treatment was needed. He was clinically followed and had an uneventful course.

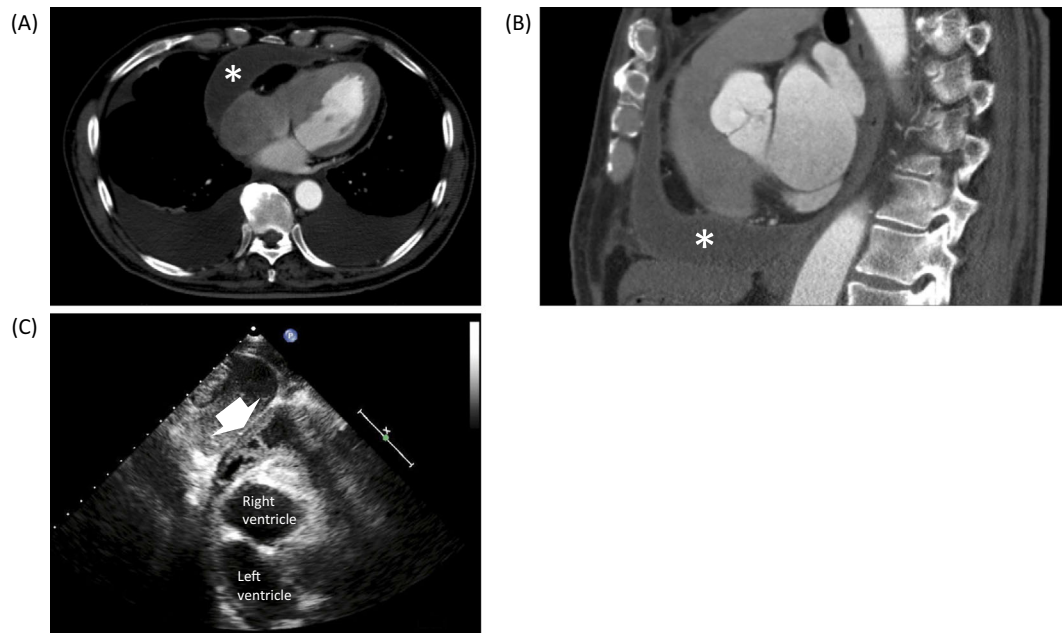
At the present admission, the patient was hospitalized

<sup>1</sup>Department of Cardiology, Kasugai Municipal Hospital, Japan, <sup>2</sup>Department of Cardiac Surgery, Gifu Prefectural Tajimi Hospital, Japan and

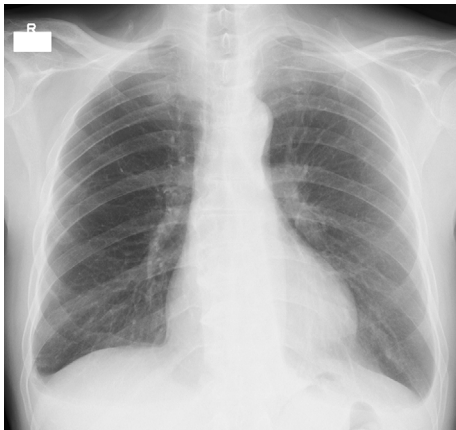
<sup>3</sup>Department of Cardiac Surgery, Nagoya University Graduate School of Medicine, Japan

Received: February 19, 2018; Accepted: May 13, 2018; Advance Publication by J-STAGE: August 10, 2018

Correspondence to Dr. Mitsutoshi Oguri, oguricap0909@gmail.com



**Figure 1.** Contrast-enhanced chest CT image at the initial diagnosis showing a well-defined, non-enhanced pericardial cyst (asterisk): axial view (A), sagittal view (B). A subcostal long axis view showing an echolucent space with a couple of partitions adjacent to the right ventricle at the initial diagnosis (white arrow) (C). CT: computed tomography



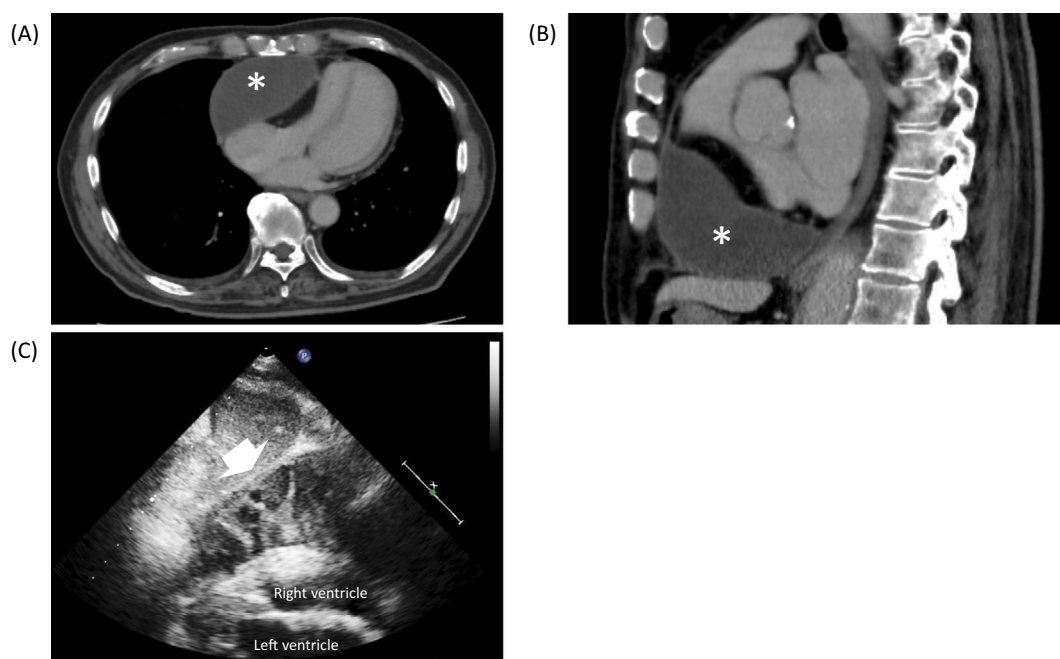
**Figure 2.** Chest radiograph showing cardiomegaly and costophrenic angle blunting.

with distended jugular veins and peripheral leg edema with redness and purpura. He was taking methotrexate 8 mg, salazosulfapyridine 500 mg, and corticosteroid 5 mg to control his rheumatoid arthritis, which had a high disease activity (disease activity score 28). His blood pressure was 120/60 mm Hg, with a regular pulse rate at 100 beats/min. Chest radiography showed an enlarged cardiac silhouette and costophrenic angle blunting (Fig. 2). Electrocardiography revealed sinus tachycardia at a rate of 100 beats/min and abnormal Q waves in leads II, III, and aV<sub>F</sub>. The white blood cell count and serum concentrations of C-reactive protein were elevated at 9,700/ $\mu$ L and 17.4 mg/dL, respectively. Iron deficiency anemia was also observed (red blood cell count,  $409 \times 10^4$ / $\mu$ L; hemoglobin, 9.8 g/dL; hematocrit,

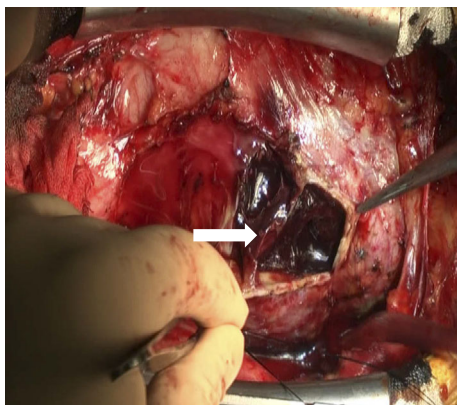
34.3%; MCV, 82; Ferritin, 17 ng/dL). Contrast-enhanced chest CT revealed an enlarged cyst in the right pericardium (Fig. 3A and B). Transthoracic echocardiography showed an echogenic and multilocular pericardial lesion with severe compression of the right atrium and ventricle (Fig. 3C). The partition structures were wobbling, with a lack of flow on Doppler color imaging. A ventricular septal shift with a medial e' of 9.0 cm/s was seen. For the further evaluation of his lower leg purpura, a skin biopsy was performed, which established the diagnosis of leukocytoclastic vasculitis.

His fever, lower leg purpura, and inflammatory reaction resolved spontaneously within a week; we therefore speculated that his symptoms had been caused by lower leg vasculitis. Because distension of the jugular veins and lower leg edema persisted, mechanical compression by the enlarged pericardial cyst was deemed hemodynamically significant, and treatment was considered necessary. The patient was referred to a cardiac surgeon. As the cyst was tightly attached to the right atrium and ventricle, a small incision was made, and the cyst was subsequently removed (Fig. 4). A 4×10-cm blood-containing cyst was completely resected successfully; however, no reduction in the central venous pressure was seen. The presence of a stiff right-sided pericardium implied concurrent constrictive pericarditis. We therefore performed a subsequent partial pericardiectomy. Continuous monitoring during surgery showed a central venous pressure decrease from 20 to 12 mmHg owing to partial pericardiectomy.

The postsurgical course was uneventful, and the patient was discharged after 5 days on colchicine 0.5 mg daily. A pathologic evaluation of the cyst confirmed the diagnosis of an inflamed pericardial cyst and constrictive pericarditis with



**Figure 3.** Follow-up CT obtained after two years shows an enlarged pericardial cyst (asterisk): axial view (A), sagittal view (B). The pericardial cyst became multilocular, and an echogenic lesion with severe compression of the right ventricle (white arrow) (C) was seen. CT: computed tomography



**Figure 4.** Intraoperative photograph of the blood-containing pericardial cyst attached to the right atrium and ventricle. The partition structure is present in the cyst (white arrow).

hyperplasia of fibrous connective tissue. Cultures from the extracted tissue were negative for bacteria and fungi.

## Discussion

Pericardial cysts are usually unilocular and smooth and vary widely in size (2-28 cm) (6). Although approximately 70% of patients with pericardial cysts are asymptomatic, compression by large cysts can cause various symptoms, such as dyspnea, pain, and cough (1). Inflammation is an etiology of pericardial cysts, including chronic inflammatory diseases and bacterial infection (4); it is also considered a major complication leading to eventual symptom development. Our case may therefore be relevant to cases of inflammatory pericardial cysts with encapsulated and loculated

pericardial effusions. Furthermore, to our knowledge, there have only been five reports of hemorrhagic pericardial cysts (7-11). These cysts can often lead to life-threatening conditions, such as cardiac tamponade, necessitating surgical removal. This report is significant because of the rare presentation of this case, including the presence of hemorrhaging in the cyst, concurrent constrictive pericarditis, and mid-term changes in the clinical findings.

Constrictive pericarditis was diagnosed based on symptoms and signs indicating right heart failure and septal compression on echocardiography. Furthermore, in our patient, effusive constrictive pericarditis due to the persistent elevation of central venous pressure was diagnosed (4). Constrictive pericarditis can be idiopathic but is common after cardiac surgery and radiation therapy; etiologies also include viral infection and connective tissue disorder (12). Although an association between pericardial cyst and constrictive pericarditis has not been reported, pericardial inflammation affecting the surrounding tissues can induce constrictive pericarditis. We should recognize that constrictive pericarditis may be an important life-threatening complication of inflammatory pericardial cysts.

There are a few reports on the conservative management of pericardial cysts. Simsek et al. reported the conservative management of an asymptomatic patient for one year (13). More recently, Lin et al. reported the successful conservative management of an asymptomatic patient with a large pericardial cyst who was followed up with non-enhanced CT for six months (14). However, reports on the long-term clinical course are lacking. Our patient had an uneventful clinical course for two years and then developed symptoms.

Although it is difficult to determine the cause of inflam-

matory changes in pericardial cysts and hemorrhaging in the cyst, multiple factors may be involved. For example, it may be possible that concomitant pericarditis, such as post-myocardial infarction pericarditis or latent viral infectious pericarditis, or secondary infection after aspiration affected these conditions. Given that the patient has been receiving medical treatment for rheumatoid arthritis for several decades, collagenous pericarditis might have been present. Although low pericardial fluid sugar was detected by aspiration, other diagnostic findings of collagenous pericarditis (e.g., the pericardial fluid complement level and pericardial fluid rheumatoid factor) were not investigated. Therefore, whether or not collagenous pericarditis coexisted in this case cannot be confirmed. Furthermore, the combination of anti-platelet and anticoagulant therapies can promote hemorrhaging in the cyst. However, leukocytoclastic vasculitis diagnosed by a leg skin biopsy is unlikely to be associated with inflammatory changes in the pericardial cyst, as this skin-related inflammation is usually limited to a local manifestation (15).

This case report underscores the notion that an inflammatory pericardial cyst can cause hemorrhaging in the cyst and constrictive pericarditis, but only rare cases with hemodynamically significant complications require surgical treatment. In addition, it is crucial to understand the relationship between the pericardial cyst and comorbid conditions.

**The authors state that they have no Conflict of Interest (COI).**

## References

1. Patel J, Park C, Michaels J. Pericardial cyst: case reports and a literature review. *Echocardiography* **21**: 269-272, 2004.
2. Al-Mallah MH, Almasoudi F, Ebid M, et al. Multimodality imaging of pericardial diseases. *Curr Treat Options Cardiovasc Med* **19**: 89, 2017.
3. Jeung MY, Gasser B, Gangi A, et al. Imaging of cystic masses of the mediastinum. *Radiographics* **22**: S79-93, 2002.
4. Adler Y, Charron P, Imazio M, et al. 2015 ESC Guidelines for the diagnosis and management of pericardial diseases: The Task Force for the Diagnosis and Management of Pericardial Diseases of the European Society of Cardiology (ESC). *Eur Heart J* **36**: 2921-2964, 2015.
5. Najib MQ, Chaliki HP, Raizada A, et al. Symptomatic pericardial cyst: a case series. *Eur J Echocardiogr* **12**: E43, 2011.
6. Braude PD, Falk G, McCaughan BC, et al. Giant pericardial cyst. *Aust N Z J Surg* **60**: 640-641, 1990.
7. Yip MF, Walsh BM. Hemorrhagic pericardial cyst diagnosis accelerated by emergency physician echocardiography: a case report. *J Emerg Med* **52**: e105-e109, 2017.
8. Temizkan V, Onan B, Inan K, et al. Hemorrhage into a pericardial cyst and associated right ventricular compression after blunt chest trauma. *Ann Thorac Surg* **89**: 1292-1295, 2010.
9. Tanoue Y, Fujita S, Kanaya Y, et al. Acute cardiac tamponade due to a bleeding pericardial cyst in a 3-year-old child. *Ann Thorac Surg* **84**: 282-284, 2007.
10. Shiraishi I, Yamagishi M, Kawakita A, et al. Acute cardiac tamponade caused by massive hemorrhage from pericardial cyst. *Circulation* **101**: E196-197, 2000.
11. Borges AC, Gellert K, Dietel M, et al. Acute right-sided heart failure due to hemorrhage into a pericardial cyst. *Ann Thorac Surg* **63**: 845-847, 1997.
12. Syed FF, Schaff HV, Oh JK. Constrictive pericarditis--a curable diastolic heart failure. *Nat Rev Cardiol* **11**: 530-544, 2014.
13. Simsek H, Gunes Y, Akil MA, et al. Asymptomatic giant pericardial cyst mimicking dextrocardia on chest X-ray. *Herz* **39**: 1013-1015, 2014.
14. Lin AN, Lin S, Lin K, et al. Pericardial incidentaloma: benign pericardial cyst. *BMJ Case Rep* 2017.
15. Sais G, Vidaller A, Jucglà A, et al. Prognostic factors in leukocytoclastic vasculitis: a clinicopathologic study of 160 patients. *Arch Dermatol* **134**: 309-315, 1998.

The Internal Medicine is an Open Access journal distributed under the Creative Commons Attribution-NonCommercial-NoDerivatives 4.0 International License. To view the details of this license, please visit (<https://creativecommons.org/licenses/by-nc-nd/4.0/>).