

# SpeedBridge Knotless Double-Pulley Rotator Cuff Repair



Alex Lencioni, M.D., Hannah Bradsell, B.S., Kevin Shinsako, M.S., P.A.-C., and Rachel M. Frank, M.D.

**Abstract:** Rotator cuff tears remain a common injury, and may require rotator cuff repair, one of the most frequently performed orthopaedic procedures. Achieving an ideal construct during rotator cuff repair is crucial, and while many techniques exist to accomplish this, they are continuously evolving to improve stability and biomechanics of the repaired shoulder. Improving efficiency of the procedure alongside the increasing complexity of innovative techniques remains of the utmost importance. The double-pulley SpeedBridge technique achieves medial fixation in a double-row, transosseus-equivalent repair, and the knotless nature of the technique creates for a low-profile construct and improves overall efficiency. The purpose of this Technical Note is to describe a reproducible and efficient approach to arthroscopic rotator cuff repair using the SpeedBridge knotless double-pulley technique.

## Introduction

Rotator cuff tears are among the most common musculoskeletal injuries and remain a growing cause of shoulder disability worldwide. Because of the trend of an aging population, a proportional increase in prevalence of rotator cuff tears has been observed in recent years in correlation with age being a reported risk factor.<sup>1</sup> Given the volume of rotator cuff tears, rotator cuff repair remains one of the most common orthopaedic surgical procedures performed worldwide.<sup>2</sup> Following the rise in rotator cuff tears, there has also been a consistent linear increase in rotator cuff repair procedures since 2012, most frequently performed arthroscopically, with projections until 2070 showing a

continuous increase in their prevalence.<sup>2,3</sup> This growing frequency and demand for rotator cuff repair procedures call for evolving innovative techniques to reduce surgical time while maintaining and improving clinical outcomes.

The ideal rotator cuff repair has a high initial fixation strength, allows for minimal gap formation, maintains mechanical stability, and optimizes the biology of the tendon-bone healing zone to facilitate restoring normal anatomy and function as the rotator cuff heals.<sup>4,5</sup> The knotless double-pulley construct using the SpeedBridge (Arthrex Inc., Naples, FL) system achieves appropriate medial fixation in a double-row, transosseus-equivalent repair by creating high footprint compression and a durable repair as a result. The knotless aspect of this repair additionally reduces procedure time and removes the risk of knot impingement. The purpose of this Technical Note is to describe the use of the SpeedBridge system with the knotless double-pulley technique to perform a rotator cuff repair.

## Surgical Technique

A demonstration of arthroscopic rotator cuff repair using the knotless double-pulley SpeedBridge technique is presented in [Video 1](#).

## Patient Positioning and Anesthesia

The patient is brought back to the operating room and is transferred to the operating table. General and regional anesthesia are then induced. The patient is then transferred to the operative table. Prior to elevating the head

University of Colorado School of Medicine, Aurora, Colorado, U.S.A.

The authors report the following potential conflicts of interest or sources of funding: R.M.F. reports being a board or committee member of AAOS, American Orthopaedic Society for Sports Medicine, Arthroscopy Association of North America, International Cartilage Repair Society, and Orthopedics Today; she reports being a consultant, paid speaker, or presenter for Arthrex and has received royalties and financial or material support from Elsevier. Full ICMJE author disclosure forms are available for this article online, as [supplementary material](#).

Received September 23, 2021; accepted December 21, 2021.

Address correspondence to Rachel M. Frank, M.D., University of Colorado School of Medicine, 12631 E. 17th Ave, Mail Stop B202, Aurora, CO 80045, U.S.A. E-mail: [rachel.frank@cuanschutz.edu](mailto:rachel.frank@cuanschutz.edu)

© 2022 THE AUTHORS. Published by Elsevier Inc. on behalf of the Arthroscopy Association of North America. This is an open access article under the CC BY-NC-ND license (<http://creativecommons.org/licenses/by-nc-nd/4.0/>). 2212-6287/211366

<https://doi.org/10.1016/j.eats.2021.12.039>

**Table 1.** Keys to Beach Chair Positioning

Step	Notes
Position the patient properly in supine position.	Position the patient to ensure the buttocks will be pressed against the back of the bed.
Raise the back of the chair to 60°.	
Shift the patient so the medial scapula is on the edge of the bed.	Several folded surgical towels can be placed medially to the scapula to improve position.
Confirm the buttocks' position against the back of the bed.	There should be no gap between the patient and the bed.
Place a large pad or several pillows underneath the patient's legs.	
Secure the nonoperative arm to the patient's abdomen or on an arm board.	
Secure the head and airway accessibility.	A variety of methods can be used, but the maintenance of a neutral position is vital.
Position the arm in the proper position using an arm-positioner.	Be aware when applying traction to avoid neurologic damage.
Secure the patient's position with a safety-belt and tape.	
Rotate the bed 60° to 90°.	Be sure to provide the surgical team the appropriate amount of space.

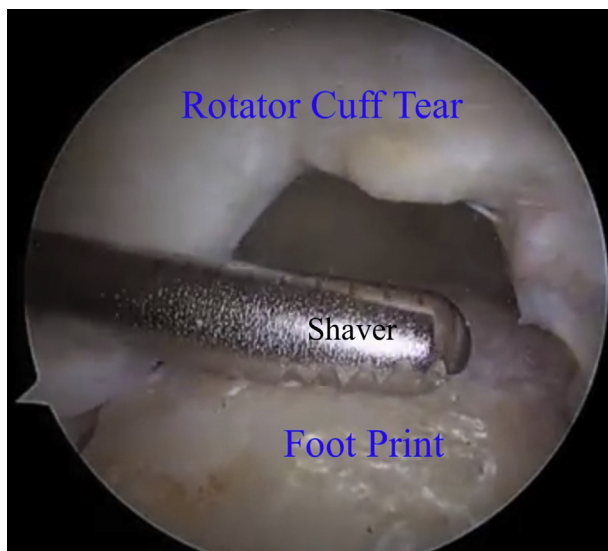[This table was published in *Arthroscopy Techniques*, Volume 6, J. D. Higgins, R. M. Frank, J. T. Hamamoto, M. T. Provencher, A. A. Romeo, and N. N. Verma, *Shoulder Arthroscopy in the Beach Chair Position*, pp. 1153-1158, Copyright Arthroscopy Association of North America (2017).]

and chest into the beach chair position, it is imperative to ensure the patient is positioned correctly onto the operating table to avoid complications related to patient position (Table 1).<sup>6</sup>

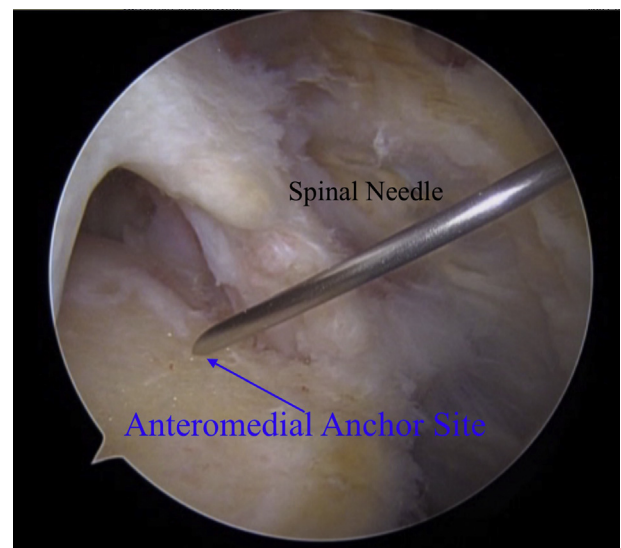
### Portal Placement

After marking out the acromion, scapular spine, clavicle, and AC joint, we start each case with a standard posterior viewing portal. We mark this portal by placing, if a left shoulder, our thumb in the sulcus between the glenoid and humeral head, index finger at Neviaser's portal, and small finger over the coracoid,

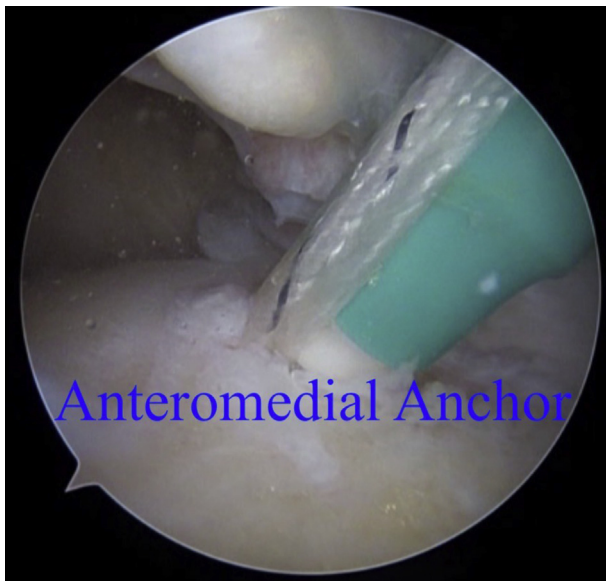
and then perform a shrug test to ensure we are in the correct position for the posterior portal. Generally, this portal is 2 cm inferior and 1-2 cm medial to the posterior lateral aspect of the acromion. Once we have established intra-articular position with the camera, we make the anterior portal under direct visualization, in the center of the rotator interval between the biceps tendon and subscapularis. After the diagnostic evaluation of the glenohumeral joint and articular side of the rotator cuff, we then enter the subacromial space. Our next portal established is our lateral portal, which is generally made along the "50 yard line" off the lateral



**Fig 1.** Viewing from our lateral portal and inserting the rotary shaver or burr from our posterior portal, the rotator cuff footprint is prepared for medial row anchor placement. The articular border and location for medial row anchor placement is also identified, which are placed at typical location for appropriate reduction of rotator cuff tendon.



**Fig 2.** Viewing from our posterior portal. An 18-gauge spinal needle is inserted through our established lateral portal or in a percutaneous approach and is used to identify the desired trajectory for posteromedial and anteromedial anchor placement.

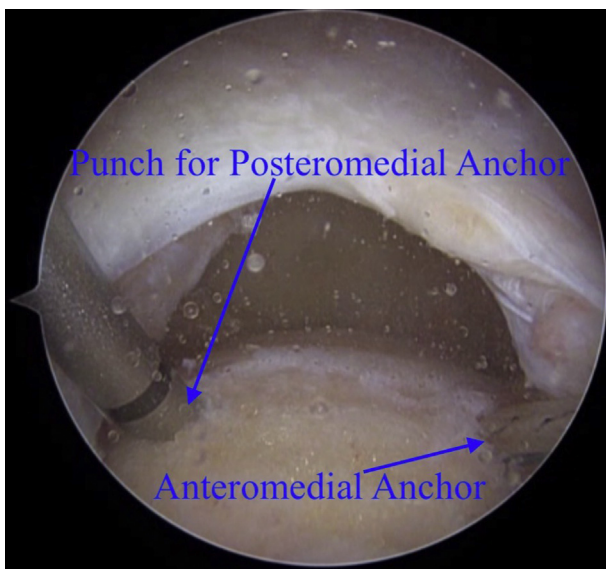


**Fig 3.** Viewing from our posterior portal. An anteromedial row anchor is placed at the typical location for appropriate reduction of rotator cuff tendon.

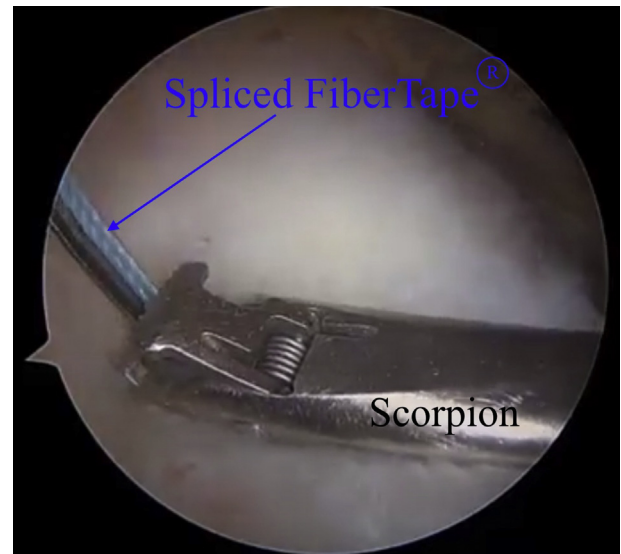
border of the acromion. These are the three main portals used for our SpeedBridge rotator cuff tear with additional portals made as necessary to assess and repair the rotator cuff tear. Posterolateral and antero-lateral portals are also made pending the location of the rotator cuff tear.

### Surgical Technique

The knotless double-pulley SpeedBridge technique is an innovative technique that allows for a low-profile,




**Fig 4.** Viewing from the lateral portal. The knotless anchor is placed at the posteromedial row through the percutaneous portal. The anteromedial row anchor can also be seen.



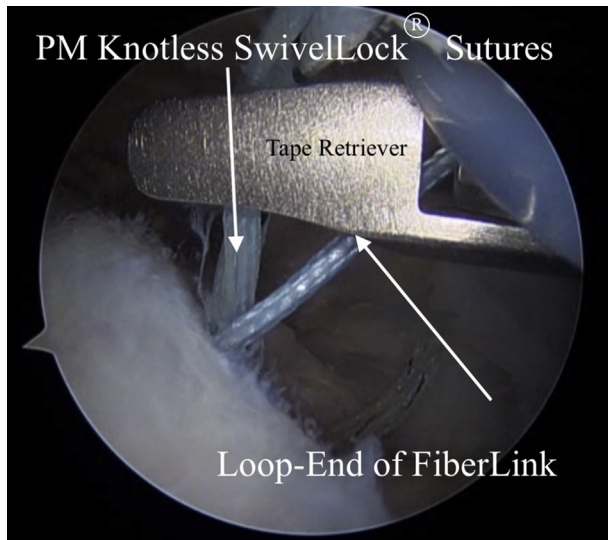
**Fig 5.** Viewing from the posterior portal. The posteromedial preloaded spliced tape is retrieved from the posteromedial knotless anchor and passed through the rotator cuff in appropriate location for standard repair.

robust biomechanical construct at the underside of the rotator cuff repair. The basic construct of the double-loaded knotless SwiveLock (Arthrex Inc., Naples, FL) allows for the repair stitch to be shuttled through the anchor using the shuttle suture. The shuttle suture has two portions: the loop portion and the tape portion. The tape portion is used as a pull end and the loop portion as the loading end.

During rotator cuff repair using this technique, the footprint of rotator cuff is prepared in standard fashion



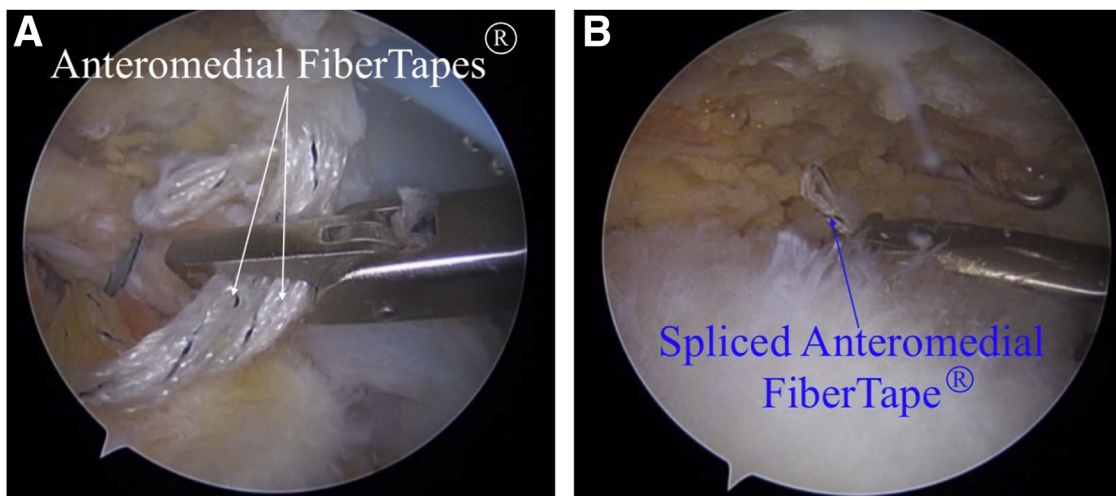
**Fig 6.** Viewing from our posterior portal. Having passed with a self-retrieving suture passer preloaded with a FiberLink suture adjacent to the more posterior FiberTape sutures, the tail end of the FiberLink suture is retrieved from an accessory superior portal.



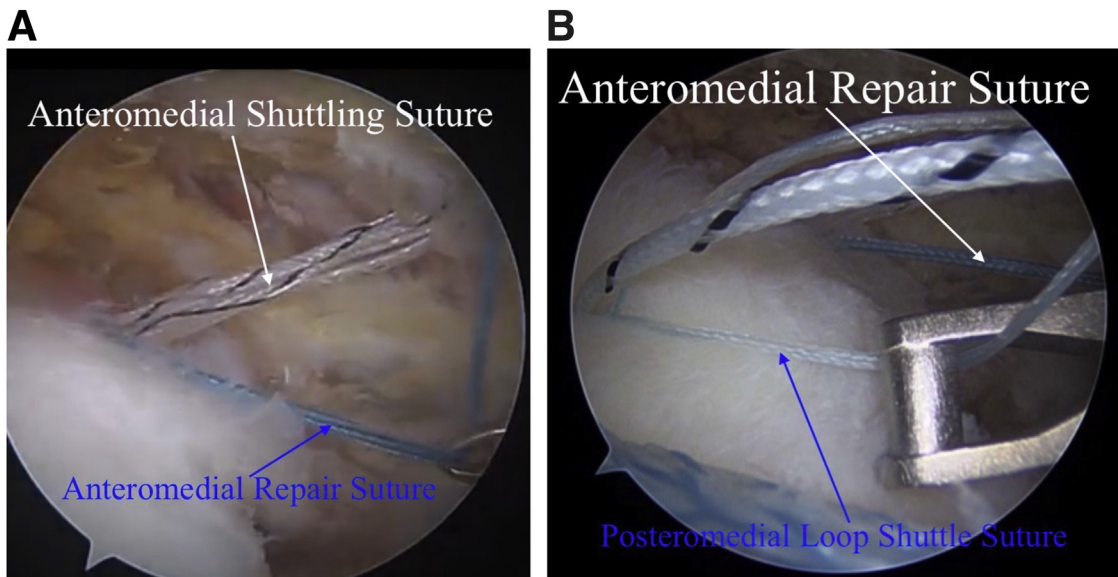
**Fig 7.** Viewing from our posterior portal. From the lateral portal, the knotless SwiveLock sutures are retrieved and loaded into the FiberLink loop. Then, the tail end of the FiberLink that was previously retrieved through the superior portal is pulled to shuttle the sutures from the knotless SwiveLock through the rotator cuff.

using a rotary shaver or burr (Fig 1), and the articular border and location for medial row anchor placement is identified. To avoid suture bridges, the authors place a cannula (PassPort; Arthrex Inc., Naples, FL) in the lateral portal. To complete the medial row repair, medial row anchors are placed at typical locations for appropriate reduction of rotator cuff tendon. First, an 18-gauge spinal needle is used to identify the desired trajectory for the anteromedial anchor placement

(Fig 2), and an anteromedial row anchor is then placed at the appropriate location for proper rotator cuff tendon reduction (Fig 3). In a similar fashion, an 18-gauge spinal needle is used to identify the desired trajectory for the posteromedial anchor placement. Next, the 4.75 mm knotless SwiveLock suture anchor is placed at the posteromedial row through the percutaneous portal (Fig 4). Then, the tape from this anchor is retrieved through the lateral portal, and passed through the rotator cuff using a self-retrieving suture passer (Scorpion; Arthrex Inc., Naples, FL) in appropriate location for standard repair (Fig 5). The tape is then retrieved from an accessory portal to remove from the working portal. Using a self-retrieving suture passer, a FiberLink (Arthrex Inc., Naples, FL) suture is loaded on the self-retrieving suture passer, and the tail of the FiberLink is passed adjacent to the more posterior FiberTapes (Arthrex Inc., Naples, FL). The tail end of the FiberLink suture is retrieved from the accessory superior portal (Fig 6). From the lateral portal, the knotless SwiveLock sutures are retrieved and loaded into the FiberLink loop (Fig 7). Then, the tail end of the FiberLink that was previously retrieved through the superior portal is pulled to shuttle the sutures from the knotless anchor through the rotator cuff. The preloaded, spliced tape is retrieved from the anteromedial knotless anchor through the lateral portal and passed through the rotator cuff in the surgeons' desired fashion (Fig 8). This process is repeated with the anteromedial anchor. At this phase of the repair, all sutures should be passed through the rotator cuff. Next, the anteromedial anchor repair suture, colored blue, is retrieved while the posteromedial anchor loop portion of the shuttle suture is



**Fig 8.** (A) Viewing from the posterior portal. The preloaded, spliced tape is retrieved from the anteromedial anchor through the lateral portal. (B) The tape is passed through the rotator cuff in desired fashion. Following this step, in similar fashion as the posteromedial anchor, a FiberLink suture is loaded on the self-retrieving suture passer, the tail of the FiberLink is then passed and retrieved from the accessory superior portal. From the lateral portal, the knotless SwiveLock sutures are retrieved and loaded into the FiberLink loop.

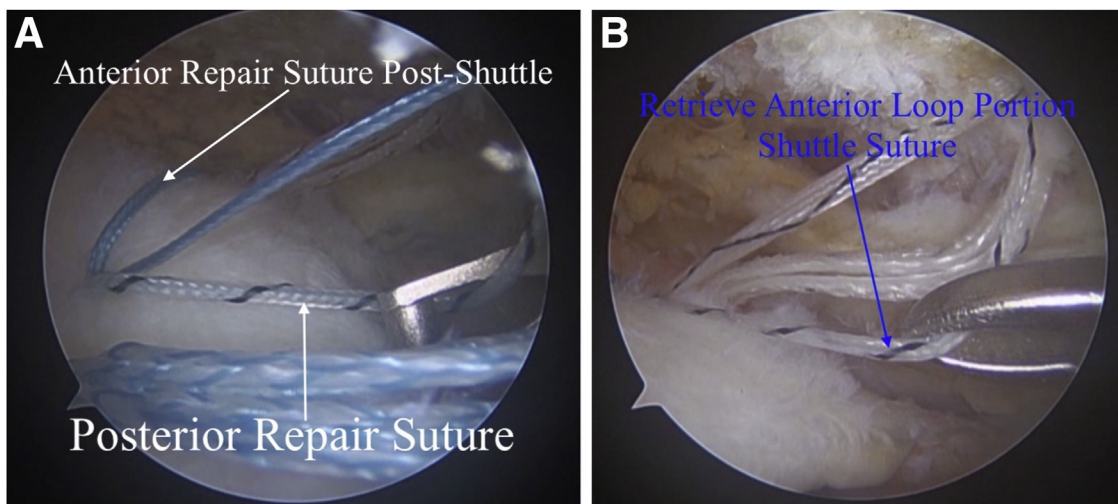


**Fig 9.** (A) Viewing from the posterior portal. The anterior anchor blue repair suture is retrieved. (B) Simultaneously, the posterior anchor loop portion of the shuttle suture is obtained through lateral portal. Outside the shoulder, the blue repair stitch is loaded through the loop portion of the shuttle suture, folding the blue repair stitch at the ink-mark indicator. The tail end of the posterior anchor passing suture is then pulled to load the knotless mechanism.

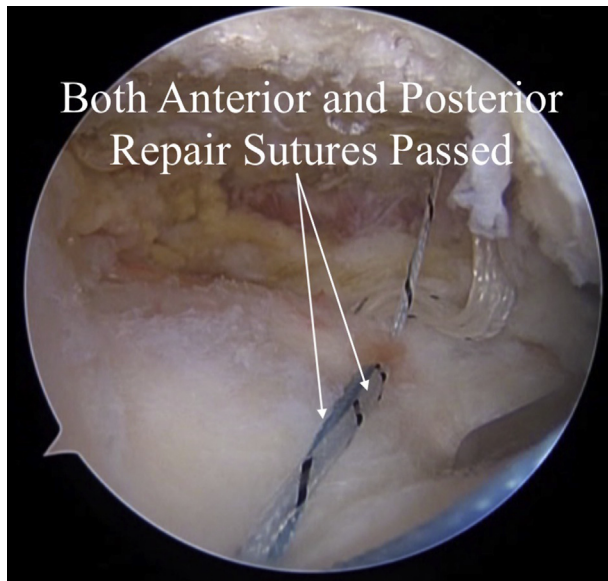
simultaneously obtained through the lateral portal (Fig 9). Outside the shoulder, the blue repair stitch is loaded through the loop portion of the shuttle suture, folding the blue repair stitch at the ink-mark indicator. The tail end of the posteromedial anchor passing suture is then pulled to load the knotless mechanism. In similar fashion, the posteromedial anchor repair suture, colored black and white, is retrieved while the anteromedial anchor loop portion of the shuttle suture is simultaneously obtained through the lateral portal (Fig 10). Outside the shoulder, the black and white repair stitch is loaded through the loop portion of shuttle

suture. The tail end of the anteromedial anchor passing suture is pulled to load the anteromedial anchor knotless mechanism. Finally, the two repair sutures are tensioned to the desired amount (Fig 11).

The lateral row repair is completed in standard fashion of a double-row technique by retrieving the FiberTape suture from each medial row anchor, loading each lateral row anchor, and tensioning each limb independently to remove any slack of tendon. The anterolateral anchor is placed and the tails of the FiberTape of the anterolateral anchor are cut. These steps are repeated for the posterolateral anchor. The



**Fig 10.** (A) Viewing from the posterior portal. The posterior anchor repair suture, colored black and white, is retrieved. (B) Simultaneously, the loop portion of the anterior anchor shuttle suture is obtained through the lateral portal. Outside the shoulder, the black and white repair stitch is loaded through the loop portion of shuttle



**Fig 11.** Viewing from the lateral portal. Once the tail end of the anterior anchor passing suture is pulled to load the anterior anchor knotless mechanism, the two repair sutures are tensioned to the desired amount.

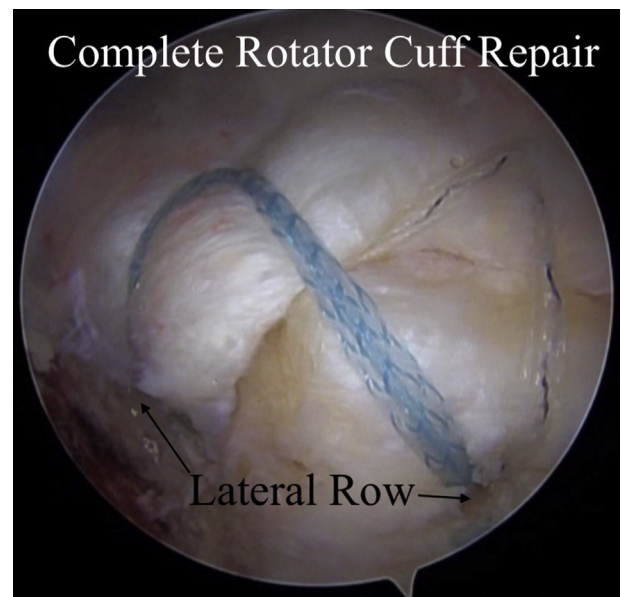
FiberTapes are passed through the islet of the posterolateral anchor, the anchor is docked, and the FiberTapes are cut flush. Once the lateral row has been placed, the knotless suture anchors are further tensioned to the desired tension and cut flush (Fig 12).

### Discussion

Several arthroscopic techniques are currently used to repair full-thickness rotator cuff tears, including a variety of single- and double-row constructs. The SpeedBridge knotless double-pulley construct is an alternative to other double-row repair techniques. A recent study by Noyes and Denard<sup>7</sup> prospectively observed the functional outcomes and healing rates of full-thickness supraspinatus tendon tears repaired using suture tape and a medial double-pulley technique. Overall, 88% (21 of 24) of patients included in the study were satisfied with their outcomes, 88% of the treated rotator cuff tears were healed at a minimum of 6 months post-operatively, and functional outcomes showed a statistically significant improvement over the course of the study. The authors determined that this technique is an efficient way to obtain medial fixation and achieves clinically acceptable results.<sup>7</sup> A separate study by Moon et al.<sup>8</sup> in 2018 compared a single-row technique to the SpeedBridge technique. The group that underwent repair using the SpeedBridge technique experienced significantly less medium and large retears compared to the group that underwent repair using the single-row technique. It was suggested by the authors that this could have been due to the suture configurations on the rotator cuff footprint generating less local tendon

vascular damage with the SpeedBridge method, which may contribute to improved tendon continuity. Further, the SpeedBridge technique preserved medial-row tendon vascularity when compared to the single-row technique, which is associated with tendon strangulation due to medial row knot tying. The knotless nature of the SpeedBridge technique decreases the risk of medial row tendon strangulation and maintains tendon vascularity.<sup>8</sup> It should be noted, however, that the SpeedBridge technique performed in this study was without medial-row tying, which is an alternative to the double-pulley technique that includes a broad double-mattress suture medially. An early clinical study by Vaishnav and Millet<sup>5</sup> also supports these findings, concluding that a knotless self-reinforcing double-row repair system is a viable option for treating rotator cuff repairs, as it provides enhanced contact area and restores the native footprint of the tendon, resulting in improved outcomes.

Rotator cuff repair techniques are continuously evolving as more becomes understood about the biology involved in the healing process and the value of efficiency in the operating room. In a prospective randomized controlled trial, Sahin et al.<sup>9</sup> found that the standard knot-tying and the knotless technique during suture-bridge rotator cuff repair both resulted in significant improvement of clinical outcomes at mid-term



**Fig 12.** Viewing from the lateral portal. The lateral row repair is completed in standard fashion of a double-row technique by retrieving the FiberTape suture from each medial row anchor and loading each lateral row anchor. Each limb is independently tensioned to remove any slack of tendon. Once the lateral row has been placed, the knotless suture anchors are further tensioned to the desired tension and cut flush. The completed knotless double-pulley rotator cuff repair can be seen here.

**Table 2.** Advantages and Disadvantages

Advantages	Disadvantages
Technique improves the stability and strength of the construct at the underside of the rotator cuff repair.	FiberTape does not slide as well as suture in the islet of the anchor.
FiberTape knot slides more easily through the cannula and without worry of entanglement compared to suture.	
FiberTape is biomechanically stronger than suture.	

follow-up, including comparable postoperative range of motion, pain, and functional outcomes. Both techniques also had similar retear rates; however, retear pattern differed significantly, with the knot-tying technique resulting in significantly greater type 2 (medial) retears, while the knotless technique was associated with greater type 1 (lateral) retears. Of note, revision repair of type 2 failures are considered more challenging than type 1 revision repairs. This is due to the diminished amount of tendon stock available. The associated lower risk of type 2 repair failures with using knotless techniques has been thought to be advantageous.<sup>9</sup> A recent meta-analysis similarly found no difference in clinical outcomes between knot-tying and knotless double-row arthroscopic RCR, as well as comparable retear rates between techniques. One study included in the analysis found a significantly lower retear rate in the knotless group.<sup>10</sup> In addition to finding no differences in outcomes, the authors noted the following advantages of a knotless technique: less technically demanding, reduced operative time and cost to patient, and easier suture limb management.<sup>10</sup> In a biomechanical study, knotless construct with suture tape resulted in the greatest mean load to failure at 3 mm of displacement, and increased stiffness compared to both knotted and knotless constructs with no. 2 sutures.<sup>11</sup> Further, knotless fixation overall demonstrated less variability in biomechanical properties, specifically load to failure, compared to knotted fixation.<sup>11</sup> Therefore, the knotless nature of the SpeedBridge system produces a reproducible, sturdy repair and satisfactory fixation of rotator cuff repairs, while also saving procedural time compared to knot-tying repairs. A more recent study by Millet et al.<sup>12</sup> reported no difference in final functional outcomes at a minimum of 2 years follow-up between knotted suture bridging and knotless tape bridging transosseous-equivalent techniques. The authors also found that patients with the knotless tape bridging repair were less likely to have a

full-thickness rotator cuff retear.<sup>12</sup> Similarly, Pogorzelski et al.<sup>13</sup> found equivalent clinical results between these techniques, reporting significant improvements in patient-reported outcomes and extremely high survivorship at 5 years of follow-up in both primary and revision cases using both techniques.

The double-pulley repair method was developed to increase the contact area between the tendon and bone at the medial row of the repair, ultimately providing a wide area of tissue compression and equal pressure distribution between the suture strands overlying the tendon.<sup>14</sup> Combining a knotless double-pulley technique with the viable method of the knotless double-row, transosseous-equivalent repair achieves maximum footprint compression and improves the stability of the construct. A summary of the advantages and disadvantages of this technique can be found in Table 2, and a summary of pearls can be found in Table 3. Overall, the SpeedBridge knotless double-pulley rotator cuff repair construct is a cost-effective technique that saves procedural time and optimizes efficiency and convenience in the operating room, while maintaining clinically significant patient-reported and functional outcomes and rotator cuff repair survivorship.

## References

1. Wani Z, Abdulla M, Habeebullah A, Kalogriantis S. Rotator cuff tears: Review of epidemiology, clinical assessment and operative treatment. *Trauma* 2016;18:190-204.
2. McElvany MD, McGoldrick E, Gee AO, Neradilek MB, Matsen FA. Rotator cuff repair. *Am J Sports Med* 2015;43:491-500.
3. Villatte G, Erivan R, Barth J, Bonneville N, Descamps S, Boisgard S. Progression and projection for shoulder surgery in France, 2012-2070: Epidemiologic study with trend and projection analysis. *Orthop Traumatol Surg Res* 2020;106:1067-1077.
4. Cole BJ, Elattrache NS, Anbari A. Arthroscopic rotator cuff repairs: An anatomic and biomechanical rationale for different suture-anchor repair configurations. *Arthroscopy* 2007;23:662-669.
5. Vaishnav S, Millett PJ. Arthroscopic rotator cuff repair: Scientific rationale, surgical technique, and early clinical and functional results of a knotless self-reinforcing double-row rotator cuff repair system. *J Shoulder Elbow Surg* 2010;19:83-90.

**Table 3.** Pearls

Pearls
Cannula prevents suture entanglement.
Use of an 18-gauge spinal needle to identify anchor trajectory enables more accurate placement of desired position for anchor placement.

6. Higgins JD, Frank RM, Hamamoto JT, Provencher MT, Romeo AA, Verma NN. Shoulder arthroscopy in the beach chair position. *Arthrosc Tech* 2017;6:e1153-e1158.
7. Noyes MP, Denard PJ. Outcomes following double-row and medial double-pulley rotator cuff repair. *Orthopedics* 2020;1-6.
8. Moon N, Lee SJ, Kwak SH, Lee E, Jeong HS, Suh KT. Clinical and radiologic outcomes after arthroscopic rotator cuff repair: Single-row versus Speed-Bridge technique. *Acta Orthop Belg* 2018;84:516-525.
9. Şahin K, Şentürk F, Ersin M, Arzu U, Chodza M, Erşen A. Repair integrity and functional outcomes between knot-tying and knotless suture-bridge arthroscopic rotator cuff repair: A prospective randomized clinical trial. *Orthop J Sports Med* 2021;9:232596712110024.
10. Paramasivam Meenakshi Sundaram P, Lee WWB, Sayampanathan AA, Tan HCA. Comparison of clinical outcomes between knotted and knotless double-row arthroscopic rotator cuff repairs: A meta-analysis. *JSES Int* 2021;5:254-260.
11. Denard PJ, Adams CR, Fischer NC, Piepenbrink M, Wijdicks CA. Knotless fixation is stronger and less variable than knotted constructs in securing a suture loop. *Orthop J Sports Med* 2018;6:232596711877400.
12. Millett PJ, Espinoza C, Horan MP, et al. Predictors of outcomes after arthroscopic transosseous equivalent rotator cuff repair in 155 cases: A propensity score weighted analysis of knotted and knotless self-reinforcing repair techniques at a minimum of 2 years. *Arch Orthop Trauma Surg* 2017;137:1399-1408.
13. Pogorzelski J, Fritz EM, Horan MP, et al. Minimum five-year outcomes and clinical survivorship for arthroscopic transosseous-equivalent double-row rotator cuff repair. *J Am Acad Orthop Surg* 2019;27:e1093-e1101.
14. Parnes N, Carey P, Ciani M, Morman M. The combined "double-pulley" simple knot technique for arthroscopic transtendon fixation of partial articular-sided tear of the subscapularis tendon. *Arthrosc Tech* 2016;5:e177-e183.