

# Direct hepatic vein puncture and transseptal access for atrial flutter and fibrillation ablation in a patient with prior ligation of the inferior vena cava



Prakash Goutham Suryanarayana, MD,\* Michael Ayers, MD,<sup>†</sup> Scott O. Trerotola, MD,<sup>‡</sup> Saman Nazarian, MD, PhD, FHRS\*

From the \*Cardiac Electrophysiology, Department of Medicine, Hospital of the University of Pennsylvania, Philadelphia, Pennsylvania, <sup>†</sup>Cardiovascular Medicine, Department of Medicine, Hospital of the University of Pennsylvania, Philadelphia, Pennsylvania, and <sup>‡</sup>Interventional Radiology, Department of Radiology, Hospital of the University of Pennsylvania, Philadelphia, Pennsylvania.

## Introduction

The inferior vena cava (IVC) is commonly used in procedures involving left heart instrumentation, whereby catheters are introduced through the right or left femoral vein and advanced through the IVC towards the interatrial septum.<sup>1,2</sup> Transseptal puncture then facilitates access into the left atrium for catheter ablation or other interventional procedures. When the IVC is not available, such as in cases with congenital abnormalities or surgical ligation of the IVC,<sup>3–5</sup> an alternate route is required to access the left atrium. Superior access techniques through the right internal jugular vein or right subclavian vein have been described using a stiff angulated sheath or a steerable sheath to navigate down the superior vena cava towards the interatrial septum for transseptal access into the left atrium.<sup>2,6</sup> Remote magnetic catheter navigation can also be used to perform pulmonary vein isolation by a retrograde aortic approach.<sup>7</sup> Alternatively, the hepatic vein has been used to bypass the IVC by providing a shorter and more direct path compared to both superior and femoral venous or retrograde aortic access. A needle is typically introduced into the liver under fluoroscopic guidance with anteroposterior and lateral projections in the mid to anterior axillary line below

the costal margin<sup>8</sup> to avoid inadvertent aortic root puncture.<sup>5</sup> The hepatic vein provides an inferior access route that is similar to femoral vein access, and is of sufficient size to accommodate large sheaths usually required for ablation procedures. However, since the transhepatic route carries the catheter posteriorly towards the coronary sinus, this technique requires a high-torque sheath with tight curves that can withstand catheter manipulation to allow entry into the right atrium, and optimal positioning on the septum, ideally guided by intracardiac or transesophageal echocardiography.<sup>8</sup> Although this can be achieved using a fixed-curve sheath, it has been reported that a steerable sheath provides better catheter manipulation.<sup>5,9</sup>

Although hepatic vein access generally provides greater catheter stability and procedural familiarity than the superior approach, it is uncommonly utilized owing to technical limitations. The altered catheter trajectory may limit adequate force translation of the transseptal needle, potentially requiring additional force to puncture the interatrial septum using the current methodologies. In this article, we describe a novel transhepatic technique using (1) a sheath that allowed flexible steerability with the dilator in place and (2) radiofrequency (RF) transseptal wire enabling a patient with surgical ligation of the IVC to receive RF ablation treatment for symptomatic paroxysmal atrial fibrillation and typical atrial flutter.

**KEYWORDS** Atrial fibrillation; Interrupted IVC; Pulmonary vein isolation; Radiofrequency ablation; Transhepatic access; Transseptal puncture (Heart Rhythm Case Reports 2020;6:382–385)

Disclosures: Dr Nazarian is a consultant for CardioSolv and Circle Software, has given lectures for Circle Software, and serves as principal investigator for research funding from the US National Institutes of Health, Biosense Webster, ImriCor, and Siemens to the University of Pennsylvania. Dr Trerotola is a consultant for B Braun, BD Bard, MedComp, Teleflex, Adrenas, and Cook, and receives royalties from Teleflex. The University of Pennsylvania Conflict of Interest Committee manages all commercial arrangements. The other authors report no conflicts of interest. **Address reprint requests and correspondence:** Dr Saman Nazarian, Cardiac Electrophysiology, University of Pennsylvania, 3400 Spruce Street, Founders 9118, Philadelphia, PA 19104. E-mail address: [Saman.Nazarian@penmedicine.upenn.edu](mailto:Saman.Nazarian@penmedicine.upenn.edu).

## Case report

### Patient history

A 69-year-old man presented for evaluation of paroxysmal atrial fibrillation and typical atrial flutter. His history was also significant for hypertension, coronary artery disease status post percutaneous intervention on the left anterior descending artery, and, most importantly, acute lymphocytic leukemia at a young age complicated by venous thromboembolic disease, which required surgical ligation of the IVC in the late 1970s. Paroxysmal atrial fibrillation was diagnosed in 2015, when he presented with palpitations, fatigue, dyspnea,

### KEY TEACHING POINTS

- The hepatic vein provides an approach inferior to the heart that is familiar to operators in patients with inferior vena cava interruption.
- Interventional radiology should be leveraged to access the hepatic vein under ultrasound guidance.
- Use of an appropriate deflectable sheath and radiofrequency wire facilitate transseptal puncture for left atrial catheterization.

and exercise intolerance. Class III antiarrhythmic drug therapy was offered but he declined. In 2018, the patient experienced persistent typical atrial flutter and was referred for pulmonary vein isolation and catheter ablation of atrial flutter. Preprocedural computed tomography imaging (Figure 1) confirmed that IVC access was not available owing to ligation, and, as such, transhepatic access was planned, with informed consent.

### Superior access for diagnostic catheters

The right internal jugular vein was accessed percutaneously under general anesthesia. A steerable decapolar catheter (Dynamic Deca; Bard, Summit, NJ) was advanced toward the coronary sinus through a 7F sheath (Avanti; Cordis, Hialeah, FL) for mapping reference electrograms and left atrial pacing. An intracardiac echocardiography (ICE) catheter (AcuNav; Biosense Webster, Irvine, CA) was introduced into the right atrium through a 9F sheath (Avanti; Cordis) for a baseline ICE study to rule out pericardial effusion, to aid transseptal puncture, and for periprocedural monitoring. An esophageal temperature probe was placed to guide the ablation.

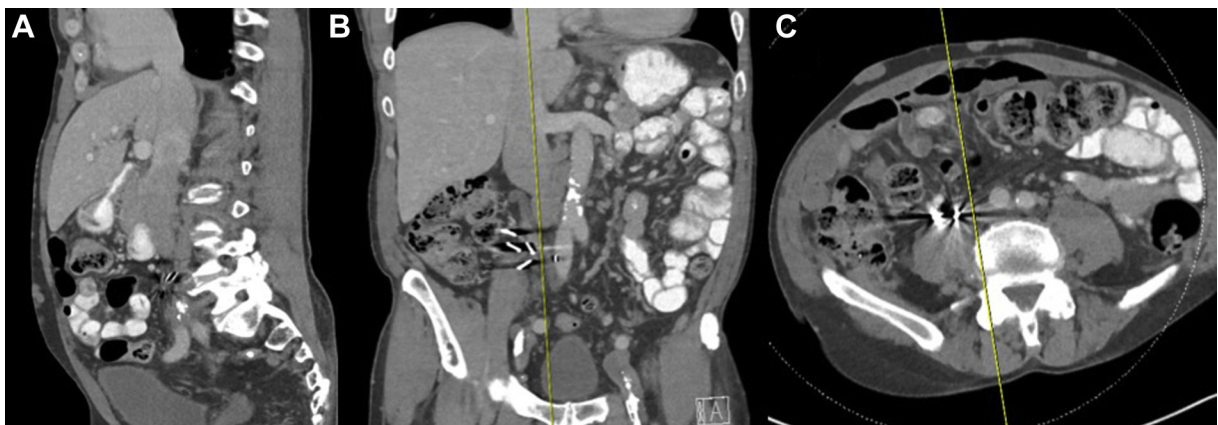### Transhepatic left atrial access

Under ultrasound guidance, percutaneous access to the middle hepatic vein was obtained using an 18 gauge trocar needle

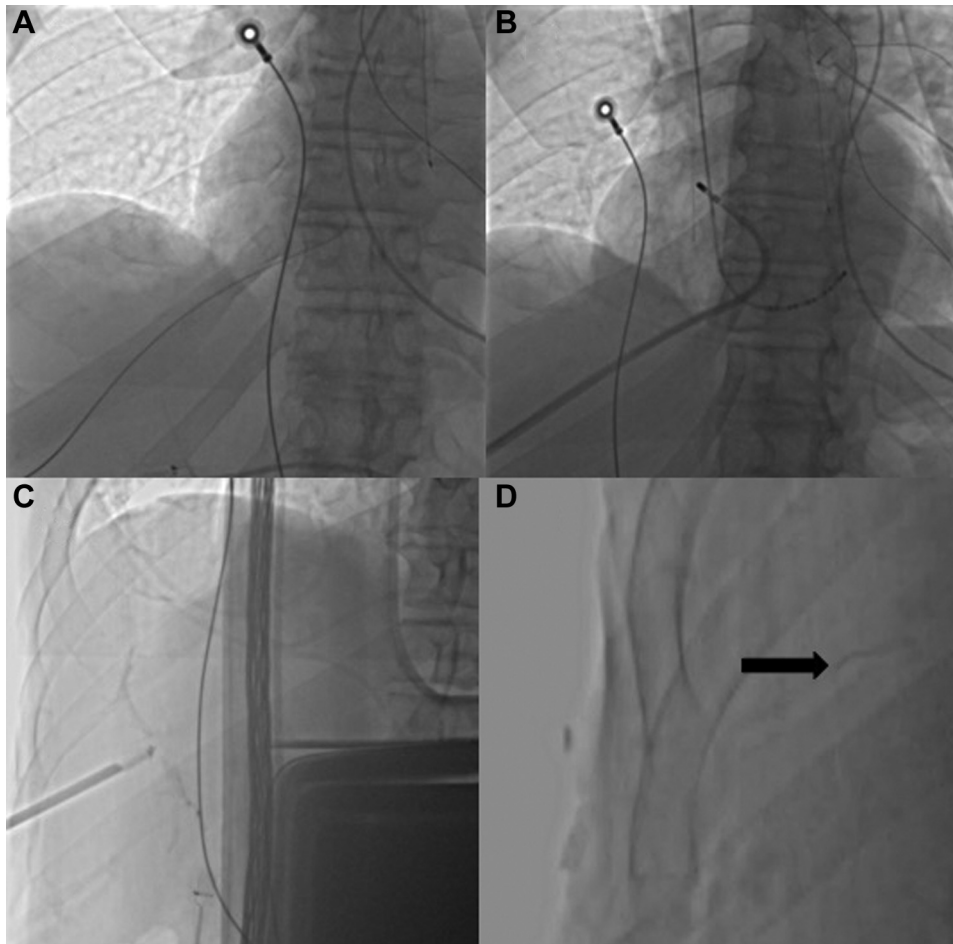
(Cook Medical, Bloomington, IN) below the right costal margin between the midclavicular and right anterior axillary line. Aspiration of venous blood was used along with injection of contrast to confirm entry into the vein. Once needle access into the middle hepatic vein was confirmed, a 0.035-inch J wire was introduced into the right atrium (Figure 2A), and a 12F short (13 cm, Check-Flo; Cook,) sheath was advanced into the hepatic vein to provide stability for an inner transeptal sheath. A short steerable sheath (12F Agilis EPI Steerable Introducer; Abbott, St. Paul, MN) was advanced through the outer sheath to access the right atrium. Owing to the posteroinferior oblique direction provided by transhepatic access, the stiff dilator of the Agilis sheath did not allow optimal positioning of the tip onto the fossa ovalis for transseptal puncture. Next, a steerable sheath with a flexible dilator (12F SupraCross Steerable Sheath; Baylis, Montreal, Canada) was advanced through the outer sheath into the right atrium. After brief manipulation, the sheath tip was positioned on the interatrial septum; ICE confirmed the RF transseptal wire (SupraCross RF Wire; Baylis Medical) engaging the fossa ovalis with slight tenting. Left atrial access was obtained upon the first application of RF energy (1-second constant). The SupraCross sheath was then advanced into the left atrium over the RF wire for subsequent mapping and ablation steps (Figure 2B, and Supplementary Video).

### Catheter ablation

A 3-dimensional electroanatomic map of the left atrium was created on the CARTO 3D system (Biosense Webster) using the PentaRay mapping catheter (Biosense Webster). An irrigated-tip ablation catheter (Thermocool SmartTouch SF Catheter; Biosense Webster) was used to circumferentially isolate the pulmonary veins as 2 common left- and right-sided ostia (Figure 3A and B). Pulmonary vein isolation was confirmed using exit and entrance blocks. The ablation catheter and sheath were then withdrawn into the right atrium to construct a right atrial map on CARTO. The catheter was positioned in the cavotricuspid isthmus region to perform atrial flutter line ablation starting at the tricuspid valve



**Figure 1** Computed tomography abdominal image in **A**: sagittal, **B**: coronal, and **C**: axial planes showing inferior vena cava ligation clips with chronic calcific thrombosis of the deep veins distal to the ligation and collateral venous channels.



**Figure 2** Serial fluoroscopic still frames during the procedure. **A:** Placement of the wire into the middle hepatic vein. **B:** Advancement of the SupraCross sheath (Baylis, Montreal, Canada) and ablation catheter into the right superior pulmonary vein following transseptal puncture. **C:** Withdrawal of the 12F short sheath with placement of the gelfoam plug in the tract between the liver capsule and vein entry site. **D:** The remaining gelfoam, which is faintly visible via fluoroscopy (*black arrow*).

annulus until signal was lost in the IVC and bidirectional block was confirmed (Figure 3C).

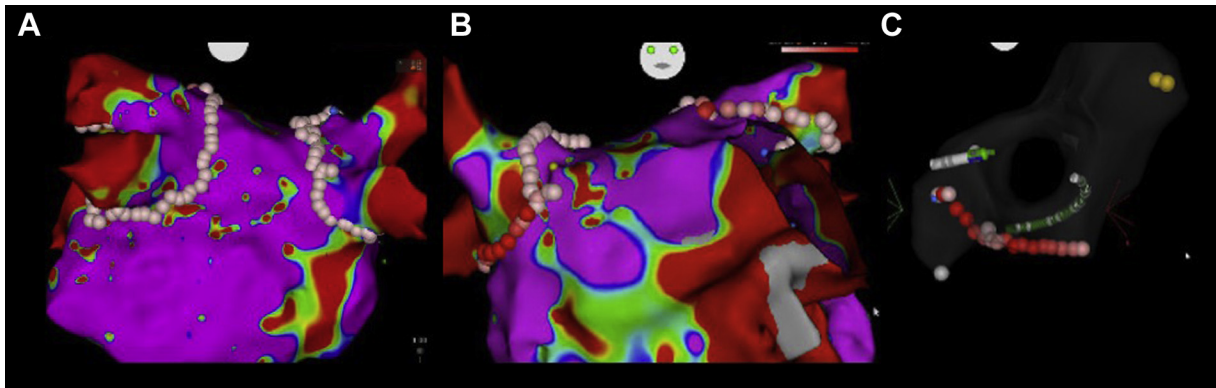
Following completion of the procedure, 20 mg thrombin was administered and after activated clotting time was less than 200 seconds, a gelfoam plug approximately 4 cm long was prepared by rolling and compressing a sheet of gelfoam and inserted into a section of 12F sheath as a loader. The loader was introduced through the indwelling 12F sheath and the plug pushed forward to the vein entry site using the 12F dilator from the sheath. The 12F short sheath was then withdrawn while stabilizing the plug with the dilator, depositing the plug in the tract between the liver capsule and vein entry site (Figure 2C and D). Manual pressure was applied to the internal jugular vein. The patient was confined to bed rest for 6 hours in the right lateral position and was observed overnight. Given that hemoglobin levels remained normal, a bleeding scan was not necessary and the patient was discharged from the hospital the following morning. Anticoagulation with Xarelto (20 mg orally, daily) was resumed 4 hours after the procedure. The patient underwent 30-day

monitoring at 1 month, including twice-daily pulse checks, which ruled out asymptomatic arrhythmia recurrence; has remained in sinus rhythm on successive 6-week-, 6-month-, and 12-month-visit electrocardiograms; and reported no recurrence of symptoms.

## Discussion

Alternative access methods are needed in patients with compromised access to the IVC, such as in this case with surgical ligation of the IVC and unavailability of superior access owing to existing mapping, pacing, and ICE catheters. Remote magnetic navigation, when available, provides a reasonable access route via a retrograde aortic approach; however, it lacks contact force sensing and is suboptimal in case of peripheral arterial, aortic, and valvular disease.<sup>7</sup> The hepatic vein provides a means for left atrial access using an approach inferior to the heart that is familiar to operators, enabling the use of all standard tools, while bypassing the IVC. In this case, support from interventional radiology





**Figure 3** **A:** Posteroanterior view and **B:** anteroposterior view of the left atrial electroanatomic map and pulmonary vein isolation radiofrequency ablation lesions. **C:** Cavotricuspid isthmus ablation lesion set for typical atrial flutter. The His signal position is visualized by yellow dots.

was critical for initial access of the hepatic vein. Although transhepatic access for left heart procedures has been described previously,<sup>5,8–12</sup> several technical challenges and a higher risk of complications may present using these reported methods, and may inhibit the adoption of this technique.

Firstly, depending on patient anatomy, a tight angle of curvature may be required in order to access the interatrial septum. A fixed-curve sheath, or even a steerable sheath with a stiff dilator, as was observed in this case, may prevent the ability to reach an optimal septal site for puncture. The use of a steerable sheath with flexible dilator provided a sufficient angle of curvature to allow positioning of the sheath tip onto the fossa ovalis. Secondly, the use of an RF transseptal system, which has been previously shown to reduce the risk of complications relative to puncture using a conventional mechanical needle,<sup>13</sup> facilitated safe transseptal puncture with minimal force and tissue tenting. From a standard femoral approach, the RF wire may also enhance workflow efficiency by allowing repositioning on the septum without rewiring.<sup>14</sup> Though RF transseptal puncture using non-femoral vein access has been described previously using the superior approach,<sup>15</sup> to our knowledge this is the first reported use of an RF puncture wire from a transhepatic approach.

## Conclusions

The use of a steerable sheath with flexible dilator provided the ability to easily position the sheath tip perpendicularly to the interatrial septum using the nontraditional transhepatic access route. The use of an RF wire facilitated transseptal puncture with minimal force and forward tissue tenting despite the more challenging angle of approach. Despite the difference in access site, left and right atrial mapping and RF ablation were performed as usual, with minimal additional challenges and no complications. The overall technique described in this report can be used to improve the feasibility, safety, and adoption of transhepatic access for left heart procedures, allowing more patients to become candidates for atrial fibrillation ablation.

## Appendix Supplementary data

Supplementary data associated with this article can be found in the online version at <https://doi.org/10.1016/j.hrcr.2020.03.011>.

## References

- Haegeli LM, Calkins H. Catheter ablation of atrial fibrillation: an update. *Eur Heart J* 2014;35:2454–2459.
- Lim HE, Pak HN, Tse HF, Lau CP, Hwang C, Kim YH. Catheter ablation of atrial fibrillation via superior approach in patients with interruption of the inferior vena cava. *Heart Rhythm* 2009;6:174–179.
- Johnson JL, Fellows KE, Murphy JD. Transhepatic central venous access for cardiac catheterization and radiologic intervention. *Cathet Cardiovasc Diagn* 1995; 35:168–171.
- Singh SM, Neuzil P, Skoka J, et al. Percutaneous transhepatic venous access for catheter ablation procedures in patients with interruption of the inferior vena cava. *Circ Arrhythm Electrophysiol* 2011;4:235–241.
- Nguyen DT, Gupta R, Kay J, et al. Percutaneous transhepatic access for catheter ablation of cardiac arrhythmias. *Europace* 2013;15:494–500.
- Rajappan K, Sporton SC, Schilling RJ. Left atrial tachycardia and inferior vena cava thrombotic occlusion complicating atrial fibrillation ablation successfully treated from the right subclavian vein. *BMJ Case Rep* 2009; 2009:bcr2006087395.
- Miyazaki S, Nault I, Haissaguerre M, Hocini M. Atrial fibrillation ablation by aortic retrograde approach using a magnetic navigation system. *J Cardiovasc Electrophysiol* 2010;21:455–457.
- Ebeid MR. Transhepatic vascular access for diagnostic and interventional procedures: techniques, outcome, and complications. *Catheter Cardiovasc Interv* 2007; 69:594–606.
- Ekeruo IA, Sharma S, Cohen A, Hematpour K. Hepatic vein access for pulmonary vein isolation in patients without femoral vein access. *HeartRhythm Case Rep* 2018;5:395–398.
- Morcos R, Al Tahii H, Bansal P, Manam R, Brijeshwar M. Transhepatic vascular access for implantation of a Watchman left atrial appendage closure device. *Reports* 2018;1:5.
- Johnston TA, Donnelly LF, Frush DP, O’Laughlin MP. Transhepatic catheterization using ultrasound-guided access. *Pediatr Cardiol* 2003;24:393–396.
- Orme GJ, Mendenhall C, Blair F, Wen Chen SY, Rhee E, Su W. Percutaneous transhepatic approach for cryoballoon pulmonary vein isolation in a patient with persistent atrial fibrillation and interruption of the inferior vena cava. *Heart-Rhythm Case Rep* 2018;4:332–335.
- Winkle RA, Mead RH, Engel G, Patrawala RA. The use of a radiofrequency needle improves the safety and efficacy of transseptal puncture for atrial fibrillation ablation. *Heart Rhythm* 2011;8:1411–1415.
- Jauvert G, Grimard C, Alonso C, Lazarus A. Use of a radiofrequency guidewire to simplify workflow for left atrium access: a case series [published online ahead of print October 24, 2019]. *J Interv Card Electrophysiol*. <https://doi.org/10.1007/s10840-019-00165-x>.
- Betensky BP, Santangeli P. Radiofrequency wire-facilitated transseptal access using a superior approach for atrial fibrillation ablation in a patient with inferior vena cava obstruction. *HeartRhythm Case Rep* 2016;2:265–267.