

Case Report

Acute Hydrocephalus Following Cervical Spinal Cord Injury

Seong Son, M.D., Sang Gu Lee, M.D., Chan Woo Park, M.D., Woo Kyung Kim, M.D.

Department of Neurosurgery, Gachon University, Gil Medical Center, Incheon, Korea

We present a case of acute hydrocephalus secondary to cervical spinal cord injury in a patient with diffuse ossification of the posterior longitudinal ligament (OPLL). A 75-year-old male patient visited the emergency department with tetraparesis and spinal shock. Imaging studies showed cervical spinal cord injury with hemorrhage and diffuse OPLL from C1 to C4. We performed decompressive laminectomy and occipitocervical fusion. Two days after surgery, his mental status had deteriorated to drowsiness with dilatation of the right pupil. Findings on brain computed tomography revealed acute hydrocephalus and subarachnoid hemorrhage in the cerebellomedullary cistern, therefore, extraventricular drainage was performed immediately. Acute hydrocephalus as a complication of cervical spine trauma is rare, however, it should be considered if the patient shows deterioration of neurologic symptoms.

Key Words : Hydrocephalus · Spinal cord injuries · Ossification of the posterior longitudinal ligament of the spine.

INTRODUCTION

Patients with ossification of the posterior longitudinal ligament (OPLL) of the cervical spine are at potential risk for spinal cord injury (SCI) after trauma. In management of acute SCI, it is important to remain alert to development of complications, which could disturb the patient's recovery.

We present a case of acute hydrocephalus following a cervical SCI in a patient with OPLL.

CASE REPORT

A 75-year-old male patient was referred to our emergency department with a tetraparesis after a trivial fall at home. He had been intermittently admitted to our spine center due to cervical OPLL and diffuse idiopathic skeletal hypertrophy. There was no evidence of head injury and his mental status was alert. On neurological examination, his sensation was off below the C5 dermatome, with right side motor weakness of 0/V and left side motor weakness of II/V. In addition, we detected decreased anal tone, loss of urinary sense, and hypotonia of deep tendon reflex. He also exhibited signs of spinal shock, including hypoten-

sion and bradycardia.

Except for brain cortical atrophy, no abnormal findings were observed on brain computed tomography (CT). Plain cervical radiographs and CT showed diffuse, thick OPLL from level C1 to C4, which was slightly thickened, compared to a previous imaging study performed six years ago. Cervical magnetic resonance imaging showed severe spinal cord compression with signal change of the spinal cord from C1 to C4 (Fig. 1). In particular, heterogeneous signal change of the C1-2 level suggested acute intramedullary hemorrhage of the spinal cord.

We performed emergency cervical spine surgery. Decompressive total laminectomy from C1 to C5, and occipitocervical fusion from occiput to C5 were performed (Fig. 2). In the operation field, cord edema was severe and pulsation of the cord was weak. After the operation, his motor weakness showed slight improvement.

Two days after surgery, his mental status had deteriorated to drowsiness, with dilation of the right pupil of 4 mm. Findings on brain CT revealed acute hydrocephalus and subarachnoid hemorrhage (SAH) in the cerebellomedullary cistern (Fig. 3). Brain and carotid CT angiography showed no vascular abnormality. To alleviate symptoms, we performed lumbar cerebro-

• Received : November 5, 2012 • Revised : March 27, 2013 • Accepted : August 1, 2013

• Address for reprints : Sang Gu Lee, M.D.

Department of Neurosurgery, Gachon University, Gil Hospital, 21 Namdong-daero 774beon-gil, Namdong-gu, Incheon 405-760, Korea
Tel : +82-32-460-3304, Fax : +82-32-460-3899, E-mail : samddal@gilhospital.com

• This is an Open Access article distributed under the terms of the Creative Commons Attribution Non-Commercial License (<http://creativecommons.org/licenses/by-nc/3.0>) which permits unrestricted non-commercial use, distribution, and reproduction in any medium, provided the original work is properly cited.

spinal fluid (CSF) drainage. The pressure of lumbar drainage was as high as 26 cmH₂O, and CSF was mixed with fresh blood. Despite lumbar drainage, his symptoms did not show improve-

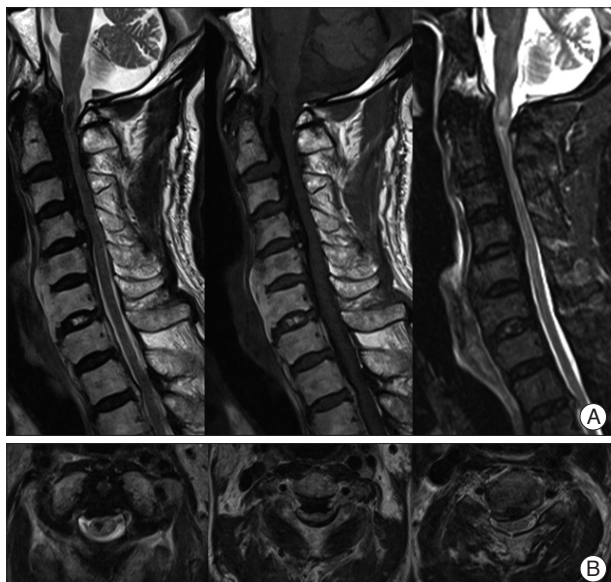


Fig. 1. Preoperative cervical MRI. A : Sagittal cervical MRI revealing thick diffuse OPLL with cord compression and heterogeneous signal change from the cervicomedullary junction to the C4 level. B : Also, axial MRI reveals right side dominant spinal cord compression and signal change of the spinal cord. MRI : magnetic resonance imaging, OPLL : ossification of the posterior longitudinal ligament.

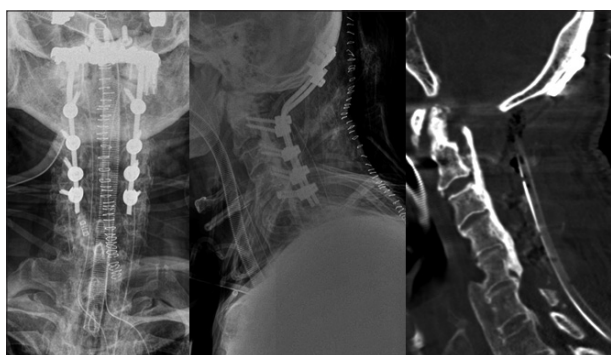


Fig. 2. Decompressive total laminectomy from C1 to C5, and occipito-cervical fusion were performed.

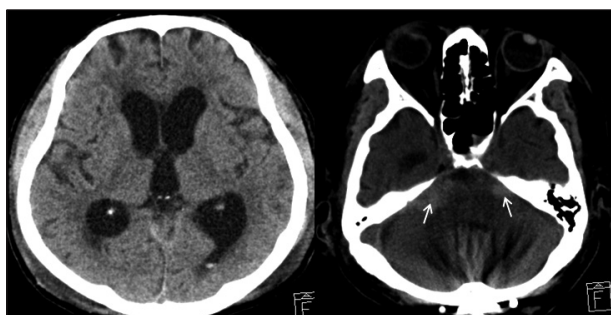

Fig. 3. Brain CT shows marked enlargement of the lateral, third, and fourth ventricles. Also, SAH is observed in the cerebellomedullary cistern (arrows). CT : computed tomography, SAH : subarachnoid hemorrhage.

ment, therefore, extraventricular drainage (EVD) was performed. Two weeks after EVD, ventriculo-peritoneal shunt was performed, however, neurologic deterioration was not fully recovered. Three months after trauma, he eventually died due to heart failure.

DISCUSSION

Hydrocephalus is a common complication of a brain lesion, but an uncommon complication of a spine lesion. Hydrocephalus secondary to spinal pathology has been reported. It has been described in association with spinal tumors, spinal infections, post-cervical myelography, and congenital abnormalities of the cervicomedullary junction^{5,7)}. In these cases, the pathology was thought to be due to disruption of CSF flow, impaired absorption at arachnoid villi due to elevated CSF protein or fibrinogen, tumor infiltration into the cistern, direct compression of ventricular outlet, or compression of the spinal venous plexus by the tumor itself⁷⁾. On the other hand, hydrocephalus after spine trauma is extremely rare.

Hydrocephalus may be either communicating or non-communicating. The non-communicating type is usually the result of obstruction of CSF flow due to various causes, including aqueduct stenosis or tumors. Communicating hydrocephalus is usually post-inflammatory in origin and complicates acute or chronic meningitis, or it may follow hemorrhage or trauma, when blood in the CSF may degrade CSF absorption at the arachnoid villi⁷⁾. Hydrocephalus following head injury or injury to the brain stem is usually the communicating type and presents relatively early⁸⁾.

Several hypotheses regarding the mechanism of hydrocephalus following spine trauma have been postulated. The first possible mechanism is non-communicating hydrocephalus due to direct compression of CSF outlet pathways. Menéndez et al.⁶⁾ reported on a case of hydrocephalus with an occipital condylar fracture fragment pushing into the medulla oblongata. This bone fragment may cause direct compression and obstruction of CSF outlets, such as the fourth ventricle, foramen of Magendie, or foramen of Luschka. However, in our patient, no evidence of direct compression of CSF outlets was observed on various imaging studies.

The second potential mechanism is non-communicating (i.e., obstructive) hydrocephalus due to spinal cord edema. Previous authors have suggested that swelling of the spinal cord, observed after spine trauma, may extend up to two vertebral segments above and below the injured vertebrae¹¹⁾. Spreading of spinal cord edema as high as the medulla oblongata after a cervical SCI has also been reported¹⁰⁾. Challagundla et al.¹⁾ reported on a case of hydrocephalus following fracture dislocation of C5-6 in a patient with ankylosing spondylitis. He postulated that hydrocephalus resulted from obstruction of CSF flow at the fourth ventricular outlets due to ascending edema of the medulla oblongata from the cervical spine. However, in our case, brain CT

showed a communicating type of hydrocephalus with dilation of the fourth ventricle, and no obvious obstructive pathology was observed in the fourth ventricle area, and lumbar CSF pressure was also high; therefore, it is less likely that hydrocephalus resulted from obstruction of the CSF outlet due to edema.

The third plausible mechanism is communicating hydrocephalus due to a traumatic vascular lesion and SAH. Development of a traumatic aneurysm or dissection in craniocervical vasculature, including the cerebral artery, carotid artery, and vertebral artery is a recognized complication of serious trauma⁹⁾. The most common presenting symptom of these vascular lesions is delayed neurological deterioration following a delayed intracranial hemorrhage and hydrocephalus, and CT angiography remains the best diagnostic procedure²⁾. Hossain et al.³⁾ reported on a case of delayed SAH and hydrocephalus due to post-traumatic aneurysm of the posterior inferior cerebellar artery in a patient with SCI at the T7 level. However, in our case, because neurologic deterioration is early onset rather than delayed onset and CT angiography revealed no vascular lesion, it is less likely that SAH is caused by vascular lesion.

The last possible mechanism is communicating hydrocephalus due to traumatic SAH in the spinal cord. Joseph et al.⁴⁾ reported on a case of hydrocephalus after a penetrating stab injury to the spinal cord at the C1-2 level. He postulated that blood entering the subarachnoid space caused delayed absorption of CSF at the arachnoid villi and communicating hydrocephalus. As in the previous case, in our patient, we believe that the pathogenesis may be related to the intramedullary hemorrhage of the spinal cord at the C1-2 level. The blood may enter the cerebellomedullary cistern and disturb the absorption of the CSF at the arachnoid villi over the hemispheres, hence leading to a communicating hydrocephalus. This is supported by brain CT scans showing the communicating type of hydrocephalus and fresh blood on lumbar CSF drainage.

CONCLUSION

We have described a patient who suffered acute communicating hydrocephalus due to traumatic SAH of the spinal cord. In any patient with cervical SCI, hydrocephalus should be considered if the patient's level of consciousness shows deterioration.

References

1. Challagundla SR, Joseph G, Brown J, McLean AN, Fraser MH : Hydrocephalus complicating a cervical spine fracture in a patient with ankylosing spondylitis. *Br J Neurosurg* 22 : 700-701, 2008
2. Haddad FS, Haddad GF, Taha J : Traumatic intracranial aneurysms caused by missiles : their presentation and management. *Neurosurgery* 28 : 1-7, 1991
3. Hossain M, Brown J, McLean AN, Fraser MH : Delayed presentation of post-traumatic aneurysm of the posterior inferior cerebellar artery in a patient with spinal cord injury. *Spinal Cord* 40 : 307-309, 2002
4. Joseph G, Johnston RA, Fraser MH, McLean AN : Delayed hydrocephalus as an unusual complication of a stab injury to the spine. *Spinal Cord* 43 : 56-58, 2005
5. Kim YD, Kim DH : Lumbar schwannoma associated with hydrocephalus. *J Korean Neurosurg Soc* 37 : 228-231, 2005
6. Menéndez JA, Başkaya MK, Day MA, Nanda A : Type III occipital condylar fracture presenting with hydrocephalus, vertebral artery injury and vasospasm : case report. *Neuroradiology* 43 : 246-248, 2001
7. Mirone G, Cinalli G, Spennato P, Ruggiero C, Aliberti F : Hydrocephalus and spinal cord tumors : a review. *Childs Nerv Syst* 27 : 1741-1749, 2011
8. Saboe LA, Reid DC, Davis LA, Warren SA, Grace MG : Spine trauma and associated injuries. *J Trauma* 31 : 43-48, 1991
9. Schuster JM, Santiago P, Elliott JP, Grady MS, Newell DW, Winn HR : Acute traumatic posteroinferior cerebellar artery aneurysms : report of three cases. *Neurosurgery* 45 : 1465-1467; discussion 1467-1468, 1999
10. Sudo H, Taneichi H, Kaneda K : Secondary medulla oblongata involvement following middle cervical spinal cord injury associated with latent traumatic instability in a patient with ossification of the posterior longitudinal ligament. *Spinal Cord* 44 : 126-129, 2006
11. Yablon IG, Ordia J, Mortara R, Reed J, Spatz E : Acute ascending myelopathy of the spine. *Spine (Phila Pa 1976)* 14 : 1084-1089, 1989