

Single Case

A Case Report of Kidney-Only Transplantation in Primary Hyperoxaluria Type 1: A Novel Approach with the Use of Nedosiran

Matthew C. Breeggemann^a Stephen L. Gluck^a Marshall L. Stoller^b
Marsha M. Lee^c

^aDivision of Nephrology, University of California San Francisco, San Francisco, CA, USA;

^bDepartment of Urology, University of California San Francisco, San Francisco, CA, USA; ^cDivision of Pediatric Nephrology, Department of Pediatrics, University of California, San Francisco, CA, USA

Keywords

Primary hyperoxaluria type 1 · Urinary oxalate · Plasma oxalate · Lumasiran · Nedosiran

Abstract

The primary hyperoxalurias (PHs) are a group of diseases characterized by kidney stones, nephrocalcinosis, and chronic kidney disease. At stages of advanced kidney disease, glomerular filtration of oxalate becomes insufficient, plasma levels increase, and tissue deposition may occur. Hemodialysis is often unable to overcome the excess hepatic oxalate production. The current surgical management of primary hyperoxaluria type 1 (PH1) is combined liver kidney transplantation. In a subset of PH1 patients who respond to pyridoxine, kidney-only transplantation has been successfully performed. Recently, kidney-only transplantation has also been performed in PH1 patients receiving a small interfering RNA therapy called lumasiran. This drug targets the hepatic overproduction of oxalate, making kidney-only transplantation a potentially practical novel approach for managing PH1 patients with advanced kidney disease. It is unknown if similar effects could be seen with a different small interfering RNA agent called nedosiran. This article will briefly review PH1, describe the small interfering RNA therapies being used to treat PH, summarize the reported cases of kidney-only transplantation performed with lumasiran, and detail a case of kidney-only transplantation performed in a PH1 patient receiving nedosiran.

© 2023 The Author(s).
Published by S. Karger AG, Basel

Correspondence to:
Matthew C. Breeggemann, Matthew.Breeggemann@ucsf.edu

Introduction

Primary hyperoxaluria type 1 (PH1) is an ultra-rare autosomal recessive kidney stone disease that results from deficient alanine glyoxalate aminotransferase (AGT) activity. This hepatic peroxisomal enzyme metabolizes L-alanine and glyoxylate to produce pyruvate and glycine [1]. When AGT activity is reduced, the accumulation of glyoxylate serves as a substrate for cytosolic lactate dehydrogenase A (LDHA)-mediated oxalate production [2]. Oxalate has no known function in humans and has a high affinity for calcium. The resultant crystalluria can lead to calcium oxalate kidney stones, genitourinary obstruction, nephrocalcinosis, and chronic kidney disease (CKD) [3]. 20-year kidney survival in primary hyperoxaluria (PH) correlates with baseline urinary oxalate (UOx) excretion, and the risk of kidney failure is greater with increasing UOx levels [4]. Interestingly, AGT has a pyridoxal phosphate cofactor-binding site, and administration of high doses of pyridoxine has been shown to lower UOx in some PH1 patients [5]. This has even allowed for kidney-only transplantation in the minority of patients who experience significant UOx reductions on pyridoxine [6, 7]. However, most PH1 patients will ultimately pursue combined liver kidney transplantation (CLKT) at the onset of advanced kidney disease and associated rise in plasma oxalate (POx) levels.

In November 2020, the first and currently only drug to treat PH1 was approved by the FDA. Lumasiran, a subcutaneously administered siRNA therapy, inhibits expression of peroxisomal glycolate oxidase by mRNA degradation. Glycolate oxidase metabolizes glycolate into glyoxylate, and thus inhibition of this enzyme decreases cytosolic LDHA-mediated glyoxylate to oxalate conversion. Lumasiran has been shown to reduce both UOx and POx in three different ongoing clinical trials involving PH1 patients (Table 1) [8–10].

Similar to the small subset of PH patients who respond favorably to pyridoxine, kidney-only transplantation has been performed in a small group of patients receiving lumasiran. The first-reported case involved a 39-year-old woman with PH1 who had been receiving lumasiran for approximately 7 months and achieved normalization of POx ranging from 20.9 to 24.0 $\mu\text{mol/L}$ (normal levels are defined in this paper as $<33 \mu\text{mol/L}$) prior to transplantation. One session of hemodialysis (HD) was performed postoperatively for delayed graft function, and preventative measures including high fluid intake, low oxalate diet, a crystallization inhibitor, pyridoxine, and a thiazide-like diuretic were advised postoperatively. UOx excretion was elevated at 1.15 mmol/d ($<0.45 \text{ mmol/d}$). Unfortunately, the patient developed Banff 2A rejection and had evidence of allograft oxalate crystal deposition on a biopsy performed 25 days after transplantation [11]. The findings from a study of five PH1 patients who received kidney-only transplants on lumasiran and were followed for at least 6 months with pretransplant POx levels ranging from 10 to 72 $\mu\text{mol/L}$ (average 49.8 $\mu\text{mol/L}$) demonstrated 1 patient with allograft oxalate crystal deposition. None experienced delayed graft function, but the 3 patients with the highest POx levels received HD postoperatively, though this appears to have been discontinued in all patients before 3 months posttransplant. All of the patients were prescribed hyperhydration and most were on pyridoxine and crystallization inhibitors after transplantation. At 6 months posttransplant, POx levels ranged from undetectable to 21 $\mu\text{mol/L}$. In the 3 patients with whom UOx levels were assessed, values ranged from 0.101 to 2.046 mmol/d (average 1.0 mmol/d). No patients were reported to have experienced allograft rejection [12].

Nedosiran is a different siRNA therapy being investigated for the treatment of PH. Due to its mechanism of downregulating LDHA mRNA, nedosiran has the potential to treat all three types of PHs, though only PH1 and PH2 patients were enrolled in the phase 2 trial PHYOX2 (NCT03847909). Similar to lumasiran, subcutaneously administered nedosiran will also be studied in pediatric patients in the PHYOX8 trial (NCT05001269). It has been used in a patient with end-stage kidney disease [13], whose case will be detailed later in this article. Active recruiting to study the drug in advanced kidney disease is underway in the PHYOX7 trial

Table 1. Summary of clinical trials involving lumasiran

Study name	Study design	Inclusion criteria	N	Primary outcome	Primary results
ILLUMINATE-A	Double-blind randomized (2:1) placebo controlled	Age ≥6 years eGFR ≥30 mL/min/1.73 m ² 24-h UOx ≥0.70 mmol	39	Percent Δ in 24-h UOx from baseline	65.4% UOx reduction (lumasiran group)
ILLUMINATE-B	Single-arm, open-label	Age <6 years eGFR >45 mL/min/1.73 m ² Normal SCr (if < 1 year) Spot UOx:Cr > ULN	18	Percent Δ in spot UOx:Cr from baseline	72.0% UOx reduction
ILLUMINATE-C	Single-arm, open-label Cohort A: not receiving HD Cohort B: receiving HD	Any age eGFR ≤45 mL/min/1.73 m ² Elevated SCr (if < 1 year) POx ≥20 μmol/L	A: 6 B: 15	Percent Δ in POx from baseline	33.3% POx reduction (cohort A) 42.4% POx reduction (cohort B)

N, number of participants; eGFR, estimated glomerular filtration rate; UOx, urinary oxalate; SCr, serum creatinine; ULN, upper limit normal; POx, plasma oxalate.

(NCT04580420). The CARE Checklist has been completed by the authors for this case report, attached as online supplementary material (for all online suppl. material, see <https://doi.org/10.1159/000531053>).

Case Description

A 17-year-old patient (they/them) with PH1 developed end-stage kidney disease and was started on HD. Their other medical history is notable for Factor V Leiden (heterozygous type), major depressive disorder, generalized anxiety disorder, and gastroesophageal reflux. They passed approximately 10 kidney stones in their lifetime, with the first episode at age 3 years requiring hospitalization. The diagnosis of PH1 was made by genetic testing 2 years later (c.973delG, exon 10 + c.836T>C, exon 8). No significant reduction in UOx was observed during a pyridoxine trial. Their estimated average daily fluid consumption was 4–5 L. Medications included potassium citrate, escitalopram, hydroxyzine, omeprazole, and cholecalciferol. Their family history is notable for PH1 in a younger sibling who underwent CLKT at age 2 years and ultimately repeat kidney transplantation at age 11 years.

HD was initiated at a frequency of 6 days per week following an acute rise in POx (shown in Fig. 1) to reduce the morbidity associated with oxalosis. Three months after HD initiation, they started nedosiran on a compassionate use basis. HD frequency was progressively decreased to 3 days per week following a reduction in POx. The patient declined an offer for a CLKT in favor of waiting for a kidney-only transplant.

At age 19 years, they received a deceased donor kidney transplant. Pretransplant POx was 12.8 μmol/L. Intravenous basiliximab was used for induction. Urine output was 275 mL at 15 min post-reperfusion. Daily HD was initiated on postoperative day (POD) 1 to target POx levels of <3 μmol/L. An abdominal ultrasound including studies of the renal allograft did not reveal any abnormalities. The posttransplant immunosuppressive regimen included

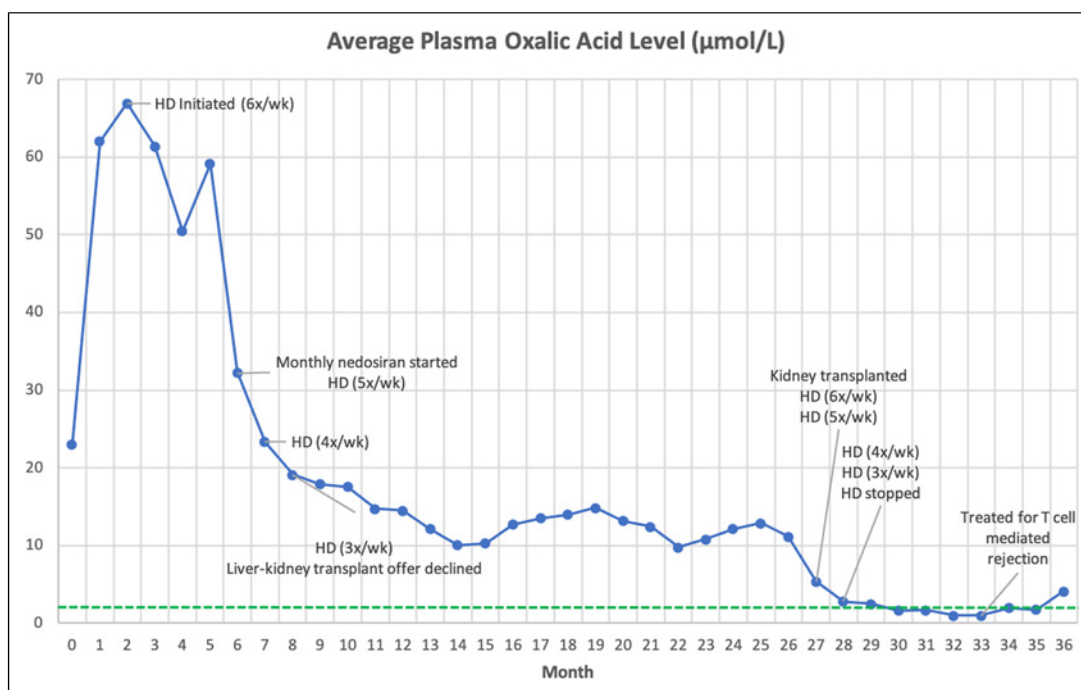


Fig. 1. Average monthly pre-HD POx levels ($\mu\text{mol/L}$). Green dotted line indicates upper limit of normal. A value of $1.0 \mu\text{mol/L}$ was assigned for values resulting as $<2 \mu\text{mol/L}$.

basiliximab, prednisone, tacrolimus, and mycophenolate mofetil. Infection prophylactic agents included trimethoprim/sulfamethoxazole and valganciclovir. They received their scheduled monthly dose of nedosiran on POD 6 and were discharged on POD 10. Continued hyperhydration and citrate were recommended.

Following hospital discharge, they continued HD 6 days weekly for oxalate removal. This was reduced to 5 times weekly at 4 weeks posttransplantation for pre-HD POx levels of $1.8\text{--}4.0 \mu\text{mol/L}$, four times weekly at 5 weeks posttransplantation for pre-HD POx levels of $1.8\text{--}4.0 \mu\text{mol/L}$, and 3 times weekly at 6 weeks posttransplantation for pre-HD POx levels of $1.6\text{--}3.0 \mu\text{mol/L}$. The last HD session was at 7 weeks posttransplantation, when the pre-HD POx level was $2.9 \mu\text{mol/L}$. POx has since remained at $<5 \mu\text{mol/L}$ following discontinuation of HD and through 9 months posttransplant (shown in Fig. 1). Importantly, UOx has remained minimally elevated ranging from 42.7 to 48.0 mg/d ($3.6\text{--}38.0 \text{ mg/d}$) since discontinuation of HD and through 9 months posttransplant (shown in Fig. 2). Ultrasound of the renal allograft is without kidney stones and nephrocalcinosis.

Unfortunately, the patient developed acute T-cell-mediated transplant rejection (Banff 1B) detected on a surveillance biopsy performed at 6 months posttransplant. There was no evidence of tissue oxalate crystal deposition. They were treated with Thymoglobulin and methylprednisolone. Repeat transplant biopsy 2 months later was notable for borderline changes (Banff i1,t1) and no tissue oxalate crystal deposition. Baseline creatinine of 1.0 mg/dL has since increased to 1.2 mg/dL ($0.55\text{--}1.02 \text{ mg/dL}$).

Discussion

PH1 is a devastating metabolic disease that results from the hepatic overproduction of oxalate. Patients often suffer from frequent stone episodes before developing progressive

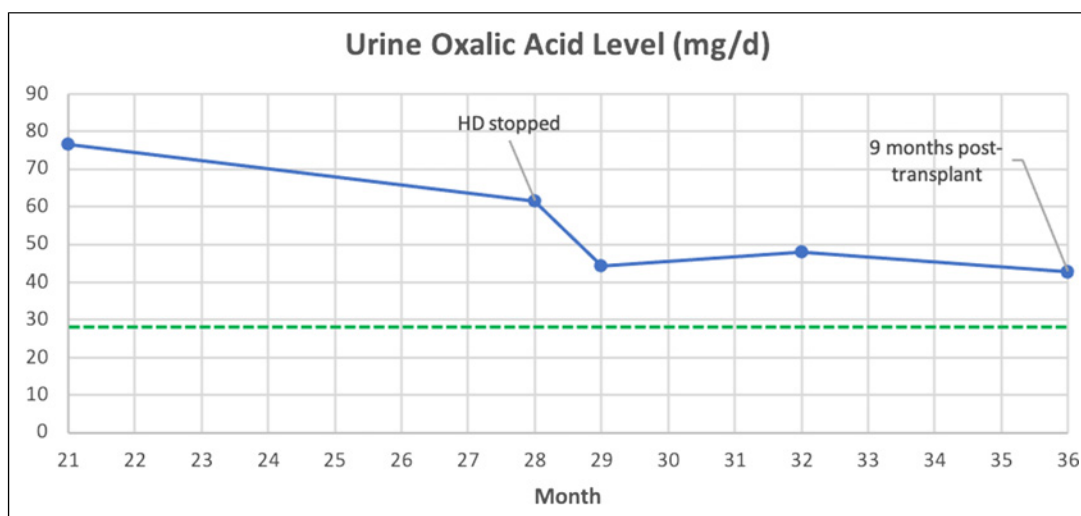


Fig. 2. 24-h urine oxalate levels (mg/d). Green dotted line indicates upper limit of normal.

CKD and oxalosis in young adulthood. They adopt an intensive dialysis regimen before waiting for a CLKT. This grim outlook has improved recently with the advent of siRNA therapies targeting hepatic enzymes to reduce UOx and POx. Their marked effectiveness offers hope to this historically vulnerable patient population. While the goal continues to be early identification of PH to start effective management before advanced kidney disease ensues, many will continue to require transplantation.

To date, there have been 6 published cases of patients receiving lumasiran who underwent kidney-only transplantation. Each patient had variable pretransplant POx levels and two had evidence of oxalate crystal deposition on posttransplant biopsies. UOx levels were elevated in most patients, which likely reflects mobilization of bone and other tissue oxalate stores which may take months or even years to clear.

The ideal pretransplant POx levels for those pursuing kidney-only transplantation while on siRNA therapy are unknown. Similarly, the ideal posttransplant UOx levels are unknown. It seems reasonable to assume that lower values would correlate with better renal allograft survival in avoiding posttransplant oxalate nephropathy. However, given the sparsity of reported cases to date, this has yet to be established. The authors of the 5 patient case series referenced above indicate that POx levels <80–90 $\mu\text{mol/L}$ may allow for kidney-only transplantation in PH1 patients receiving lumasiran. Additional data from long-term follow-up of all patients choosing this novel transplantation strategy are greatly needed including those receiving nedosiran.

Our case demonstrates that nedosiran might make kidney-only transplantation the preferred strategy in some PH patients who reach advanced kidney disease. We were able to reduce the posttransplant POx to lower levels than the patients described on lumasiran by continuing intensive dialysis after the surgery. Our patient also had lower pretransplant POx levels possibly due to the short duration with advanced kidney disease, indicating lower tissue oxalate stores. Adherence to hyperhydration, crystallization inhibitors, treatment of hypercalciuria, and pyridoxine (if responsive) are also important for posttransplant patients. It is worth noting that our patient, and one of the kidney-only-transplanted PH1 patients on lumasiran, experienced advanced T-cell-mediated rejection. Given the well-described role that transplanted livers play in modulating host alloimmunity, one potential benefit of CLKT would be decreased risk of kidney allograft rejection. However, this must also be balanced with the high associated morbidity and mortality that liver transplant recipients face.

In summary, PH represents one of the most severe forms of kidney stone disease. Fortunately, an extensive amount of knowledge regarding PH and its ideal management will be available in the near future as additional studies are performed and important PH clinical trials conclude. We have come a long way to help a vulnerable patient population advance from a time when limited therapies existed to successfully implementing pyridoxine, lumasiran, nedosiran, and other treatments aimed at lowering UOx and POx, preventing painful kidney stone episodes and reducing the high frequency of CKD.

Statement of Ethics

Written informed consent was obtained from the patient for publication of the details of their medical case and any accompanying images. Ethical approval is not required for this study in accordance with local or national guidelines.

Conflict of Interest Statement

The authors have no conflicts of interest to declare.

Funding Sources

The authors received no financial support for the research, authorship, and/or publication of this article.

Author Contributions

Matthew C. Breeggemann was involved with chart reviewing the case, performing literature review, and writing the manuscript. Stephen L. Gluck and Marshall L. Stoller were involved with performing literature review, supervision, and editing the manuscript. Marsha M. Lee was involved with direct patient care, performing literature review, supervision, and editing the manuscript. All authors read and approved the final manuscript.

Data Availability Statement

All data generated or analyzed during this study are included in this article. Further inquiries can be directed to the corresponding author.

References

- 1 Pey AL, Albert A, Salido E. Protein homeostasis defects of alanine-glyoxylate aminotransferase: new therapeutic strategies in primary hyperoxaluria type I. *BioMed Res Int*. 2013;2013:687658.
- 2 Dindo M, Conter C, Oppici E, Ceccarelli V, Marinucci L, Cellini B. Molecular basis of primary hyperoxaluria: clues to innovative treatments. *Urolithiasis*. 2019;47(1):67–78.
- 3 Mulay SR, Kulkarni OP, Rupanagudi KV, Migliorini A, Darisipudi MN, Vilaysane A, et al. Calcium oxalate crystals induce renal inflammation by NLRP3-mediated IL-1 β secretion. *J Clin Invest*. 2013;123(1):236–46.

- 4 Zhao F, Bergstralh EJ, Mehta RA, Vaughan LE, Olson JB, Seide BM, et al. Predictors of incident ESRD among patients with primary hyperoxaluria presenting prior to kidney failure. *Clin J Am Soc Nephrol*. 2016;11(1):119–26.
- 5 Leumann E, Hoppe B. What is new in primary hyperoxaluria? *Nephrol Dial Transplant*. 1999;14(11):2556–8.
- 6 Lorenz EC, Lieske JC, Seide BM, Meek AM, Olson JB, Bergstralh EJ, et al. Sustained pyridoxine response in primary hyperoxaluria type 1 recipients of kidney alone transplant. *Am J Transplant*. 2014;14(6):1433–8.
- 7 Metry EL, Garrelfs SF, Peters-Sengers H, Hulton SA, Acquaviva C, Bacchetta J, et al. Long-term transplantation outcomes in patients with primary hyperoxaluria type 1 included in the European hyperoxaluria consortium (OxalEurope) registry. *Kidney Int Rep*. 2022;7(2):210–20. Published 2021 Nov 26.
- 8 Garrelfs SF, Frishberg Y, Hulton SA, Koren MJ, O’Riordan WD, Cochat P, et al. Lumasiran, an RNAi therapeutic for primary hyperoxaluria type 1. *N Engl J Med*. 2021;384(13):1216–26.
- 9 Sas DJ, Magen D, Hayes W, Shasha-Lavsky H, Michael M, Schulte I, et al. Phase 3 trial of lumasiran for primary hyperoxaluria type 1: a new RNAi therapeutic in infants and young children. *Genet Med*. 2022;24(3):654–62.
- 10 Michael M, Groothoff JW, Shasha-Lavsky H, Lieske JC, Frishberg Y, Simkova E, et al. Lumasiran for advanced primary hyperoxaluria type 1: phase 3 ILLUMINATE-C trial. *Am J Kidney Dis*. 2023;81(2):145–155.e1.
- 11 Joher N, Moktefi A, Grimbert P, Pagot E, Jouan N, El Karoui K, et al. Early post-transplant recurrence of oxalate nephropathy in a patient with primary hyperoxaluria type 1, despite pretransplant lumasiran therapy. *Kidney Int*. 2022;101(1):185–6.
- 12 Sellier-Leclerc AL, Metry E, Clave S, Perrin P, Acquaviva-Bourdain C, Levi C, et al. Isolated kidney transplantation under lumasiran therapy in primary hyperoxaluria type 1: a report of 5 cases. *Nephrol Dial Transplant*. 2022;38(2):517–21.
- 13 Shee K, Ahn J, Hamouche F, Mena J, Chi T, Stoller ML. Nedosiran dramatically reduces serum oxalate in dialysis-dependent primary hyperoxaluria 1: a compassionate use case report. *Urology*. 2021;156:e147–9.