

Ultrasound-Guided Superior and Middle Trunk Brachial Plexus Block with Superficial Cervical Plexus Block for Shoulder Surgeries in High-Risk Patients: Case Series

Vinodhadevi Vijayakumar^{1*}, Arimanickam Ganesamoorthi¹, Nandhakumar Subramaniyan¹, Parthiban Kasirajan²

¹Department of Anesthesiology and Critical Care, Meenakshi Hospital, Thanjavur, Tamil Nadu, India, ²Department of Orthopaedics and Traumatology, Meenakshi Hospital, Thanjavur, Tamil Nadu, India

Abstract

There is a constant quest for a regional anesthetic technique that would provide anesthesia adequately for shoulder surgeries but lacks the complications of an interscalene block, such as phrenic nerve palsy. The nerves to be blocked for a surgery can be analyzed and tailored. We discuss the precise blockade of the superior and middle trunk of the brachial plexus along with superficial cervical plexus block using ultrasound for performing three different shoulder surgeries exclusively under regional anesthesia, in high-risk patients without any clinically observed complications.

Keywords: Brachial plexus block, middle trunk block, shoulder surgeries, superficial cervical plexus block, superior trunk block, ultrasound guided regional anesthesia, superior and middle trunk block

INTRODUCTION

Ultrasound imaging plays an important role in the diagnosis and intervention of musculoskeletal disorders.^[1,2] In a conventional interscalene block, anatomical landmarks are used, and the administration of large volumes of local anesthetic agents, results in the undesired blockade of structures mainly the ipsilateral phrenic nerve.^[3,4] Ultrasonographic nerve tracking in the cervical region has been extensively described in the literature.^[5] Phrenic nerve-sparing alternatives for conventional interscalene blocks similar to the ultrasound-guided superior trunk block, and suprascapular nerve block alone or with axillary nerve block have been recently described.^[6-9] The aforementioned ultrasound-guided blocks are performed for intra/postoperative analgesia as supplements to general anesthesia (GA). Shoulder surgeries performed only with these blocks without GA have not been reported. Institutional Ethics Committee approval and informed written consent from all three patients have been obtained for this publication.

Received: 17-07-2019 Revised: 02-11-2019 Accepted: 27-12-2019 Available Online: 19-02-2020

Access this article online

Quick Response Code:



Website:
www.jmuonline.org

DOI:
10.4103/JMU.JMU_73_19

CASE REPORTS

Case 1

A 44-year-old male patient with a history of hypertension presented with multiple rib fractures (3-7) and a hemopneumothorax with intercostal drainage on the right side following a road traffic accident (RTA). Four days after the injury, an open reduction internal fixation (ORIF) with locking screw for a comminuted displaced fracture (middle third) of the right clavicle was performed under ultrasound-guided superior and middle trunk brachial plexus block (SMT-BPB) and superficial cervical plexus block (SCPB). Intraoperatively, 0.5 mg of midazolam, 50 mcg of fentanyl, and 1 g of paracetamol g were administered intravenously (IV).

Address for correspondence: Dr. Vinodhadevi Vijayakumar, Consultant Anesthesiologist, Department of Anesthesiology and Critical Care, 244/7, Trichy Main Road, Meenakshi Hospital, Thanjavur, Tamil Nadu, India.
E-mail: vinodhavijayakumar@gmail.com

This is an open access journal, and articles are distributed under the terms of the Creative Commons Attribution-NonCommercial-ShareAlike 4.0 License, which allows others to remix, tweak, and build upon the work non-commercially, as long as appropriate credit is given and the new creations are licensed under the identical terms.

For reprints contact: WKHLRPMedknow_reprints@wolterskluwer.com

How to cite this article: Vijayakumar V, Ganesamoorthi A, Subramaniyan N, Kasirajan P. Ultrasound-guided superior and middle trunk brachial plexus block with superficial cervical plexus block for shoulder surgeries in high-risk patients: Case series. J Med Ultrasound 2020;28:185-7.

Case 2

A 50-year-old male patient presented with the Glasgow coma scale (GCS) score of 10/15 following a RTA. Computed tomography (CT) of the brain revealed a right temporal extradural hemorrhage, left parietal contusion, and pneumocephalus. He was treated with anticerebral edema measures and antiepileptics. Four days later, his GCS improved to 15/15 with no neurological deficits, and a serial CT of the brain showed a decreasing trend of cerebral edema. He underwent an ORIF with tension band wiring for the comminuted displaced fracture of the acromion process of the right scapula. The surgery was uneventful, under ultrasound-guided SMT-BPB and SCPB.

Case 3

A 63-year-old male, a known diabetic with coronary artery disease (with a history of coronary artery bypass grafting for triple-vessel disease) on dual antiplatelets (aspirin 75 mg and clopidogrel 75 mg) presented with an avulsion fracture of greater tuberosity of the right humerus. His echocardiography revealed regional wall motion abnormality in the right coronary artery territory and moderate left ventricular systolic dysfunction with an ejection fraction-45%. A closed reduction and cancellous screw fixation were achieved under ultrasound-guided SMT-BPB and SCPB.

Description of the technique

Patients were positioned supine with their head end elevated by 15° and head turned to the opposite side. Under strict aseptic precautions, using the ultrasound system (Philips HD11XE) L12-3 (broadband linear array probe), the brachial plexus was traced from the root to divisions in the neck with the probe maintained perpendicular to the long axis of the plexus. The superior trunk was confirmed by the union of the cervical nerve roots (C) 5 and C6 and their division into the anterior and posterior divisions. The middle trunk was confirmed by tracing the C7 root and its continuation as a single structure before it divides into anterior and posterior divisions [Figure 1]. The local anesthesia (LA) mixture was prepared (10 ml of 2% lignocaine with adrenaline (5 mcg/ml) and 10 ml of 0.5% bupivacaine). Using the in-plane technique, a 23G Quincke-Babcock needle was inserted from the lateral to the medial side (to prevent phrenic nerve injury). The superior trunk of the brachial plexus was blocked at its most distal part immediately before its anterior and posterior divisions with 5 ml of the LA mixture by slow injection, preventing its spread anterior to the anterior scalene muscle to avoid phrenic palsy. The middle trunk was blocked just before its division into anterior and posterior, with 5 ml of LA mixture.

In the out-of-plane technique, the needle was inserted at the level of the midpoint of the posterior border of the sternocleidomastoid (SCM) and 10 ml of the LA mixture was deposited in the fascial plane of the superficial cervical plexus. The drug was injected slowly to avoid its spread more medially under the SCM, preventing phrenic palsy.

Intraoperatively, none of the three patients experienced pain, fall in SpO₂, symptomatic dyspnea (phrenic nerve), Horner's syndrome, or hoarseness of voice. The surgical duration was 60–90 min, and the surgeries were successfully completed without needing general anesthesia. Patients had complete analgesia for approximately 6 h from the time of onset of the block. Postoperatively, they received IV tramadol 50 mg eighth hourly and IV paracetamol 1 g sixth hourly. They had no complications on discharge and follow-up sessions after 2, 4, and 26 weeks.

DISCUSSION

Our three patients underwent different surgeries of the shoulder with different clinically associated comorbidities (chest injury, head injury, and coronary artery disease). We defined high-risk patients as the American Society of Anesthesiologists (3 or more) physical status^[10] and/or those in whom a blockade of the phrenic nerve would result in a worsening respiratory status.

We discussed the option of regional anesthesia (RA) with the patients, their relatives, and the surgeon. All three patients were cooperative and were willing for RA. They were assured that GA would be administered if they felt any discomfort. The surgeon was prepared to change the patient's position from beach chair to supine if GA had to be administered.

With a conventional interscalene block, the phrenic nerve can get blocked causing hemi-diaphragmatic palsy in as many as 100% of patients.^[3] The cervical sympathetic chain and the recurrent laryngeal nerve can also get blocked due to their proximity to the brachial plexus, leading to Horner's syndrome, and voice hoarseness, respectively.^[6] These unwanted complications are due to the large volume of drugs administered in the interscalene block and their spread (≥ 20 ml).^[4] Although we administered a total volume of 20 ml of LA mixture to our patients, the volume deposited around the brachial plexus (SMT) was only 10 ml (5 ml for

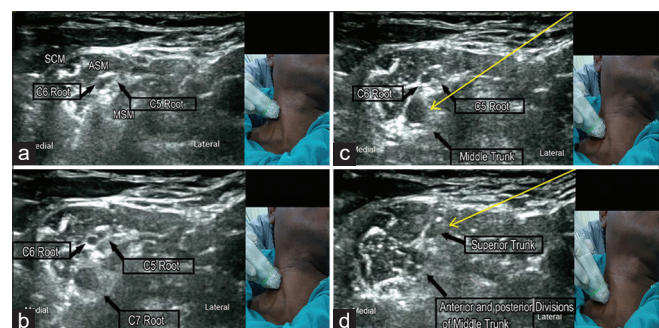


Figure 1: Sonoanatomy of the right side brachial plexus and the position of the ultrasound transducer in the neck are demonstrated. (a) Cervical root (C) 5, C6. SCM: Sternocleidomastoid, ASM: Anterior Scalene Muscle, MSM: Middle Scalene Muscle. (b) Emerging of C7 root (c) C5-C6 about to unite to form superior trunk. C7 continues as middle trunk. (d) Superior trunk formed, middle trunk divided into the anterior and posterior divisions. The yellow arrow indicates the trajectory the needle is passed in in-plane technique to block the middle trunk (C) and Superior trunk (D). The black arrow indicates parts of the brachial plexus

each trunk). The rest of the 10 ml of LA mixture was deposited around the superficial cervical plexus. Alternatives such as supraclavicular block may offer inferior analgesia as the nerve to subclavius and suprascapular nerve supplying the shoulder will be spared.^[7] Recently, there were two reports where the superior trunk block was used for intra- and postoperative analgesia in shoulder surgeries^[8,9] Reviewing the literature revealed that a phrenic nerve-sparing, regional anesthetic technique solely for surgical anesthesia of shoulders without GA has not been described. The newer ultrasound-guided approaches and nerve blocks are all demonstrated for intra/postoperative analgesia along with GA.^[6-9]

Modifications in the interscalene block technique such as reducing local anesthetic volume,^[11] reducing its concentration,^[12] and injecting with low pressure^[6] have significantly reduced the incidence of phrenic nerve palsy.

The various nerves to be blocked for performing surgeries in the patients mentioned above under RA were analyzed as the RA targets for shoulder surgeries are described in detail, considering their cutaneous, muscular, bony, and capsular components.^[6,13]

By using ultrasonography, we precisely located the roots, trunks, and divisions of the brachial plexus. The superior trunk (C5 and C6) and the middle trunk (C7) are the sites where the nerves supplying the shoulder are densely packed and relatively distant from the phrenic nerve. They are the ideal targets for the block to be effective and safe avoiding unwanted complications. An additional blockade of the superficial cervical plexus was required to block the cutaneous nerve supply to the shoulder, the supraclavicular nerves (C3 and C4 components). Blocking only the SMT (C5-7) components would spare this nerve.^[6,13]

Shoulder surgeries requiring the blockade of the long thoracic nerves (C5-C7) and dorsal scapular nerve (C5) are not blocked by this technique as they arise from the cervical root level. The objective evaluation of phrenic nerve palsy using spirometry, ultrasonography, electrical impedance tomography,^[14] and further randomized control trials are needed to confirm the phrenic sparing feature of SMT-BPB.

CONCLUSION

SMT-BPB is a refined technique of interscalene under ultrasound guidance that precisely targets only the SMT, with a lower volume and slower injection that prevents phrenic nerve palsy. Thus, RA can be used to the advantage of high-risk patients, in whom conventional interscalene is avoided for the risk of phrenic nerve palsy.

Declaration of patient consent

The authors certify that they have obtained all appropriate patient consent forms. In the form the patient(s) has/have given his/her/their consent for his/her/their images and other

clinical information to be reported in the journal. The patients understand that their names and initials will not be published and due efforts will be made to conceal their identity, but anonymity cannot be guaranteed.

Financial support and sponsorship

Nil.

Conflicts of interest

There are no conflicts of interest.

REFERENCES

1. Chang KV, Wu WT, Huang KC, Jan WH, Han DS. Limb muscle quality and quantity in elderly adults with dynapenia but not sarcopenia: An ultrasound imaging study. *Exp Gerontol* 2018;108:54-61.
2. Chang KV, Wu WT, Han DS, Özçakar L. Static and dynamic shoulder imaging to predict initial effectiveness and recurrence after ultrasound-guided subacromial corticosteroid injections. *Arch Phys Med Rehabil* 2017;98:1984-94.
3. Urmey WF, Talts KH, Sharrock NE. One hundred percent incidence of hemidiaphragmatic paresis associated with interscalene brachial plexus anesthesia as diagnosed by ultrasonography. *Anesth Analg* 1991;72:498-503.
4. Riazi S, Carmichael N, Awad I, Holtby RM, McCartney CJ. Effect of local anaesthetic volume (20 versus 5 ml) on the efficacy and respiratory consequences of ultrasound-guided interscalene brachial plexus block. *Br J Anaesth* 2008;101:549-56.
5. Chang KV, Lin CP, Hung CY, Özçakar L, Wang TG, Chen WS. Sonographic nerve tracking in the cervical region: A pictorial essay and video demonstration. *Am J Phys Med Rehabil* 2016;95:862-70.
6. El-Boghdady K, Chin KJ, Chan VW. Phrenic nerve palsy and regional anesthesia for shoulder surgery: Anatomical, physiologic, and clinical considerations. *Anesthesiology* 2017;127:173-91.
7. Auyong DB, Hanson NA, Joseph RS, Schmidt BE, Slee AE, Yuan SC. Comparison of anterior suprascapular, supraclavicular, and interscalene nerve block approaches for major outpatient arthroscopic shoulder surgery: A randomized, double-blind, noninferiority trial. *Anesthesiology* 2018;129:47-57.
8. Lin JA, Chuang TY, Yao HY, Yang SF, Tai YT. Ultrasound standard of peripheral nerve block for shoulder arthroscopy: A single-penetration double-injection approach targeting the superior trunk and supraclavicular nerve in the lateral decubitus position. *Br J Anaesth* 2015;115:932-4.
9. Burckett-St Laurent D, Chan V, Chin KJ. Refining the ultrasound-guided interscalene brachial plexus block: The superior trunk approach. *Can J Anaesth* 2014;61:1098-102.
10. Mayhew D, Mendonca V, Murthy BV. A review of ASA physical status-historical perspectives and modern developments. *Anaesthesia* 2019;74:373-9.
11. Chibata I, Tosa T. Transformations of organic compounds by immobilized microbial cells. *Adv Appl Microbiol* 1977;22:1-27.
12. Wong AK, Keeney LG, Chen L, Williams R, Liu J, Elkassabany NM. Effect of local anesthetic concentration (0.2% versus 0.1% ropivacaine) on pulmonary function, and analgesia after ultrasound-guided interscalene brachial plexus block: A randomized controlled study. *Pain Med* 2016;17:2397-403.
13. Agur AM, Dalley AF. *Upperlimb. Grant's Atlas of Anatomy*. 14th ed. Philadelphia, PA: Wolters Kluwer. 2017. p. 96-7.
14. Wiegel M, Hammermüller S, Wrigge H, Reske AW. Electrical impedance tomography visualizes impaired ventilation due to hemidiaphragmatic paresis after interscalene brachial plexus block. *Anesthesiology* 2016;125:807.