

# Cutaneous manifestations associated with COVID-19 in children: A systematic review

Seema Shah<sup>1</sup>, Kiran Akhade<sup>2</sup>, Satyaki Ganguly<sup>3</sup>, Rachita Nanda<sup>4</sup>,  
Eli Mohapatra<sup>5</sup>, Anil Kumar Goel<sup>6</sup>

<sup>1</sup>Assistant Professor, <sup>4</sup>Additional Professor, <sup>5</sup>Professor, Department of Biochemistry, <sup>2</sup>Project Coordinator, SCoE-SAM, State Centre of Excellence, Department of Pediatrics, <sup>3</sup>Associate Professor, Department of Dermatology, <sup>6</sup>Professor, Department of Pediatrics, All India Institute of Medical Sciences, Raipur, Chhattisgarh, India

## ABSTRACT

Cutaneous manifestation of COVID 19 in children has not yet been reviewed systematically. Hence, this review gives the clinicians a future direction to be vigilant for skin presentations during pandemics. The Pubmed database used for literature search with keywords COVID 19, children, and skin in different combinations. Articles published in English with cases of age one month to 18 years were eligible. The outcome included varied aspects of cutaneous and COVID 19 infection. The authors did not register review protocol. Of 51 publications identified, 13 studies containing 149 children met the eligibility criteria. Acraly located erythematous maculopapular lesion was the most common finding in 138 children. The researcher reported Erythema multiforme, varicella like exanthem, and Kawasaki disease like presentations in the rest of the cases. The duration of the skin lesion was 1-2 weeks in 43%. Skin biopsy done in 18 patients revealed superficial and deep perivascular and peri eccrine lymphocytic infiltrate and lymphocytic vasculitis. RT PCR was positive in 13.8% cases. Serological markers for HSV, parvovirus B19 analyzed across various studies, were negative, except positive mycoplasma pneumoniae in 2 of 20 cases tested. Clinicopathologic analysis established chilblains like lesion in 43% cases with no confirmed etiology like cold exposure, autoimmune dysfunction, drug reaction, or viral infection. The usual cephalo caudal spread of a viral exanthem was also missing. However, a low number of discussed cases was a limitation of the study. The absence of any confirmed etiology for such cutaneous manifestations, the possibility of COVID 19, should be explored and thoroughly evaluated and isolated during such a pandemic.

**Keywords:** Chilblain, children, Coronavirus, COVID-19, cutaneous

## Introduction

The ongoing pandemic of COVID-19 started with reporting a group of patients with an unidentified form of viral pneumonia first reported in Wuhan, China, in December 2019. This viral infection predominated with respiratory symptoms, soon

flooded China's whole and later also spread to the rest of the world within a short span, owing to its high infectivity and transmission by asymptomatic individuals. WHO declared this infection as a Public Health Emergency of International Concern on Jan 30, 2020, and later as pandemic on Mar 11, 2020.<sup>[1]</sup> The virus belongs to the family of beta-corona virus lineage B, had more than 80% resemblance to the previously reported SARS-CoV in 2003, and was identified as the novel Coronavirus (CoV). The International Committee on Taxonomy of Viruses (ICTV) named it SARS-CoV-2, and the disease was named COVID-19 by the WHO.<sup>[2]</sup> Coronavirus disease (COVID-19) outbreak situation reports more than 8.3

**Address for correspondence:** Dr. Anil Kumar Goel, Professor & Head, Pediatrics & Pediatric Emergency Medicine, Department of Pediatrics, All India Institute of Medical Sciences, Raipur, Chhattisgarh, India. E-mail: akgoel.paeds@gmail.com

Received: 24-07-2020

Revised: 17-09-2020

Accepted: 14-10-2020

Published: 30-01-2021

### Access this article online

#### Quick Response Code:



Website:  
www.jfmpc.com

DOI:  
10.4103/jfmpc.jfmpc\_1389\_20

This is an open access journal, and articles are distributed under the terms of the Creative Commons Attribution-NonCommercial-ShareAlike 4.0 License, which allows others to remix, tweak, and build upon the work non-commercially, as long as appropriate credit is given and the new creations are licensed under the identical terms.

For reprints contact: WKHLRPMedknow\_reprints@wolterskluwer.com

**How to cite this article:** Shah S, Akhade K, Ganguly S, Nanda R, Mohapatra E, Goel AK. Cutaneous manifestations associated with COVID-19 in children: A systematic review. J Family Med Prim Care 2021;10:93-101.

million confirmed cases with more than 4.5 lakh deaths, affecting more than 216 countries worldwide.<sup>[3]</sup>

The viral S protein (peplomer) of SARS-CoV-2 interacts with angiotensin-converting enzyme 2 (ACE II) receptors present on human cells and enters the host cell. ACE 2 receptors, being most abundant on alveolar type II cells, is the primary site of entry. The respiratory manifestations may present as mild symptoms of flu-like illness or severe category with ARDS and multi-organ failure.<sup>[4]</sup> However, the author reported extra-respiratory involvement of COVID-19 infections in increasing numbers.

Concurrent with the surge of COVID-19 cases, during its peak in different countries, clinicians and dermatologists started reporting a sizable number of patients presenting with a cutaneous lesion, especially in critically ill adult patients and in asymptomatic children.<sup>[5]</sup> Various skin lesions, typically in chilblains like acral lesions, erythema multiforme mimics, and other cutaneous manifestations were noted. All these published articles are in the form of case reports and original articles and not in the form of a systematic review to guide clinicians comprehensively.

This study's primary objective is to systematically review all published literature on a different spectrum of cutaneous manifestation in pediatric patients with COVID-19.

The aim of this review is to summarize the major patterns of dermatological manifestations associated with SARS-CoV-2 virus infection.

Primary care physicians could play a relevant role in the response to the SARS-CoV-2 pandemic with the early recognition of skin lesions suggestive of COVID-19. Skin manifestations may represent a relevant feature of COVID-19, and these lesions may be under recognized because of the lack of routine dermatology consultations during the pandemic. Only patients with severe respiratory symptoms are usually screened for SARS-CoV-2 infection. As a result, it is quite difficult to accurately determine the actual prevalence of the infection.

## Methods

### Protocol and registration

An extensive systematic search was carried out on Medline (via PubMed) database to identify published literature on cutaneous manifestations associated with COVID-19 in pediatric patients, following the recommendations of preferred reporting items for systematic reviews meta-analyses guidelines.<sup>[6,7]</sup> No previously registered review protocol could be located on Prospero. The review protocol could not be registered because of the matter's earnestness and anticipated long holding up period.

Eligibility criteria:

(1) Study population:

- Cutaneous lesion
- Age group >1 month till 18 years of age

- Temporal association (Dec 2019–May 28, 2020; in the same time frame as the peak of COVID-19 in the regions of reported studies)
  - Discussing “COVID-19” in context with cutaneous lesion
- (2) Intervention/Indicators: We included clinical studies discussing cutaneous manifestations in children in context with COVID-19.
- (3) Comparators: There were no limitations on the type of comparators in the studies.
- (4) Outcomes: The outcome of interest was the type of cutaneous lesion, site involved, biopsy findings, RT-PCR status of patients, antibody titer status, contact history with COVID-19 patients, the treatment offered, and any resulting sequelae.
- (5) Study design: Study designs from the selected publications included Case reports, case series, prospective and retrospective cohort studies, case-control study, and clinical trials.
- (6) Language: Studies published in English.
- (7) Publication status: Studies ahead of print as well as already published were both included.

The exclusion criteria to eliminate non-eligible studies were

- (1) Studies that did not report cutaneous manifestations
- (2) Studies that involved neonates or adults
- (3) Review articles, meta-analyses, editorials, and other forms (e.g., commentary and correspondence to included published literature).

### Information Source and Search strategy

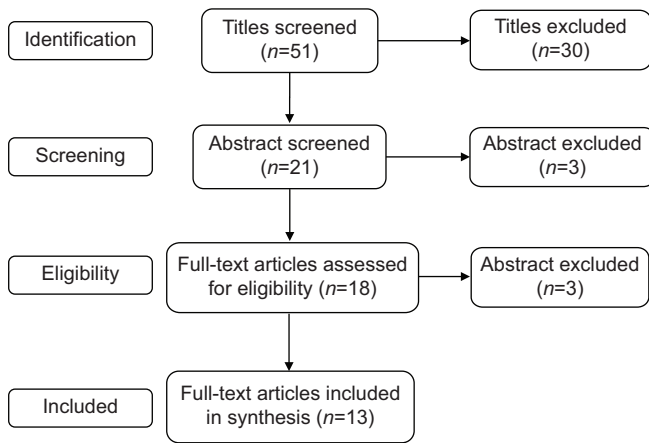
Data search was done on 28/05/2020 at 3:30 PM with key search terms as (Coronavirus OR COVID-19 OR SARS-CoV-2) AND (Paediatrics OR children) AND (skin OR dermatology OR urticaria or cutaneous) in the PubMed database without any selection on the study type. The publication date was chosen to be within the last year, as the first case of COVID-19 was reported towards the end of December 2019.

Study selection:

Our database search results were sent by email to the first two reviewers, and both SS & KA identified and selected the potential literature following the eligibility criteria. Full texts of the eligible studies were obtained. Disagreements were settled by discussion or consensus with the opinion of a third reviewer (AG). The study selection process is shown in Figure 1.

Data collection process and data items:

The data was extracted from selected eligible studies; using a pre-designed datasheet. The extracted records included first authors, site of study, sample size, age, sex, type, and site of skin lesion, skin biopsy findings, coexistent or preceding history of respiratory or other systemic illness, RT-PCR and antibody status



**Figure 1:** The final inclusion of a total of 13 studies from an initial search of 51 studies is depicted in the PRISMA flow diagram

for SARS-COV2, contact history with confirmed or suspected COVID patients, the treatment offered and resulting sequelae if any.

**Risk of bias:** The reviewers assessed the studies independently to reduce the risk of bias, and data extraction sheets were independently prepared by two reviewers and then compiled by a third reviewer by consensus.

**Summary measures and synthesis of results:** The statistical analyses performed using SPSS version 20. Continuous variables are formulated as mean ( $\pm$  standard deviation), while qualitative and epidemiological data were denoted as proportions and percentages.

**Results:** Initial PubMed search with the mentioned keywords identified 51 articles, of which 30 were eliminated at identification stage. Screening of these 21 articles by abstract further eliminated 3 articles.<sup>[8-10]</sup> After applying eligibility criteria, another 5 articles were eliminated.<sup>[11-15]</sup> Thus, a total of 13 articles met the inclusion criteria and were systematically reviewed. Out of that 5 were case series,<sup>[16-20]</sup> 4 were case reports,<sup>[21-24]</sup> and 4 were original studies.<sup>[25-28]</sup> Maximum number of articles were reported from Italy,<sup>[16,19-22,24,26]</sup> followed by Spain,<sup>[17,23,25]</sup> France,<sup>[8]</sup> Turkey,<sup>[28]</sup> and USA.<sup>[27]</sup>

All studies were published during April and May 2020. A total of 149 different patients were analyzed and discussed. The youngest case is of 8 months female baby (28), and the oldest is an 18-year-old male<sup>[19]</sup> with the mean patient age at 11.096 years (SD  $\pm$  4.56 years). Males comprised 85 cases (57%), while females accounted for 64 cases (43%).

Table 1 summarizes cutaneous and systemic features.

Acrally located erythematous to violaceous maculopapular lesion having blurred edges, occasionally with superficial bullae and the focal hemorrhagic crust, was the most common finding in 127 children.<sup>[16,20,24-26]</sup> A similar but larger lesion as erythematous

to purpuric plaques with occasional macules was reported in 11 cases.<sup>[16,19,21,27]</sup> Erythema multiforme like lesion observed in 6 cases, consisted of target and targetoid, confluent macules, papules, and plaques of different sizes, few with bleeding and crust at the center with the involvement of conjunctiva in one and mucous membrane in one patient each.<sup>[17,18,23]</sup> Bilaterally symmetrical varicella like exanthem presented as erythematous papules and vesicles with superficial vesiculation and crust formation, on the trunk, in an 8-year-old female child. However, the limbs, face, genitals, and mucous membranes were spared.<sup>[22]</sup> A generalized exanthematous lesion with palmer edema, cervical lymphadenopathy, glossitis, and desquamation of extremities; Kawasaki disease like presentation, was reported in a 3-year-old male child with negative RT PCR but ground glass consolidation in CT chest suggestive of COVID pneumonia.<sup>[18]</sup> Additionally, Bursal *et al.* reported non-acral erythematous maculopapular rash starting on the face and extending to trunk and extremities in 3 of their COVID positive patients.<sup>[28]</sup>

The lesion site was feet alone in 120 cases, mostly at the dorsal surface of toes and sometimes on the lateral margin of feet. Plantar surface and heel was also involved occasionally, more so in erythema multiforme type lesion. Hands alone were involved in 4 cases, affecting the dorsal surface of fingers and periungual region. The involvement of both hands and feet were reported in 23 cases. Duration of skin lesion (n = 96) was <1 week in 6, 1-2 weeks in 64 (43%), and 2-3 weeks in 4 cases. Further, Andina *et al.* mentioned in their study that 22 children reported a median of 7 days with a range of 1-28 days.<sup>[25]</sup>

Systemic manifestations like fever, upper respiratory tract infection (URI), and Gastro-Intestinal (GI) symptoms were present in 11, 20, and 22 cases, respectively. Upper respiratory tract infection (URI) as mild flu and rhinorrhea while GI symptoms included loss of taste, diarrhea, nausea, and vomiting. URI and GI symptoms together were present in 10 cases. Radiologic evidence of pneumonia was present in 2 patients; both were under five years of age and negative for RT PCR (16, 18). The incubation period varied from less than ten days (n = 10) to 30 days (n = 32) with more than 60 days in a 5-year-old boy having pneumonia but negative RT PCR.<sup>[16]</sup>

Symptomatic treatment with antihistaminic, topical steroid or antibiotic was given in 41, Oral short course steroid in 2 and IV immunoglobulins in one patient with Kawasaki Disease like presentation. No cutaneous sequelae were reported in any study.

Table 2 depicts the histopathology of skin biopsy and other laboratory evaluation.

Skin biopsy done in 18 cases revealed superficial and deep perivascular and peri eccrine lymphocytic infiltrate (18/18), lymphocytic vasculitis (18/18), vacuolar degeneration of basal layer (12/18), mucin deposition at reticular and peri adnexal dermis (6/18), hemorrhagic parakeratosis (6/18), and fibrin thrombus in (2/18) cases.

Table 1: Cutaneous &amp; Systemic Features

| Ref. No | Cases (n) | Sex M/F | Skin lesions  | Site of skin lesion   | Duration of skin lesions (n)         | *History             | Systemic manifestations (n)                      | Duration of systemic illness (n) | Treatment given   |
|---------|-----------|---------|---|---|--------------------------------------|----------------------|--|----------------------------------|---|
| 16      | 4         | 2/2     | Erythematous edematous macules, papules and plaques with blurred edges and a central cyanotic area with Pruritus in (n=1) and mild pain in (n=3)  | Feet: 4/4   | 2-3 weeks (2)<br>NR (2)              | NR                   | Fever (3), URI (1),<br>Pneumonia (1)<br>None (1) | <10 days (2)<br>> 2 months in 1  | No Rx: 3/4<br>Systematic antibiotic 1/4   |
| 25      | 22        | 13/9    | Erythematous to purpuric macules and violaceous swellings with Pruritus (n=9) and mild pain (n=7)   | Feet: 19/22<br>Both: 3/22   | 1-28 days (22)<br>(median 7 days)    | None 22/22           | URI (9/22) GI (2/22), both (10/22)               | 1-28 days (median 14 days)       | No Rx: 20/22<br>(Analgesics + Antihistamines + Topical steroid) 1/22 Oral short course steroid 1/22 |
| 21      | 1         | 1/0     | Erythematous edematous, partially eroded, macules and plaques- asymptomatic lesion  | Both :1/1   | 2-3 weeks (1)                        | None 1/1             | GI (1)   | >20 days                         | NR  |
| 26      | 63        | 30/33   | Erythematous-edematous lesions 31/54 and blistering lesions in 23/54, Pain 17/63, itching 17/63, Both 13/63. Asymptomatic lesions 16/63   | Feet 54/63<br>Hands 4/63<br>Both: 5/63  | 1-2 week (63)                        | 6/63 history present | Fever (4/63)<br>URI (5/63)<br>GI (7/63)          | NR                               | NR  |
| 27      | 6         | 5/1     | Red to violaceous macules, plaques with superficial bullae, focal hemorrhagic crust, Reticulated erythema. Pruritus and mild pain in all cases  | Both: 6/6<br>Forearm: 6   | NR (6)                               | None 6/6             | Fever (2/6)<br>URI (2/6)                         | <10 days (6)                     | NR  |
| 17      | 4         | 3/1     | Erythema multiforme like target (three rings) and targetoid (two rings), confluent macules, papules and plaques of different sizes, some with bleeding or crust at the centre. Pruritus 3/4, mild pain 1/4  | Both: 4/4, Elbow: 4/4, Knee: 4/4<br>Ankles: 3/4<br>Forearms: 3/4<br>Ears :1/4 Thigh: 1/4<br>Arms :1/4 | NR (4)                               | NR                   | URI (2)<br>GI (1)<br>None (1)                    | NR                               | No Tt: 2/4<br>Topical steroid ¼<br>Oral steroid ¼   |
| 22      | 1         | 0/1     | Diagnosed as Viral exanthema, Erythematous papules and few vesicles scattered bilaterally and symmetrically on the trunk. The lesion had superficial vesiculation leading to crust formation.   | Trunk only<br>Limbs & mucous membranes were spared.   | <1 week (1)                          | NR                   | URI (1)  | <10 days (1)                     | NR  |
| 23      | 1         | 1/0     | Erythema Multiforme like lesion with hemorrhagic purpuric eruption and vesicular blisters with itching  | Feet 1/1  | <1 week (1)                          | NR                   | None (1),  | None                             | NR  |
| 18      | 2         | 2/0     | Case1: Erythema Multiforme like presentation with severe erosive cheilitis, diffuse gingival erosions, bilateral conjunctivitis and multiple target lesions.<br>Case 2: Generalized exanthema, bilateral palmar edema, glossitis, and cervical lymphadenopathy and desquamation of the extremities, diagnosed as Kawasaki disease | Case1: Both hands & feet, conjunctiva, lips & gums<br>Case 2: Whole body, palm and tongue             | Case1: <1 week (1)<br>Case 2: NR (1) | NR                   | Fever (1)<br>GI (1)<br>Pneumonia (1)             | <10 days (1)                     | Case1: No Rx<br>Case2: IV Ig  |

Contd...

Table 1: Contd...

| Ref. No | Cases (n) | Sex M/F | Skin lesions   | Site of skin lesion               | Duration of skin lesions (n)            | *History | Systemic manifestations (n) | Duration of systemic illness (n) | Treatment given                            |
|---------|-----------|---------|--|-----------------------------------|---|----------|-----------------------------|----------------------------------|--|
| 19      | 3         | 3/0     | Erythematous violaceous macules and papules, some with blisters and necrotic lesions with pain and itching in some   | Feet 3/3                          | 2-3 weeks (1)<br>1-2 week (1)<br>NR (1) | NR       | Fever (2),<br>None (1)      | NR                               | NR   |
| 28      | 3         | 0/3     | Erythematous macula popular skin rash with pruritus  | Face 3/3<br>Both 3/3<br>Trunk 3/3 | <1 week (3/3)                           | NR       | Fever (1)<br>NR (2)         | NR                               | NR   |
| 24      | 1         | 0/1     | Erythematous ulcerative chilblain-like lesions with dyschromia of the nails; with pain and itching. The lack of finger pressure clearing of the erythematous lesions suggests that the vasculitis to be of ischemic hemorrhagic nature. Pain and itching | Feet 1/1                          | NR (1)                                  | None 1/1 | None (1)                    | NR                               | NR   |
| 20      | 38        | 25/13   | Red bluish erythematous patches with vesiculo-bullous swelling and erosion   | Feet 38/38                        | NR (38)                                 | NR       | NR                          | NR                               | Topical steroid and antibiotic cream 38/38 |

Both: both hands and feet; NR: Not reported, No: absent. \*History: History of autoimmune disorders, Raynaud's phenomenon, recent addition of new drug or dosage, previous chilblain or familial chilblain, acrocyanosis

In terms of COVID-19 diagnosis, 13/94 were positive for RT PCR, and the antibody was positive in 3/14 cases. Complete blood count (n = 43), LFT and RFT (n = 35) did not reveal any abnormality. Viral markers (Parvovirus B19, HSV, CMV, EBV, Measles, Rubella, HIV, Hepatitis B and C, Enterovirus) analyzed across various studies were negative. Serology for mycoplasma pneumoniae was positive in 2 of 20 cases.<sup>[26,27]</sup>

## Discussion

This systematic review describes cutaneous manifestations, histopathologic and laboratory evaluation along with the possibility of a causal association with COVID-19 in terms of either positive RT PCR or history of contact with suspected or confirmed COVID-19 patients. All the included studies reported a surge in children seeking dermatology consultations in the same time frame as the peak of COVID-19 infection in their respective regions.

SARS-CoV-2, the causative agent of COVID-19, enters host cells via ACE II and the transmembrane serine protease 2 (TMPRSS2) receptors co-expressed in type II alveolar cells of the lungs, upper epithelial and gland cells of the esophagus, and enterocytes of the ileum and colon.<sup>[29]</sup> The common presenting feature is mild flu in the majority of cases, followed by GI symptoms.<sup>[30]</sup> Atypical presentations at the forefront, like cutaneous lesions, neurological abnormalities, anosmia, ocular involvement, and venous thromboembolism, are frequent.<sup>[5,31-34]</sup> We found systemic manifestations in 65 cases (43.6%) as described.

The varied cutaneous presentations, histopathological findings, and other details are tabulated in Table 3.

The majority of the children showed erythematous maculopapular eruptions, which is generally the most typical cutaneous presentation in any viral illness. However, a closer look in our study subjects throws up several contradicting observations. Instead of general cephalocaudal distribution in any viral exanthem, the cases manifested at the acral region of feet and hands. The maculopapular viral exanthem always heals with exfoliation, but most of our study population showed secondary changes like erosion, vesiculation, and crusting. These unusual accompaniments may be used as a clue to suspect COVID-19 association specifically, in the absence of usual causative agents.

Acral chilblain-like lesion, instead an unusual feature during the months of March-May, when the temperature was not unbearably cold or humid, a prerequisite for developing chilblains advocates possible association of coronavirus infection. Negative history for autoimmune disorders, Raynaud's phenomenon, familial chilblains, and absent immune-reactants in skin biopsy further excludes the possibility of secondary causes of chilblains.

No significant drug history refutes the possibility of a drug-induced skin lesion in most children; however, temporal co-relation with HCQ was argued in one patient where lesion appeared after starting HCQ and subsided after its withdrawal.

A standard coagulation profile ruled out disseminated intravascular coagulation or coagulation derangements as a cause for the cutaneous features instead of a prevalent procoagulant state reported in the acral ischemic lesion in adults.<sup>[35]</sup>

Table 2: Histopathology &amp; Laboratory Evaluation

| Ref. No. | RT PCR test        | **Ab    | Contact history       | Skin Biopsy (n=18)   | Routine Blood test (CBC, LFT, KFT, ANA) | Coagulation profile | CRP, Ferritin Fibrinogen IL6 | d Dimer (<500 µg/L normal range) |
|----------|--------------------|---------|-----------------------|--|---|---------------------|------------------------------|----------------------------------|
| 16       | -ve 4/4            | NR      | SC: 4/4               | Lymphocytic perivascular and peri adnexal infiltration with signs of vasculitis and fibrin thrombus in superficial capillaries 2/2   | Thrombocytosis & monocytosis 1/4        | N 4/4               | N (4/4)                      | 1/1: 723 µg/L                    |
| 25       | +ve 1/19           | NR      | CC: 1/22<br>SC: 12/22 | Lymphocytic vasculopathy, superficial and deep angiocentric and eccrinotropic lymphocytic infiltration, papillary dermal edema, vacuolar degeneration of the basal layer 6/6   | N: 22/22                                | N 18                | NR                           | 1/16 high (900 ng/ml)            |
| 21       | +ve 1/1            | NR      | CC: 1/1               | Superficial and deep lymphocytic infiltrate in a perivascular and peri eccrine pattern, no endothelial damage 1/1  | ANA + ve1<br>Cryoglobulin present 1     | N1                  | NR                           | NR                               |
| 26       | +ve 2/11           | +ve 2/6 | CC: 2/63<br>SC: 8/63  | NR   | ANA+ve in 1/22                          | N 22                | N 22                         | NR                               |
| 27       | -ve 6/6            | -ve 6/6 | SC: 6/6               | Superficial and deep lymphocytic infiltrate, perivascular and peri eccrine distribution, Mucin deposition in both the reticular and peri adnexal dermis. Hemorrhagic parakeratosis at stratum corneum. Direct immunofluorescence was negative for immunoreactant deposition 6/6  | NR                                      | NR                  | NR                           | NR                               |
| §17      | +ve 1/4            | NR      | SC: 1/4<br>NC: 3/4    | 2/2; A superficial and deep perivascular and peri eccrine lymphocytic infiltrate with lymphocytic vasculitis and vascular ectasia, epidermis spared, no eosinophils were seen in the infiltrate. fibrinoid necrosis and thrombosis absent. Necrotic keratinocytes also absent in both samples. IHC positive for SARS-CoV-2 spike protein | N: 2/2                                  | N 3/3               | NR                           | 2/2 N                            |
| 22       | +ve 1/1            | NR      | CC: 1/1               | NR   | Thrombocytopenia 1/1                    | NR                  | N 1 (CRP)                    | NR                               |
| #23      | -ve 1/1            | -ve 1/1 | NC: 1/1               | Partial epidermal necrosis and perivascular lymphoid infiltrate in superficial and deep dermis, capillaries in papillary dermis had microthrombi, with extravasation of RBC. Vasculitis changes were present in relation to the lymphoid component but not in the thrombotic one.  | N: 1/1                                  | NR                  | N 1 (CRP)                    | NR                               |
| 18       | +ve 1/1<br>-ve 1/1 | NR      | CC: 1/2<br>SC: 1/2    | NR   | N: 2/2                                  | NR                  | High CRP<br>High TLC         | NR                               |
| 19       | +ve 3              | NR      | CC: 2/3<br>NC: 1/3    | NR   | NR                                      | NR                  | NR                           | NR                               |
| 28       | +ve 3              | NR      | NC :3/3               | NR   | NR                                      | NR                  | NR                           | NR                               |
| 24       | -ve                | +ve     | NR                    | NR   | N: 1/1                                  | N                   | C3, C4, IL6                  | N                                |
| 20       | -ve                | NR      | NR                    | NR   | NR                                      | NR                  | NR                           | NR                               |

NR: Not reported, SC: Suspected Covid, CC: RT PCR Confirmed Covid, NC: No contact, N: Normal, Ab: SARS-COV antibody. <sup>§</sup>Immunohistochemical stain with Ab against SARS-CoV/SARS-CoV-2 spike protein showed granular positivity in endothelial cells and epithelial cells of eccrine glands (2/2), but both -ve for RT PCR. \* Viral markers were done for CMV, EBV, parvovirus B19 in 21 cases and were found negative. Serology for mycoplasma pneumoniae done in 20 cases but was positive in 2 cases only. <sup>†</sup> HSV, measles, rubella, parotitis, HIV and hepatitis B and C, enterovirus were done in and all found negative

In a substantial number of the described patients, negative viral serology for Herpes Simplex Virus and Mycoplasma pneumoniae, the most common causes for erythema multiforme, suggests the COVID-19 associated pathogenesis in these cases. Similarly, the presence of negative viral markers for Parvovirus B19, CMV, and EBV, among others, eliminates the possibility of these usual viruses as a causative factor for viral exanthema

and viral skin lesions. Additionally, a normal complete blood count excluded the likelihood of any hematologic etiology in the majority of cases.

The exact mechanism of cutaneous involvement in COVID-19 is not precise, but the pathogenesis probably involves high interferon. Viral infection causes the release of type I interferon, which

**Table 3: Pattern of Skin lesions with different characteristics**

| Type  | Acral Chilblain like lesion (n=138) (79M/59F)   | Erythema multiforme (n=6) (5M/1F)   | Varicella like exanthema (n=1) (1F)  | Kawasaki disease like presentation (n=1) (1M)  | Non acral erythematous maculopapular rash (n=3)  |
|---|---|---|--|--|--|
| Reference   | [16],[19],[20],[21],[24],[25],[26],[27]   | [17], [18], [23]  | [22]   | [18]   | [28]   |
| Skin lesion   | Erythematous, violaceous or purpuric macules, papules and plaques with blurred edges, few with superficial bullae and focal hemorrhagic crust   | Target (3 rings) and targetoid (2 rings), confluent macules, papules and plaques of different sizes, some with bleeding or crust at centre.   | Erythematous papules and few vesicles with superficial vesiculation and crust formation. | Generalized exanthema with desquamation, palmar edema, glossitis and cervical lymphadenopathy. | Erythematous maculopapular rash with pruritus  |
| Site involved                                       | Feet: 120, Hands: 4, *Both: 15, Forearm :10   | Feet: 1, ¶Both: 5, Elbow: 4<br>Knees: 4, Forearms: 3<br>Ankles: 3/6 cases<br>Ears :1, Conjunctiva: 1,<br>Lips: 1/6 case   | Trunk only (bilaterally symmetrical)<br>Mucous membranes spared.                         | Whole body, palm and tongue  | HCQ received (n=3), Rash starting on face and then extended to extremities and trunk after HCQ (n=1), Face: 3/3.*Both: 3/3, Trunk: 3/3 |
| Duration of skin lesion                             | <1 week: 1, 1-2 weeks :65<br>2-3 weeks: 7, NR: 44   | <1 week: 2<br>NR: 4   | <1 week :1/1   | NR   | <1 week: 3   |
| Skin biopsy   | Superficial and deep perivascular and peri eccrine lymphocytic infiltrate (15/15), Lymphocytic vasculitis with endothelial cell swelling and RBC extravasation (14/15), Vacuolar degeneration of basal layer (12/15), Mucin deposition at reticular and peri adnexal dermis (6/15), Hemorrhagic parakeratosis at stratum corneum (6/15), Fibrin thrombus (2/15)<br>Direct immunofluorescence was negative for immunoreactant deposition (6/6) | Superficial and deep perivascular and peri eccrine lymphocytic infiltrate 3/3, Lymphocytic vasculitis 3/3, Partial epidermal necrosis in 1/3, No eosinophils in the infiltrate, no fibrinoid necrosis and no thrombosis.<br>IHC stain with Ab against SARS-CoV-2 spike protein showed granular positivity in endothelial and epithelial cells of eccrine glands in 2 cases, though both are PCR negative for SARS CoV2. | NR   | NR   | NR   |
| History of Autoimmune dis./Raynauds phenomenon/Drug | Present 6/87- (Autoimmune dis.)   | NR  | NR   | NR   | NR   |
| RT PCR  | +ve 7/87  | +ve 2/6   | +ve 1/1  | +ve 1/1  | +ve 3/3  |
| Contact history                                     | CC: 6/85<br>SC: 30/85<br>NC: 49/85  | SC: 2/6<br>NC: 4/6  | CC: 1/1  | NC: 1/1  | NC: 3/3  |
| Systemic illness                                    | Fever 11, URI 20, GI 11, Both 10<br>Pneumonia 1   | URI 3, GI 1   | URI  | Fever: 1<br>Pneumonia: 1   | Fever: 1<br>NR: 2  |
| Duration of Systemic illness                        | 1-4 weeks: 30 (median 14 days) >2 months: Pt having pneumonia   | NR  | 6 days   | <10 days -1  | NR   |

CC; Confirm contact. SC: suspected contact, NC: No contact, NR: Not reported, \*Both: both hands and feet

activates the JAK-STAT signaling pathway, resulting in increased expression of genes, which inhibits viral proliferation and helps eliminate virus and immunity against viral disease.<sup>[36]</sup> Chilblain-like lesions has been reported in patients with high type I interferon.<sup>[37]</sup> So, there is a possibility that these children had high IFN initially, which helped in the early elimination of the virus and development of skin lesions in the convalescent phase. It is proposed that erythema multiforme type lesion in COVID-19 occurs secondary to activation of the complement pathway in a setting of prevailing procoagulant state, causing thrombogenic vasculopathy.<sup>[38]</sup>

The low positivity rate for RT-PCR (13.8%) can be explained in terms of faster clearance of virus from the nasopharyngeal site in children, a lower viral load, false-negative test reports, or delayed development of cutaneous lesions in the late convalescent phase by which the children might have eliminated the virus. Serological testing in these cases can confirm previous infections, but the sensitivity and specificity of the available tests are yet to be validated. The fact that immune histochemical staining (IHC) with Ab against SARS-CoV/SARS-CoV-2 spike protein was positive in 2/2 cases, with negative RT PCR reports, advocates a definite causal role of

SARS-CoV-2.<sup>[17]</sup> Limitations of the study: The study sample is less looking at the disease's pandemic nature to give any concrete comment on the path physiology and pattern of presentation of the disease process. Strength of the study: The author has tried to screen all published data with all possible keywords and analyzed the available literature on a case-to-case basis.

## Conclusion

In the setting of prevalent COVID-19 infection, in the absence of any confirmed etiology for the cutaneous involvement, a good association of cutaneous manifestations with COVID-19 can be argued. The fact that IHC stain was positive in skin biopsy in patients with negative RT PCR establishes the possible presence of COVID-19 infection. Nonetheless, in the absence of case reports from this subcontinent, with the pandemic continuing, this review will help clinicians to look for COVID-19 association in unexplained dermatologic presentations and advocate early isolation of the patient to eliminate the threat of cross-infection or spread to fellow patients.

Summary: This systematic review describes cutaneous manifestations, histopathologic and laboratory evaluation along with the possibility of a causal association with COVID-19 in terms of either positive RT PCR or history of contact with suspected or confirmed COVID-19 patients. All the included studies reported a surge in children seeking dermatology consultations in the same time frame as the peak of COVID-19 infection in their respective regions.

## Acknowledgements

The authors would like to thank Dr. Rahul Satarkar, Associate Professor Pathology at SHKM GMC Mewat, India, for his critical analysis of the biopsy result.

Author contributions: SS conceived, designed the study and prepared the manuscript. KA and RN retrieved and analyzed the data. SG helped in data extraction, analysis, and interpretation of the data. EM & AG revised the manuscript critically. All authors approved the final manuscript.

## Research quality and ethics statement

This manuscript's authors declare that this scientific work complies with reporting quality, formatting, and reproducibility guidelines set forth by the EQUATOR Network (PRISMA Guidelines for systematic review). The authors also attest that this clinical investigation was not determined to require the Institutional Review Board/Ethics Committee review, and the corresponding protocol/approval number is not applicable. We also certify that we have not plagiarized the contents in this submission and have done a Plagiarism Check.

## Key message

This review will help clinicians to look for COVID-19 association, in unexplained dermatologic presentations and advocates early

isolation of the patient to eliminate the threat of cross-infection or spread to fellow patients.

## Financial support and sponsorship

Nil.

## Conflicts of interest

There are no conflicts of interest.

## References

1. WHO Rolling updates on coronavirus disease (Covid-19). Updated 19/06/2020. Available from: <https://www.who.int/emergencies/diseases/novel-coronavirus-2019/events-as-they-happen>. [Last accessed on 2020 Jun 19].
2. Gorbalenya AE, Baker SC, Baric RS, deGroot RJ, Drosten C, Gulyaeva AA, *et al.* The species Severe acute respiratory syndrome-related coronavirus: Classifying 2019-nCoV and naming it SARS-CoV-2. *Nat Microbiol* 2020;5:536-44.
3. WHO Coronavirus Disease (COVID-19) Dashboard Data last updated: 2020/6/19, 05:30GMT+5:30. Available from: <https://www.who.int/emergencies/diseases/novel-coronavirus-2019>. [Last accessed on 2020 Jun 19].
4. Yuki K, Fujiogi M, Koutsogiannaki S. COVID-19 pathophysiology: A review. *Clin Immunol* 2020;215:108427. doi: 10.1016/j.clim. 2020.108427. Epub ahead of print. PMID: 32325252; PMCID: PMC7169933.
5. Recalcati S. Cutaneous manifestations in COVID-19: A first perspective. *J Eur Acad Dermatol Venereol* 2020;34:e212-3.
6. Hutton B, Salanti G, Caldwell DM, Chaimani A, Schmid CH, Cameron C, *et al.* The PRISMA extension statement for reporting of systematic reviews incorporating network meta-analyses of health care interventions: Checklist and explanations. *Ann Intern Med* 2015;162:777-84.
7. Liberati A, Altman DG, Tetzlaff J, Mulrow C, Gøtzsche PC, Ioannidis JPA, *et al.* The PRISMA statement for reporting systematic reviews and meta-analyses of studies that evaluate healthcare interventions: Explanation and elaboration. *BMJ* 2009;339:b2700.
8. Boscia C. Skin-to-skin care and COVID-19. *Pediatrics* 2020;e20201836. doi: 10.1542/peds. 2020-1836.
9. Wolf GK, Glueck T, Huebner J, Muenchhoff M, Hoffmann D, French LE, *et al.* Clinical and epidemiological features of a family cluster of symptomatic and asymptomatic severe acute respiratory syndrome coronavirus 2 infection. *J Pediatr Infect Dis Soc*, p1aa060, doi: 10.1093/jpids/p1aa060.
10. Joob B, Wiwanitkit V. Chilblains-like lesions and COVID-19. *Pediatr Dermatol* 2020. doi: 10.1111/pde. 14238.
11. Recalcati S, Barbagallo T, Frasin LA, Prestinari F, Cogliardi A, Provero MC, *et al.* Acral cutaneous lesions in the time of COVID-19. *J Eur Acad Dermatol Venereol* 2020;34:e346-7.
12. Diotallevi F, Campanati A, Bianchelli T, Bobyr I, Luchetti MM, Marconi B, *et al.* Skin involvement in SARS-CoV-2 infection: Case series. *J Med Virol* 2020;10.1002/jmv. 26012. doi: 10.1002/jmv. 26012.
13. Kolivras A, Dehavay F, Delplace D, Feoli F, Meiers I, Milone L, *et al.* Coronavirus (COVID-19) infection-induced chilblains: A case report with histopathologic findings. *JAAD Case Rep* 2020;6:489-92.
14. Docampo-Simón A, Sánchez-Pujol M, Juan-Carpena G,



- Palazón-Cabanes J, Vergara-De Caso E, Berbegal L, *et al.* Are chilblain-like acral skin lesions really indicative of COVID-19? A prospective study and literature review. *J Eur Acad Dermatol Venereol* 2020. doi: 10.1111/jdv.16665.
15. Lai CC, Ko WC, Lee PI, Jean SS, Hsueh PR. Extra-respiratory manifestations of COVID-19. *Int J Antimicrob Agents* 2020;56:106024. doi: 10.1016/j.ijantimicag. 2020.106024.
  16. Colonna C, Monzani NA, Rocchi A, Gianotti R, Boggio F, Gelmetti C. Chilblain-like lesions in children following suspected COVID-19 infection. *Pediatr Dermatol* 2020;37:437-40.
  17. Torrelo A, Andina D, Santonja C, Noguera-Morel L, Bascuas-Arribas M, Gaitero-Tristán J, *et al.* Erythema multiforme-like lesions in children and COVID-19. *Pediatr Dermatol* 2020;37:442-6.
  18. Labé P, Ly A, Sin C, Nasser M, Chapelon-Fromont E, Ben Saïd P, *et al.* Erythema multiforme and Kawasaki disease associated with COVID-19 infection in children. *J Eur Acad Dermatol Venereol* 2020;34:e539-41.
  19. Guarneri C, Rullo EV, Pavone P, Berretta M, Ceccarelli M, Natale A, *et al.* Silent COVID-19: What your skin can reveal. *Lancet Infect Dis* 2020. doi: 10.1016/S1473-3099 (20) 30402-3.
  20. Mastrolonardo M, Romita P, Bonifazi E, Giuffrida R, Lotti T, Foti C, *et al.* The management of the outbreak of acral skin manifestations in asymptomatic children during COVID-19 era. *Dermatol Ther* 2020;e13617. doi: 10.1111/dth. 13617.
  21. Locatelli AG, Robustelli Test E, Vezzoli P, Carugno A, Moggio E, Consonni L, *et al.* Histologic features of long lasting chilblain-like lesions in a pediatric COVID-19 patient. *J Eur Acad Dermatol Venereol* 2020;34:e365-8.
  22. Genovese G, Colonna C, Marzano AV. Varicella-like exanthem associated with COVID-19 in an 8-year-old girl: A diagnostic clue? *Pediatr Dermatol* 2020;37:435-6.
  23. García-Gil MF, García García M, Monte Serrano J, Prieto-Torres L, Ara-Martín M. Acral purpuric lesions (Erythema multiforme type) associated with thrombotic vasculopathy in a child during the COVID-19 pandemic. *J Eur Acad Dermatol Venereol* 2020;10.1111/jdv. 16644. doi: 10.1111/jdv. 16644.
  24. Papa A, Salzano AM, Di Dato MT, Varrassi G. Images in practice: Painful cutaneous vasculitis in a SARS-Cov-2 IgG-positive child. *Pain Ther* 2020. doi: 10.1007/s40122-020-00174-4.
  25. Andina D, Noguera-Morel L, Bascuas-Arribas M, Gaitero-Tristán J, Alonso-Cadenas JA, Escalada-Pellitero S, *et al.* Chilblains in children in the setting of COVID-19 pandemic. *Pediatr Dermatol* 2020;37:406-11.
  26. Piccolo V, Neri I, Filippeschi C, Oranges T, Argenziano G, Battarra VC, *et al.* Chilblain-like lesions during COVID-19 epidemic: A preliminary study on 63 patients. *J Eur Acad Dermatol Venereol* 2020;34:e291-3.
  27. Cordoro KM, Reynolds SD, Wattier R, McCalmont TH. Clustered cases of acral perniosis: Clinical features, histopathology and relationship to COVID-19. *Pediatr Dermatol* 2020;10.1111/pde. 14227. doi: 10.1111/pde. 14227.
  28. Bursal Duramaz B, Yozgat CY, Yozgat Y, Turel O. Appearance of skin rash in pediatric patients with COVID-19: Three case presentations. *Dermatol Ther* 2020;e13594. doi: 10.1111/dth. 13594.
  29. Zhang H, Kang Z, Gong H, Xu D, Wang J, Li Z, *et al.* Digestive system is a potential route of COVID-19: An analysis of single-cell coexpression pattern of key proteins in viral entry process. *Gut* 2020;69:1010-8.
  30. Zhou F, Yu T, Du R, Fan G, Liu Y, Liu Z. Clinical course and risk factors for mortality of adult inpatients with COVID-19 in Wuhan, China: A retrospective cohort study. *Lancet* 2020;395:1054-62.
  31. Mao L, Jin H, Wang M, Hu Y, Chen S, He Q. Neurologic manifestations of hospitalized patients with coronavirus disease 2019 in Wuhan, China. *JAMA Neurol* 2020. doi: 10.1001/jamaneurol. 2020.1127.
  32. Giacomelli A, Pezzati L, Conti F, Bernacchia D, Siano M, Oreni L. Self-reported olfactory and taste disorders in SARS-CoV-2 patients: A cross-sectional study. *Clin Infect Dis* 2020;71:889-90.
  33. Wu P, Duan F, Luo C, Liu Q, Qu X, Liang L, *et al.* Characteristics of ocular findings of patients with Coronavirus disease 2019 (COVID-19) in Hubei Province, China. *JAMA Ophthalmol* 2020;138:575-8.
  34. Chibane S, Gibeau G, Poulin F, Tessier P, Goulet M, Carrier M, *et al.* Hyperacute multi-organ thromboembolic storm in COVID-19: A case report. *J Thromb Thrombolysis* 2020;1-4. doi: 10.1007/s11239-020-02173-w. Epub ahead of print. PMID: 32506364; PMCID: PMC7275659.
  35. Zhang Y, Cao W, Xiao M, Li YJ, Yang Y, Zhao J, *et al.* Clinical and coagulation characteristics of 7 patients with critical COVID-2019 pneumonia and acro-ischemia. *Zhonghua Xue Ye Xue Za Zhi* 2020;41:E006.
  36. Ivashkiv LB, Donlin LT. Regulation of type I interferon responses. *Nat Rev Immunol* 2014;14:36-49.
  37. Fiehn C. Familial Chilblain lupus-What can we learn from type I interferonopathies? *Curr Rheumatol Rep* 2017;19:61.
  38. Magro C, Mulvey JJ, Berlin D, Nuovo G, Salvatore S, Harp J, *et al.* Complement associated microvascular injury and thrombosis in the pathogenesis of severe COVID-19 infection: A report of five cases. *Transl Res* 2020;220:1-13.