

# Repair of Symptomatic Partial Gluteus Medius Tear During Total Hip Arthroplasty Through the Direct Anterior Approach



David R. Maldonado, M.D., Samantha C. Diulus, B.S., Mitchell B. Meghpara, M.D., Rachel M. Glein, B.S., Hari K. Ankem, M.D., Ajay C. Lall, M.D., M.S., and Benjamin G. Domb, M.D.

**Abstract:** Gluteus medius (GM) tears are a well-established source of pain and disability. Considering previous studies, which have reported rates of incidental GM tears in 20% of patients undergoing primary total hip arthroplasty (THA) and a 3-fold greater rate in elderly female patients, additional focus should be placed on identifying treatment options. The direct anterior approach (DAA) for primary THA has gained popularity within the past few years. However, there has been a paucity in the literature on how to address symptomatic and partial GM tears through this approach. The purpose of this Technical Note is to describe a method to repair partial GM tears during primary THA using the DAA.

Total hip arthroplasty (THA) for end-stage osteoarthritis is one of the most successful orthopaedic procedures, with excellent long-term outcomes in the literature. The gluteus medius (GM) and minimus muscle–tendon complex is critical for gait and hip joint stability, and tears involving these muscles are currently

a well-established source of pain and disability. Incidental GM tears have been reported in 20% of patients undergoing primary THA, with a 3-fold greater rate in elderly female patients. The posterior approach is the most popular approach in THA. Because of the excellent exposure and visualization, regardless of the size of

*From the American Hip Institute, Chicago (A.C.L., B.G.D.); American Hip Institute Research Foundation, Chicago (D.R.M., S.C.D., M.B.M., R.M.G., H.K.A., A.C.L., B.G.D.); and AMITA Health St. Alexius Medical Center, Hoffman Estates (M.B.M., A.C.L., B.G.D.), Illinois, U.S.A.*

*The authors report the following potential conflicts of interest or sources of funding: B.G.D. reports grants and other from American Orthopedic Foundation, during the conduct of the study; personal fees from Adventist Hinsdale Hospital; personal fees and nonfinancial support from Amplitude; grants, personal fees, and nonfinancial support from Arthrex; personal fees and nonfinancial support from DJO Global; grants from the Kaufman Foundation; grants, personal fees, and nonfinancial support, from Medacta; grants, personal fees, nonfinancial support, and other from Pacira Pharmaceuticals; grants, personal fees, nonfinancial support, and other from Stryker; grants from Breg; personal fees from Orthomerica; grants, personal fees, nonfinancial support, and other from Mako Surgical Corp; grants and nonfinancial support from Midwest Associates; grants from ATI Physical Therapy, grants, personal fees, and nonfinancial support from St. Alexius Medical Center; and grants from Ossur, outside the submitted work. In addition, he has a patent 8920497 - Method and instrumentation for acetabular labrum reconstruction with royalties paid to Arthrex, a patent 8708941 - Adjustable multi-component hip orthosis with royalties paid to Orthomerica and DJO Global, and a patent 9737292 - Knotless suture anchors and methods of tissue repair, with royalties paid to Arthrex, and is the Medical Director of Hip Preservation at St. Alexius Medical Center, the Clinical Instructor at the University of Illinois College of Medicine, a board member for the American Hip Institute Research Foundation, AANA Learning Center Committee, the Journal of Hip Preservation Surgery, the Journal of Arthroscopy, He has HAD ownership interests in*

*the American Hip Institute, Hinsdale Orthopedic Associates, Hinsdale Orthopedic Imaging, SCD#3, North Shore Surgical Suites, and Munster Specialty Surgery Center. A.C.L. reports grants, personal fees, and nonfinancial support from Arthrex; nonfinancial support from Iroko; nonfinancial support from Midwest; nonfinancial support from Smith & Nephew; grants and nonfinancial support from Stryker; nonfinancial support from Vericel; nonfinancial support from Zimmer Biomet; and personal fees from Graymont Medical, outside the submitted work, and is the Co-Medical Director of Hip Preservation at St. Alexius Medical Center, the Clinical Instructor at the University of Illinois College of Medicine, and member of the AANA Learning Center Committee. D.R.M. reports nonfinancial support from Arthrex; nonfinancial support from Stryker; nonfinancial support from Smith & Nephew; and nonfinancial support from Ossur, outside the submitted work, and is an editorial board member of the Journal of Arthroscopy. M.B.M. reports nonfinancial support from Smith & Nephew; nonfinancial support from Stryker; and nonfinancial support from Arthrex, outside the submitted work. Full ICMJE author disclosure forms are available for this article online, as [supplementary material](#).*

*Received August 24, 2020; accepted October 21, 2020.*

*Address correspondence to Dr. Benjamin G. Domb, 999 M.D., E Touhy Ave., Suite 450, Des Plaines, IL 60018. E-mail: [DrDomb@americanhipinstitute.org](mailto:DrDomb@americanhipinstitute.org)*

*© 2020 by the Arthroscopy Association of North America. Published by Elsevier. This is an open access article under the CC BY-NC-ND license (<http://creativecommons.org/licenses/by-nc-nd/4.0/>).*

*2212-6287/201464*

*<https://doi.org/10.1016/j.eats.2020.10.043>*

the GM tear, this approach is an ideal alternative when both pathologies need to be addressed.

Nonetheless, the direct anterior approach (DAA) has gained popularity in recent years for THA<sup>1,2</sup>; however, it has been questioned whether an efficacious GM tear repair is reproducible using the DAA.<sup>3</sup> There are several patterns of GM tearing.<sup>4</sup> Although the DAA is perhaps not the best option for large and retracted full-thickness GM tears, it can be used effectively for partial-thickness GM tears, preserving the DAA advantages in primary THA surgery.<sup>5,6</sup> We present a description on how to address partial GM tears through the DAA with the traction table,<sup>2</sup> using the suture-staple and trans-tendinous techniques.<sup>7,8</sup> Potential indications and contraindications are listed in Table 1. Furthermore, advantages and disadvantages are presented in Table 2.

This study was performed in accordance with the ethical standards in the 1964 Declaration of Helsinki. This study was carried out in accordance with relevant regulations of the US Health Insurance Portability and Accountability Act (HIPAA). Details that might disclose the identity of the subjects under study have been omitted.

### Surgical Technique (With Video Illustration)

#### Patient Positioning

It is the authors' preference to use general anesthesia. The patient is placed in the supine position on the Hana table (Mizuho OSI, Union City, CA). The patient is then slid down against a padded perineal post. Both legs are placed in neutral rotation.

#### Direct Anterior Approach

There is no modification to the DAA when a partial GM tear is part of the surgical plan. By using the anterior superior iliac spine as an anatomic landmark, a longitudinal and slightly oblique incision is marked 3 cm distal and 3 cm lateral from this point (Fig 1). Once the skin and subcutaneous tissue is incised, the fascia of the tensor fascia lata (TFL) is exposed and incised in line with the skin incision. The interval between the TFL and the rectus femoris muscle is developed, and the circumflex vessels are identified and

**Table 1.** Surgical Indications and Contraindications for Partial GM Tear Through DAA in THA

Indications	Contraindications
<ul style="list-style-type: none"> <li>• Symptomatic partial and small full-thickness GM tear.</li> </ul>	<ul style="list-style-type: none"> <li>• Large full-thickness and retracted GM tear.</li> <li>• Irreparable GM tear when procedure like gluteus maximus transfer is needed.</li> <li>• BMI &gt;40</li> </ul>

BMI, body mass index; DAA, direct anterior approach; GM, gluteus medius; THA, total hip arthroplasty.

**Table 2.** Advantages and Disadvantages

Advantages	Disadvantages
<ul style="list-style-type: none"> <li>• Same surgical approach.</li> <li>• Inherent benefits of DAA in primary THA.</li> </ul>	<ul style="list-style-type: none"> <li>• Exposure and visualization can be difficult in large patients.</li> <li>• A traction table required (author's preference).</li> <li>• Additional OR staff for traction table management during surgery.</li> </ul>

DAA, direct anterior approach; OR, operative room; THA, total hip arthroplasty.

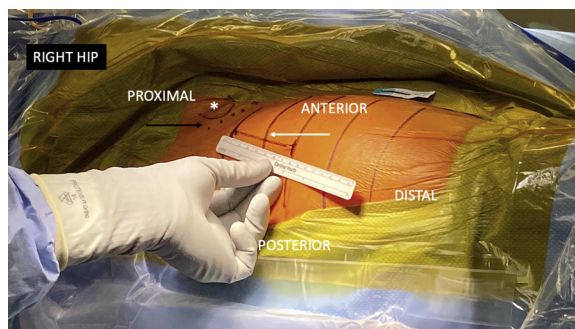
coagulated. The deep fascia is opened, and the femoral neck and anterior capsule are identified (Video 1). Although the authors performed the THA before the partial GM tear repair, the GM evaluation is done beforehand for a final status (partial tear) confirmation (Fig 2).

#### Gluteus Medius Tendon Exposure

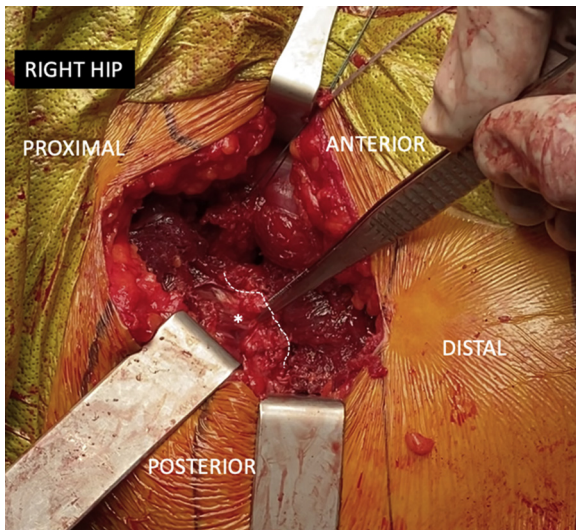
When using DAA with the Hana table, the following maneuvers/steps are required to achieve a proper GM exposure (Fig 2 and Table 3):

1. All retractors for femoral neck and anterior capsule need to be removed.
2. The operative leg is brought to 30° of abduction.
3. Twenty to 25° of internal rotation is also applied.
4. Final visualization can be obtained with hibbs retractors.

Once appropriate exposure is obtained, the surgeon must probe the tendon and determine the type of tear involved based on macroscopic findings/intraoperative evaluation and consequently, decide on a repair technique.<sup>4</sup> Based on Lall et al., we classified the partial GM tears as follows: partial-thickness tear <25% (type IIIA) and partial-thickness tear >25% (type IIIB).



**Fig 1.** The patient is in the supine position and the right hip is shown in preparation for a right total hip arthroplasty and gluteus medius repair using the direct anterior approach. The incision and the inguinal crease are marked by the white and black arrows, respectively. The white asterisk is at the level of the anterior superior iliac spine.



**Fig 2.** The patient is in the supine position at the right hip is shown. The gluteus medius tendon (\*) is exposed and probed. A small full-thickness tear is found in this patient right hip. The border of the gluteus medius tear is marked by the dot-line. To achieve this view, the operative leg is brought to 30° of abduction and 20 to 25° of internal rotation.

We use the GM tear repair algorithm for the endoscopic alternative to determine the appropriate type of repair. In cases of type IIIA, the suture-staple option would be chosen; for type IIIB, the transtendinous surgical technique would be used.<sup>4,7,8</sup>

## Repair Technique

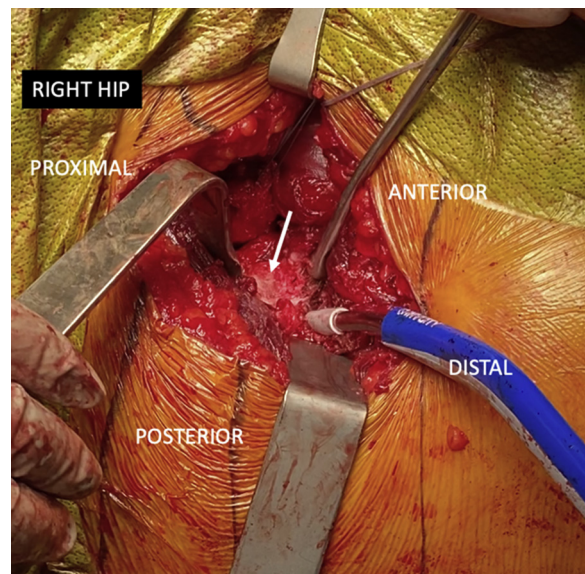
### Suture-Staple Technique

After trochanteric bursectomy (if required), the GM insertion is probed and confirmation of partial destabilization from its undersurface on the lateral facet is made. To enhance biologic response, a microfracture awl (Arthrex, Naples, FL) is used to create multiple holes within the lateral facet to obtain bone marrow material.<sup>9</sup> The microfracture awl aims for a depth of 3 to 5 mm. In general, 5 to 8 holes are required in the destabilized area. The PEEK 3.0-mm Knotless SutureTak anchors (Arthrex) are used, and the number of anchors (at least 2) depends on the surface area that needs to be compressed. With the corresponding metal

punch, one anchor is placed anteriorly and one is placed posteriorly in the lateral facet of the greater trochanter at the level of the partial tear. It is vital that the metal punch is properly oriented to avoid hitting the femoral stem; an angle between 30° and 45° is required for this task. The repair suture from each anchor is shuttled through the adjacent anchor looped shuttle stitch (A to B and B to A) and a horizontal mattress suture staple configuration is created. If more tendon compression is required, a second row can be added distally using the same technique.

### Transtendinous Technique

As mentioned previously, this alternative is preferred for partial type IIIB GM tears. Once the tear is identified and assessed, a longitudinal incision within the mid-substance of the GM tendon is made until the bone (footprint) is reached. This technique also can be used for small full-thickness GM tears (Fig 2). The underlying damage and nonviable tendon tissue are excised. With the use of a motorized burr or curette, the tendon footprint on the lateral facet is decorticated until a bleeding bed of bone is obtained (Fig 3). The “window concept” is applied: First, a small 90° Hohmann retractor is placed on the posterior border of the greater trochanter to expose the most posterior area of the lateral facet. Second, the same steps are used for the anterior counterpart. Considering the appropriate direction of anchor insertion to avoid the femoral stem, 1 or 2 double-loaded 5.5-mm PEEK Corkscrew suture anchors (Arthrex) are placed through the tendon split onto the footprint (Fig 4). Then, one limb of each suture

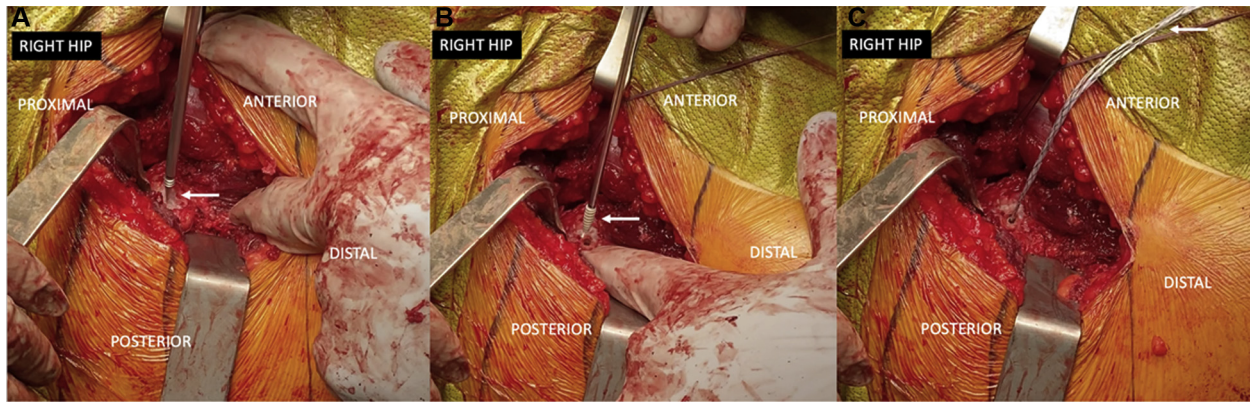


**Fig 3.** The patient is in the supine position at the right hip is shown. The gluteus medius tendon has been retracted posteriorly. The tendon footprint on the lateral facet (white arrow) is decorticated.

**Table 3.** Pearls and Pitfalls

Pearls	Pitfalls
<ul style="list-style-type: none"> <li>Abduction of 30-40° in the operative leg.</li> </ul>	<ul style="list-style-type: none"> <li>Minimal experience in DAA can result in a nonreproducible procedure.</li> </ul>
<ul style="list-style-type: none"> <li>Internal rotation of 20-30° in the operative leg.</li> </ul>	<ul style="list-style-type: none"> <li>Iatrogenic GM damage during femoral capsular release stage.</li> </ul>
<ul style="list-style-type: none"> <li>Aim the punch before anchor insertion, away from the femoral stem.</li> </ul>	<ul style="list-style-type: none"> <li>Perform micropuncture after anchor placement can compromise anchor fixation.</li> </ul>

DAA, direct anterior approach; GM, gluteus medius.



**Fig 4.** The patient is in the supine position at the right hip is shown. In this case a single double-loaded 5.5-mm PEEK Corkscrew suture-anchor (Arthrex, Naples, FL) is selected for the repair. The sequence of suture-anchor insertion is shown. A. The corresponding suture-anchor punch (white arrow) is used at the footprint. B. The suture-anchor is (white arrow) placed in the selected location. C. Sutures can be seen after suture-anchor placement (white arrow).

is passed through the anterior and posterior tendon leaflets (Fig 5). Finally, both sets of sutures are tied in a horizontal mattress fashion; an arthroscopic knot pusher may be used for this step. This process is repeated until complete closure of the tendon over the bone is achieved (Fig 6 and Video 1).

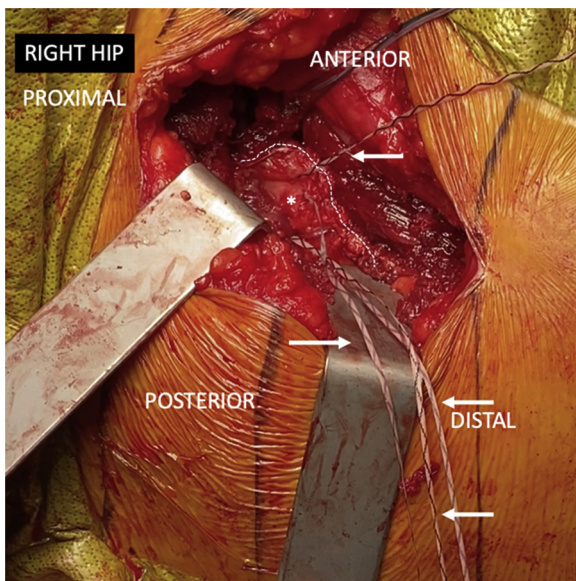
#### Postoperative Rehabilitation Protocol

While patients who undergo a suture-staple GM repair are not required to wear a brace following surgery, they are instructed to use crutches or a walker with weight-bearing as tolerated. Patients who undergo a transtendinous repair are instructed to practice partial weight-bearing (20 lbs) while wearing a low-profile

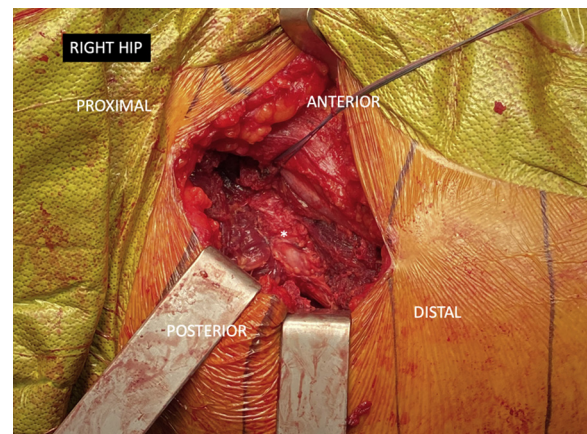
abduction brace (DJO Global, Vista, CA) for 6 weeks in addition to using crutches or a walker. All patients are counseled to complete home physical therapy and home nursing care according to standard protocol. After 1 to 2 weeks of home care, patients participate in another 6 to 8 weeks of outpatient physical therapy to increase range of motion and strength. Patients also follow-up at the 2-week, 3-month, and annual time points for clinical and radiographic assessment.

#### Discussion

The purpose of this technique is to address the partial GM tear through a DAA in the setting of primary THA. Currently, the posterior approach is often advocated for as the ideal approach since it allows for excellent exposure during the THA procedure as well as the GM repair.<sup>3,10</sup> Further, it has been previously stated that GM tear cannot be fixed using the DAA.<sup>3</sup> The authors must mention that the posterior approach is more suitable for full-thickness GM tears, particularly if a



**Fig 5.** The sutures (white arrows) have been passed in a mattress fashion through the gluteus medius tendon (asterisk). The border of the gluteus medius tear is marked by the dotted line.



**Fig 6.** The gluteus medius tendon has been repaired and final constructed is shown.

**Table 4.** Risks

Risks
<ul style="list-style-type: none"> <li>• Related to the DAA with traction table: pudendal nerve injury, femoral fracture.</li> </ul>
DAA, direct anterior approach.

salvage procedure such a gluteus maximus transfer with or without TFL is a surgical possibility.<sup>11-14</sup> Nevertheless, repair of partial GM tears is feasible using the DAA. The authors acknowledge the demanding nature of this procedure, especially at the beginning of the DAA learning curve (Tables 3 and 4).<sup>15-17</sup> Moreover, although the use of a traction table is not mandatory for primary DAA THA,<sup>18</sup> the contemporary surgical technique has been implemented by the authors while using an specialized traction table.

Signs of GM tears such as lateral hip pain, abductor weakness, and unstable gait should be closely assessed by the clinician to identify tears in the setting of hip osteoarthritis.<sup>19-21</sup> Tools to confirm GM tears include diagnostic injections, preferably under ultrasound, in addition to magnetic resonance imaging.<sup>22-29</sup> Intraoperatively, it is vital for surgeons to develop the ability to recognize the different patterns of partial GM tearing. In addition, partial-thickness GM tears require unique techniques to address the limited access to the deep side of the GM tendon and usually involve suture anchors with or without knotless technology.<sup>7,8</sup>

With the proper indications, partial tears can be evaluated and treated through the DAA in a reproducible manner by applying previously described arthroscopic techniques in an open setting.

## References

- Meermans G, Konan S, Das R, Volpin A, Haddad FS. The direct anterior approach in total hip arthroplasty: A systematic review of the literature. *Bone Joint J* 2017;99-B:732-740.
- Post ZD, Orozco F, Diaz-Ledezma C, Hozack WJ, Ong A. Direct anterior approach for total hip arthroplasty: Indications, technique, and results. *J Am Acad Orthop Surg* 2014;22:595-603.
- Whiteside LA, Roy ME. Incidence and treatment of abductor deficiency during total hip arthroplasty using the posterior approach: Repair with direct suture technique and gluteus maximus flap transfer. *Bone Joint J* 2019;101-B:116-122 (6\_suppl\_B).
- Lall AC, Schwarzman GR, Battaglia MR, Chen SL, Maldonado DR, Domb BG. Greater trochanteric pain syndrome: An intraoperative endoscopic classification system with pearls to surgical techniques and rehabilitation protocols. *Arthrosc Tech* 2019;8:e889-e903.
- Maldonado DR, Kyin C, Walker-Santiago R, et al. Direct anterior approach versus posterior approach in primary total hip replacement: Comparison of minimum 2-year outcomes [published online October 20, 2019]. *Hip Int*. <https://doi.org/10.1177/1120700019881937>.
- Maldonado DR, Laseter JR, Kyin C, Lall AC, Domb BG. Direct anterior approach in total hip arthroplasty leads to superior outcomes at 3-month follow-up when compared with the posterior approach: A matched study using propensity score analysis. *J Am Acad Orthop Surg Glob Res Rev* 2019;3:12.
- Domb BG, Nasser RM, Botser IB. Partial-thickness tears of the gluteus medius: Rationale and technique for trans-tendinous endoscopic repair. *Arthroscopy* 2010;26:1697-1705.
- Hartigan DE, Mansor Y, Perets I, Walsh JP, Mohr MR, Domb BG. Knotless "Suture Staple" technique for endoscopic partial thickness abductor tendon repair. *Arthrosc Tech* 2018;7:e975-e980.
- Redmond JM, Cregar WM, Gupta A, Hammarstedt JE, Martin TJ, Domb BG. Trochanteric micropuncture: Treatment for gluteus medius tendinopathy. *Arthrosc Tech* 2015;4:e87-e90.
- Lachiewicz PF, Kauk JR. Anterior iliopsoas impingement and tendinitis after total hip arthroplasty. *J Am Acad Orthop Surg* 2009;17:337-344.
- Chandrasekaran S, Darwish N, Vemula SP, Lodhia P, Suarez-Ahedo C, Domb BG. Outcomes of gluteus maximus and tensor fascia lata transfer for primary deficiency of the abductors of the hip. *Hip Int* 2017;27:567-572.
- Jang SA, Cho YH, Byun YS, Gu TH. Abductor reconstruction with gluteus maximus transfer in primary abductor deficiency during total hip arthroplasty. *Hip Pelvis* 2016;28:178-181.
- Whiteside LA. Gluteus transfer technique restores abductor deficiency in total hip arthroplasty. *Orthop Proc* 2018;100-B:43-43(suppl 13).
- Whiteside LA. Surgical technique: Gluteus maximus and tensor fascia lata transfer for primary deficiency of the abductors of the hip. *Clin Orthop* 2014;472:645-653.
- Pirruccio K, Evangelista PJ, Haw J, Goldberg T, Sheth NP. Safely implementing the direct anterior total hip arthroplasty: A methodological approach to minimizing the learning curve. *J Am Acad Orthop Surg* 2020;28:930-936.
- Steiger RN de, Lorimer M, Solomon M. What is the learning curve for the anterior approach for total hip arthroplasty? *Clin Orthop* 2015;473:3860.
- Yoshino K, Nakamura J, Hagiwara S, Suzuki T, Kawasaki Y, Ohtori S. Anatomical implications regarding femoral nerve palsy during a direct anterior approach to total hip arthroplasty: A cadaveric study. *J Bone Joint Surg Am* 2020;102:137-142.
- Sarraj M, Chen A, Ekhtiari S, Rubinger L. Traction table versus standard table total hip arthroplasty through the direct anterior approach: A systematic review. *Hip Int* 2020;30:662-672.
- Chandrasekaran S, Vemula SP, Gui C, Suarez-Ahedo C, Lodhia P, Domb BG. Clinical features that predict the need for operative intervention in gluteus medius tears. *Orthop J Sports Med* 2015;3:2.
- Lindner D, Shohat N, Botser I, Agar G, Domb BG. Clinical presentation and imaging results of patients with symptomatic gluteus medius tears. *J Hip Preserv Surg* 2015;2:310-315.
- Walker-Santiago R, Ortiz-Declet V, Maldonado DR, Wojnowski NM, Domb BG. The modified resisted internal

- rotation test for detection of gluteal tendon tears. *Arthrosc Tech* 2019;8:e331-e334.
22. Balog TP, Rhodehouse BB, Turner EK, et al. Accuracy of ultrasound-guided intra-articular hip injections performed in the orthopedic clinic. *Orthopedics* 2017;40:96-100.
  23. Chang K-V, Wu W-T, Lew HL, Özçakar L. Ultrasound imaging and guided injection for the lateral and posterior hip. *Am J Phys Med Rehabil* 2018;97:285-291.
  24. Chi AS, Long SS, Zoga AC, et al. Prevalence and pattern of gluteus medius and minimus tendon pathology and muscle atrophy in older individuals using MRI. *Skeletal Radiol* 2015;44:1727-1733.
  25. Docking SI, Cook J, Chen S, et al. Identification and differentiation of gluteus medius tendon pathology using ultrasound and magnetic resonance imaging. *Musculoskelet Sci Pract* 2019;41:1-5.
  26. Hartigan DE, Perets I, Walsh JP, et al. Radiographic risk factors and signs of abductor tears in the hip. *Arthroscopy* 2018;34:2389-2397.
  27. Hartigan DE, Perets I, Walsh JP, Domb BG. Imaging of abductor tears: Stepwise technique for accurate diagnosis. *Arthrosc Tech* 2017;6:e1523-e1527.
  28. LaPorte C, Vasaris M, Gossett L, Boykin R, Menge T. Gluteus medius tears of the hip: A comprehensive approach. *Phys Sportsmed* 2019;47:15-20.
  29. Ross JA, Greenwood AC, Sasser P, Jiranek WA. Peri-articular injections in knee and hip arthroplasty: Where and what to inject. *J Arthroplasty* 2017;32:S77-S80.