

Acute thrombosis of mechanical bi-leaflet aortic valve prosthesis

Theodor Tirilomis

Department for Thoracic, Cardiac, and Vascular Surgery, University of Goettingen, Goettingen, Germany

Address for correspondence: *Dr. Theodor Tirilomis, Department for Thoracic, Cardiac, and Vascular Surgery, University of Goettingen, Robert-Koch-Str. 40, 37075 Goettingen, Germany.*

E-mail: theodor.tirilomis@med.uni-goettingen.de

ABSTRACT

Thrombosis of mechanical aortic valve prosthesis is a rare but life-threatening complication. In most reported cases, inadequate anticoagulation or cessation of anticoagulation is the cause of prosthesis thrombosis. The case of a 70-year-old male patient hospitalized for severe dyspnoea is presented. Although the patient was under continuous anticoagulation, thrombosis of the 16 years previously implanted mechanical 31-sized aortic valve prosthesis was diagnosed. Emergency surgery was performed and postoperative course was uneventful. Patients with large size prostheses should have closer anticoagulation monitoring, even after many years of event-free postimplant course.

Key words: Anticoagulation, aortic valve, mechanical prosthesis, thrombosis

INTRODUCTION

Thrombosis of mechanical prosthesis for aortic valve replacement is uncommon.^[1,2] The bi-leaflet St. Jude Medical cardiac valve prosthesis is one of the most commonly used mechanical valve substitutes and has a special design, which provides nearly laminar flow, a low-pressure gradient, and a large effective orifice area resulting in reduced risk of thrombus formation.^[2]

CASE REPORT

A 70-year-old man with history of calcified, rheumatic aortic stenosis who underwent aortic valve replacement 16 years ago (31-mm St. Jude Medical bi-leaflet mechanical valve prosthesis) developed severe shortness of breath in the last weeks. Additionally, he reported gastroenteritis few weeks ago. Clinical examination on admission showed orthopnoea, tachypnoea,

tachycardia, and hypotension. Cardiac auscultation revealed systolic murmur and absence of the metallic click sound. The chest X-ray demonstrated enlargement of the heart [Figure 1], and the echocardiography revealed dilation of the left ventricle and reduced contractility with an ejection fraction of 15%. Flow velocity over the prosthetic valve was 4 m/s in combination with severe regurgitation into the left ventricle. The International Normalized Ratio (INR) at admission was 2.3.

The patient underwent emergency reoperation immediately. The mechanical aortic prosthesis showed complete immobilization of both leaflets due to thrombotic material located in both sides of the leaflets pivots [Figures 2 and 3]. The mechanical valve was removed and a bio-prosthesis was implanted. Postoperative recovery was uneventful. Thrombotic material was sent for microbiological examination and there were no bacteria.

DISCUSSION

Prosthetic valve thrombosis is the most serious thromboembolic complication with high mortality.^[1] The bi-leaflet mechanical St. Jude Medical valve prosthesis has a very low complication rate with a

Access this article online	
Quick Response Code: 	Website: www.jcdronline.com
	DOI: 10.4103/0975-3583.98899

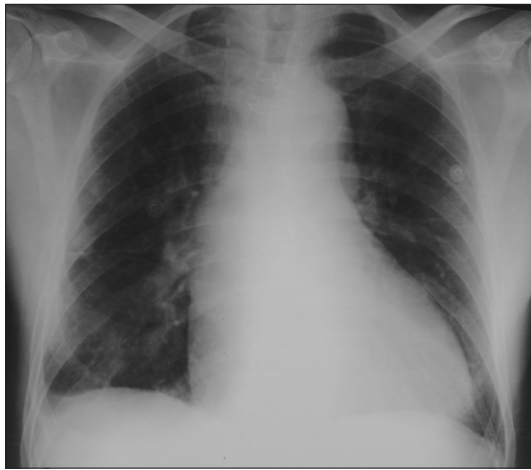


Figure 1: Chest X-ray (anteroposterior view) demonstrating cardiomegaly

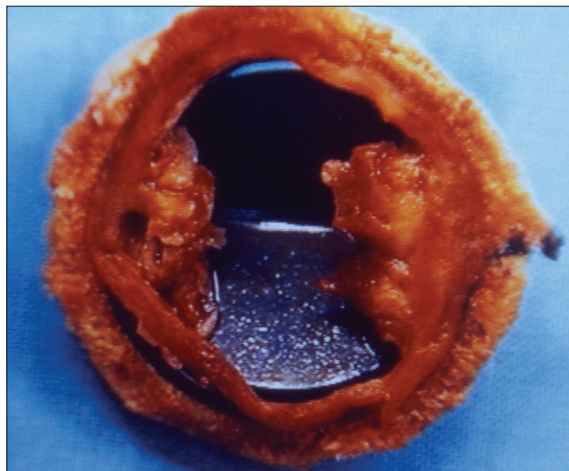


Figure 2: Aortic view of the explanted aortic prosthesis showing complete immobilization of both leaflets due to thrombosis located in both areas of the leaflet pivots. The sewing ring was covered completely by “neointimal” tissue (is here partially removed), but there was no interaction between this tissue and the prosthesis leaflets

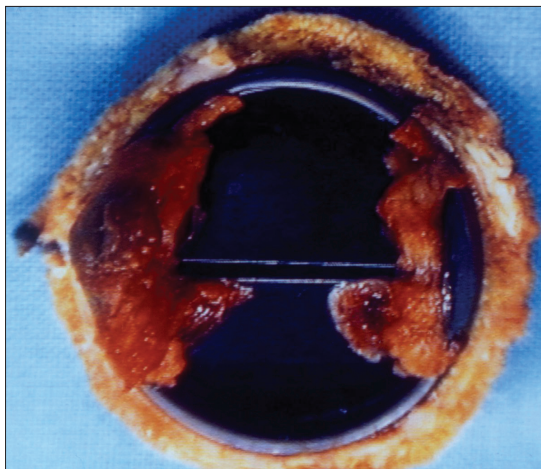


Figure 3: Ventricular view of the explanted aortic prosthesis showing the thrombosis of the leaflet pivots

thrombosis rate of 0.03% per patient-year.^[3,4] The two leaflet pivots of this prosthesis are designed within a “butterfly” recessed in the orifice ring without fixed pivot points. This allows rapid, controlled movement of the leaflets without the possibility to produce an area of stasis.^[2] Velocity and turbulent shear stress studies of this mechanical valve prosthesis found for the region adjacent to the pivot mechanism a combination of high turbulent shear stresses and flow separation.^[5] Nevertheless, larger valve size seems to be risk factor for the late thrombembolic event.^[1]

Because of early reports of leaflet entrapment due to small thrombus, anticoagulation is recommended for life.^[6] A decrease in anticoagulation or the absence of anticoagulation, even for short periods, was reported to be a significant risk factor for thrombembolic complication after valve replacement with the St. Jude Medical prosthesis.^[1,7,8] In the present case, the patient did not discontinue anticoagulation, the INR monitoring was performed by the family doctor every 3 to 4 weeks and was within the target range. Nevertheless, it is possible that during gastroenteritis the level was even lower but this is only speculation. Closer anticoagulation monitoring (e.g., once a week) could probably help to reduce risk of late prosthesis thrombosis.

Self-management of INR has been reported to result in better achievement of the target level.^[9] A prospective, randomized, and multicenter trial of self-management demonstrated the efficacy and safety of very low-dose INR (target range of 1.6–2.1 for aortic valve replacement).^[10]

Although most patients died of cardiac arrest or cardiogenic shock before any surgery or intervention,^[11] valve thrombosis does not cause sudden death.^[12] The clinical condition of the patients deteriorates over several days allowing time for diagnosis and specific treatment.^[11,13] The operative risk remains acceptable even when the patient’s clinical condition is severe. Satisfactory results have been reported after thrombolytic therapy for prosthetic valve thrombosis. Although severe complications during treatment have been reported to be transient, nonsurgical treatment is an alternative for valve thrombosis only when the patient’s clinical condition is not critical.^[14,15]

CONCLUSION

This case illustrates the need for closer monitoring of

the anticoagulation treatment in patients with large size prostheses after replacement of the aortic valve, even if the course after mechanical valve implantation is uneventful for many years. In case of suspected valve thrombosis, early diagnosis is recommended and emergency operation is indicated in patients with critical clinical condition.

REFERENCES

1. Fernandez J, Laub GW, Adkins MS, Anderson WA, Chen C, Bailey BM, *et al.*. Early and late-phase events after valve replacement with the St. Jude Medical prosthesis in 1200 patients. *J Thorac Cardiovasc Surg* 1994;107:394-406.
2. Arom KV, Nicoloff DM, Kersten TE, Northrup WF 3rd, Lindsay WG. Six years of experience with the St. Jude Medical valvular prosthesis. *Circulation* 1985;72:II153-8.
3. Burckhardt D, Striebel D, Vogt S, Hoffmann A, Roth J, Weiss P, *et al.* Heart valve replacement with St. Jude Medical valve prosthesis. Long-term experience in 743 patients in Switzerland. *Circulation* 1988;78:II18-24.
4. Smith JA, Westlake GW, Mullerworth MH, Skillington PD, Tatoulis J. Excellent long-term results of cardiac valve replacement with the St. Jude Medical valve prosthesis. *Circulation* 1993;88:II49-54.
5. Yoganathan AP, Wick TM, Reul H. Influence of flow characteristics of prosthetic valves on thrombus formation. In: Butchart EG, Bodnar E, editors. *Thrombosis, Embolism, and Bleeding*. London: ICR Publishers; 1992. p. 123-148.
6. Nuñez L, Iglesias A, Sotillo J. Entrapment of leaflet of St. Jude Medical cardiac valve prosthesis by miniscule thrombus: Report of two cases. *Ann Thorac Surg* 1980;29:567-9.
7. Katircioğlu SF, Ulus AT, Yamak B, Ozsöyler I, Birincioğlu L, Taşdemir O. Acute mechanical valve thrombosis of the St. Jude Medical prosthesis. *J Card Surg* 1999;14:164-8.
8. Schreiber C, Augustin N, Holper K, Lange R. Acute thrombosis of a mechanical heart valve caused by inadequate anticoagulation with low molecular weight heparin. *Herz* 2001;26:482-4.
9. Huth C, Friedl A, Rost A. Intensity of oral anticoagulation after implantation of St. Jude Medical aortic prosthesis: Analysis of the GELIA Database (GELIA 4). *Eur Heart J* 2001;3(Suppl Q):Q33-8.
10. Koertke H, Zittermann A, Wagner O, Ennker J, Saggau W, Sack FU, *et al.* Efficacy and safety of very low-dose self-management of oral anticoagulation in patients with mechanical heart valve replacement. *Ann Thorac Surg* 2010;90:1487-93.
11. Buttard P, Bonnefoy E, Chevalier P, Marcaz PB, Robin J, Obadia JF, *et al.* Mechanical cardiac valve thrombosis in patients in critical hemodynamic compromise. *Eur J Cardiothorac Surg* 1997;11:710-3.
12. Butchart EG, Lewis PA, Grunkemeier GL, Kulatilake N, Breckenridge IM, *et al.* Low risk of thrombosis and serious embolic events despite low-intensity anticoagulation. Experience with 1,004 Medtronic Hall valves. *Circulation* 1988;78 :166-77.
13. Butchart EG. Thrombogenicity, thrombosis and embolism. In: Butchart EG, Bodnar E, editors. *Thrombosis, Embolism, and Bleeding*. London: ICR Publishers; 1992. p. 172-205.
14. Renzulli A, Vitale N, Caruso A, Dialetto G, de Luca L, Schinosa T, *et al.* Thrombolysis for prosthetic valve thrombosis: Indications and results. *J Heart Valve Dis* 1997;6:212-8.
15. Aoyagi S, Fukunaga S, Suzuki S, Nishi Y, Oryoji A, Kosuga K. Obstruction of mechanical valve prostheses: Clinical diagnosis and surgical or nonsurgical treatment. *Surg Today* 1996;26:400-6.

How to cite this article: Tirilomis T. Acute thrombosis of mechanical bi-leaflet aortic valve prosthesis. *J Cardiovasc Dis Res* 2012;3:228-30.

Source of Support: Nil, **Conflict of Interest:** None declared.

Announcement

iPhone App



Download
iPhone, iPad
application

FREE

A free application to browse and search the journal's content is now available for iPhone/iPad. The application provides "Table of Contents" of the latest issues, which are stored on the device for future offline browsing. Internet connection is required to access the back issues and search facility. The application is Compatible with iPhone, iPod touch, and iPad and Requires iOS 3.1 or later. The application can be downloaded from <http://itunes.apple.com/us/app/medknow-journals/id458064375?ls=1&mt=8>. For suggestions and comments do write back to us.