

# CT findings in viral lower respiratory tract infections caused by parainfluenza virus, influenza virus and respiratory syncytial virus

Min-Chul Kim (MD)<sup>a</sup>, Mi Young Kim (MD)<sup>b,\*</sup>, Hyun Joo Lee (MD)<sup>b</sup>, Sang-Oh Lee (MD)<sup>a</sup>, Sang-Ho Choi (MD)<sup>a</sup>, Yang Soo Kim (MD)<sup>a</sup>, Jun Hee Woo (MD)<sup>a</sup>, Sung-Han Kim (MD)<sup>a</sup>

## Abstract

Viral lower respiratory tract infections (LRTIs) can present with a variety of computed tomography (CT) findings. However, identifying the contribution of a particular virus to CT findings is challenging due to concomitant infections and the limited data on the CT findings in viral LRTIs. We therefore investigate the CT findings in different pure viral LRTIs.

All patients who underwent bronchoalveolar lavage (BAL) and were diagnosed with LRTIs caused by parainfluenza virus (PIV), influenza virus, or respiratory syncytial virus (RSV) between 1998 and 2014 were enrolled in a tertiary hospital in Seoul, South Korea. A pure viral LRTI was defined as a positive viral culture from BAL without any positive evidence from respiratory or blood cultures, or from polymerase chain reaction (PCR), or from serologic tests for bacteria, fungi, mycobacteria, or other viruses.

CT images of 40 patients with viral LRTIs were analyzed: 14 with PIV, 14 with influenza virus, and 12 with RSV. Patch consolidation ( $\geq 1$  cm or more than 1 segmental level) was found only in PIV (29%) ( $P=0.03$ ), by which CT findings caused by PIV could resemble those seen in bacterial LRTIs. Ground-glass opacities were seen in all cases of influenza virus and were more frequent than in PIV (71%) and RSV (67%) ( $P=0.05$ ). Bronchial wall thickening was more common in influenza virus (71%) and RSV (67%) LRTIs than PIV LRTIs (21%) ( $P=0.02$ ). With respect to anatomical distribution, PIV infections generally affected the lower lobes (69%), while influenza virus mostly caused diffuse changes throughout the lungs (57%), and RSV frequently formed localized patterns in the upper and mid lobes (44%).

The CT findings in LRTIs of PIV, influenza virus, and RSV can be distinguished by certain characteristics. These differences could be useful for early differentiation of these viral LRTIs, and empirical use of appropriate antiviral agents.

**Abbreviations:** BAL = bronchoalveolar lavage, CT = computed tomography, LRTI = lower respiratory tract infection, PCR = polymerase chain reaction, PIV = parainfluenza virus, RSV = respiratory syncytial virus.

**Keywords:** CT findings, influenza, parainfluenza virus, respiratory syncytial virus, viral lower respiratory tract infections (LRTIs)

Editor: Ken Rosenthal.

**Summary:** Viral lower respiratory tract infections (LRTIs) caused by parainfluenza virus, influenza virus, and respiratory syncytial virus are described with their characteristic computed tomography (CT) findings. These findings could be useful for early differentiation of these viral LRTIs.

**Funding:** This study was supported by grants of the Korea Health Technology R&D Project through Korea Health Industry Development Institute (KHIDI), funded by the Ministry of Health & Welfare, Republic of Korea (grant no. HI15C2774) and Asan Institute of Life Sciences (grant no. 2015-462).

The authors have no conflicts of interest to disclose.

<sup>a</sup> Department of Infectious Diseases, <sup>b</sup> Department of Radiology and Research Institute of Radiology, Asan Medical Center, University of Ulsan College of Medicine, Seoul, Republic of Korea.

\* Correspondence: Sung-Han Kim, Department of Infectious Diseases, Asan Medical Center, University of Ulsan College of Medicine, 86 Asanbyeongwon-Gil, Songpa-Gu, Seoul 138-736, Republic of Korea (e-mail: kimsunghanmd@hotmail.com); Mi Young Kim, Department of Radiology and Research Institute of Radiology, Asan Medical Center, University of Ulsan College of Medicine, 86 Asanbyeongwon-Gil, Songpa-Gu, Seoul 138-736, Republic of Korea (e-mail: mimowdr@gmail.com).

Copyright © 2016 the Author(s). Published by Wolters Kluwer Health, Inc. All rights reserved.

This is an open access article distributed under the Creative Commons Attribution-NoDerivatives License 4.0, which allows for redistribution, commercial and non-commercial, as long as it is passed along unchanged and in whole, with credit to the author.

Medicine (2016) 95:26(e4003)

Received: 20 March 2016 / Received in final form: 24 May 2016 / Accepted: 31 May 2016

<http://dx.doi.org/10.1097/MD.0000000000004003>

## 1. Introduction

Lower respiratory tract infection (LRTI) refers to a broad clinical entity of acute respiratory infections resulting in lower respiratory signs or symptoms such as sputum, dyspnea, wheezing, or crackles, wherein tracheobronchitis, bronchiolitis, and pneumonia are included.<sup>[1-3]</sup> Respiratory viruses are increasingly recognized as important pathogens causing LRTI.<sup>[4-12]</sup> Parainfluenza virus (PIV), influenza virus, and respiratory syncytial virus (RSV) are the 3 most common respiratory viruses documented in LRTI and are the important pathogens which can potentially lead to fatal outcomes particularly in immunocompromised patients.<sup>[13-18]</sup>

Discriminating the viral LRTIs caused by PIV, influenza virus, and RSV, however, remains problematic due to nonspecific clinical presentations which have considerable overlaps among them.<sup>[6,7,14]</sup> The radiologic appearances of these viral LRTIs are also unclear, because they are frequently accompanied by infections by bacteria, fungi, mycobacteria, or other viruses, and data on the radiologic findings of the individual viruses are very limited. Examination of bronchoalveolar lavage (BAL) often permits a definitive diagnosis, but is not always feasible due to the unstable clinical conditions especially in critically ill patients. Hence, better understanding of the radiologic findings in viral LRTIs could assist physicians in establishing their viral etiology, employing empirical antiviral agents, and obviating unnecessary antibacterial treatments.

A few studies have evaluated computed tomography (CT) findings in LRTIs caused by PIV, influenza virus, and RSV.<sup>[19–40]</sup> Nevertheless, they were flawed by important limitations. Since they predominantly relied for virus identification on upper respiratory specimens such as nasopharyngeal aspirates or swabs, the viruses detected could indicate coincidental upper respiratory tract infections. Furthermore, only a limited number of patients with severe viral LRTIs were included. We therefore analyzed the CT findings in LRTIs in which BAL was performed because of their severity and in which PIV, influenza virus, or RSV were proven from the BAL samples to be the culprits.

## 2. Methods

### 2.1. Study population

This study was performed at the Asan Medical Center, a 2700-bed tertiary hospital in Seoul, South Korea, from January 1998 to December 2014. All adult patients aged  $\geq 16$  years, who underwent BAL and were diagnosed with LRTIs caused by PIV, influenza virus, or RSV, were enrolled. Chest CTs obtained from these patients were identified and reviewed. The need for informed consent was waived in view of the observational nature of the study.

### 2.2. Virus identification

In all cases, a diagnosis of LRTI caused by PIV, influenza virus, or RSV was established when the patient developed new-onset lower respiratory tract signs or symptoms such as sputum, dyspnea, wheezing, or crackles, and each virus was confirmed by viral culture of BAL samples only. We employed a shell vial culture (Diagnostic Hybrids, Inc., Athens, USA) that can detect PIV, influenza virus, RSV, cytomegalovirus, and adenovirus. The medical records of the patients with confirmed viral LRTIs were reviewed, and the patients with “pure” viral LRTI were finally analyzed. Pure viral LRTI was defined as a positive viral culture from BAL samples without any evidence of concomitant infection with other pathogens; patients giving positive respiratory or blood cultures, polymerase chain reaction (PCR), or serologic tests for bacteria, fungi, or mycobacteria were excluded. Patients infected with 2 or more respiratory viruses were also excluded.

### 2.3. CT analysis

Chest CT scans with or without contrast enhancement of the patients with pure viral LRTIs, obtained within 2 weeks of the date of viral culture, were retrospectively analyzed. Two radiologists with 19 (MYK) and 6 (HJL) years of experience, respectively, who were blind to the patients’ characteristics and clinical outcomes, independently reviewed the CT images and reached final decisions by consensus. In addition, the CT findings were compared to see whether there were any radiologic differences between infections with PIV, influenza virus, and RSV.

Various generations of CT scanners were used for this study. Most of the chest CT examinations were performed with a SOMATOM (Siemens Medical Solutions, Forchheim, Germany) or a Lightspeed Volume CT (VCT) (General Electric Medical Systems, Milwaukee, WI). The reconstruction intervals were 5 mm, with a 5 mm interval without a gap for the B50 algorithm and a 1 mm reconstruction with a 5 mm gap for the B60 algorithm. Imaging was obtained at sustained full inspiration,

and the scan range was from the supraclavicular area to the level of the adrenal glands. All the images were viewed on the mediastinal (width: 450 HU; level: 50 HU) and lung window (width: 1500 HU; level:  $-700$  HU) axial image settings on the picture archiving and communication system (PACS).

### 2.4. Radiologic findings and definitions

The CT morphologies of pure viral LRTIs were examined for the presence or absence of the following findings: patch consolidation ( $\geq 1$  cm or more than 1 segmental level), multifocal consolidations ( $< 1$  cm and more than 3 in number), ground-glass opacities, centrilobular nodules, bronchial wall thickening, interlobular septal thickening, pleural effusion, and normal appearance. Each finding was preferentially defined according to the criteria of the Fleischner Society glossary of terms.<sup>[41]</sup> Distinction between patch consolidation and multifocal consolidations was made by extent and number of the lesions: patch consolidation referred to relatively large ( $\geq 1$  cm) or extensive (more than 1 segmental level) lesion, however, multifocal consolidations indicated relatively small ( $< 1$  cm) and multiple (more than 3) ones. Bronchial wall thickening was determined to be present, in accordance with the previous studies, if the bronchus seemed more prominent than the adjacent artery in the absence of bronchiectasis.<sup>[24,32–34]</sup> Normal appearance was defined as the absence of pathologic findings except for preexisting lung parenchymal conditions such as emphysema, bronchiectasis, or interstitial lung disease (ILD). Furthermore, the anatomical distribution of changes was analyzed according to their zonal predominance (upper and mid, lower, and whole lung), localization (segmental and lobar, diffuse and random, and other), and symmetry (bilateral, unilateral).

Unlike previous studies, we did not exclude patients with preexisting lung parenchymal diseases such as ILD, chronic obstructive lung disease (COPD), and solid tumors involving the lungs. Previous studies excluded these patients because preexisting lung lesions can make it difficult to identify those changes developed by the viral LRTIs. However, these patients are of particular concern for viral LRTIs, and they might be helped if the CT findings permitted early diagnosis of the virus involved. Therefore, we decided to include them in our analysis. The newly appeared CT findings were identified by comparing the images with the underlying lesions seen in the previous or following CT images.

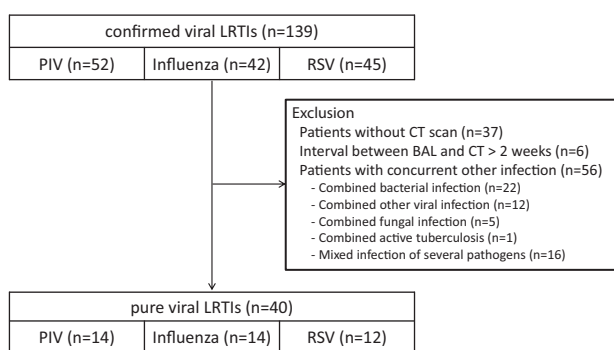
### 2.5. Statistical analysis

Statistical analyses were performed to compare the CT findings in infections by the 3 different viruses. The SPSS for Windows software package, version 20.0 (SPSS Inc, Chicago, IL) was used. Categorical variables were compared using the  $\chi^2$  or Fisher exact test, and continuous variables were compared using the Mann–Whitney *U* test. A *P*-value  $< 0.05$  were considered statistically significant.

## 3. Results

### 3.1. Clinical characteristics of patients

A total of 139 patients were diagnosed with LRTIs with PIV, influenza virus, and RSV using viral culture of BAL samples. Of these patients, 37 did not undergo CT scans, and 6 were excluded because the interval between CT scan and viral culture was more



**Figure 1.** Flow diagram of the study. CT=computed tomography, LRTI=lower respiratory tract infections, PIV=parainfluenza virus, RSV=respiratory syncytial virus.

than 2 weeks. Fifty-six patients who had concurrent infection with other pathogens were also excluded (see Fig. 1). Finally, the CT findings for 40 patients having pure viral LRTI were analyzed: 14 with PIV, 14 with influenza virus, and 12 with RSV.

The baseline clinical characteristics and outcomes of these 40 patients are shown in Table 1. There was a significant seasonal

**Table 1**  
**Baseline clinical characteristics and outcomes of 40 patients with pure viral lower respiratory tract infections.**

Variable	PIV (n=14)	Influenza virus (n=14)	RSV (n=12)	P value
<b>Demographics</b>				
Age, mean years ±SD	60 ± 10	57 ± 15	63 ± 11	0.39
Male gender	12 (86)	7 (50)	8 (67)	0.13
<b>Season</b>				
Spring (3–5)	4 (29)	5 (36)	4 (33)	<0.001
Summer (6–8)	9 (64)	0	0	
Fall (9–11)	1 (7)	0	2 (17)	
Winter (12–2)	0	9 (64)	6 (50)	
<b>Underlying disease</b>				
Hematologic malignancy and HCT	3 (21)	4 (29)	5 (42)	0.62
Interstitial lung disease	7 (50)	5 (36)	6 (50)	0.69
Solid tumors	1 (7)	4 (29)	1 (8)	0.33
COPD	2 (14)	0	0	0.32
Others	0	1 (7)*	0	>0.99
Previous healthy	2 (14)	0	1 (8)	0.50
Immunosuppressive condition†	6 (43)	11 (79)	9 (75)	0.11
Neutropenia (ANC < 500/μL)	1 (7)	1 (7)	1 (8)	>0.99
Lymphopenia (ALC < 200/μL)	1 (7)	1 (7)	1 (8)	>0.99
Corticosteroid within the prior 30 days	6 (43)	9 (64)	7 (58)	0.50
Antiviral treatment	5 (36)‡	11 (79)§	4 (33)‡	0.03
<b>Outcome</b>				
ICU admission	6 (43)	5 (36)	5 (42)	0.92
Mechanical ventilation	5 (36)	4 (29)	5 (42)	0.92
In-hospital mortality	4 (29)	3 (21)	5 (42)	0.62

Data are no. (%) of patients unless indicated otherwise. ALC=absolute lymphocyte count, ANC=absolute neutrophil count, COPD=chronic obstructive pulmonary disease, HCT=hematopoietic stem cell transplantation, ICU=intensive care unit, PIV=parainfluenza virus, RSV=respiratory syncytial virus, SD=standard deviation.

\* This patients had a myasthenia gravis.

† Immunosuppressive condition is defined as presence of underlying diseases, such as HIV infection, malignancy, liver cirrhosis, and chronic renal failure, and/or receipt of immunosuppressive treatment.

‡ Oral ribavirin and intravenous immunoglobulin (IVIg) were used.

§ Oral oseltamivir and intravenous peramivir were used.

variation in occurrence: PIV infections happened predominantly in summer, whereas influenza virus and RSV infections occurred mostly in winter ( $P < 0.001$ ). The patients with influenza virus (79%) LRTIs received antiviral treatment, consisting of oseltamivir or peramivir, more frequently than those with PIV (36%) or RSV (33%) LRTIs ( $P = 0.03$ ). Other baseline clinical characteristics and outcomes were not significantly different between the 3 groups.

**3.2. CT findings in viral LRTIs**

The individual respiratory viruses tended to generate several characteristic CT findings despite considerable overlap between them. The image findings are summarized in Table 2. Patch consolidation ( $\geq 1$  cm or more than 1 segmental level) was found only in PIV LTRIs (29%) ( $P = 0.03$ ) and made these LTRIs look like bacterial infections. The representative images of PIV LRTI are shown in Fig. 2. All cases of influenza virus had ground-glass opacities, which were more frequent than in PIV (71%) and RSV (67%) LTRIs ( $P = 0.05$ ) (Fig. 3). Bronchial wall thickening was more common in influenza virus (71%) and RSV (67%) infections than in PIV infections (21%) ( $P = 0.02$ ) (Fig. 4). Therefore, the CT images of influenza virus and RSV LTRIs could seem to be more compatible with viral infections than those of PIV LTRIs. We did not detect any significant differences between the 3 viruses in terms of multifocal consolidations ( $< 1$  cm and more than 3 in number), centrilobular nodules, interlobular septal thickening, pleural effusion, and normal appearance.

**Table 2**  
**CT findings in 40 patients diagnosed with a pure viral LRTI.**

Variable	PIV (n=14)	Influenza virus (n=14)	RSV (n=12)	P value
<b>CT finding</b>				
Patch consolidation*	4 (29)	0	0	0.03
Multifocal consolidations†	6 (43)	8 (57)	7 (58)	0.67
Ground-glass opacities	10 (71)	14 (100)	8 (67)	0.05
Centrilobular nodules	4 (29)	3 (21)	4 (33)	0.91
Bronchial wall thickening	3 (21)	10 (71)	8 (67)	0.02
Interlobular septal thickening	6 (43)	4 (29)	2 (17)	0.39
Pleural effusion				0.71
Unilateral	2 (14)	1 (7)	0	
Bilateral	2 (14)	4 (29)	4 (33)	
None	10 (71)	9 (64)	8 (67)	
Normal appearance‡	1 (7)	0	3 (25)	0.10
<b>Anatomical distribution</b>				
<b>Zonal predominance</b>				
Upper and mid	2/13 (15)§	2/14 (14)	4/9 (44)¶	0.06
Lower	9/13 (69)§	4/14 (29)	2/9 (22)¶	
Whole lung	2/13 (15)§	8/14 (57)	3/9 (33)¶	
<b>Localization</b>				
Segmental and lobar	5/13 (38)§	3/14 (21)	6/9 (67)¶	0.09
Diffuse	8/13 (62)§	11/14 (79)	3/9 (33)¶	
<b>Symmetry</b>				
Bilateral	7/13 (54)§	6/14 (43)	9/9 (100)¶	0.02
Unilateral	6/13 (46)§	8/14 (57)	0/9 (0)¶	

Data are no. (%) of patients unless indicated otherwise. CT=computed tomography, LRTI=lower respiratory tract infection, PIV=parainfluenza virus, RSV=respiratory syncytial virus.

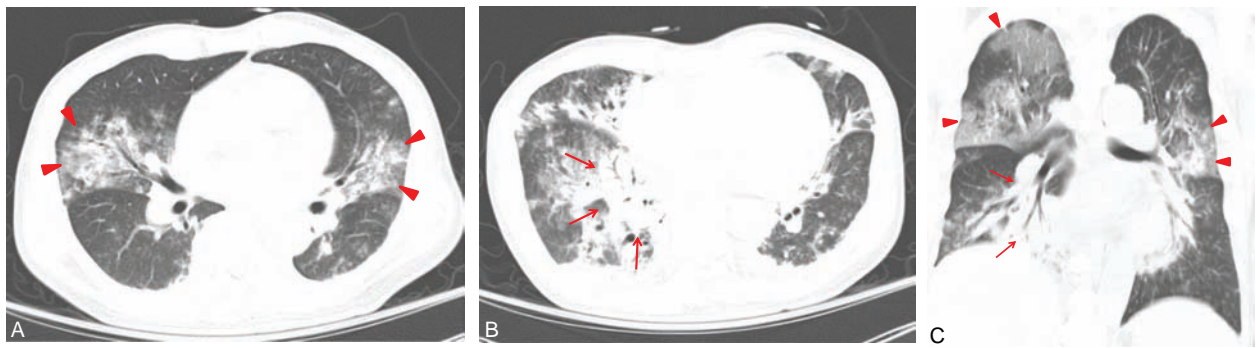
\* Patch consolidation indicates the consolidation of  $\geq 1$  cm or more than one segmental level.

† Multifocal consolidations indicate the consolidations of  $< 1$  cm and more than 3 in number.

‡ Normal appearance represents the absence of pathologic findings except the underlying lung parenchymal condition such as emphysema, bronchiectasis.

§ One PIV patient with normal appearance of CT image was excluded.

¶ Three RSV patients with normal appearance of CT image were excluded.

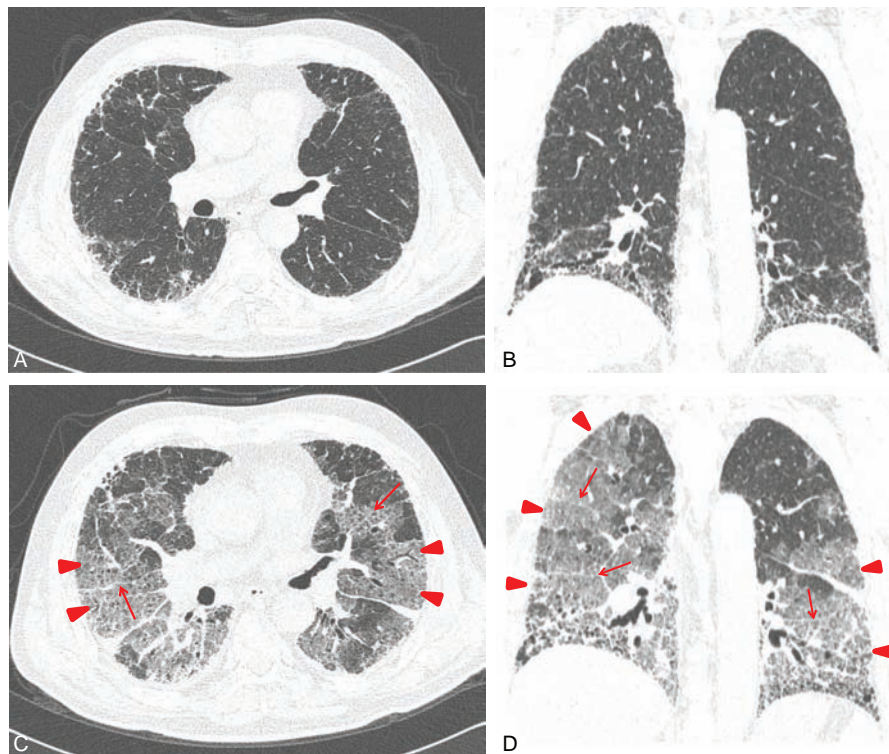


**Figure 2.** Computed tomography (CT) images of parainfluenza virus pneumonia in a 55-year-old man diagnosed with lymphoma. Chest CT axial (A, B) and coronal (C) images (5-mm slice) were obtained at the levels of the lower lobar bronchi and the segmental bronchi. Note the patch consolidation (arrows) with air-bronchogram predominantly in the right lower lobes. Note also the multifocal ground glass opacities (arrow heads) in both lungs, especially in the right upper lobes. Bilateral pleural effusions can also be seen.

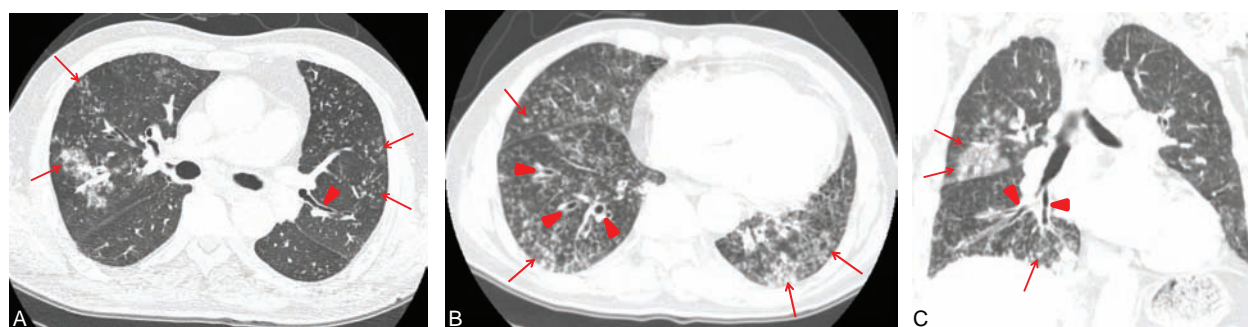
Differences of anatomical distribution were also noted for the individual respiratory virus LTRIs (Table 2). Each virus had a tendency to prefer a certain area of the lungs ( $P=0.06$ ): CT findings of PIV LTRIs were predominantly found in the lower lungs (69%), those of influenza virus in the whole lungs (57%), and those of RSV in the upper and mid lungs (44%). PIV (62%) and influenza virus (79%) LTRIs frequently showed a diffuse distribution, whereas RSV predominantly revealed a segmental and lobar distribution (67%); however, the difference was not statistically significant ( $P=0.09$ ). All cases of RSV demonstrated

a bilateral distribution, unlike PIV LTRIs (54%) and influenza virus LTRIs (43%) ( $P=0.02$ ).

In short, PIV LTRIs occasionally presented with patch consolidation ( $\geq 1$  cm or more than one segmental level) located in the lower lobes (Fig. 2). Influenza virus LTRIs mostly exhibited diffuse ground-glass opacities over the whole lung (Fig. 3), and RSV LTRIs often formed localized and bilateral patterns, which were more often in the upper and mid lobes (Fig. 4). It was notable that CT images of all 3 types of LTRI often contained multifocal consolidations ( $< 1$  cm and more than three in number)



**Figure 3.** Computed tomography (CT) images of influenza virus pneumonia in a 77-year-old man with underlying idiopathic pulmonary fibrosis. Chest CT axial (A, C) and coronal images (C, D) (1-mm slice) were obtained at the levels of the right lower lobar bronchi and segmental bronchi. (A, B) There are diffuse reticular opacities predominantly in the subpleural areas and both lower lobes, pointing to underlying idiopathic pulmonary fibrosis. Mild traction bronchiectasis exists in both lower lobes. (C, D) Seven days later, there are newly developed diffuse ground-glass opacities (arrow heads) and interlobular septal thickenings (arrows) in the both spared lungs on follow-up CT.



**Figure 4.** Computed tomography (CT) images of respiratory syncytial virus bronchiolitis in a previously healthy 60-year-old man. (A–C) Chest CT axial (A, B 1- and 5-mm slice) and coronal images (C 5-mm slice) were obtained at the levels of the main stem bronchi and segmental bronchi of both lower lobes. Note the ill-defined centrilobular nodules (arrows) in both lungs, predominantly in the right middle lobe and both lower lobes. Note also the diffuse bronchial wall thickening (arrow heads) in the right lower lobe.

**Table 3**  
**Previous studies upon the CT finding in LRTIs caused by PIV, influenza virus, and RSV.**

First author [ref.]	Year	Number of patients	Specimen	Assay	CT findings		
					PIV	Influenza virus	RSV
Mayer <sup>[27]</sup>	2014	RSV 51	Throat swab, BAL, etc.	PCR			Ground-glass opacities, consolidations*
Herbst <sup>[24]</sup>	2013	PIV 24	Nasopharyngeal swab, BAL	PCR	Bronchial wall thickening, tree-in-bud opacities, consolidation		
Lee <sup>[20]</sup>	2013	Influenza virus 98	Nasopharyngeal swab,	PCR		Ground-glass opacities, consolidations	
Wang <sup>[19]</sup>	2013	Influenza virus 12	Nasopharyngeal swab,	PCR		Ground-glass opacities, consolidations	
Syha <sup>[28]</sup>	2012	RSV 13	NA	Culture			Ground-glass opacities, consolidations, centrilobular opacities
Li <sup>[21]</sup>	2012	Influenza virus 70	NA	PCR		Ground-glass opacities, consolidations	
El-Badrawy <sup>[22]</sup>	2012	Influenza virus 12	BAL	PCR, IF		Bronchial wall thickening, ground-glass opacities, consolidations	
Miller <sup>[32]</sup>	2011	Influenza virus 60, RSV 19	Nasopharyngeal swab, BAL	PCR		Various findings, normal	Bronchial wall thickening, tree-in-bud opacities
Marchiori <sup>[23]</sup>	2011	NA	NA	NA		Consolidations, ground-glass opacities	
Shiley <sup>[34]</sup>	2010	PIV 4, Influenza virus 21, RSV 8	Nasopharyngeal swab, BAL	PCR	Tree-in-bud opacities, consolidations	Normal, ground-glass opacities	Tree-in-bud opacities
Ferguson <sup>[25]</sup>	2009	PIV 6	Nasopharyngeal aspirate, BAL	Culture, PCR, IF	Multiple small nodules		
Kanne <sup>[35]</sup>	2007	NA	NA	NA	Consolidations, centrilobular nodules, ground-glass opacities,	Ground-glass opacities, consolidations, centrilobular nodules	Centrilobular nodules, ground-glass opacities, consolidation
Kim <sup>[40]</sup>	2002	NA	NA	NA		Consolidations, ground-glass opacities,	
Ko <sup>[29]</sup>	2000	RSV 10	Nasopharyngeal swab, BAL	Culture, IF			Ground-glass opacities, consolidation
Present study	2015	PIV 14, Influenza virus 14, RSV 12	BAL	Culture	Patch consolidation (≥1 cm or more than 1 segmental level), ground-glass opacities, multifocal consolidations	Ground-glass opacities, bronchial wall thickening, multifocal consolidations	Bronchial wall thickening, ground-glass opacities, multifocal consolidations

BAL = bronchoalveolar lavage, CT = computed tomography, IF = immunofluorescence, LRTI = lower respiratory tract infection, NA = not available, PCR = polymerase chain reaction, PIV = parainfluenza virus, RSV = respiratory syncytial virus.

\* In the study, the most characteristic CT findings at the beginning of RSV pneumonia were nodules, tree-in-bud opacities, and bronchial wall thickening.

(PIV [43%], influenza virus [57%], and RSV [58%]). In addition, pleural effusion was not uncommon in all 3 types. Hence, the CT findings in LRTIs caused by any one of the three viruses could masquerade as bacterial infections, especially in severe cases.

#### 4. Discussion

We have identified certain specific characteristics of the CT findings in patients with LRTIs due to PIV, influenza virus, and RSV. The PIV LRTIs were distinctive in leading to patchy consolidation ( $\geq 1$  cm or more than 1 segmental level) and were preferentially located in the lower lobes of the lung with a diffuse distribution. Patients with influenza virus LRTIs had ground-glass opacities frequently diffused over the whole lungs. Influenza virus and RSV LRTIs often had bronchial wall thickenings, and RSV LRTIs were predominantly localized in the upper and mid lobes.

Several studies have previously evaluated the CT findings in LRTIs caused by PIV, influenza virus, and RSV (Table 3). In PIV LRTIs, Herbst et al<sup>[24]</sup> mainly observed bronchial wall thickenings and tree-in-bud opacities. Ferguson et al<sup>[25]</sup> reported multiple small nodules ( $< 5$  mm) in 6 patients with PIV LRTIs. However, the previous findings are not consistent with our data for PIV LRTIs, which were characterized by patch consolidation, ground-glass opacities, and multifocal consolidations. This discrepancy could be due to the fact that the earlier studies included only a limited number of severe cases, so that the potential CT findings of severe PIV infections were not fully evaluated. For influenza virus, several studies consistently found ground-glass opacities and consolidations,<sup>[19–23,32,34,35]</sup> which is in line with our findings. For RSV, bronchial wall thickening and centrilobular opacities were considered to predominate in view of the frequent presentation of bronchiolitis.<sup>[27–29,32,34,35]</sup> The present study confirmed that bronchial wall thickening was frequently seen in RSV infections, although RSV could manifest as ground-glass opacities or consolidations in severe cases.

The availability of the PCR has greatly improved the identification of viral pathogens in respiratory tract infections, compared with conventional virological diagnostic methods such as serologic tests and viral culture.<sup>[6,7,9–12]</sup> However, positivity in virus PCR, which indicates the presence of viral genomes, may not always imply an active infection, because false positivity is possible in the cases of past infection or colonization by the virus.<sup>[13]</sup> However, positive culture of virus, which demonstrates the presence of viable virus, strongly suggests active infection. We believe that identification of living virus by culture from BAL is the most reliable method of proving a virus to be the pathogen. We therefore employed viral culture rather than virus PCR to detect pure viral LRTIs.

Our study has a few limitations. First, we only included the patients who underwent BAL and CT. Thus, there could have been a selection bias toward more severe LRTIs, and CT findings of relatively mild cases might be underestimated. Second, some may argue that concomitant bacterial LRTI could not be definitely ruled out due to the relative insensitivity of conventional culture for bacterial respiratory pathogens resulting LRTIs. However, most studies in this area have used similar practical criteria for viral LRTIs in the real world.<sup>[24,25,32,36]</sup> In addition, if such confounding by concomitant bacterial infection did occur, it would be more likely to lead to a bias toward the null hypothesis. Third, CT findings in early stage of viral LRTI may be distinct from those in late stage. However, we could not compare the CT findings according to different stages of disease due to the

relatively small number of our patients. Last, the imaging techniques used for CT examinations were heterogeneous because of the observations made extended over a long time.

In conclusion, LRTIs due to PIV, influenza virus, and RSV each have characteristic features in CT images despite considerable overlap between them. Our findings could help in the early differentiation of these viruses and the empirical use of appropriate antiviral agents.

#### References

- Woodhead M, Blasi F, Ewig S, et al. Guidelines for the management of adult lower respiratory tract infections – full version. *Clin Microbiol Infect* 2011;17(suppl 6):E1–59.
- Woodhead M, Blasi F, Ewig S, et al. Guidelines for the management of adult lower respiratory tract infections. *Eur Respir J* 2005;26:1138–80.
- Graffelman AW. Dept of General Practice, Leiden University Medical Center, Leiden University, Lower Respiratory Tract Infections in Adults: A Clinical Diagnostic Study in General Practice. 2005.
- Hong HL, Hong S B, Ko G B, et al. Viral infection is not uncommon in adult patients with severe hospital-acquired pneumonia. *PLoS One* 2014;9:e95865.
- Choi SH, Hong SB, Ko GB, et al. Viral infection in patients with severe pneumonia requiring intensive care unit admission. *Am J Respir Crit Care Med* 2012;186:325.
- Ruuskanen O, Lahti E, Jennings LC, et al. Viral pneumonia. *Lancet* 2011;377:1264–75.
- Pavia AT. Viral infections of the lower respiratory tract: old viruses, new viruses, and the role of diagnosis. *Clin Infect Dis* 2011;52(suppl 4):S284–9.
- Johansson N, Kalin M, Tiveljung-Lindell A, et al. Etiology of community-acquired pneumonia: increased microbiological yield with new diagnostic methods. *Clin Infect Dis* 2010;50:202–9.
- Johnstone J, Majumdar SR, Fox JD, et al. Viral infection in adults hospitalized with community-acquired pneumonia: prevalence, pathogens, and presentation. *Chest* 2008;134:1141–8.
- Jennings LC, Anderson TP, Beynon KA, et al. Incidence and characteristics of viral community-acquired pneumonia in adults. *Thorax* 2008;63:42–8.
- Angeles Marcos M, Camps M, Pumarola T, et al. The role of viruses in the aetiology of community-acquired pneumonia in adults. *Antivir Ther* 2006;11:351–9.
- Templeton KE, Scheltinga SA, van den Eeden WC, et al. Improved diagnosis of the etiology of community-acquired pneumonia with real-time polymerase chain reaction. *Clin Infect Dis* 2005;41:345–51.
- Rocha Neto OG, Leite RF, Baldi BG. Update on viral community-acquired pneumonia. *Rev Assoc Med Bras* 2013;59:78–84.
- Pavia AT. What is the role of respiratory viruses in community-acquired pneumonia?: what is the best therapy for influenza and other viral causes of community-acquired pneumonia? *Infect Dis Clin North Am* 2013;27:157–75.
- Vigil KJ, Adachi JA, Chemaly RF. Viral pneumonias in immunocompromised adult hosts. *J Intensive Care Med* 2010;25:307–26.
- Marcos MA, Esperatti M, Torres A. Viral pneumonia. *Curr Opin Infect Dis* 2009;22:143–7.
- Camps Serra M, Cervera C, Pumarola T, et al. Virological diagnosis in community-acquired pneumonia in immunocompromised patients. *Eur Respir J* 2008;31:618–24.
- Seemungal T, Harper-Owen R, Bhowmik A, et al. Respiratory viruses, symptoms, and inflammatory markers in acute exacerbations and stable chronic obstructive pulmonary disease. *Am J Respir Crit Care Med* 2001;164:1618–23.
- Wang Q, Zhang Z, Shi Y, et al. Emerging H7N9 influenza A (novel reassortant avian-origin) pneumonia: radiologic findings. *Radiology* 2013;268:882–9.
- Lee JE, Choe KW, Lee SW. Clinical and radiological characteristics of 2009 H1N1 influenza associated pneumonia in young male adults. *Yonsei Med J* 2013;54:927–34.
- Li P, Zhang JF, Xia XD, et al. Serial evaluation of high-resolution CT findings in patients with pneumonia in novel swine-origin influenza A (H1N1) virus infection. *Br J Radiol* 2012;85:729–35.
- El-Badrawy A, Zeidan A, Ebrahim MA. 64 Multidetector CT findings of influenza A (H1N1) virus in patients with hematologic malignancies. *Acta Radiol* 2012;53:662–7.

- [23] Marchiori E, Zanetti G, D'Ippolito G, et al. Swine-origin influenza A (H1N1) viral infection: thoracic findings on CT. *AJR Am J Roentgenol* 2011;196:W723–8.
- [24] Herbst T, Van Deerlin VM, Miller WT Jr. The CT appearance of lower respiratory infection due to parainfluenza virus in adults. *AJR Am J Roentgenol* 2013;201:550–4.
- [25] Ferguson PE, Sorrell TC, Bradstock K, et al. Parainfluenza virus type 3 pneumonia in bone marrow transplant recipients: multiple small nodules in high-resolution lung computed tomography scans provide a radiological clue to diagnosis. *Clin Infect Dis* 2009;48:905–9.
- [26] Gasparetto EL, Peron TC, Rocha Gde M, et al. High resolution computed tomography findings in parainfluenza virus pneumonia after bone marrow transplantation: case report. *Rev Port Pneumol* 2004;10:485–9.
- [27] Mayer JL, Lehnert N, Egerer G, et al. CT-morphological characterization of respiratory syncytial virus (RSV) pneumonia in immune-compromised adults. *Rofo* 2014;186:686–92.
- [28] Syha R, Beck R, Hetzel J, et al. Human metapneumovirus (HMPV) associated pulmonary infections in immunocompromised adults – initial CT findings, disease course and comparison to respiratory-syncytial-virus (RSV) induced pulmonary infections. *Eur J Radiol* 2012;81:4173–8.
- [29] Ko JP, Shepard JA, Sproule MW, et al. CT manifestations of respiratory syncytial virus infection in lung transplant recipients. *J Comput Assist Tomogr* 2000;24:235–41.
- [30] Qin J, Xu J, Dong Y, et al. High-resolution CT findings of pulmonary infections after orthotopic liver transplantation in 453 patients. *Br J Radiol* 2012;85:e959–65.
- [31] Ariza-Heredia EJ, Fishman JE, Cleary T, et al. Clinical and radiological features of respiratory syncytial virus in solid organ transplant recipients: a single-center experience. *Transpl Infect Dis* 2012;14:64–71.
- [32] Miller WT Jr, Mickus TJ, Barbosa E Jr, et al. CT of viral lower respiratory tract infections in adults: comparison among viral organisms and between viral and bacterial infections. *AJR Am J Roentgenol* 2011;197:1088–95.
- [33] Miller WT Jr, Barbosa E Jr, Mickus TJ, et al. Chest computed tomographic imaging characteristics of viral acute lower respiratory tract illnesses: a case-control study. *J Comput Assist Tomogr* 2011;35:524–30.
- [34] Shiley KT, Van Deerlin VM, Miller WT Jr. Chest CT features of community-acquired respiratory viral infections in adult inpatients with lower respiratory tract infections. *J Thorac Imaging* 2010;25:68–75.
- [35] Kanne JP, Godwin JD, Franquet T, et al. Viral pneumonia after hematopoietic stem cell transplantation: high-resolution CT findings. *J Thorac Imaging* 2007;22:292.
- [36] Franquet T, Rodriguez S, Martino R, et al. Thin-section CT findings in hematopoietic stem cell transplantation recipients with respiratory virus pneumonia. *AJR Am J Roentgenol* 2006;187:1085–90.
- [37] Escuissato DL, Gasparetto EL, Marchiori E, et al. Pulmonary infections after bone marrow transplantation: high-resolution CT findings in 111 patients. *AJR Am J Roentgenol* 2005;185:608–15.
- [38] Gasparetto EL, Escuissato DL, Marchiori E, et al. High-resolution CT findings of respiratory syncytial virus pneumonia after bone marrow transplantation. *AJR Am J Roentgenol* 2004;182:1133–37.
- [39] Franquet T, Muller NL, Gimenez A, et al. Infectious pulmonary nodules in immunocompromised patients: usefulness of computed tomography in predicting their etiology. *J Comput Assist Tomogr* 2003;27:461–8.
- [40] Kim EA, Lee KS, Primack SL, et al. Viral pneumonias in adults: radiologic and pathologic findings. *Radiographics* 2002;22(Spec No):S137–49.
- [41] Hansell DM, Bankier AA, MacMahon H, et al. Fleischner Society: glossary of terms for thoracic imaging. *Radiology* 2008;246:697–722.