



ELSEVIER

Contents lists available at ScienceDirect

Indian Heart Journal

journal homepage: www.elsevier.com/locate/ihj

Original Article

Comparison of distal radial access versus standard transradial access in patients with smaller diameter radial Arteries(The distal radial versus transradial access in small transradial ArteriesStudy: D.A.T.A - S.T.A.R study)

Yashasvi Chugh ^a, Naga Sasidhar Kanaparthi ^b, Shobhit Piplani ^c, Sunita Chugh ^d,
Adhir Shroff ^e, Mladen Vidovich ^e, James Nolan ^f, Mamas Mamas ^g,
Sanjay Kumar Chugh ^{d,*}

^a Minneapolis Heart Institute, Abbott Northwestern Hospital, Minneapolis, USA

^b Westchester Medical Center, Westchester County, NY, USA

^c Sawai Man Singh Medical College and Hospital, Jaipur, Rajasthan, India

^d Jaipur National University Hospital, Jaipur, Rajasthan, India

^e University of Illinois at Chicago, Chicago, IL, USA

^f Royal Stoke University Hospital, Stoke-on-Trent, United Kingdom

^g Keele Cardiovascular Research Group, Keele University, United Kingdom

ARTICLE INFO

Article history:

Received 18 December 2019

Accepted 3 November 2020

Available online 11 November 2020

Keywords:

Radial access
Distal radial access
Radial artery
Distal radial artery
Hand hematoma
Forearm hematoma
Small radial artery

ABSTRACT

Aims: To evaluate safety and efficacy of distal right radial access (DRRA) compared to right radial access (RRA), for coronary procedures, in patients with smaller diameter radial arteries (SDRA) (radial artery diameter (RAD) < 2.1 mm).

Methods and results: This is a retrospective analysis of safety and efficacy of DRRA Vs. RRA in patients undergoing coronary procedures at our cardiac catheterization laboratories over a 10- month period between September 2017 and June, 2018 (first 5 calendar months with RRA-first; next 5 calendar months with DRRA-first). All patients underwent pre-procedure ultrasound of arm arteries. All patients had RAD < 2.1 mm (mean RAD 1.63 ± 0.27 mm; RAD ≤ 1.6 mm in 73.5%). Baseline characteristics were similar between groups. Primary end-point of puncture success was significantly lower in DRRA vs RRA group [79.5% vs 98.5%, $p < 0.0001$]. Puncture success was also lower in the subgroup of patients with RAD < 1.6 mm Vs. ≥ 1.6 mm in the DRRA group ($p < 0.0001$). The secondary end-point of puncture time was significantly higher (2.1 ± 1.4 min vs. 1.0 ± 0.45 min, $p < 0.00001$) in the DRRA Vs. RRA group. The occurrence of vascular access site complications (including access site hematomas), radial artery occlusion (RAO) and distal RAO at day 1 and day 30 were similar between RRA and DRRA groups. Non-vascular access-site complication was seen only in the DRRA group.

Conclusion: DRRA is a safe and effective access for coronary procedures; though technically challenging in patients with SDRA (RAD < 2.1 mm; mean RAD 1.63 ± 0.27 mm), with lower puncture success and higher puncture time compared to RRA.

© 2020 Cardiological Society of India. Published by Elsevier B.V. This is an open access article under the CC BY-NC-ND license (<http://creativecommons.org/licenses/by-nc-nd/4.0/>).

Abbreviations: DRRA, Distal right radial access at anatomical snuffbox; RRA, Right radial access at wrist; RA, Radial artery; DRA, Distal radial artery; RAO, Radial artery occlusion; SDRA, Small diameter radial arteries; RAD, Radial artery diameter.

* Corresponding author. Department of Cardiology, Jaipur National University Hospital and Medical College, Institute for Medical Sciences and Research Center, Jaipur, Rajasthan, India.

E-mail address: skchughcardiology@yahoo.com (S.K. Chugh).

<https://doi.org/10.1016/j.ihj.2020.11.002>

0019-4832/© 2020 Cardiological Society of India. Published by Elsevier B.V. This is an open access article under the CC BY-NC-ND license (<http://creativecommons.org/licenses/by-nc-nd/4.0/>).

1. Introduction

Transradial access^{1,2} is associated with decreased mortality and reduced access site bleeding complications in high risk patient groups undergoing percutaneous coronary interventions and is recommended as a class 1 indication in acute coronary syndromes in the European Society of Cardiology guidelines.² Distal radial artery access (DRRA) at the anatomical snuffbox has been reported³⁻⁵

as a safe and feasible unique alternative to radial artery access at the wrist.³ The need for patent hemostasis with forearm radial access, to minimize risk of RAO,⁶ mandates close vigilance for bleeding to prevent forearm hematoma formation and enable its prompt effective management if it develops, to avert progression to a compartment syndrome. The latter risk may be less with DRRA as not only is the puncture site distal to the forearm, it may be more readily compressible.

Though right arm access is preferred² by most operators because of its ergonomic advantage; there is a lack of data on distal right radial access compared to RRA in patients with small diameter radial arteries (SDRA). We aimed to retrospectively analyze procedural performance, outcomes, safety and efficacy of distal right radial access (DRRA) compared to right radial access (RRA),⁹ for coronary diagnostic and interventional procedures, in patients with SDRA (RAD<2.1 mm).

2. Methods

2.1. Study Design

Fig. 1 This is a retrospective analysis of safety and efficacy of DRRA Vs. RRA in patients undergoing coronary procedures at our cardiac catheterization laboratories over a 10- month period between September 2017 and June, 2018. All patients underwent pre-procedure ultrasound of arm arteries. All patients had RAD <2.1 mm. Consecutive patients underwent procedures using RRA first in all cases from September, 2017 to January, 2018 (5 calendar months). Crossover to alternate access due to failure of RRA and use of access other than RRA qualified for exclusion. From February,

2018 till June, 2018 (5 calendar months), DRRA was used first in all cases. Patients who failed DRRA underwent RRA. Crossover to alternate access due to failure of RRA qualified for exclusion. Patients who underwent procedures by ulnar, femoral, brachial or left upper limb access were not included. Baseline characteristics were similar between groups. One operator experienced in transradial (approximately >15,000 transradial & and >500 prior distal radial procedures) performed all the interventions and another experienced in color Doppler ultrasound and echocardiography performed and read all the color Doppler ultrasounds.

2.2. Exclusion

- 1 From September, 2017 to January, 2018 (5 calendar months): Any access other than RRA; including crossover to alternate access were excluded.
- 2 From February 2018 till June, 2018 (5 calendar months): In case of failed DRRA; RRA was attempted; subsequent failure of which led to cross-over to an alternate access site; selection of which was based on the operator's judgment (left radial, left or right ulnar, right femoral, or high right radial) and subsequent exclusion from the study. Similarly, in case of puncture failure in the RRA group, access-site was crossed-over and the patients were excluded from the study. Patients who underwent procedures by ulnar, femoral, brachial or left upper limb access were not included.

Keeping in view our objective to assess the safety and efficacy of DRRA compared to standard RRA, in this population with SDRA, not only were those with poorly palpable DRA or RA not excluded; the same puncture and hemostasis techniques were used for both

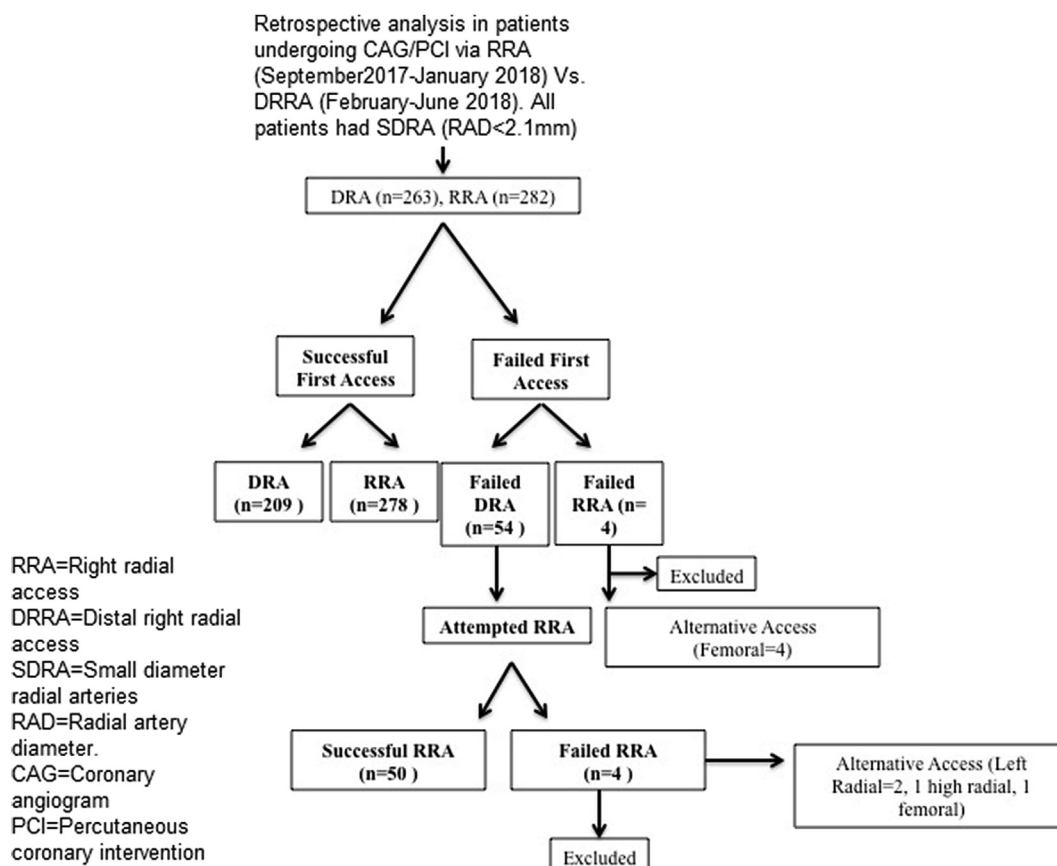


Fig. 1. Study design.

groups of patients and DRA measurement was not used to pre-select cases because no data exists for its cut-off value, below which DRRA is not recommended. Palpable pulse intensity was graded on a scale of 0–3; 0 indicating no palpable pulse, 1+ indicating faint pulse, 2+ indicating a normal pulse, and +3 indicating a bounding pulse.

Each participant gave written informed consent and the study was approved by the institutional ethics committee.

2.3. Study procedure

2.3.1. Color Doppler Ultrasound Imaging⁷

Each patient underwent an ultrasound examination of bilateral arm arteries (to assess radial artery diameter and brachial artery bifurcation/radial artery anomaly)⁷ prior to the cardiac catheterization procedure and at 1 & 30 day follow-up for RAO and distal RAO. The operator was blinded to the results of the forearm ultrasound. Color and pulsed Doppler assessment were undertaken for DRA occlusion in the anatomical snuffbox. Measurement of DRA diameter using ultrasound has been reported to be feasible only in DRAs with >2 mm diameter having straight course.⁸

Further, it is still unclear whether DRA diameter is smaller than or equal to ipsilateral RA,^{3,5,8-10} reflecting inconsistency in reproducibility of ultrasonographically assessed DRA diameter. Further, its role in pre-selection of cases for distal radial access is not established, just as with the utility of ultrasound-guided puncture; neither of which is mandatory for DRRA. Hence, neither was utilized.

2.3.2. Distal radial and transradial catheterization procedure

(i) **Cardiac Catheterization Procedure:** 0.5–1 mL of 2% lidocaine was used as local anesthetic.⁹ This dose was adequate for DRRA⁹ and RRA. Though there is no data on optimal dose of lidocaine, larger doses made palpation and hence puncture of the DRA

Or RRA difficult. The same access technique was used in both groups. The superiority of seldinger Vs. transfixion using metallic needle Vs. sheathed needle with anterior Vs. posterior puncture in DRRA is not established. All patients received 0.5 mL–1 mL Inj Midazolam and 25–50mcg of Inj Fentanyl administered in small aliquots slowly intravenously for sedation and analgesia; following which the access artery was punctured without ultrasound

guidance, using an over the needle cannula system (Jelco TM venous cannula (20-gauge venipuncture catheter needle)⁵ or Terumo sheathed needle, with transfixion or double wall puncture technique by intention, for both groups; as is our usual practice for RA access,^{7,11} even with SDRA (supplementary video-1). Anterior puncture, if it occurred incidentally, was accepted. Puncture of DRA was attempted along the course of DRA downwards from trapezium till the floor of the anatomical snuffbox (Fig. 2A–D) to avoid scraping the periosteum of carpals.

TerumoTM radial sheath was used (5 F or 6 F; per operator discretion) for coronary angiography (CAG) and angioplasty (PCI). Following cannulation, diltiazem (5 mg) and unfractionated heparin (5000 IU) were administered intra-arterially via the radial sheath for diagnostic catheterization (weight - adjusted 70 IU/kg heparin was given for those <50 or >80 kg); for angioplasty, additional dose of 1000–2000 IU of Heparin was given to maintain activated clotting time (ACT) at 250–300sec. Additional diltiazem (5 mg) was administered intra-arterially, with each catheter exchange and prior to sheath removal in all DRA and RA cases. TIG (Terumo TM) was the default catheter for CAG. Guide catheter selection for PCI was as per operator's discretion. Intra-arterial injection nitroglycerin (50mcg) administration, into access artery was optional at the discretion of the operator.

iii) **Hemostasis:** Though various techniques, from compression device to bandage to

Even manual compression have been used for hemostasis by different operators,^{3-5,9,10} the superiority of any one technique over the other is not established. Gauzeball/bandage roll (2.5 cm × 5 cm) and elastic bandage (5 cm × 15 cm) without patent hemostasis⁶ was used in both groups (Fig. 3A–F) per our routine practice with RA access,^{5,10,12} on account of its overall simplicity and to maintain homogeneity between groups especially since the feasibility and relevance of patent hemostasis is not established in DRRA.

The bandage was loosened 1 h post-procedure followed by palpation of hand and forearm¹³ proximal to bandage every 3 min for 1 h for early detection of hematoma. Per our usual practice, patients were discharged 3 h after a coronary angiogram; with advice to remove the bandage 12 h later.

Patient demographics including left ventricular ejection fraction and hemodynamic instability; pre-procedural characteristics, palpability of DRA and RA (poorly- or well-palpable), ultrasound data (radial diameter and anomalies), patient anxiety (on a scale of

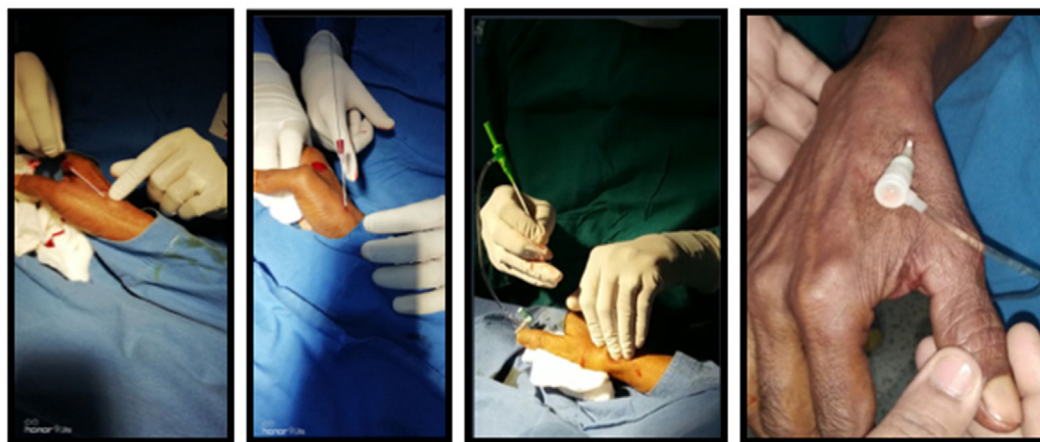

Fig. 2. Hand position for distal radial artery puncture: approximately 30° short of full pronation with <15° extension and variable ulnar flexion at the wrist with the patient's forearm by the side. The extent of wrist extension and ulnar flexion were varied per operator discretion, to optimize palpability of the DRA. Fig. 2(A–D). (Left to Right): Distal radial artery was cannulated in the anatomical snuff. Box which is on dorsal surface of hand formed anteriorly by Abductor Polices Longus and Extensor Polices Brevis, Posteriorly by Extensor Polices Longus, Base by styloid process of radius, Floor by scaphoid and trapezium bones. Fig. 2A: showing puncture of DRA using Jelco canula. Fig. 2B: Sheath wire inserted. Fig. 2C: Sheath inserted over the wire. Fig. 2D: Sheath successfully inserted in the DRA.

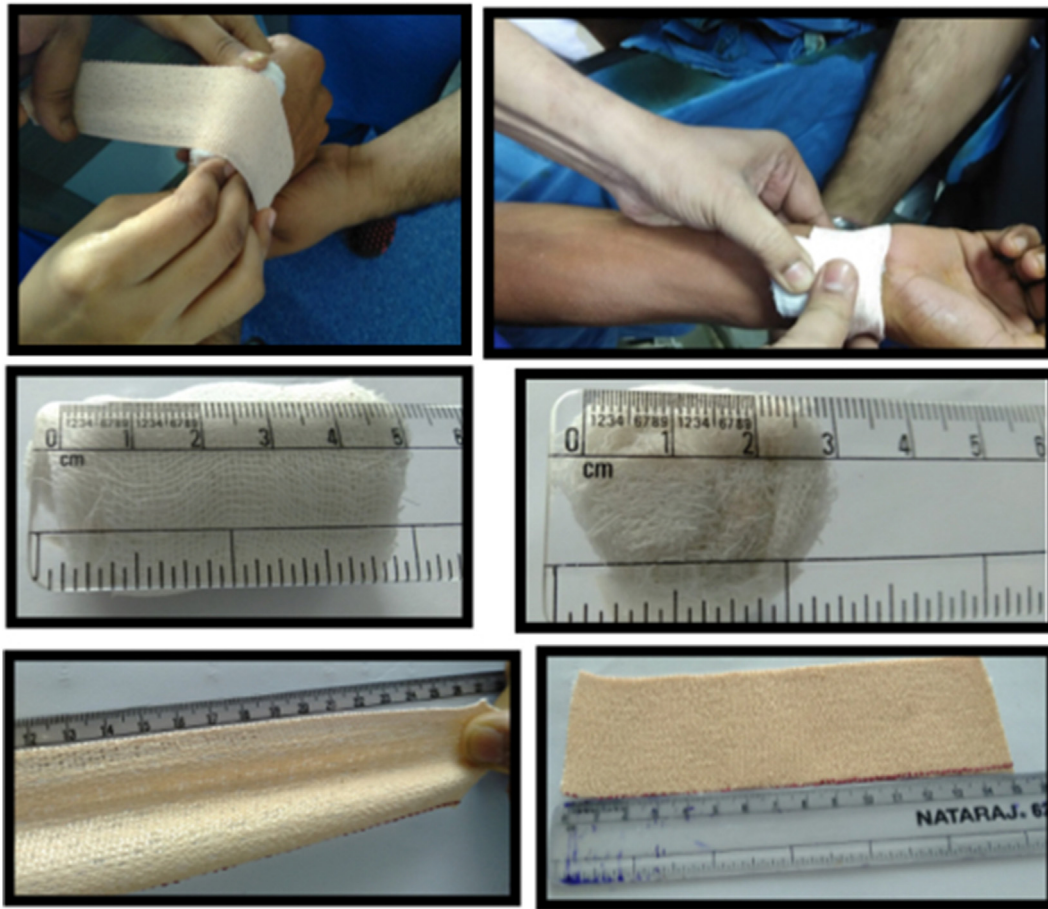


Fig. 3. Hemostasis for DRRA and RRA was achieved using a gauze ball and elastic bandage technique (G-BAND) Fig. 3 (A–F) (Left to Right): A) Technique of placing bandage roll and elastic bandage application for DRRA (B) and RRA (C) Dimensions of Bandage Roll: 5 cm in length (D) and 2.5 cm in diameter (E) length of fully stretched bandage (27 cm) (F) length at baseline 15 cm. Width of elastic bandage was 5 cm.

3: mild to severe), procedural characteristics, \geq grade 2/3 pain during puncture (scale 1–3), anterior vs posterior punctures, periprocedural radial artery spasm (\geq grade 3/4 of spasm grading by Chugh et al)⁷; and study end-points were recorded (Table I-II).

Radial artery occlusion (RAO) and distal RAO were also recorded on days 1 and 30 post-procedure, clinically by palpating the radial artery & distal radial artery, with simultaneous compression of ipsilateral ulnar artery & by color Doppler ultrasound.⁷ All clinical assessments were performed by an experienced reader.

2.4. Study end-points

2.4.1. Primary end-points

Puncture Success was defined as successful insertion of the radial sheath. Reason for puncture failure was recorded (inability to obtain bleed back in the hub of the needle; inability to insert length of sheath wire into the DRA after achieving bleed back into the needle hub; inability to insert sheath successfully into DRA).

2.4.2. Secondary end-points

Puncture Time (Intra-procedural) was defined as the time taken from first contact of puncture needle with skin to successful cannulation of the access artery with uninterrupted smooth passage of length of sheath wire. Puncture was discontinued per operator discretion or after 5 min in primary angioplasty cases. Reason for prolonged puncture time was noted (delay in obtaining

bleed back in the needle hub from puncture of the DRA; delay in cannulating the DRA with wire and/or sheath).

Radial Artery Occlusion (RAO) on Color Doppler Ultrasound (Day 1 & 30) Defined as slow flow or no flow on 2D color Doppler, or low velocity signal on pulsed doppler or monophasic flow in a previously blocked radial suggesting collateral flow.

Distal Radial Artery Occlusion on Color Doppler Ultrasound (Day 1 & 30) Defined as flow reversal on color Doppler ultrasound in the radial artery in anatomical snuffbox.

Vascular Access Site Complications (VASC): Included forearm hematomas (≥ 5 cm) and hematomas localized to hand (due to bleeding and extravasation); compartment syndrome, pseudo-aneurysm formation, dissection and AV fistulas. To prevent progression to compartment syndrome, any patient whose forearm hematoma was ≥ 5 cm, was closely monitored, together with compression all along the radial artery in the forearm using gauze and bandage; in addition inflation of a sphygmomanometer cuff on the arm to above systolic blood pressure (with intermittent deflations).¹³ For 'hand' hematomas, additional gauze and bandages were applied on palmar and dorsal aspect of the hand, at the DRA site. A plethysmograph probe on the index finger or thumb of the affected hand was used to monitor for hand-ischemia.

Non -Vascular Access Site Complications: any access-site related permanent or temporary, motor or sensory nerve injury including localized transient numbness and paresthesia at 1 and 6 weeks corroborated by a neurological evaluation.

Table 1
Patient Demographics and Pre-procedural ultrasound characteristics.

	Right Radial Group (n = 282)	Distal Right Radial Group (n = 263)	p Value
Clinical Characteristics			
Age, y	53.8 ± 12.9	55.1 ± 11.9	0.21
Females/Male	84/198 (29.7%/70.3%)	79/184 (30%/70%)	0.95
Weight (kg)	65.6 ± 9.7	64.0 ± 9.0	0.94
Height (cm)	169.3 ± 7.0	169.4 ± 7.5	0.59
BMI	22.8 ± 3.6	22.3 ± 3.1	0.66
Tobacco Smoker/Chewer	200 (70.9%)	156 (59.3%)	0.004
CPD	52 (18.4%)	36 (13.6%)	0.132
Hypertension	34 (12%)	32 (12.1%)	0.968
Diabetes Mellitus	37 (13.1%)	37 (14%)	0.747
Heart Failure with EF ≤ 40%	44 (15.6%)	49 (18.6%)	0.35
Hemodynamic Instability	45 (15.9%)	61 (23.1%)	0.06
Previous procedure using same access	70 (24.8%)	61 (23.1%)	0.56
Forearm Ultrasound			
RA size (mm) (mean ± SD)	1.59 ± 0.27	1.62 ± 0.26	0.948
RA size, Males	1.63 ± 0.27	1.66 ± 0.27	0.26
RA size, Females	1.46 ± 0.22	1.51 ± 0.21	0.17
Vascular Anomalies			
Intimal Thickness	0 (0%)	2 (0.8%)	0.18
Parallel Radial Artery	6 (2.1%)	13 (4.9%)	
Radial Artery Loop	1 (0.4%)	1 (0.4%)	
Accessory Radial Artery	1 (0.4%)	0 (0%)	
Occluded Artery	1 (0.4%)	3 (1.1%)	

Composite Secondary End Point: including hematoma, non vascular access site complications, RAO, and DRAO at day 1.

2.5. Statistical analysis

Descriptive statistics were used for initial analysis. Continuous data are presented as mean with SD. Dichotomous data and categorical data was presented as percentages. Difference between groups of continuous data were examined using the Fischer exact or Student *t* test and the chi-square test was used to compare dichotomous and categorical data. Statistical significance was assumed at a value of *p* < 0.05. All statistical analyses were performed with STATA for Windows. The sample size calculation was performed assuming primary endpoint of puncture success as 98.7%⁷ in RRA group and 88.6% in the DRRRA group⁴. Overall, 120 patients per group (total = 240) were deemed adequate to achieve 90% power considering an alpha error of 0.05. We identified potential variables that may influence our primary end-point with a

univariate logistic regression model. A multi-variate logistic regression model with all clinically relevant variables was then established to estimate odds ratios (ORs) with 95% confidence bounds.

3. Results

After exclusions, as per Figure- 1; 545 patients were included in the study. Pre-procedural (Table 1) and procedural characteristics (Table II) were similar between the groups. Pain (≥grade2/3) was not reported during DRRRA. Finally, 328 people underwent successful RRA and 209 underwent successful DRRRA (Fig. 1). In three cases, DRRRA was used for coronary angiogram; following which the sheath was removed and gauze/bandage applied. The patients underwent coronary angioplasty a few hours later through the RRA with gauze/bandage still on at the DRRRA site.

Table 2
Procedural characteristics and Secondary end-points in RRA vs. DRRRA groups.

	Right Radial (RRA) Group (n = 328)	Distal Right Radial (DRRA) Group (n = 209)	p Value
Procedural Characteristics			
Sheath Size			
5 F	156	107	
6 F	172	102	0.41
Procedure Type			
Coronary Angiogram	236	152	
PCI (Single vessel)	79	45	
PCI (Two vessel)	2	1	
Primary PCI	11	11	0.67
Radial Artery Spasm	3 (0.9%)	3 (1.4%)	0.31
Puncture Time (min)	1.17 ± 0.8	2.08 ± 0.9	0.0001
Vascular Access Site Complications	2 (0.6%)	4 (1.9%)	0.16
Non Vascular Access Site Complications	0 (0%)	3 (1.4%)	0.031
Radial Artery Occlusion			
Day 1	8 (2.4%)	5 (2.4%)	0.97
Day 30	7 (2.1%)	6 (2.9%)	0.58
Distal Radial Artery Occlusion			
Day 1	8 (2.4%)	5 (2.4%)	0.93
Day 30	5 (1.5%)	6 (2.8%)	0.28

*PCI: Percutaneous Coronary Intervention.

3.1. Primary endpoint

Of the 263 patients in DRRA group, 209 had puncture success, and 54 had puncture failure. Puncture success was significantly lower in the DRRA compared to RRA group (79.5% vs 98.5%, $p < 0.0001$). After excluding the patients with poorly palpable DRA ($n = 31$), puncture success was 88.7% vs 98.5% for DRRA Vs. RRA, $p < 0.0001$. The reasons for puncture failure were: no bleed back in the needle hub ($n = 13$); inability to insert sheath wire into DRA ($n = 36$); and inability to insert sheath into DRA in ($n = 5$) patients. All patients who had puncture success had procedure success; though in 8 cases, the procedure was completed using alternative access and these patients were therefore excluded from the study (Fig. 1).

We performed multivariate logistic regression analysis using the following clinical variables: age, sex, BMI, hemodynamic status (stable vs. unstable), radial artery diameter (<1.6 vs. ≥ 1.6 mm),¹⁴ patient anxiety. Although RAD was unrelated to puncture success or time, there were more puncture failures in patients with RAD <1.6 mm vs. ≥ 1.6 mm¹⁴ in the both groups. (Table III)

3.2. Secondary endpoints

3.2.1. Puncture time

Secondary end-point of puncture time was significantly longer in patients with DRRA compared with RRA (2.1 ± 1.4 min vs. 1.0 ± 0.45 min, $p < 0.00001$). Prolonged puncture time occurred because of delay in obtaining bleed back in the needle from puncture of the distal radial artery in 37%; in 63% it occurred from delay in cannulating the distal radial artery with wire and/or sheath.

3.2.2. Radial Artery Occlusion

Rates of RAO at Day 1 and 30 (2.4% vs 2.4%, $p = 0.97$ and 2.1% vs. 2.9%, $p = 0.58$ respectively) were similar in both groups (DRRA vs. RRA).

3.2.3. Distal radial artery occlusion

Distal RAO on Day 1 & 30 were 2.4% vs. 2.5% ($p = 0.93$) and 2.8% vs. 1.5% ($p = 0.28$) respectively (DRRA vs RRA).

3.2.4. Access -site complications

Vascular access-site complications were similar in both DRRA (Fig. 4A–B) and RRA groups (1.9% vs. 0.35%, $p = 0.12$). Forearm hematomas occurred only with RRA and hematomas in the DRRA group were localized only to the hand and were managed successfully.¹³ Non-vascular complications were limited to localized transient paresthesia, with mild sensory impairment (at 1 week, resolved in all patients by 6 -week follow-up) over the dorsum of the hand in the region of anatomical snuff box: seen in 3/209 DRRA cases (1.4%) vs. 0% in RRA group ($p = 0.031$)

Subgroup of patients with radial artery diameters <1.6 mm and ≥ 1.6 mm and their outcomes (Table III) Majority (73.5%) patients had RAD <1.6 mm. The distribution of patients with RAD <1.6 mm was 239/328 and 148/209 patients in the RRA Vs. DRRA groups respectively (Table III).

3.3. DRRA group

Numerically higher rates of RAO and DRAO at days 1 and 30 as well as higher puncture failures were seen in patients with RAD <1.6 mm V patients with RAD ≥ 1.6 mm ($p < 0.0001$); however puncture times were similar in both groups. Further, higher rates of a composite of hematomas, non-vascular access-site complications, RAO & DRAO at Day 1 were seen ($p < 0.001$) in the subgroup with RAD <1.6 mm.

3.4. RRA group

Patients with radial artery diameters (<1.6 mm) had higher puncture times ($p < 0.05$) and lower puncture success. Vascular access site complications, RAO and DRAO on ultrasound at Day 1 and Day 30, were also higher in these patients though not statistically significant. However, higher rates of a composite of hematomas, non -vascular access site complications, RAO & DRAO at Day 1 were seen ($p < 0.001$).

4. Discussion

The use of DRA for coronary procedures, has been shown to be feasible³⁻⁵ in small observational studies. To the best of our knowledge, unlike most current studies on distal left radial access^{4,5}; this is the first study comparing puncture success, puncture time and vascular and non-vascular access site complications of DRRA with RRA in patients with SDRA.

Unlike previous studies^{4,5,9,10} in which poorly-palpable DRA, reported in upto 41% patients, were excluded; our study included all-comers without pre-selection, including those with a weak and poorly-palpable DRA pulse, with the aim to assess DRA as a safe and effective access compared to RRA. The puncture success was therefore lower (79.5%) and puncture time was prolonged in our study. Also, after excluding only those with poorly-palpable DRA, our puncture success rate in DRRA group was 88.7%; with a failure rate of 11.3% compared to 10% reported in other studies which carefully selected study patients and excluded those unsuitable for DRA.^{3-5,9,10} This failure rate in DRRA reported across studies is attributable to the unique anatomical challenges of DRA including (i) angulation and tortuosities in the DRA in its course over the trapezius to the floor of anatomical snuffbox, and (ii) presence of branches of the deep palmar arch, of which the DRA too is a branch. However, since the RA in the forearm does not have any of these unique challenges; puncture failures and puncture time were considerably less in the RRA group.

Further, though debatable, DRA diameter is generally believed to be smaller^{3,5,8-10} than the RA. This may help explain the higher puncture failure of DRA Vs RRA when used as default access. Again, because the mean RAD (1.63 ± 0.27 mm) in our study population was smaller than the reported mean RAD (>2.1 mm) in other studies^{3,5,9,10}; puncturing a proportionately smaller DRA was even more challenging with more puncture failure and longer puncture time. Not only does this explain an even higher puncture failure rate in the DRRA group in our study compared to that in other studies^{5,9,10}; it also explains a higher DRRA puncture success rate after exclusion of patients with poorly-palpable DRA from the DRRA group. Again, although the higher puncture failure in DRRA group may be because ultrasound -guided puncture was not used, there is no data to support this and even data on ultrasound-guided RA puncture has limitations.¹⁵ Further, because a majority of our study patients had a radial artery diameter of <1.6 mm, such higher failure rate with DRRA is not unexpected. South East Asians are known to have smaller radial arteries, increasing their risk of procedural complications and puncture failure compared to their Caucasians.¹⁶ Also, prior adequate experience of the operator with coronary procedures via RRA and DRRA rules out the possibility of learning curve being responsible for higher puncture failures in DRRA group in the study.

A trend for a higher hematoma rate, localized to the hand only was observed in the DRRA group (Fig. 3), and is attributed to a greater number of failed puncture attempts over the DRA, with resultant trauma to the artery and its small branches in the snuff box. None of these patients had remote forearm bleed from puncture of a perforator or branch by wire in the study. Though the higher incidence of 'hand' hematoma may have been because of use

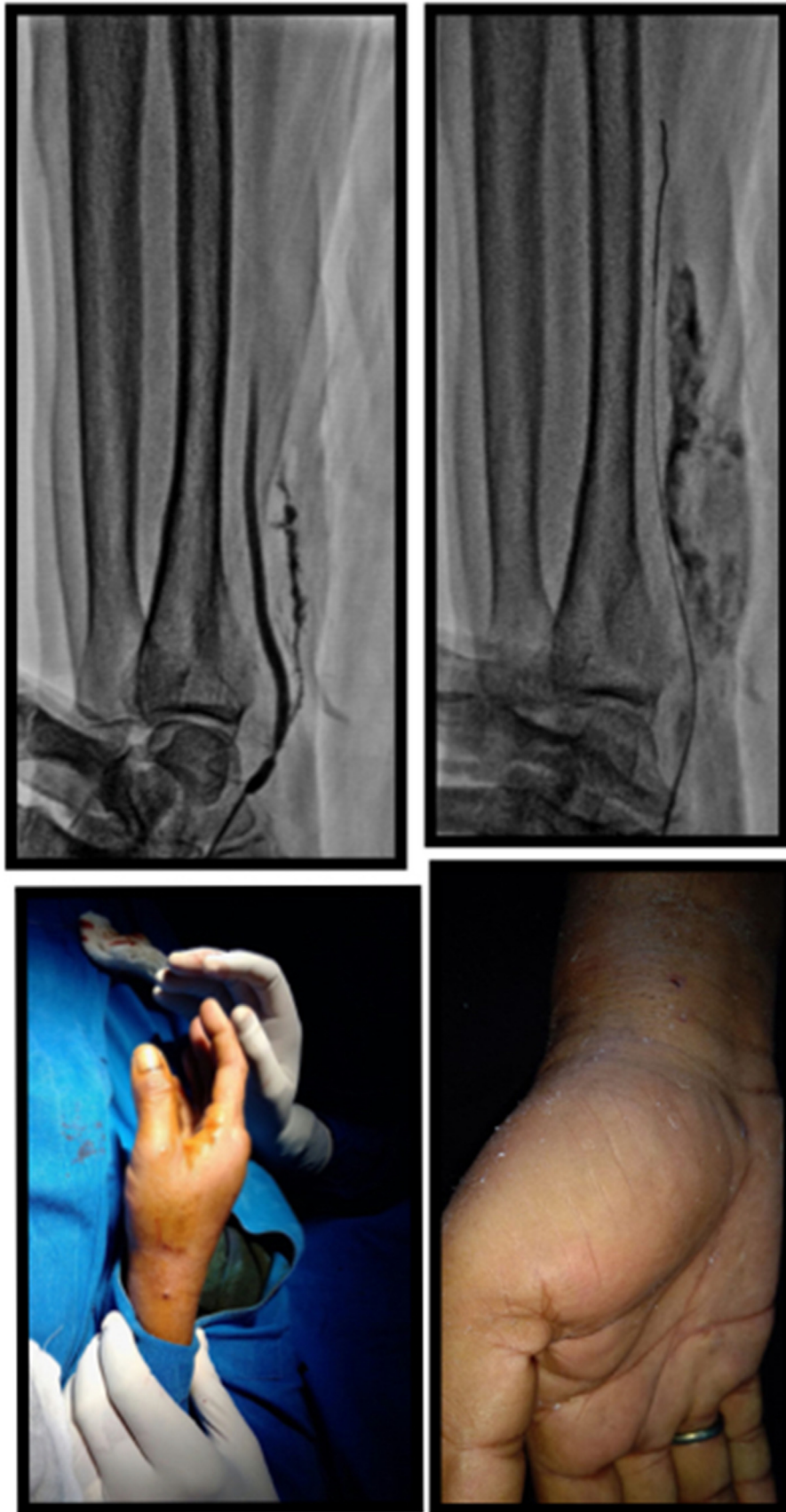

Fig. 4. (A,B) (left to right) Complication of distal right radial access: Hand hematoma following DRRA, localized to hand (A) Dorsal (B) palmar aspect of hand.

Table III
Outcomes in patients with radial artery diameters <1.6 mm vs ≥1.6 mm.

	Radial Artery Diameter <1.6 mm	Radial Artery Diameter ≥1.6 mm	p Value
DRRA Group	(n = 148)	(n = 61)	
Puncture Success (%)	77.5%	89.8%	0.0001
Puncture Time (min)	2.02 + 1.43	2.19 + 1.43	0.48
Vascular Access Site Complications	4 (1.7%)	0 (0%)	0.21
Non Vascular Access Site Complications	3 (1.4%)	0 (0%)	0.21
Radial Artery Occlusion			
Day 1	4 (2.7%)	1 (1.6%)	0.34
Day 30	6 (4.1%)	0 (0%)	0.11
Distal Radial Artery Occlusion			
Day 1	5 (2.1%)	0 (0%)	0.16
Day 30	5 (2.1%)	1 (1.6%)	0.71
Composite Secondary Endpoint *	16 (10.8%)	1 (1.6%)	0.001
RRA Group	(n = 239)	(n = 89)	
Puncture Success (%)	96%	100%	0.05
Puncture Time (min)	1.20 + 0.82	0.76 + 0.34	0.05
Vascular Access Site Complications	1 (0.7%)	1 (1.6%)	0.51
Non Vascular Access Site Complications	0 (0%)	0 (0%)	0.42
Radial Artery Occlusion			
Day 1	7 (2.9%)	1 (1.1%)	0.64
Day 30	6 (2.5%)	1 (1.1%)	0.44
Distal Radial Artery Occlusion			
Day 1	5 (2.1%)	1 (1.1%)	0.56
Day 30	4 (1.7%)	1 (1.1%)	0.49
Composite Secondary Endpoint ^a	13 (5.4%)	3 (3.3%)	0.001

^a Composite of access site hematoma, non -vascular access site complications, radial artery occlusion day 1, and distal radial artery occlusion day 1.

of gauze and bandage for DRRA hemostasis; there is no published data to support this possibility. On the contrary, because of gauze and bandage use in both DRRA and RRA, there was homogeneity in hemostasis technique allowing for meaningful comparison between groups. Forearm hematomas occurred only in the RRA group and with our prompt, aggressive management¹³ of forearm hematomas ≥5 cm; none of our patients developed compartment syndrome.¹⁷

Transient numbness over the region of the snuffbox (corroborated on neurological assessment), only reported in the DRRA group, was likely due to inadvertent trauma of sensory branches of the superficial radial nerve in the proximity during puncture. All patients that developed this complication had a radial artery diameter <1.6 mm, which may have contributed to increased puncture attempts and in-turn neurological injury to the snuff box.

Though not powered for small differences in RAO; RAO was similar ($p = NS$) in both groups with similar baseline characteristics (Tables. I-II), with use of same technique for puncture and hemostasis, with same sheath length, as well as artery/sheath ratio based on usage of comparable 5 F and 6 F sheaths; comparable radial artery spasm, and other procedural characteristics.

Contrary to the lower RAO reported with DRRA in earlier studies which were also not powered for conclusion,^{3,9} our study found similar rates of RAO and DRAO between groups, and the reasons were: (i) direct (puncture site) and indirect (presence of sheath within vessel) radial artery endothelial injury^{19,20}; (ii) spasm in the RA; (iii) low-flow between sheath and radial artery related to RA: sheath mismatch^{7,13} especially in SDRA; all substrates for thrombosis and precursors of RAO.¹⁹ Though it is unclear whether RAO would have been different between groups, had patent hemostasis been used; it seems extremely unlikely, because the RAO rate in our study with the gauze-ball and bandage technique, but without patent hemostasis was comparable to that reported with patent hemostasis in PROPHET II²⁵.

Unlike in the PROPHET trial^{6,18} which used only plethysmography to assess radial artery patency; in our study, RAO (and DRAO) were diagnosed with greater accuracy using doppler ultrasound.¹⁸

Patent hemostasis has been shown to reduce the rate of RAO⁶ while larger sheaths have been found to be associated with higher RAO¹⁹; yet, with use of bigger sheaths (6 F Vs 5 F. in 52.4% Vs, 47.6%) and *without* patent hemostasis, RAO was 2.9% in the standard radial group in our study, compared to 3% RAO reported in PROPHET II study²⁵ which used patent hemostasis, smaller (5 F) sheaths in 100% and did not include any PCI cases in the study. One definite advantage of using DRRA as default is that the RA in forearm may be available for repeat procedures in situations where DRRA is occluded or inaccessible because of hematoma or tenderness from a recent prior procedure. Our study has some important limitations; (i) Like many other initial publications on the subject,^{4,9,10} this too was a non-randomized, single center, single operator retrospective analysis (ii) The study was not powered to detect a small difference in RAO between groups (iii) As per our usual practice, patent hemostasis was not used; though this helped meaningful comparison by maintaining homogeneity between groups (v) The findings may not be applicable to other ethnic groups with larger RA diameters (vi) Ultrasound guided puncture was not used (vi) DRA diameter was not measured.

5. Conclusion

DRRA is a safe and effective access for coronary procedures; though technically challenging in smaller diameter radial arteries, with lower puncture success and higher puncture time compared to RRA. The rates of vascular complications, RAO and distal RAO are similar between RRA and DRRA groups. Larger randomized trials are needed to further evaluate advantages of DRRA over RRA.

Conflict of interests

None to report for all co-authors.

Funding disclosures

No disclosure for all co-authors.

Appendix A. Supplementary data

Supplementary data to this article can be found online at <https://doi.org/10.1016/j.ihj.2020.11.002>.

References

- Kiemeneij F, Laarman GJ. Percutaneous transradial artery approach for coronary stent implantation. *Cathet Cardiovasc Diagn*. 1993;30(2):173–178.
- Martial H, Christian P, Carlo DM, et al. Consensus document on the radial approach in percutaneous cardiovascular interventions: position paper by the European association of percutaneous cardiovascular interventions and working groups on acute cardiac care and thrombosis of the European society of Cardiology. *EuroIntervention*. 2013;8:1242–1251.
- Kaledin AL, Kochanov IN, Podmetin PS, Seletsky SS, Ardeev V. *Distal radial artery in endovascular interventions*. 2017. <https://doi.org/10.13140/RG.2.2.13406.33600>.
- Kiemeneij F. Left distal transradial access in the anatomical snuffbox for coronary angiography (ldTRA) and interventions (ldTRI). *EuroIntervention*. 2017;13(7):851–857.
- Lee JW, Park SW, Son JW, Ahn SJ, Lee SH. Real-world experience of the left distal transradial approach for coronary angiography and percutaneous coronary intervention: a prospective observational study (LeDRA). *EuroIntervention*. 2018;14:995–1003.
- Pancholy S, Coppola J, Patel T, Roke-Thomas M. Prevention of radial artery occlusion-patent hemostasis evaluation trial (PROPHET study): a randomized comparison of traditional versus patency documented hemostasis after transradial catheterization. *Cathet Cardiovasc Interv*. 2008;72(3):335–340.
- Chugh S, Chugh S, Chugh Y, Rao SV. Feasibility and utility of pre-procedural ultrasound imaging of the arm to facilitate transradial coronary diagnostic and interventional procedures (PRIMAFACIE-TRI). *Cathet Cardiovasc Interv*. 2013;82:64–73.
- Hull E, Kinsey EN, Bishop WL. Mapping of the snuffbox and cubital vessels for percutaneous arterial venous fistula (pAVF) in dialysis patients. *J Vasc Access*. 2013;14(3):245–251.
- Flores EA, Todd R. Use of the distal radial artery (DRA) in the anatomical snuffbox as a default access in the cardiac catheterization laboratory. *Cathet Cardiovasc Interv*. 2018;91(Suppl 2):S218.
- Valsecchi O, Vassileva A, Cereda AF, et al. Early clinical experience with right and left distal transradial access in the anatomical snuffbox in 52 consecutive patients. *J Invasive Cardiol*. 2018;30(6):218–223.
- Chugh SK. Tips and tricks for transradial interventions. In: Chugh SK, ed. *Handbook of Transradial Interventions*. Oxford University Press; 2021 (In press).
- Bertrand OF, Rao SV, Pancholy S, et al. Transradial approach for coronary angiography and interventions: results of the first international transradial practice survey. *JACC Cardiovasc Interv*. 2010;3(10):1022–1031.
- Chugh SK, Chugh Y, Chugh S. How to tackle complications in radial procedures: tip and tricks. *Indian Heart J*. 2015;67(3):275–281.
- Chugh SK, Chugh S, Chugh Y. Addressing the challenges of access of small radial and ulnar arteries in transradial and transulnar interventions: insights from a color Doppler study. *JACC (J Am Coll Cardiol)*. 2014;63(12):A442.
- Bhattacharjee S, Maitra S, Baidya DK. Comparison between ultrasound-guided technique and digital palpation technique for radial artery cannulation in adult patients: an updated meta-analysis of randomized controlled trials. *J Clin Anesth*. 2018;47:54–59.
- Rathore S, Stables RH, Pauriah M, et al. Impact of length and hydrophilic coating of the introducer sheath during transradial coronary intervention: a randomized study. *JACC Cardiovasc Interv*. 2010;3(5):475–483.
- Tizon-Marcos H, Barbeau GR. Incidence of compartment syndrome of the arm in a large series of transradial approach for coronary procedures. *J Interv Cardiol*. 2008;21(5):380–384.
- Pancholy SB, Bernat I, Bertrand OF, Patel TM. Prevention of radial artery occlusion after transradial catheterization: the PROPHET-II randomized trial. *JACC Cardiovasc Interv*. 2016;9(19):1992–1999.
- Rashid M, Kwok CS, Pancholy S, et al. Radial artery occlusion after transradial interventions: a systematic review and meta-analysis. *J Am Heart Assoc*. 2016;5, e002686. <https://doi.org/10.1161/JAHA.115.002686>.
- Yonetsu T, Kakuta T, Lee T, et al. Assessment of acute injuries and chronic intimal thickening of the radial artery after transradial coronary intervention by optical coherence tomography. *Eur Heart J*. 2010;31(13):1608–1615.