



# External Auditory Canal: Computed Tomography Analysis and Classification

Mohammad Waheed El-Anwar<sup>1</sup> Yasser Ahmed Fouad<sup>1</sup> Ahmed Fouad Elgohary<sup>1</sup> Sameh Saber<sup>2</sup>   
Mohamed Adel Mobasher<sup>1</sup>

<sup>1</sup> Department of Otorhinolaryngology-Head and Neck Surgery, Faculty of Medicine, Zagazig University, Zagazig, Egypt

<sup>2</sup> Department of Radiodiagnosis, Faculty of Medicine, Zagazig University, Zagazig, Egypt

Address for correspondence: Mohammad Waheed El-Anwar, MD, Otolaryngology, Head and Neck Surgery Department, Faculty of Medicine, Zagazig University, Zagazig, Egypt (e-mail: mwenteg1973@gmail.com).

Int Arch Otorhinolaryngol 2023;27(4):e565–e570.

## Abstract

**Introduction** Computed tomography (CT) details of the external auditory canal (EAC) are not fully covered in the literature, so building up base for the CT evaluation and description is important. Preoperative details of the EAC are mandatory before any approach or procedure involving the canal.

**Objective** To determine the different dimensions, measurements, and grading of the EAC by CT scan that were not previously published.

**Methods** The CT scans of 100 temporal bones (200 sides) were included. Axial images were acquired with multiplanar reformates to obtain delicate details in coronal and sagittal planes for all subjects.

**Results** At the EAC entry, the mean vertical length (height) was  $7.75 \pm 1$  mm, and its mean horizontal length (width) was  $6.1 \pm 0.8$ . At the bony cartilaginous junction of the EAC, the mean vertical length was  $7.88 \pm 1$  mm, and its mean horizontal length was  $6.22 \pm 0.9$ . At the EAC isthmus, the mean vertical length was  $6.8 \pm 0.97$  mm, and its mean horizontal length was  $5.2 \pm 0.76$ . At the medial end of the EAC, the mean vertical length was  $7.1 \pm 0.9$  mm, and its mean horizontal length was  $5.4 \pm 0.85$ . There were no reported significant differences between right and left sides in all dimensions. Males showed significantly longer vertical and horizontal dimensions of the EAC entry, vertical dimension of the isthmus, and vertical dimension of the medial end of the EAC than females.

**Conclusion** This study improves otologists and radiologists' awareness of EAC variations in the ear field and can be of help to residents in training.

## Keywords

- ▶ external auditory canal
- ▶ ear
- ▶ computed tomography
- ▶ isthmus
- ▶ endoscopic ear surgery

## Introduction

The external auditory canal (EAC) has a unique anatomy that is adapted for its auditory and nonauditory functions. The auditory functions of EAC are related to sound transmission

to the tympanic membrane (TM), while its nonauditory functions are related to protection of the middle and inner ear from trauma or environmental changes.<sup>1</sup> Anatomically, the EAC is approximately 2.5 cm in length. Its outer third is cartilaginous and directed upward and backward, while its

received  
May 31, 2022  
accepted

June 30, 2022  
article published online  
September 19, 2023

DOI <https://doi.org/10.1055/s-0042-1758213>.  
ISSN 1809-9777.

© 2023. Fundação Otorrinolaringologia. All rights reserved.  
This is an open access article published by Thieme under the terms of the Creative Commons Attribution-NonDerivative-NonCommercial-License, permitting copying and reproduction so long as the original work is given appropriate credit. Contents may not be used for commercial purposes, or adapted, remixed, transformed or built upon. (<https://creativecommons.org/licenses/by-nc-nd/4.0/>)

Thieme Revinter Publicações Ltda., Rua do Matoso 170, Rio de Janeiro, RJ, CEP 20270-135, Brazil

medial two thirds are osseous and directed downward and forward.<sup>2</sup> However, the diameter of the EAC is not well described in anatomic literature.

Regarding the surgical point of view, EAC plays a pivotal role during the selection of the surgical approach for the middle ear or TM surgery. The width of the EAC represents an important determining factor for the feasibility of the transcanal approach in the middle ear surgery.<sup>3</sup> With the advent of endoscopic ear surgery (EES), transcanal endoscopic approach became more popular between otosurgeons. However, EES through a narrow EAC remains a challenging surgical situation.<sup>4</sup> Therefore, evaluation of the diameter of the EAC should be considered before ear surgeries.

The width of the EAC can be roughly evaluated by using binocular microscopy and aural speculums.<sup>5</sup> Also, it can be roughly evaluated by using endoscopy through grading the endoscopic visibility of the TM.<sup>6</sup> However, both these methods do not accurately measure the diameter of the EAC, especially at the level of the isthmus.

Computed tomography (CT) is usually considered before ear surgery, not only to define the nature and extent of the current pathology, but also to provide more detailed information on the anatomical landmarks and variations that might affect the surgical procedure.<sup>4,7</sup> However, to the best of our knowledge, the details and normal dimensions of the EAC as seen by CT scans are not well covered in the literature.

Therefore, this study aimed to determine the different dimensions, measurements, and grading of the EAC, based on CT, that were not previously published. The results of the study may influence the otologists and neurotologists' approaches, especially for the endoscopic approach.

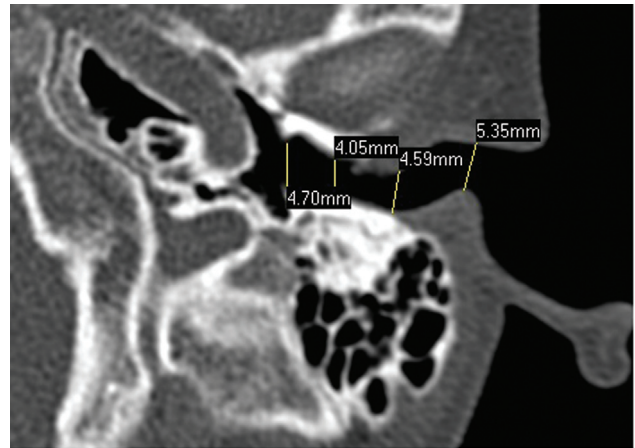
## Material and Methods

This retrospective analysis was conducted on 100 CT scans of the temporal bone (200 sides) at University Hospitals, during the period between July 2020 and May 2021. Informed written consent was signed by all subjects to share in the study after explanation of its purposes and the study was approved by the University's Institutional Review Board (IRB; 2019–66). Exclusion criteria were patients younger than 18 years, history of surgery or trauma in the ear or the skull base, and congenital anomalies, malignancies, and/or fibro-osseous lesions of the ear.

The CT examinations were performed for all the included patients with the Philips Ingenuity Core128 CT scanner (Koninklijke Philips N.V., Amsterdam, Netherlands). The protocol of 128-slice multidetector CT (MDCT) was performed with a 0.625 mm detector width, a 1.5 mm section width, and a 0.5 mm interval reconstruction.

Axial images were made covering the EAC. Examinations were conducted with window setting of 4000 window width, centered at 700 window level. A high resolution algorithm was utilized to enhance appearance of the delicate bony details.

Multiplanar reconstructions with delicate details in coronal and sagittal planes were obtained for all subjects at a dedicated postprocessing workstation Volume



**Fig. 1** Axial CT scan showed measurements of the horizontal dimensions (width) at EAC entry, bony cartilaginous junction, isthmus, and medial end.

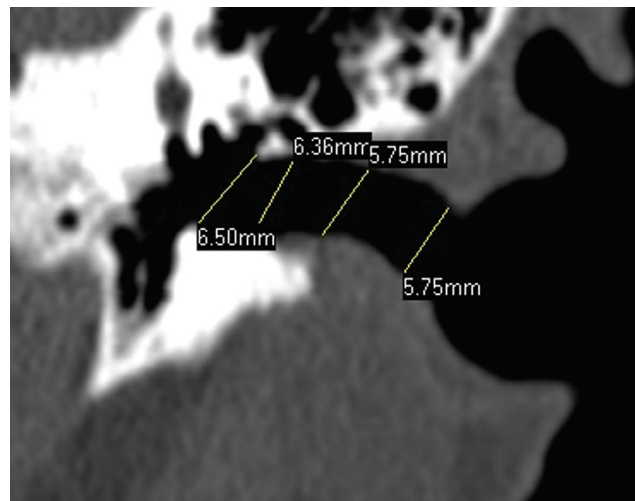
Share 4 / Advantage Workstation4.5 (GE Medical System, Milwaukee, WI, USA). Films were reviewed in a routine standardized manner in order not to miss small details.

The EAC evaluation was performed in all patients along the axial, coronal, and sagittal planes (►Figs. 1, 2). Vertical and horizontal dimensions were measured at entry, bony cartilaginous junction, isthmus, and at medial end of the EAC (►Figs. 1, 2). Statistical analysis was conducted using the Statistical Package Social Sciences (SPSS, Inc., Chicago, IL, USA) software, version 25.0. A *p*-value of < 0.05 was considered statistically significant.

## Results

A total of 100 CTs (200 sides) were included in the current study, for 43 males (49%) and 57 females (51%). The mean age was  $36.83 \pm 13.3$  years (range: 18–64 years).

At the entry of the EAC, the mean vertical length (height) was  $7.75 \pm 1$  mm (range: 5–10.9 mm), which was



**Fig. 2** Coronal CT scan showed measurements of the vertical dimensions (height) at EAC entry, bony cartilaginous junction, isthmus, and medial end.

**Table 1** Measurements (mm) of EAC dimensions (vertical and horizontal) at canal entry, bony cartilaginous junction, isthmus, and medial end of the EAC in 100 patients (200 ears)

		Mean	Range	p-value	t test
Age		36.83 ± 13.3	18–64		
Entry	Vertical	7.75 ± 1	5–10.9	<0.0001	18.2212
	Horizontal	6.1 ± 0.8	4.2–7.8		
Bony cartilaginous junction	Vertical	7.88 ± 1	5.5–10.6	<0.0001	17.4495
	Horizontal	6.22 ± 0.9	4.4–9.2		
Isthmus	Vertical	6.8 ± 0.97	4.5–9.8	<0.0001	18.1041
	Horizontal	5.2 ± 0.76	3.6–7.3		
Medial end of EAC	Vertical	7.1 ± 0.9	4.2–9.2	<0.0001	20.563
	Horizontal	5.4 ± 0.85	3.9–8.3		

Abbreviations: EAC, external auditory canal.

significantly longer ( $t = 18.2212, p < 0.0001$ ) than its mean horizontal length (antroposterior dimension, width) of  $6.1 \pm 0.8$  mm (range: 4.2–7.8 mm).

At the bony cartilaginous junction of the EAC (beginning of the bony EAC), the mean vertical length was  $7.88 \pm 1$  mm (range: 5.5–10.6 mm), which was significantly longer ( $t = 17.1041, p < 0.0001$ ) than its mean horizontal length of  $6.22 \pm 0.9$  mm (range: 4.4–9.2 mm) (►Table 1).

At the isthmus of the EAC (narrowest point of the bony EAC), the mean vertical length was  $6.8 \pm 0.97$  mm (range: 4.5–9.8 mm), which was significantly longer ( $t = 18.1041,$

$p < 0.0001$ ) than its mean horizontal length of  $5.2 \pm 0.76$  mm (range: 3.6–7.3 mm).

At the medial end of the EAC (drum), the mean vertical length was  $7.1 \pm 0.9$  mm (range: 4.2–9.2 mm), which was significantly longer ( $t = 20.563, p < 0.0001$ ) than its mean horizontal length of  $5.4 \pm 0.85$  mm (range: 3.9–8.3 mm). Therefore, the EAC (entry, bony cartilaginous junction, isthmus, and medial end) is oval in shape (►Table 1).

There were no reported significant differences between right and left EAC in all the CT dimensions ( $p > 0.05$ ) (►Table 2).

**Table 2** Measurements of the EAC dimension (mm) at its entry, at bony cartilaginous junction, isthmus, and medial end of the EAC at right and left sides

Range	Range	Mean		
18-64	36.83+ 13.3	36.83+ 13.3		Age
43 males (49%) and 57 females (51%)				Sex
5.1-10.6	7.77 + 1	Vertical	Right	Entry
4.2-7.8	6.17 + 0.8	Horizontal		
5-10.9	7.73 + 1	Vertical	left	
4.3-7.4	6.1 + 0.8	Horizontal		
5.5-10.3	7.89 + 1	Vertical	Right	Bony cartilaginous junction
5-9.1	6.24 + 0.8	Horizontal		
5.6-10.6	7.88 + 1	Vertical	Left	
4.4-9.2	6.2 + 0.89	Horizontal		Isthmus
4.5-9.8	6.785 + 0.99	Vertical	right	
3.9-7.2	5.187 + 0.75	Horizontal		
4.6-9.7	6.77 + 0.96	Vertical	left	
3.6-7.3	5.2 + 0.76	Horizontal		Medial end of EAC
4.2-9.1	7.1 + 0.93	Vertical	Right	
3.9-8.2	5.4 + 0.84	Horizontal		
5-9.2	7.12 + 0.9	Vertical	Left	
4-8.3	5.4 + 0.86	Horizontal		

Abbreviations: EAC, external auditory canal.

There was no significant difference in age between the study's males and female participants ( $p = 0.8744$ ). However, at the entry of the EAC, the mean vertical length in males was  $7.9 \pm 1.1$  mm, which was significantly longer ( $t = 2.0869$ ,  $p = 0.0382$ ) than in females (mean:  $7.6 \pm 0.93$  mm); furthermore, the mean horizontal length in males was  $6.28 \pm 0.87$  mm, significantly longer ( $t = 2.5213$ ,  $p = 0.0125$ ) than in females (mean:  $6 \pm 0.7$  mm).

At the bony cartilaginous junction of the EAC, the mean vertical length in males was  $8 \pm 1$  mm, which was not significantly longer ( $t = 1.4327$ ,  $p < 0.1535$ ) than its mean in females ( $7.8 \pm 0.96$  mm). While the mean horizontal length in males was  $6.2 \pm 0.88$ , it was near to that in females (mean:  $6.2 \pm 0.9$  mm).

At the isthmus of the EAC, the mean vertical length in males was  $6.97 \pm 0.9$  mm, which was significantly longer ( $t = 2.72$ ,  $p = 0.0071$ ) than its mean in females ( $6.6 \pm 0.99$  mm); and the mean horizontal length in males ( $5.12 \pm 0.75$  mm) was not significantly different from the one in females (range:  $5.25 \pm 0.76$  mm).

At the medial end of the EAC, the mean vertical length in males was  $7.3 \pm 0.85$  mm, which was significantly longer ( $t = 3.1033$ ,  $p = 0.0022$ ) than its mean in females. While the mean of horizontal length in males ( $5.4 \pm 0.87$  mm) did not significantly differ from that in females ( $5.4 \pm 0.84$  mm) (→ **Table 3**).

The EAC diameters were categorized at its narrowest site (isthmus) into grades. For vertical diameter at isthmus, the EAC was classified into grade 1 (from 4 to 6 mm), detected in

35 sides (17.5%); grade 2 (from 6 to 8 mm), detected in 143 sides (71.5%); and grade 3 (more than 8 mm), detected in 22 sides (11%). For the horizontal diameter (width) of the isthmus, the EAC was graded into grade 1 (from 3 to 5 mm), detected in 60 sides (30%); grade 2 (from 5 to 7 mm), detected in 138 sides (69%); and grade 3 (more than 8 mm), detected in 2 sides (1%).

## Discussion

The width of the EAC is an important factor in the feasibility and easiness of middle ear surgery, particularly the endoscopic transcanal approach.<sup>3</sup> Because of the advancement of the EES and its extensions, its anatomy and variations represent an increasing clinical and surgical significance.<sup>4,6</sup> Therefore, the study of EAC determines that using CT should be considered prior to ear surgery. However, the accurate reference data its anatomy is still not fully detailed in the current literature.

Using a binocular microscopy and four sizes of aural speculum, from 4 to 7 mm, is considered the simplest method to measure the width.<sup>5</sup> However, this method reflects roughly the diameter of its cartilaginous part and the entry of the bony EAC. In our study, we provided more accurate measurements of these diameters, as well as of its remaining parts.

On a cadaver study, Ahmad et al.<sup>8</sup> found that the mean dimension of the EAC isthmus was 5.7 and 8.2 mm for the horizontal and vertical diameters, respectively. The mean

**Table 3** Differences in measurements (mm) of EAC dimensions in females (114 ears in 57 patients) and males (86 ears in 43 patients)

		Gender	Mean $\pm$ SD	p-value	t test
Age		Males	$37 \pm 14.8$	0.8744 NS	0.1582
		Females	$36.7 \pm 12$		
Entry	Vertical	Males	$7.9 \pm 1.1$	0.0382 S	2.0869
		Females	$7.6 \pm 0.93$		
	Horizontal	Males	$6.28 \pm 0.87$	0.0125 S	
		Females	$6 \pm 0.7$		
Bony cartilaginous junction	Vertical	Males	$8 \pm 1$	0.1535 NS	1.4327
		females	$7.8 \pm 0.96$		
	Horizontal	Males	$6.2 \pm 0.88$	1.00 NS	
		Females	$6.2 \pm 0.9$		
Isthmus	Vertical	Males	$6.97 \pm 0.9$	0.0071 S	2.72
		Females	$6.6 \pm 0.99$		
	Horizontal	Males	$5.12 \pm 0.75$	0.2299 NS	
		Females	$5.25 \pm 0.76$		
Medial end of EAC	Vertical	Males	$7.3 \pm 0.85$	0.0022 S	3.1033
		Females	$6.9 \pm 0.94$		
	Horizontal	Males	$5.4 \pm 0.87$	1.00 NS	
		Females	$5.4 \pm 0.84$		

**Abbreviations:** EAC, external auditory canal; SD, standard deviation.

measurements of the dimension of the EAC isthmus in our study were 5.26 and 6.8 mm for the horizontal and vertical diameters, respectively. The difference may be caused by changes in the cadavers.

Using CT scan in measurement of the diameter of the EAC is rarely covered by the literature. Yu et al.<sup>9</sup> designed a three-dimensional ear canal model using CT scan. However, in their study, they focused on the length of the EAC, aiming to study the best design of protective ear plugs for both male and female workers in noisy environments. However, our study aims to measure the width of the EAC in four areas of surgical importance.

Li et al.<sup>5</sup> used CT scan in measurement of EAC diameter in children with congenital aural atresia; they measured the diameter in the narrowest segment of the EAC. Ito et al.<sup>10</sup> measured the diameters along the osseous EAC and compared the data collected between the pediatric and adult patient groups; they measured the maximum and minimum Feret diameter along the whole length of the EAC, with the help of software for image processing. In our study, we measured the diameter of EAC in a healthy adult population in four points of surgical importance without the need of image processing.

Mahboubi et al.<sup>11</sup> have invented six different standardized anatomic dimensions for measurements of the width of osseous EAC. However, in our study, we used only two dimensions, vertical and horizontal, which is more practical to be measured in accuracy.

Çalışkan et al.<sup>12</sup> measured the horizontal and vertical diameter of EAC in three points: the entry, isthmus, and medial end. We included these measurements and extended ours to include the cartilaginous part of the EAC, which has a clinical significance during ear examination. Additionally, it's worth mentioning that our study focuses on normal anatomical variations in the Arab population.

It was clear from the current study results that the EAC, in cross section, is oval in shape, not rounded. Therefore, preparation of an oval ear cone could be more beneficial on different ear maneuvers. It was also clear that the isthmus is the narrowest area of the EAC on its vertical or horizontal diameters and, so, should be evaluated preoperatively for transcanal approach and endoscopic surgery of the middle ear.

In the current study, there were no reported significant differences between right and left EAC in all the CT dimensions, so a difference between both sides might indicate a pathology in the EAC or encroaching it. While in many dimensions, such as the vertical and horizontal dimensions of the EAC entry, vertical dimension of the isthmus, and vertical dimension of the medial end of the EAC; in males were significantly longer than in females, which may indicate the need for different approaches or diameters of the ear endoscopes in females.

It was also noted that the different EAC dimensions showed wide variations reaching more than 2-folds between the shortest and longest dimensions. Therefore, we presented a new classification (grades) of the narrowest EAC diameter that could help the choice between microscopic and endoscopic approaches, as well as help in predicting the need for bone

removal during ear surgery. We think that grade 1 classification will be feasible for endoscopic approaches, while grade 3 will be challenging. However, the clinical significance of these grades needs to be further investigated in more detailed studies in different ear surgeries.

Thus, the current study provides basic data for detailed description of the EAC through CT scans, updating the knowledge regarding its dimensions to improve otologists and radiologists' awareness of EAC in the endoscopic field for optimum and safe surgeries. Studying the presented CT measurements might help improve operative planning and ear approaches, and preparation for the instrument set required in each case.

## Conclusion

The current work updates the knowledge of EAC from a CT perspective to improve otologists and radiologists' awareness of EAC and might help the endoscopic ear surgery field for optimum and safe surgeries.

### Ethics Approval and Consent to Participate

A written informed consent was obtained from the study participants, and Zagazig University IRB approved the study proposal (IRB 117-1-18).

### Availability of Data and Materials

The datasets used and/or analyzed during the current study are available from the corresponding author on reasonable request.

### Authors' Contributions

**MWE:** Modified the idea, reviewed the literature, conceptualization and design of the study, revised CT evaluation, did statistical analysis, interpreted the data, tabulated the interpreted data, wrote and revised the article, and contributed to the approved the final manuscript to be published; **YAF:** Suggested and developed the idea, analyzed the data, assisted in writing the manuscript, revised the article, and contributed to the final approval of the article. **AFE:** Reviewed the literature, contributed to the data interpretation, revised the manuscript, and contributed to the final approval of the article. **SS:** Made the CT, measured the CT images, recorded patients' data, revised the methodology, prepared figures, revised manuscript, and contributed to the final approval of the article. **MAM:** Reviewed the literature, assisted in taking the measurements, collected and tabulated the data, contributed to the data interpretation, assisted in preparing figures, and contributed to the final approval of the article. All authors have read and approved the manuscript.

### Funding

The authors declare no financial support or interest to this study.

### Conflict of Interests

The authors have no conflict of interests to declare.

## References

- 1 Kelly KE, Mohs DC. The external auditory canal. *Anatomy and physiology*. *Otolaryngol Clin North Am* 1996;29(05): 725–739
- 2 Gulya J, Schuknecht HE. *Anatomy of the temporal bone with-surgical implications*. 3rd ed Informa Healthcare; 2007:33
- 3 Furukawa T, Watanabe T, Ito T, Kubota T, Kakehata S. Feasibility and advantages of transcanal endoscopic myringoplasty. *Otol Neurotol* 2014;35(04):e140–e145
- 4 Pothier DD. Introducing endoscopic ear surgery into practice. *Otolaryngol Clin North Am* 2013;46(02):245–255
- 5 Li CL, Li J, Guo Y, Zhang TY. Measurement method for external auditory canal and clinical application in congenital aural stenosis. *Int J Pediatr Otorhinolaryngol* 2020;137:110233
- 6 Ayache S, Beltran M, Guevara N. Endoscopic classification of the external auditory canal for transcanal endoscopic ear surgery. *Eur Ann Otorhinolaryngol Head Neck Dis* 2019;136(04): 247–250
- 7 Chee NWC, Tan TY. The value of pre-operative high resolution CT scans in cholesteatoma surgery. *Singapore Med J* 2001;42(04): 155–159
- 8 Ahmad I, Lee WC, Binnington JD. External auditory canal measurements: localization of the isthmus. *Otorhinolaryngol Nova* 2000;10:183–186
- 9 Yu JF, Lee KC, Wang RH, et al. Anthropometry of external auditory canal by non-contactable measurement. *Appl Ergon* 2015;50:50–55
- 10 Ito T, Kubota T, Furukawa T, Kakehata S. Measurement of the pediatric and adult osseous external auditory canal: implications for transcanal endoscopic ear surgery. *Otol Neurotol* 2020;41 (06):e712–e719
- 11 Mahboubi H, Wu EC, Jahanbakhshi R, et al. A novel method to determine standardized anatomic dimensions of the osseous external auditory canal. *Otol Neurotol* 2012;33(05):715–720
- 12 Çalışkan S, Çetin H, Sinem Akkaşoğlu S. Morphometry of the external auditory canal: Radiological study. *J Surg Med* 2020;4 (01):76–79