



Waldenstrom Macroglobulinemia Manifesting as Acute Kidney Injury and Bing-Neel Syndrome With Excellent Response to Ibrutinib

Journal of Investigative Medicine High
Impact Case Reports
Volume 9: 1–6
© 2021 American Federation for
Medical Research
DOI: 10.1177/23247096211021228
journals.sagepub.com/home/hic


Hassan Jafri, MD¹ , Isna Khan, MD¹, Adarsh Sidda, MD¹,
Noman Ahmed Jang Khan, MD¹, Murad Kheetan, MD¹,
Doreen Griswold, MD¹, and Toni Pacioles, MD¹

Abstract

Waldenstrom macroglobulinemia (WM) is a lymphoplasmacytic lymphoma associated with a monoclonal immunoglobulin M protein. Extranodal involvement in WM is not very common. In this article, we present a rare case of WM with kidney and central nervous system involvement. Bing-Neel syndrome is a distinct complication of WM where lymphoplasmacytic cells involve the central nervous system (CNS). Our patient was initially treated with dialysis and steroids with improvement in his kidney function. He was then started on systemic treatment with rituximab, cyclophosphamide, and dexamethasone with stable kidney function but persistent CNS symptoms. Due to rarity of cases, there is no standard treatment for Bing-Neel syndrome. His treatment was switched to ibrutinib with dramatic improvement in his CNS symptoms as well as radiological findings on magnetic resonance imaging.

Keywords

Bing-Neel syndrome, ibrutinib, Waldenstrom macroglobulinemia

Introduction

Waldenstrom macroglobulinemia (WM) is a lymphoproliferative disorder characterized by the proliferation of lymphoplasmacytic elements in the bone marrow and the presence of monoclonal immunoglobulin M (IgM) gammopathy. Extranodal involvement in WM is rare.

Our case involves rare presentation of WM with kidney and central nervous system (CNS) involvement. Remarkably, our patient had a dramatic response to CNS symptoms as well as radiological findings on magnetic resonance imaging (MRI) on ibrutinib monotherapy after initially being treated with rituximab, cyclophosphamide, and dexamethasone.

Case Presentation

A 58-year-old male with a past medical history of prostate cancer presented to our facility with worsening confusion, weakness, and oliguria. Prostate biopsy 5 months prior to admission showed Gleason 4+3 T2aN0M0 prostate adenocarcinoma, for which he was treated with combined brachytherapy and external beam radiation. He developed left lower extremity and weakness after treatment. MRI of lumbar

spine showed degenerative changes but no attributable etiology for his weakness was evident. Around the same time, he also started developing short-term memory loss.

On presentation to our facility, complete blood count was unremarkable, and creatinine was 5.97 mg/dL. Baseline creatinine was 0.85 mg/dL 6 months prior to admission. Urinalysis revealed specific gravity 1.017, large occult blood, white blood cells (WBC) 15 to 25 cells, trace ketones, and no evidence of infection. Due to oliguric acute kidney injury with altered mental status suggestive of uremia, dialysis was initiated. Workup for the confusion including noncontrast MRI brain showed extensive white matter changes. Cerebrospinal fluid (CSF) analysis showed glucose 29 mg/dL, protein 120 mg/dL, WBC 68 cells/mm³ with 77% lymphocytes, and red blood cells 119 cells/mm³.

¹Marshall University, Huntington, WV, USA

Received March 8, 2021. Revised April 30, 2021. Accepted May 10, 2021.

Corresponding Author:

Hassan Jafri, MD, Marshall University Joan C. Edwards School of Medicine, 1400 Hal Greer Blvd, Huntington, WV 25701-3655, USA.
Email: hassanajfrimd@gmail.com



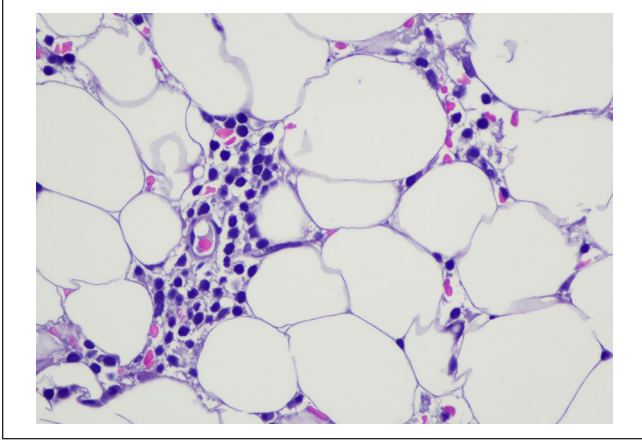


Figure 1. Hematoxylin-eosin–stained slide of the subcortical hypocellular bone marrow showing small non-paratrabeular aggregates and scattered interstitial cells (50× oil).

Computed tomography (CT) scan of chest, abdomen, and pelvis showed pleural effusion and mildly enlarged subcarinal lymph node. Infectious workup was also negative. Urine microalbumin to creatinine ratio was 851 (0-28) and urine protein to creatinine ratio was 1.81 (normal less than 0.20). Serum protein electrophoresis (SPEP) was positive for M spike. Immunofixation electrophoresis showed IgM kappa monoclonal protein and second IgM monoclonal protein with probable kappa light chain. IgM kappa monoclonal protein #1 concentration was 0.2 g/dL and IgM monoclonal protein #2 concentration was less than 0.1 g/dL. Urine protein electrophoresis showed M spike and urine immunofixation electrophoresis showed Bence Jones protein, kappa type. Free kappa light chain was 924 mg/dL (3.3-19.4 mg/dL), free lambda light chain was 24 mg/dL (5.7-26.3 mg/dL), with a kappa/lambda ratio of 38.2 (0.26-1.65). A kidney biopsy was ultimately performed, which showed extensive glomerular and arteriolar IgM kappa hyaline thrombi and glomerular features of thrombotic microangiopathy. A few kappa light chain restricted casts were seen suspicious for light chain nephropathy. Findings were deemed secondary to IgM kappa monoclonal protein. A subsequent bone marrow biopsy was consistent with lymphoplasmacytic lymphoma. Lymphoid aggregates were composed of CD20 positive B cells with admixed CD138 positive plasma cells with kappa predominance (Figures 1-6). Karyotype showed normal cytogenetics and molecular studies detected a MYD88 L265P mutation. CXCR4 mutation was not detected. HIV and hepatitis B tests were negative. He was treated with methylprednisolone 500 mg for 3 days followed by a prednisone taper. He also underwent 2 sessions of plasmapheresis as viscosity was not available at that time and patients had concerning symptoms of hyperviscosity. Later on, his serum viscosity turned out to be normal (1.5 centipoises). Dialysis was discontinued prior to discharge from hospital as his kidney function recovered

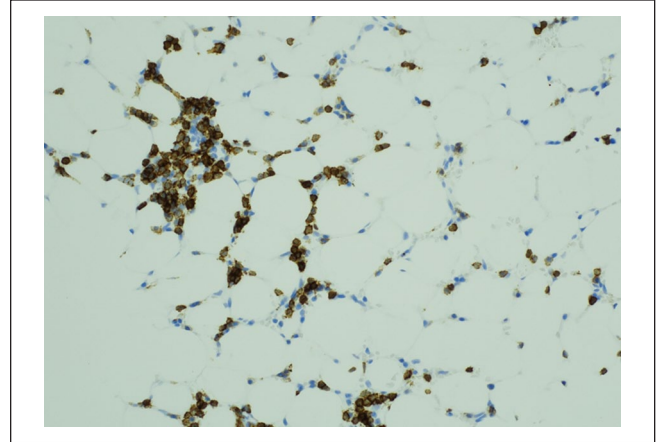


Figure 2. Immunohistochemistry for CD20 shows that the majority of the cells within the aggregate and many within the interstitium are B cells (20×).

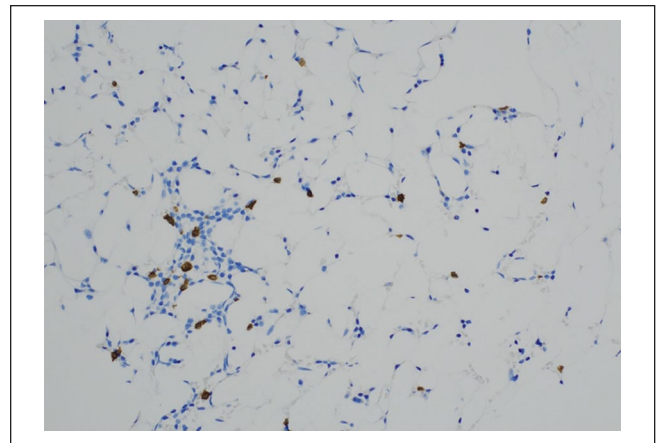


Figure 3. Conversely, CD3 immunohistochemistry shows only occasional scattered T cells (20×).

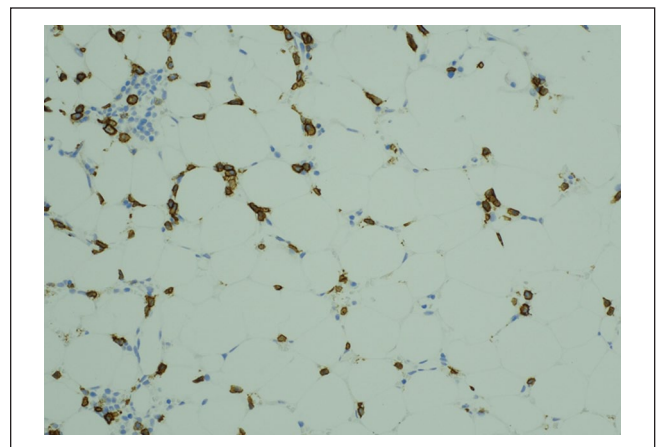


Figure 4. CD138 demonstrates increased numbers of plasma cells within the interstitium and the aggregate.

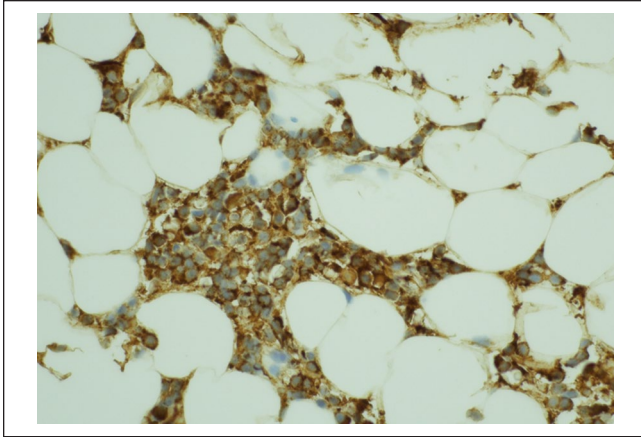


Figure 5. The plasmacytoid lymphocytes and plasma cells are kappa restricted.

with good urine output (creatinine 2.81 mg/dL). Subsequently, a month later, his creatinine in the follow-up hematology clinic visit was 1.35 mg/dL. He had a follow-up with nephrology and no more dialysis was needed. He was then initiated on treatment with rituximab, cyclophosphamide, and dexamethasone (RCD). IgM level at the time of treatment initiation was 1402 mg/dL. It increased to 1650 mg/dL after 1 month and 1877 mg/dL after 2 months. He was readmitted 3 months after initiation of chemotherapy with a 30-minute episode of right-sided facial weakness, slurred speech, and right upper extremity weakness. CT head showed severe white matter changes with scattered areas of enhancement with surrounding vasogenic edema. CT angiography was unremarkable. CSF studies showed opening pressure of 17, glucose 70 mg/dL, protein 72 mg/dL, WBC 4 cells/mm³, and red blood cells 4 cells/mm³. No definitive etiology was again attributable to these findings. A month later, he was readmitted with seizures. His hospital course was complicated by atrial fibrillation with rapid ventricular rate and aspiration pneumonia. He was started on eliquis. MRI brain showed persistent extensive periventricular leukomalacia. He was placed on dexamethasone. He continued to have issues with memory loss and weakness. He benefited with RCD treatment with continued stabilization of his renal function but his M protein was overall unchanged. After 5 cycles of RCD, his IgM was 1108 mg/dL. His SPEP showed an IgM monoclonal spike of 0.8 with kappa light chain specificity. Another lumbar puncture was pursued after holding his steroids for 2 weeks and the CSF analysis indicated elevated protein, decreased glucose, and elevated WBC with lymphocytic predominance. His lumbar puncture was abnormal but not definitive for diagnosis of CNS involvement by lymphoma. Brain biopsy was discussed but patient deferred the procedure. A repeat MRI was done that showed progression of white matter enhancement (Figure 7). Due to the persistent imaging findings, suspicion of CNS involvement by lymphoma was high. As he had been treated with multiple courses of steroids, the diagnostic yield of CSF for definitive

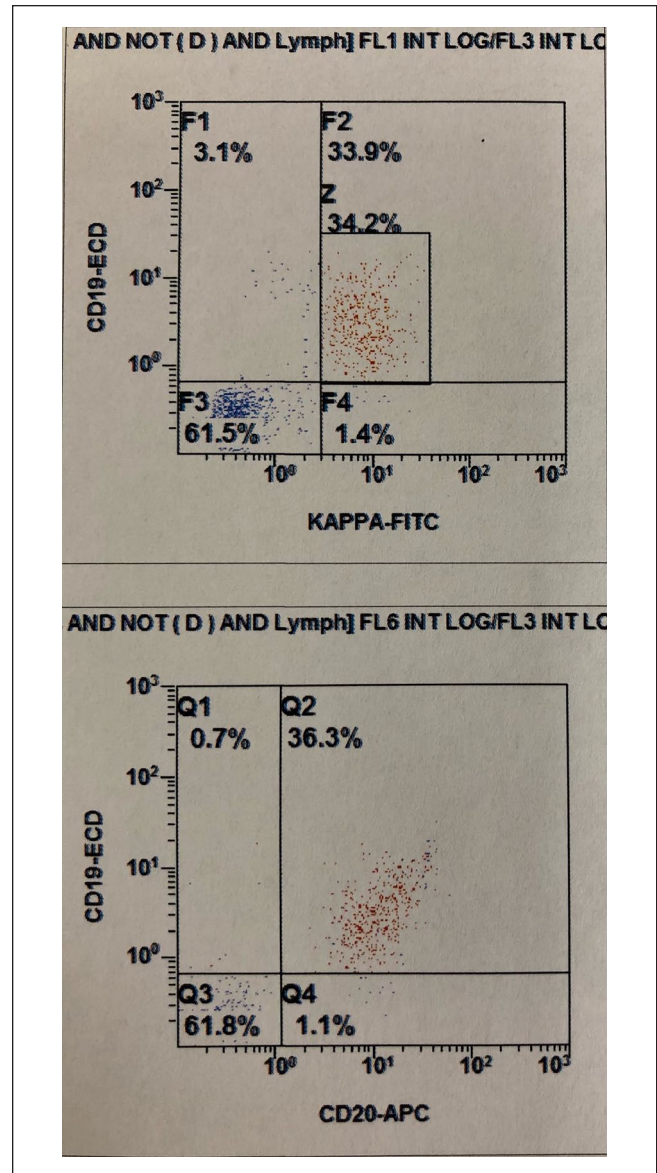


Figure 6. The histograms represent the gated lymphocytes. Of the gated lymphocytes, approximately 34% (red dots) are B cells that coexpress CD19 and CD20 and exhibit surface kappa light chain restriction.

diagnosis was likely low. He was started on ibrutinib 420 mg daily. Eliquis was held in consultation with cardiology. After initiation of therapy, the patient noted dramatic improvement in memory and weakness. Repeat MRI brain after 2 months of ibrutinib showed complete resolution of intracranial enhancement (Figure 8). His IgM protein as well as his M spike have largely remained stable since. The patient is currently tolerating ibrutinib well with no complications.

Discussion

We present this interesting case of WM with kidney and central nervous system involvement.

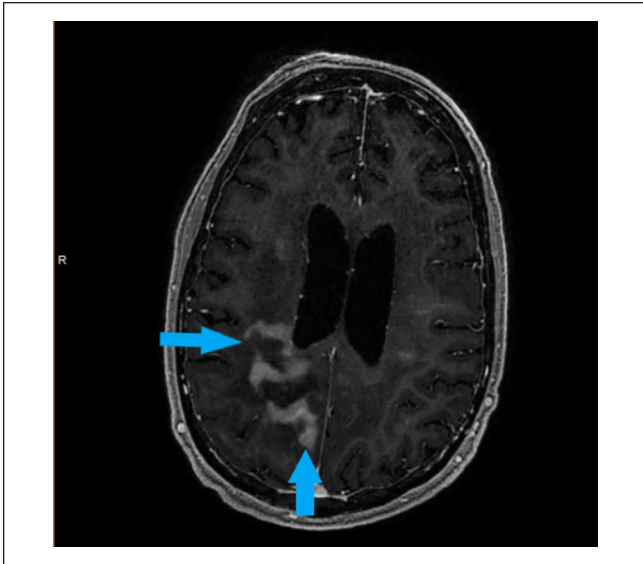


Figure 7. Magnetic resonance imaging of the brain showing intracranial white matter enhancements consistent with disease progression (blue arrows).

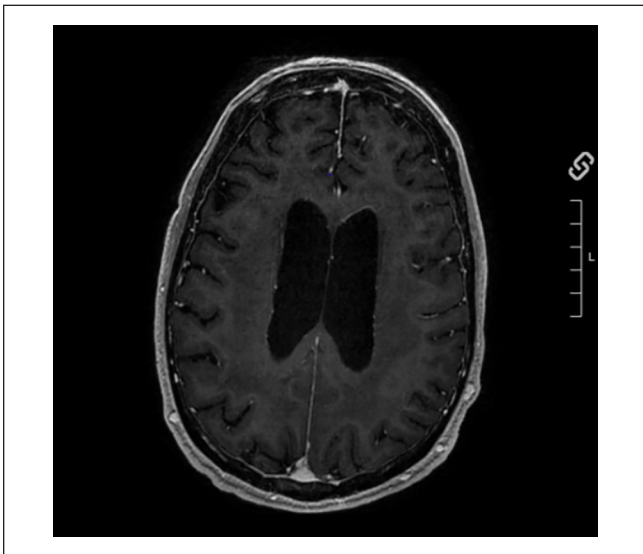


Figure 8. Magnetic resonance imaging of the brain 2 months after treatment with ibrutinib showing complete resolution of previously noticed white matter enhancements.

According to the World Health Organization, WM is lymphoplasmacytic lymphoma related to monoclonal IgM protein. Incidence rate for males (0.92 per 100 000) and females (0.30 per 100 000) person years has remained stable over the past 50 years.¹

Diagnostic criteria for WM include bone marrow involvement by lymphoplasmacytoma and monoclonal IgM gammopathy in blood. Mayo Clinic consensus stressed 10% lymphoplasmacytic plasma cell involvement to differentiate WM from IgM monoclonal gammopathy of undetermined

significance. Second International workshop does not have specific percentage of bone marrow involvement for diagnosis.²

Symptoms of WM are because of lymphoplasmacytic cells which infiltrate different organs. Paraproteins are also responsible for clinical features associated with WM. In addition, WM can have symptoms that are similar to other non-Hodgkin's lymphoma. It can lead to enlargement of liver, spleen, and lymph nodes, and less commonly involves extranodal tissues.² In contrast to multiple myeloma, kidney involvement in WM is not quite common. Vos et al did a study in patients with WM where 44 out of 1391 patients had kidney involvement by lymphoma. At 15 years, the incidence was 5.1%. Only 2 patients had thrombotic microangiopathy making it a rare manifestation.³ This makes our patient unique in his presentation, as he had evidence of thrombotic microangiopathy on kidney biopsy.

Bing-Neel syndrome (BNS) is a distinct complication of WM where lymphoplasmacytic cells involve CNS. In 1936, Jens Bing and Axel Valdemar first explained this entity. They described 2 patients who had CNS symptoms with elevated globulins and had no evidence of myeloma.⁴ Studies about BNS have shown low prevalence of the disease. According to analysis by Kulkarni et al, 13 (0.8%) out of total 1523 WM patients had BNS.⁵

Whenever patients with WM present with altered mental status, a prompt neurological evaluation with an MRI of the brain and CSF studies are warranted. Simon et al studied 44 patients with BNS where 80% patients had CNS abnormalities on imaging. There was no single consistent pattern associated with BNS on the imaging studies. There can be brain or medullary parenchymal as well as leptomeningeal enhancement.⁶

The gold standard to diagnose BNS include sampling of brain parenchyma and meninges that should reveal lymphoplasmacytic lymphoma. On immunohistochemistry like WM, B cells have pan B-cell antigens (CD19, CD20, CD79a, and CD79b). They also express CD27 and CD52 mostly which are memory B-cell markers. Some monotypic plasma cells may be seen that express CD38 and IgM. CSF should be analyzed which has clonal B cells with similar features as the bone marrow.⁷ CSF analysis typically shows increased intracranial pressure, increased protein (>100 mg/dL), decreased or normal glucose, and elevated white blood cells (between 100 and 500 cell/mm³). Flow cytometry is compulsory to demonstrate clonality in B cells. Positive CSF study supports the diagnosis; however, negative results cannot rule out BNS due to low sensitivity of the test.^{4,8,9} This was evident in our patient, where we did not have histological confirmation with a biopsy or CSF flow cytometry, but we did have a confirmatory diagnosis by bone marrow as well as a rapid response to treatment. Due to above-mentioned reasons, we strongly feel our patient had BNS.

Management of WM with no symptomatology is usually with observation. Indications for treatment include

WM-related constitutional symptoms like B symptoms from any other non-Hodgkin's lymphoma, symptomatic anemia, lymphadenopathy, or hepatosplenomegaly, as well as coexisting AL amyloidosis with organ dysfunction.¹⁰ Acute kidney injury is also an indication to start treatment. In a study by Higgins et al in patients with kidney involvement by WM, treatment was not uniform as multiple agents were used in different lines of treatment. Some patients were treated with anti-CD20 antibodies and alkylating agents while others with novel agents like bortezomib. Rituximab was used as the first-line treatment in 60% of patients in the study. Autologous stem cell transplant was also done in few patients, all with amyloid-related glomerulopathy. Some patients had also required plasmapheresis.¹¹ Our patient was treated with plasmapheresis initially and renal replacement therapy with hemodialysis was needed with steroids resulting in improvement of kidney function. Subsequently, his kidney function remained stable on systemic treatment with rituximab, cyclophosphamide, and dexamethasone.

Due to the rarity of BNS, no standard guideline for treatment is currently well established. Treatment of BNS involves initiation of treatment at the time of symptoms with goal of therapy being to improve the symptoms. High-dose methotrexate and cytarabine have been used for BNS due to their activity in CNS lymphoma but because of toxicity they are not recommended in the front-line setting. Other recommended agents include bendamustine, fludarabine, and cladribine. These are significantly less toxic than methotrexate but still have side effects including myelosuppression, immunosuppression, refractory cytopenias, and secondary myeloid neoplasms. Rituximab monotherapy is not recommended in BNS because of limited CNS penetration but can be used in conjunction with other therapies for systemic control of disease.¹²

In 2015, ibrutinib was first approved for symptomatic WM by study done by Treon et al where ibrutinib was given to patients with WM in second-line setting. Patients with BNS were not included. The overall response rate was 90.5%, and the major response rate was 73.0%. Analysis showed progression-free survival and overall survival benefit at 2 years (progression-free survival = 69.1%, overall survival = 95.2).¹³ Another study published by Treon et al showed WM treated with ibrutinib showed durable responses in the first-line setting. In both studies, responses to ibrutinib were better in patients with MYD88 mutation and wild type CXCR as was the case in our patient.

In a study by Castillo et al, 28 patients with BNS were treated with ibrutinib. Thirty-nine percent patients received ibrutinib in first-line setting. Forty-six percent received 560 mg and 54% received 420 mg dose of ibrutinib. Within 3 months, 85% patients reported improvement in symptoms and 60% had improvement on imaging. At best response, 85% of patients reported minimal to absent BNS symptoms,

83% had improvement or resolution of changes on imaging, and 47% had negative CSF cytology. The 2-year event-free survival rate with ibrutinib was 80%, the 2-year ibrutinib survival rate was 81%, and the 5-year BNS survival rate was 86%.¹⁴ Only 2 patients in the study had resolution of findings in MRI. Event-free survival was similar between 2 doses of ibrutinib.¹⁴ Patients with BNS have been successfully treated with doses of 420 mg daily. Hence it is recommended to start the lower dose as the initial first line of treatment.⁹ Our patient had a good response with 420 mg dose of ibrutinib.

Conclusions

In conclusion, our case will be useful addition to literature of cases with rare extranodal presentation of WM with acute kidney injury and symptoms concerning for BNS. Although rare we suggest BNS should be considered in differential diagnosis of WM patients who have CNS symptoms. As BNS has no specific treatment due to rarity of cases, we suggest ibrutinib should be strongly considered for treatment of WM patients with concern for BNS.

Declaration of Conflicting Interests

The author(s) declared no potential conflicts of interest with respect to the research, authorship, and/or publication of this article.

Funding

The author(s) received no financial support for the research, authorship, and/or publication of this article.

Ethics Approval

Our institution does not require ethical approval for reporting individual cases or case series.

Informed Consent

Verbal Informed consent was obtained from the patient for their anonymized information including facial images to be published in this article.

ORCID iD

Hassaan Jafri  <https://orcid.org/0000-0003-1733-101X>

References

1. Gertz MA. Waldenström macroglobulinemia: 2019 update on diagnosis, risk stratification, and management. *Am J Hematol*. 2019;94:266-276.
2. Mazzucchelli M, Frustaci AM, Deodato M, Cairoli R, Tedeschi A. Waldenström's macroglobulinemia: an update. *Mediterr J Hematol Infect Dis*. 2018;10:e2018004.
3. Vos JM, Gustine J, Rennke HG, et al. Renal disease related to Waldenström macroglobulinaemia: incidence, pathology and clinical outcomes. *Br J Haematol*. 2016;175:623-630.

4. Varettoni M, Defrancesco I, Diamanti L, et al. Bing-Neel syndrome: illustrative cases and comprehensive review of the literature. *Mediterr J Hematol Infect Dis*. 2017;9:e2017061.
5. Kulkarni T, Treon SP, Manning RA, et al. Clinical characteristics and treatment outcome of CNS involvement (Bing-Neel syndrome) in Waldenstroms macroglobulinemia. *Blood*. 2013;22:5090.
6. Simon L, Aikaterini F, Lemal R, et al. Bing-Neel syndrome, a rare complication of Waldenstrom macroglobulinemia: analysis of 44 cases and review of the literature. A study on behalf of the French Innovative Leukemia Organization (FILO). *Haematologica*. 2015;100:1587-1594.
7. Minnema MC, Kimby E, D'Sa S, et al. Guideline for the diagnosis, treatment, and response criteria for Bing-Neel syndrome. *Haematologica*. 2017;102:43-51.
8. Malkani RG, Tallman M, Gottardi-Littell N, et al. Bing-Neel syndrome: an illustrative case and a comprehensive review of the published literature. *J Neurooncol*. 2010;96:301-312.
9. Plander M, Szendrei T, Vadvári Á, Iványi J. Standard dose of ibrutinib is effective in the treatment of Bing-Neel syndrome. *Pathol Oncol Res*. 2020;26:591-592.
10. Kapoor P, Ansell S, Fonesca R, et al. Diagnosis and management of Waldenström macroglobulinemia Mayo Stratification of Macroglobulinemia and Risk-Adapted Therapy (mSMART) guidelines. *JAMA Oncol*. 2017;3:1257-1265.
11. Higgins L, Nasr SH, Said SM, et al. Kidney involvement of patients with Waldenström macroglobulinemia and other IgM-producing B cell lymphoproliferative disorders. *Clin J Am Soc Nephrol*. 2018;13:1037-1046.
12. Castillo JJ, Treon SP. How we manage Bing-Neel syndrome. *Br J Haematol*. 2019;187:277-285.
13. Treon SP, Tripsas CK, Meid K, et al. Ibrutinib in previously treated Waldenström's macroglobulinemia. *N Engl J Med*. 2015;372:1430-1440.
14. Castillo JJ, Itchaki G, Paludo J, et al. Ibrutinib for the treatment of Bing-Neel syndrome: a multicenter study. *Blood*. 2019; 133:299-305.