



Contents lists available at ScienceDirect

International Journal of Surgery Case Reports

journal homepage: www.casereports.com

Curative resection for locally advanced sigmoid colon cancer using neoadjuvant chemotherapy with FOLFOX plus panitumumab: A case report



Kenji Tomizawa^{a,*}, Yuji Miura^b, Yudai Fukui^a, Yutaka Hanaoka^a, Shigeo Toda^a, Jin Moriyama^a, Naoko Inoshita^c, Yukinori Ozaki^b, Toshimi Takano^b, Shuichiro Matoba^a, Hiroya Kuroyanagi^a

^a Department of Gastroenterological Surgery, Toranomon Hospital, Tokyo, Japan

^b Department of Medical Oncology, Toranomon Hospital, Tokyo, Japan

^c Department of Pathology, Toranomon Hospital, Tokyo, Japan

ARTICLE INFO

Article history:

Received 6 December 2016

Received in revised form 12 January 2017

Accepted 14 January 2017

Available online 17 January 2017

Keywords:

Neoadjuvant chemotherapy

Sigmoid colon cancer

Panitumumab

Case report

ABSTRACT

INTRODUCTION: FOLFOX and panitumumab combined chemotherapy plays an important role for metastatic colorectal cancer. However the usefulness of this regimen for neoadjuvant therapy is unclear. **CASE REPORT:** A 67-year-old man with abdominal pain and pneumaturia was diagnosed with RAS wild-type sigmoid colon cancer with urinary bladder invasion and colovesical fistulas. Because the cancer was considered to be unresectable, a transverse-loop colostomy was performed. Colonoscopy and computed tomography revealed a marked reduction in the size of the primary tumor after six courses of FOLFOX4 (oxaliplatin, leucovorin, and 5-fluorouracil) plus panitumumab. Laparoscopic sigmoidectomy and partial cystectomy were then performed. The pathological findings based on the resected specimen showed almost complete replacement of the tumor by fibrous tissue, with only a few degenerated tumor glands persisting in the submucosa. The patient's postoperative course was uneventful and he was doing well, without disease recurrence, after 36 months of follow up.

CONCLUSION: To our knowledge, this is the first report of a successful curative resection in a patient with initially unresectable, locally advanced colorectal cancer who was treated with FOLFOX4 combined with panitumumab.

© 2017 The Author(s). Published by Elsevier Ltd on behalf of IJS Publishing Group Ltd. This is an open access article under the CC BY-NC-ND license (<http://creativecommons.org/licenses/by-nc-nd/4.0/>).

1. Introduction

Colorectal cancer (CRC) is one of the most commonly diagnosed malignancies in Japan, affecting over 100,000 individuals. It is also the third most common cancer worldwide, with up to 1 million new cases diagnosed each year [1].

Metastatic or postoperative adjuvant chemotherapy for patients with CRC is now internationally accepted as a standard therapy to improve outcome. Moreover, recent studies have demonstrated that preoperative chemotherapy improves the outcome of patients with CRC with liver metastases [2,3]. Nowadays there are some ongoing clinical trials that evaluate the efficacy of neoadjuvant approach in locally advanced colon cancer. [4–6] However, little is

known about the effect and safety of preoperative chemotherapy for initially unresectable, locally advanced colon cancer without distant metastases.

Panitumumab (Pmab) is an epidermal growth factor receptor (EGFR)-targeted monoclonal antibody that has shown efficacy as monotherapy in phase III studies in patients with chemotherapy-refractory metastatic CRC [7]. It was also shown to improve patient outcome when added to standard chemotherapy, both first-line and subsequently [8].

Here we report the case of a patient with locally advanced sigmoid colon cancer with invasion of the bladder and colovesical fistulas in whom the tumor was radically resected after chemotherapy with FOLFOX4 plus Pmab.

2. Case report

A 67-year-old man was referred to our institute because of abdominal pain and pneumaturia. Colonoscopy showed a circumferential tumor of the sigmoid colon (Fig. 1a). The resulting constriction blocked passage of the endoscope. Initial computed

Abbreviations: CRC, colorectal cancer; Pmab, Panitumumab; EGFR, Epidermal growth factor receptor; CT, Computed tomography; PFS, Progression-free survival; OS, Overall survival.

* Corresponding author at: Department of Surgery, Toranomon Hospital, 2-2-2, Minato-ku, Tokyo, Japan.

E-mail address: kt122912292006@yahoo.co.jp (K. Tomizawa).

<http://dx.doi.org/10.1016/j.ijscr.2017.01.027>

2210-2612/© 2017 The Author(s). Published by Elsevier Ltd on behalf of IJS Publishing Group Ltd. This is an open access article under the CC BY-NC-ND license (<http://creativecommons.org/licenses/by-nc-nd/4.0/>).

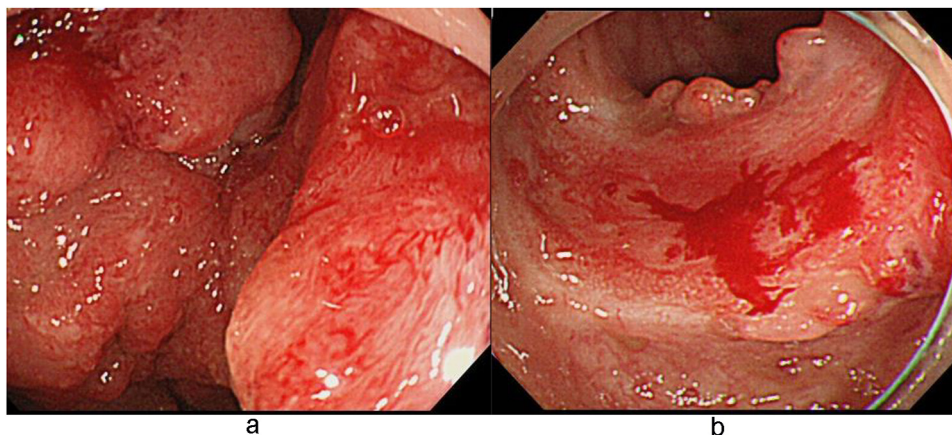


Fig. 1. (a) Colonoscopy before chemotherapy showed a circumferential tumor in the sigmoid colon, and biopsy specimens revealed moderately differentiated tubular adenocarcinoma. (b) Colonoscopy after chemotherapy showed an excellent response and the biopsies were negative for cancer cells.

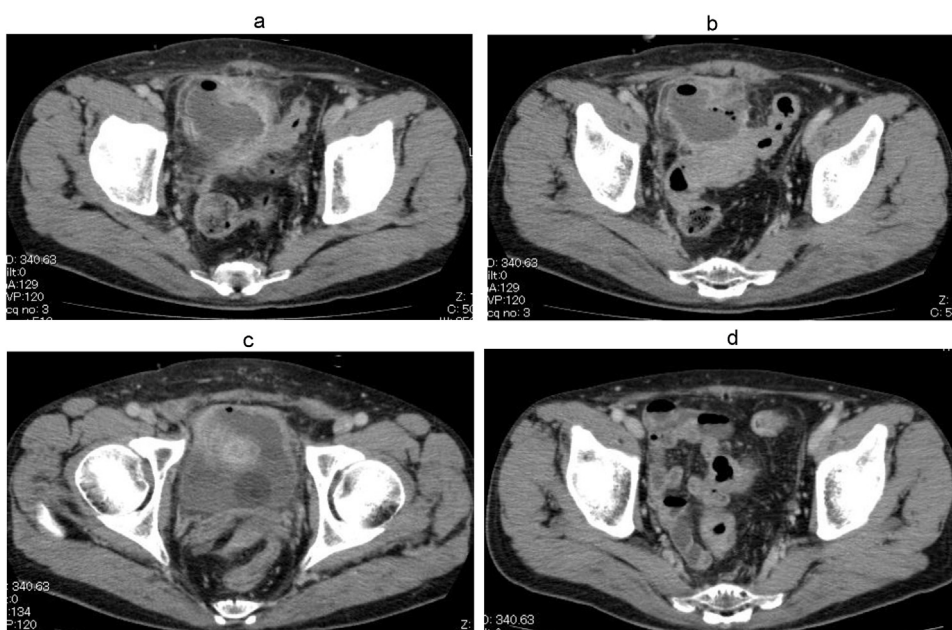


Fig. 2. (a–c)Initial computed tomography showed a circumferential thickening of the sigmoid colon wall and involving urinary bladder with a pelvic abscess and urinary air (colovesical fistula). (d) After six courses of chemotherapy showed improvement of pelvic abscess and marked reduction of the tumor.

tomography (CT) and magnetic resonance imaging showed a 4 cm × 4 cm tumor involving the urinary bladder, with a huge pelvic abscess, colovesical fistulas, and many swollen lymph nodes in the mesocolon but no distant metastasis (Fig. 2a–c).

Positron emission tomography-CT confirmed the primary tumor in the sigmoid colon and the absence of distant metastasis (Fig. 3). Microscopic examination of the tumor biopsy specimens revealed moderately differentiated tubular adenocarcinoma; the RAS status was wild-type. The patient was considered to have high-risk disease and curative resection was deemed not possible; instead, our multidisciplinary team recommended neoadjuvant chemotherapy. After undergoing a transverse-loop colostomy and improved inflammatory response caused by pelvic abscess, the patient received six courses of FOLFOX4 [oxaliplatin (85 mg/m² on day 1), leucovorin (100 mg/m² on days 1 and 2), and 5-fluorouracil (5-FU; 400 mg/m² as a bolus and 600 mg/m² as a 22-h continuous infusion on days 1 and 2)] plus Pmab (6 mg/kg) every 2 weeks. Grade 3 neutropenia, according to Common Terminology Criteria for Adverse Events (CTCAE) version 4.0, developed during the last course of chemotherapy, but not febrile neutropenia

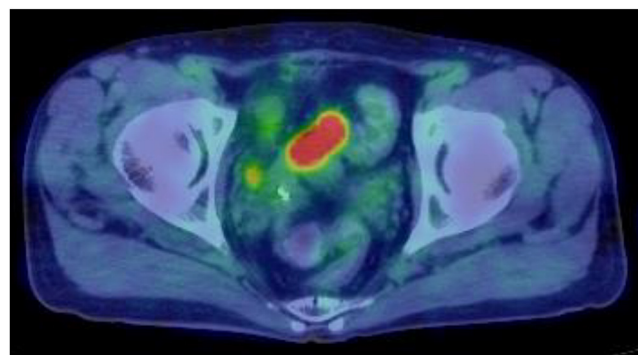


Fig. 3. PET-CT showed the primary tumor in the sigmoid colon.

or related infection. Colonoscopy and abdominal CT after systemic chemotherapy demonstrated marked tumor shrinkage, an improved pelvic abscess, and no mesocolon lymph node metastases (Figs. 1d and 2d). Biopsies of the sigmoid colon were negative for

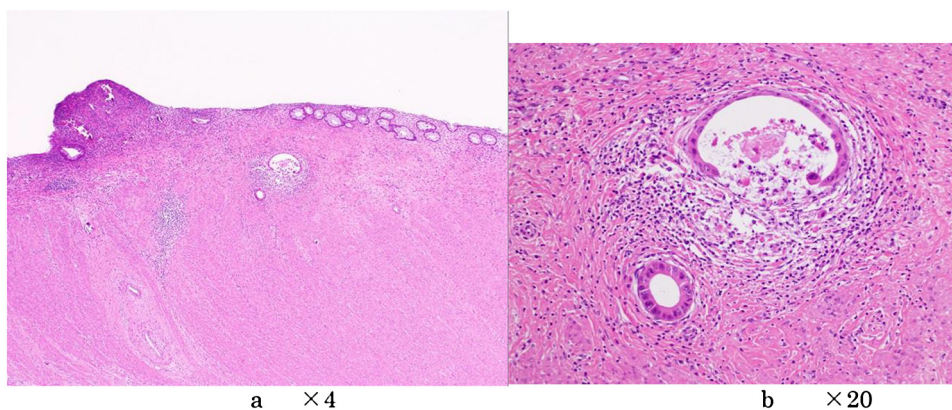


Fig 4. Microscopic findings with H&E showed the tumor had been almost replaced fibrous tissue, with only two glands cancer cells left in the submucosa.

cancer cells. The patient underwent laparoscopic sigmoidectomy and partial cystectomy 3 weeks after the completion of systemic chemotherapy. He recovered uneventfully and was discharged on postoperative day 11.

On microscopic examination, the specimen resected following therapy was replaced almost completely with fibrous tissue, with only a few degenerated tumor glands remaining in the submucosal layer, and no lymph node metastases (Fig. 4a–b). All margins were free of cancer cells. The patient continues to do well 36 months postoperatively, without any evidence of recurrence.

3. Discussion

Complete microscopic tumor removal (R0 resection) for CRC has a strong prognostic impact on both recurrence and survival rates [9]. Current guidelines recommend microscopically negative margins as the standard surgical procedure for locally advanced, adherent colon cancer [10]. Incomplete removal of the tumor despite en-bloc multivisceral resections has been reported in 7–35% of patients with locally advanced colon cancer [11–14]. Cukier et al. reported that neoadjuvant chemoradiotherapy and en-bloc multivisceral resection can result in high rates of R0 resection and excellent local control, with acceptable morbidity, in selected patients with locally advanced, adherent colon cancer [15]. In our patient, considering the difficulty of curative resection due to huge pelvic abscess, with colovesical fistulas, we first performed a transverse colostomy and reduced the risk of infection, followed by systemic neoadjuvant chemotherapy.

Pmab, a fully human monoclonal antibody targeting the EGFR, has been recently combined with 5-FU-based chemotherapy to achieve significant and clinically meaningful improvement in survival in patients with metastatic colon cancer [16]. Leone et al. reported that conversion treatment with Pmab plus XELOX (capecitabine plus oxaliplatin) yielded a strong response and high resectability rates in patients with KRAS wild-type metastatic colon cancer with extensive liver involvement [17]. In the phase II, randomized PEAK [panitumumab plus modified fluorouracil, leucovorin, and oxaliplatin (mFOLFOX6) or bevacizumab plus mFOLFOX6 in patients with previously untreated, unresectable, wild-type KRAS exon 2 metastatic colorectal cancer] study [16], the progression-free survival (PFS) of patients with wild-type KRAS exon 2 tumors was similar and their overall survival (OS) was improved with Pmab vs. bevacizumab when combined with mFOLFOX6. Therefore, patients with wild-type RAS tumors in particular seem to clinically benefit from Pmab-containing therapy.

In the PRIME study, 42% of the patients receiving Pmab-FOLFOX4 developed grade 3–4 neutropenia, 39% developed grade 3–4 skin toxicity, and 18% grade 3–4 diarrhea. In the StarPan/STAR-02 study,

21% of the patients with high-risk, locally advanced rectal cancer treated with a neoadjuvant regimen of 5-FU and oxaliplatin-RT plus Pmab achieved pathologic complete remission based on complete tumor regression [18]. In that group, 39% of the patients experienced grade 3–4 diarrhea, with one death due to toxicity, and 19% suffered grade 3–4 skin toxicity. In our patient, pre-emptive supportive treatment, including oral doxycycline and no radiotherapy, might have avoided the development of skin toxicity and diarrhea associated with Pmab administration.

Neoadjuvant chemotherapy is a well-established therapeutic strategy in gastroenterological oncology and more effective than similar postoperative therapy [19–21]. Although the role of neoadjuvant chemoradiotherapy in the management of locally advanced rectal cancer is well documented [14,21], there is no clear evidence supporting the use of adjuvant [22,23] and neoadjuvant FOLFOX4 plus monoclonal antibodies in patients with localized colon cancer without distant metastasis. Foxtrot trial evaluates preoperative 6 weeks of modified de Gramont chemotherapy plus Pmab compared with modified de Gramont chemotherapy alone in patients with radiologically staged, locally advanced, but potentially resectable colon cancer [4]. This trial reported that preoperative chemotherapy is feasible with acceptable toxicity and preoperative morbidity and postoperative results is ongoing. The present case suggests that preoperative FOLFOX4 and Pmab is an effective option for patients with RAS wild-type, locally advanced colon cancer.

4. Conclusion

In conclusion, we report a first case of curative resection in a patient with initially unresectable, locally advanced colon cancer after a combination regimen of FOLFOX4 plus Pmab. Neoadjuvant chemotherapy using FOLFOX4 plus Pmab might be a promising preoperative strategy for patients with RAS wild-type, locally advanced colon cancer. Clinician should consider that a multidisciplinary approach is important because locally advanced cases can be brought into conversion surgery by using Pmab containing regimen, and long-term relapse-free survival may be obtained. However, preoperative chemotherapy for colon cancer has yet to be rigorously investigated, such that the associations between systemic preoperative chemotherapy and locally advanced colon cancer remain to be clarified. This case report was accordance with the SCARE guideline [24].

Authors' contributions

KT wrote the final manuscript and analyzed the results. YF, YH, JM, SM and HK participated in the care of the patients. NY carried out the pathological analysis of the specimen. All authors partic-

ipated in data collection. YM, YO, and TT participated in revising the manuscript critically. All authors read and approved the final manuscript.

KT, HK, SM performed the surgery. KT, YH, ST, and JM took charge of postoperative care and prepared the manuscript. YM, YF, YO, NI, and TT assisted in drafting the manuscript and reviewed the article. All authors read and approved the final manuscript

Consent

Written informed consent was obtained from the patient for publication of this case report and accompanying images.

Funding

Kenji Tomizawa and the other co-authors have no relevant financial interests to declare in this manuscript.

Ethical approval

All approval has been given.

Competing interests

The authors declare that they have no competing interest.

Guarantor

Kenji Tomizawa, Yuji Miura.

Acknowledgements

This case report is not supported by any grants.

References

- [1] D.M. Parkin, F. Bray, J. Ferlay, P. Pisani, Global cancer statistics, 2002, *CA Cancer J. Clin.* 55 (2005) 74–108.
- [2] G. Folprecht, T. Gruenberger, W.O. Bechstein, H.R. Raab, F. Lordick, J.T. Hartmann, et al., Tumour response and secondary resectability of colorectal liver metastases following neoadjuvant chemotherapy with cetuximab: the CELIM randomised phase 2 trial, *Lancet Oncol.* 11 (2010) 38–47.
- [3] R. Wong, D. Cunningham, Y. Barbachano, C. Saffery, J. Valle, T. Hickish, et al., A multicentre study of capecitabine, oxaliplatin plus bevacizumab as perioperative treatment of patients with poor-risk colorectal liver-only metastases not selected for upfront resection, *Ann. Oncol.* 22 (2011) 2042–2048.
- [4] Foxtrot Collaborative Group, Feasibility of preoperative chemotherapy for locally advanced, operable colon cancer: the pilot phase of a randomised controlled trial, *Lancet Oncol.* 13 (2012) 1152–1160.
- [5] J. Arredondo, C. Pastor, J. Baixauli, J. Rodríguez, I. González, C. Vigil, et al., Preliminary outcome of a treatment strategy based on perioperative chemotherapy and surgery in patients with locally advanced colon cancer, *Colorectal Dis.* 15 (2013) 552–557.
- [6] A. Jakobsen, F. Andersen, A. Fischer, L.H. Jensen, J.C. Jørgensen, O. Larsen, et al., Neoadjuvant chemotherapy in locally advanced colon cancer. A phase II trial, *Acta Oncol.* 29 (2015) 1–7.
- [7] J.Y. Douillard, S. Siena, J. Cassidy, J. Taberero, R. Burkes, M. Barugel, et al., Randomized, phase III trial of panitumumab with infusional fluorouracil, leucovorin, and oxaliplatin (FOLFOX4) versus FOLFOX4 alone as first-line treatment in patients with previously untreated metastatic colorectal cancer: the PRIME study, *J. Clin. Oncol.* 28 (2010) 4697–4705.
- [8] M. Peeters, T.J. Price, A. Cervantes, A.F. Sobrero, M. Ducreux, Y. Hotko, et al., Randomized phase III study of panitumumab with fluorouracil, leucovorin, and irinotecan (FOLFIRI) compared with FOLFIRI alone as second-line treatment in patients with metastatic colorectal cancer, *J. Clin. Oncol.* 28 (2010) 4706–4713.
- [9] H. Nelson, N. Petrelli, A. Carlin, J. Couture, J. Fleshman, J. Guillem, et al., Guidelines 2000 for colon and rectal cancer surgery, *J. Natl. Cancer Inst.* 93 (2001) 583–596.
- [10] H. Nelson, N. Petrelli, A. Carlin, J. Couture, J. Fleshman, J. Guillem, et al., Guidelines 2000 for colon and rectal cancer surgery, *J. Natl. Cancer Inst.* 93 (2001) 583–596.
- [11] T. Lehnert, M. Methner, A. Pollok, A. Schaible, U. Hinz, C. Herfarth, Multivisceral resection for locally advanced primary colon and rectal cancer: an analysis of prognostic factors in 201 patients, *Ann. Surg.* 235 (2002) 217–225.
- [12] W.E. Taylor, J.H. Donohue, L.L. Gunderson, H. Nelson, D.M. Nagorney, R.M. Devine, et al., The Mayo clinic experience with multimodality treatment of locally advanced or recurrent colon cancer, *Ann. Surg. Oncol.* 9 (2002) 177–185.
- [13] R.S. Croner, S. Merkel, T. Papadopoulos, V. Schellerer, W. Hohenberger, J. Goehl, Multivisceral resection for colon carcinoma, *Dis. Colon Rectum* 52 (2009) 1381–1386.
- [14] R. Sauer, H. Becker, W. Hohenberger, C. Rödel, C. Wittekind, R. Fietkau, et al., Preoperative versus postoperative chemoradiotherapy for rectal cancer, *N. Engl. J. Med.* 351 (2004) 1731–1740.
- [15] M. Cukier, A.J. Smith, L. Milot, W. Chu, H. Chung, D. Fenech, et al., Neoadjuvant chemoradiotherapy and multivisceral resection for primary locally advanced adherent colon cancer: a single institution experience, *Eur. J. Surg. Oncol.* 38 (2012) 677–682.
- [16] L.S. Schwartzberg, F. Rivera, M. Karthaus, G. Fasola, J.L. Canon, J.R. Hecht, et al., PEAK: a randomized, multicenter phase II study of panitumumab plus modified fluorouracil, leucovorin, and oxaliplatin (mFOLFOX6) or bevacizumab plus mFOLFOX6 in patients with previously untreated, unresectable, wild-type KRAS exon 2 metastatic colorectal cancer, *J. Clin. Oncol.* 32 (2014) 2240–2247.
- [17] F. Leone, S. Artale, D. Marino, C. Cagnazzo, S. Cascinu, C. Pinto, et al., Panitumumab in combination with infusional oxaliplatin and oral capecitabine for conversion therapy in patients with colon cancer and advanced liver metastases. The MetaPan study, *Cancer* 119 (2013) 3429–3435.
- [18] C. Pinto, F. Di Fabio, E. Maiello, S. Pini, T. Latiano, C. Aschele, et al., Phase II study of panitumumab, oxaliplatin, 5-fluorouracil, and concurrent radiotherapy as preoperative treatment in high-risk locally advanced rectal cancer patients (StarPan/STAR-02 Study), *Ann. Oncol.* 22 (2011) 2424–2430.
- [19] Medical Research Council Oesophageal Cancer Working Group, Surgical resection with or without preoperative chemotherapy in oesophageal cancer: a randomised controlled trial, *Lancet* 359 (2002) 1727–1733.
- [20] D. Cunningham, W.H. Allum, S.P. Stenning, J.N. Thompson, C.J. Van de Velde, M. Nicolson, et al., Perioperative chemotherapy versus surgery alone for resectable gastroesophageal cancer, *N. Engl. J. Med.* 355 (2006) 11–20.
- [21] D. Sebag-Montefiore, R.J. Stephens, R. Steele, J. Monson, R. Grieve, S. Khanna, et al., Preoperative radiotherapy versus selective postoperative chemoradiotherapy in patients with rectal cancer (MRC CR07 and NCIC-CTG C016): a multicenter, randomised trial, *Lancet* 373 (2009) 811–820.
- [22] S.R. Alberts, D.J. Sargent, S. Nair, M.R. Mahoney, M. Mooney, S.N. Thibodeau, et al., Effect of oxaliplatin, fluorouracil, and leucovorin with or without cetuximab on survival among patients with resected stage III colon cancer: a randomized trial, *JAMA* 307 (2012) 1383–1393.
- [23] C.J. Allegra, G. Yothers, S. O'Connell, J. Sharif, N.J. Petrelli, L.H. Colangelo, et al., Phase III trial assessing bevacizumab in stages II and III carcinoma of the colon: results of NSABP protocol C-08, *J. Clin. Oncol.* 29 (2011) 11–16.
- [24] R.A. Agha, A.J. Fowler, A. Saetta, I. Barai, S. Rajmohan, D.P. Orgill, The SCARE Group, The SCARE statement: consensus-based surgical case report guidelines, *Int. J. Surg.* 34 (2016) 180–186.

Open Access

This article is published Open Access at sciendo.com. It is distributed under the [IJSCR Supplemental terms and conditions](#), which permits unrestricted non commercial use, distribution, and reproduction in any medium, provided the original authors and source are credited.