

Rintala Flap and Posterior Perichondrial Cutaneous Graft: A Combined Approach for Nasal Tip Reconstruction

Ebai A. Eseme, MD*

Daniel Da Rocha, BS*

Mathias Tremp, MD†‡

Evangelia Tzika, MD¶

Rastine Merat, MD, PhD¶

Daniel F. Kalbermatten, MD, PhD*

Carlo M. Oranges, MD, PhD*

Summary: Nasal tip reconstruction requires a meticulous approach due to the complexity of the nasal anatomy and its aesthetic importance. Many procedures have been described to restore this aesthetic unit, including the paramedian forehead flap, which is one of the workhorse flaps. However, despite excellent final outcomes, this procedure may be refused by patients, due to its temporary conspicuous appearance possibly associated with serious psychological implications, and the need of multiple interventions. We aimed to present an approach combining the Rintala flap and the posterior perichondrial cutaneous graft as a valuable alternative to treat large nasal tip defects. (*Plast Reconstr Surg Glob Open* 2022;10:e4316; doi: 10.1097/GOX.0000000000004316; Published online 6 May 2022.)

Nasal tip reconstruction requires a meticulous approach due to the complexity of the nasal anatomy and its aesthetic importance. When dealing with a large defect, it is essential to consider aesthetic subunits and the type of reconstructive procedure to ensure a successful aesthetic and psychological outcome for the patient. Many procedures have been described to restore this aesthetic unit, including grafts and local flaps. When considering closure of defects of the tip, one should acknowledge that closure with a shortened flap with undue tension could lead to nasal shortening and tip elevation.^{1,2} The paramedian forehead flap, which is one of the workhorse flaps could be a good alternative in such situations. However, despite good final outcomes, this procedure may be refused by the patients, due to its

temporary conspicuous appearance possibly associated with serious psychological implications, and the need of multiple interventions. Quality of care does not take into consideration only the surgeon's opinion but also the patient's needs, values and preferences, as well as the psychological implications of the treatment option.³

We aimed to present an approach combining the Rintala flap and the posterior perichondrial cutaneous graft (PPCG) as a valuable alternative to treat large nasal tip defects.

CASE PRESENTATION

We present the case of a 25-year-old male patient who was referred to our department for a scar excision with a 1-cm margin after removal of a melanoma on the tip of his nose. Two months before, the lesion was entirely removed in the dermatology unit of our hospital and characterized as a nonulcerated Breslow index 0.25-mm melanoma. We discussed with the patient the various available reconstructive options from skin grafts to local flap, listing the advantages and inconveniences of each approach. The frontal flap was initially proposed to the patient as the gold standard for his case. Pictures of similar nasal reconstructions with the frontal flap were shown to the patient, who systematically refused the option because of the number of procedures (two separate procedures) and the psychological impact on him. We then proposed to the patient a combined approach using a composite graft (PPCG) and a local flap (Rintala flap) to close the defect without tension (Fig. 1). This option

From the *Department of Plastic, Reconstructive and Aesthetic Surgery, Geneva University Hospitals, University of Geneva, Geneva, Switzerland; †Faculty of Medicine, University of Basel, Basel, Switzerland; ‡Hirslanden Private Hospital Group, Cham, Switzerland; and ¶Oncodermatology Unit, Division of Dermatology and Venerology, Geneva University Hospitals, Geneva, Switzerland. Received for publication February 1, 2022; accepted March 23, 2022.

Presented at the 12th European Plastic Surgery Research Council (EPSRC) Meeting, August 27–28, 2021, Turku, Finland; the 57th Congress of Swiss Plastic Surgery (SGPRAC-SSCPRE), October 22–23, 2021, Lucerne, Switzerland; Plastic Surgery The Meeting 2021, October 29–November 1, 2021, Atlanta, Georgia.

Copyright © 2022 The Authors. Published by Wolters Kluwer Health, Inc. on behalf of The American Society of Plastic Surgeons. This is an open-access article distributed under the terms of the Creative Commons Attribution-Non Commercial-No Derivatives License 4.0 (CCBY-NC-ND), where it is permissible to download and share the work provided it is properly cited. The work cannot be changed in any way or used commercially without permission from the journal.

DOI: 10.1097/GOX.0000000000004316

Disclosure: The authors have no financial interest to declare in relation to the content of this article.

Related Digital Media are available in the full-text version of the article on www.PRSGlobalOpen.com.

seemed more suitable for the patient after observing the pictures of both procedures separately. The patient gave his consent for the surgery. Surgical intervention was done under general anesthesia. The first part of the intervention started with an incision of the skin around the previous melanoma scar with a 1-cm margin of radius around the scar. The dimensions of the defect after wide excision of cutaneous and subcutaneous layers were equal to 40×24mm (Fig. 2). The incision followed the classic drawing of the Rintala flap. The nasal dorsum was undermined into the glabellar and brow area at the periosteal level to include the procerus and glabellar muscles superiorly. (See figure 1, Supplemental Digital Content 1, which displays the elevated Rintala flap. <http://links.lww.com/PRSGO/C29>.)

The distal end of the flap was advanced and could cover part of the defect at the tip of the nose. (See figure 2, Supplemental Digital Content 2, which displays the Rintala flap covering the cranial aspect of the defect. <http://links.lww.com/PRSGO/C30>.)

We then harvested the PPCG in the retro-auricular region, including the perichondrial layer with no resection of the conchal bowl. The graft measured 2.5×1 cm, and closure of the donor site was done with a transposition flap. The PPCG was then used to reconstruct the distal part of the defect (Fig. 3). The result at 12 months (Fig. 4) was satisfactory, with a good cosmetic outcome, nose stability and symmetry, and no contraction nor depression of the nose. The donor site healed uneventfully.

DISCUSSION

Plastic surgeons are frequently required to reconstruct nasal tip defects as a result of skin cancer excision after a

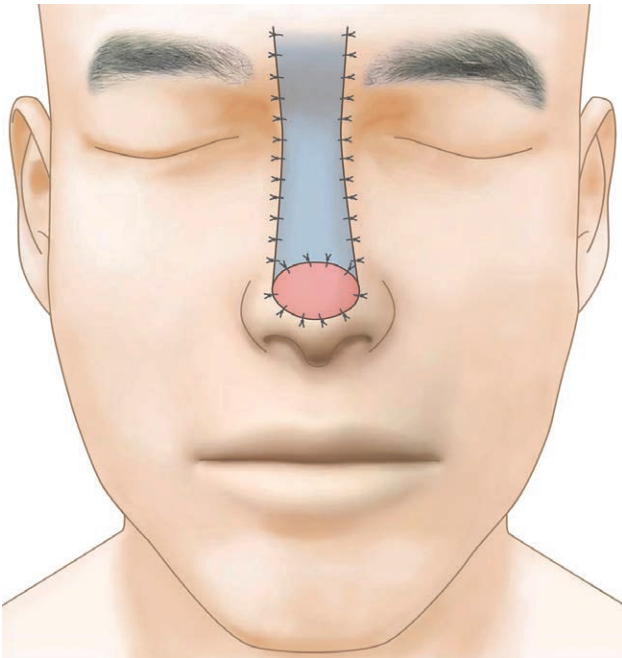


Fig. 1. Schematic representation of the procedure showing the Rintala flap (blue) covering the aesthetic subunit of the dorsum of the nose, and the PPCG (pink) covering the aesthetic subunit of the tip of the nose.

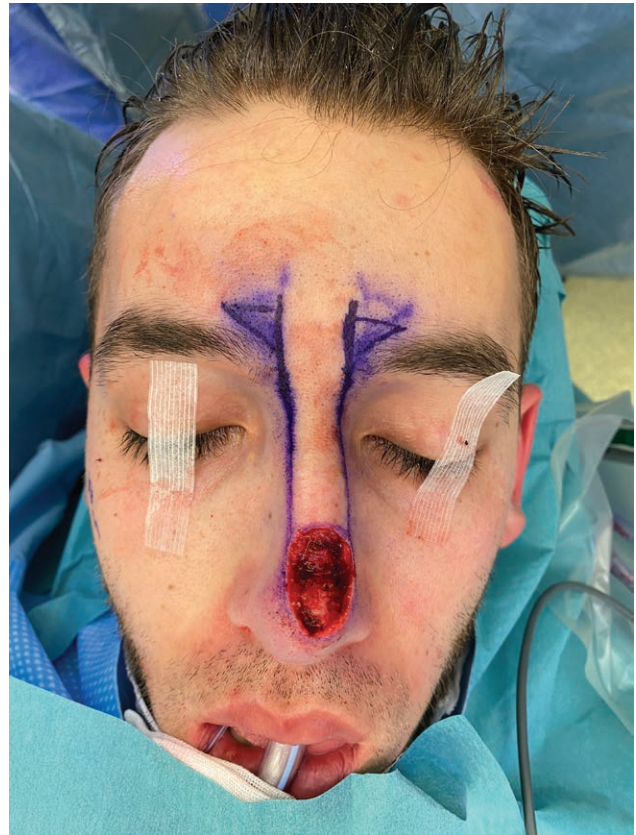

Fig. 2. Tissue defect of the distal aspect of the nose after wide excision with 1-cm margin around the scar of the previous melanoma resection. The defect measures 40×24 mm and involves the dorsum and the tip of the nose.

wide local excision or following Mohs micrographic surgery.⁴ Some of the factors that influence the outcome are an inconspicuous border scar, a good color and texture match with the surrounding skin, and symmetry.⁵ Many reconstructive options have been proposed but the aim remains to restore the anatomy, maintain airway patency, minimize morbidity and not neglect a good aesthetic outcome.^{4,5} The reconstructive approach should take into consideration the size, location, and depth of the defect to be corrected. Some of the frequently used techniques are skin graft, paramedian frontal flap, Rintala flap, cheek flaps, and nasolabial flaps.⁶⁻¹⁰ A full-thickness skin graft is a valuable and reliable nasal reconstructive option that provides aesthetic outcomes comparable to those achieved by local flaps in properly selected nasal defects. Some authors prefer to use skin grafts in patients with thin, less sebaceous skin, whereas local flaps are preferred for thicker more sebaceous skin, as found at the nasal tip. Another advantage of local flaps is the skin texture and color match, which gives a superior result when compared with skin grafts, which could also be more exposed to contractions than flaps.^{11,12} Although the PPCG has a survival rate comparable to that of full-thickness skin grafts, the PPCG presents less contraction due to its smooth composite composition, which includes few sebaceous glands. It is a reliable and stable option, indicated in case of tip cartilage

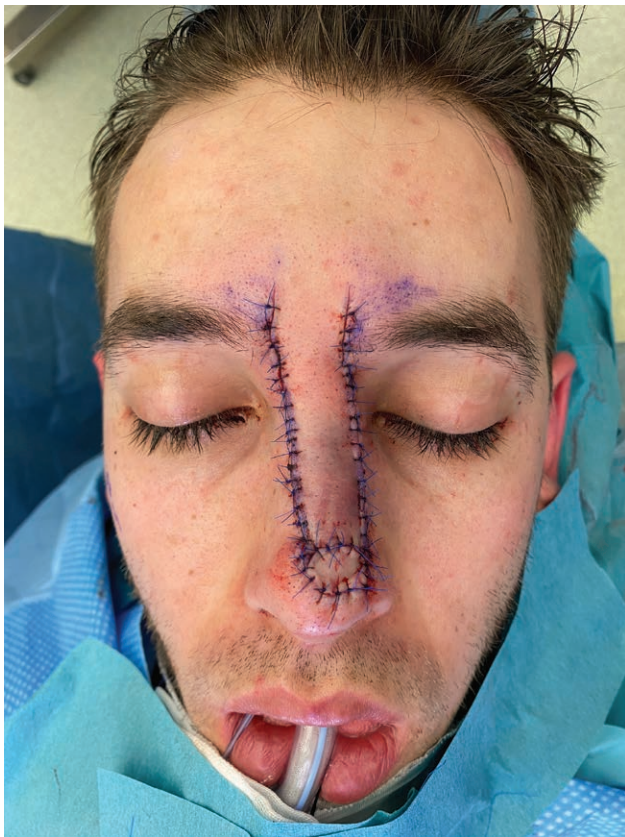

Fig. 3. Full reconstruction of the defect using a combination of Rintala flap and PPCG.

or fibro fatty tissue resection.^{13,14} We excluded a full defect reconstruction with PPCG to minimize complications and respect aesthetic subunits. Although PPCG can be harvested to a size to 2.5 cm by 4 cm, Stucker and Shaw report risks in case of large graft harvest, specifically necrosis of the graft, graft contraction, graft atrophy, textural changes, infection, and wound healing issues with the donor site.¹⁵

Respecting the aesthetic subunits while doing nasal reconstruction remains paramount. Our technique permitted us to respect this principle with the Rintala flap covering the dorsum of the nose and the PPCG covering the nasal tip.

Many authors propose a single approach for reconstruction, and for defects above 2 cm, repair is performed with the paramedian forehead flap, whereas under 1.5 cm defects, primary closure is performed using local transposition flaps or rotational flaps.¹⁰ The forehead flap is an excellent tissue match for both color and texture, associated with a rich vascular supply. Its disadvantages are mainly the number of procedures and the possible psychological impact on the patient.⁹ An alternative when the defect goes from 1.5 cm to 2 cm is the Rintala flap.⁹ This flap has the advantage of good tissue closure for defects of the tip, excellent viability, color match, and minimal scarring. Combining two techniques such as the Rintala flap and the PPCG for a large defect as an alternative to the paramedian frontal forehead flap could be a good option to reconstruct in one single procedure,

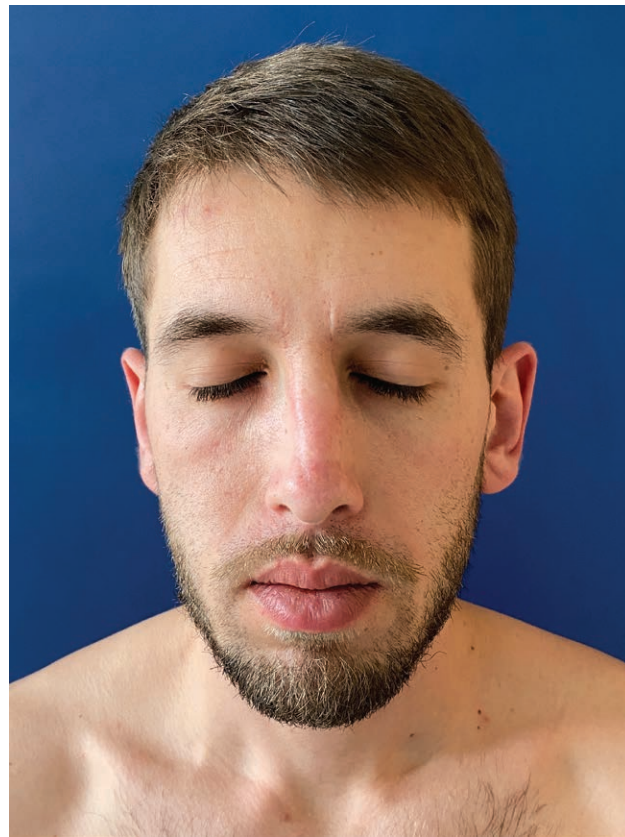


Fig. 4. Postoperative frontal view of the patient at 12 months follow-up.

respect the goals of nasal reconstruction, and avoid the psychological consequences of the frontal forehead flap.

CONCLUSIONS

The combination of Rintala flap and PPCG could be used as a single-stage reconstructive procedure of large nasal tip defects and provide good cosmetic and functional outcomes. This can be considered a valuable option particularly for patients who demonstrate a psychological inability to stand the mandatory steps of reconstruction for a paramedian forehead flap.

Carlo M. Oranges, MD, PhD

Department of Plastic, Reconstructive and Aesthetic Surgery
Geneva University Hospitals
Rue Gabrielle-Perret-Gentil 4
1205 Geneva, Switzerland
E-mail: carlo.oranges@hcuge.ch

PATIENT CONSENT

The patient provided written consent for the use of his image.

REFERENCES

1. Onishi K, Okada E, Hirata A. The Rintala flap: a versatile procedure for nasal reconstruction. *Am J Otolaryngol.* 2014;35:577–581.
2. Burget GC, Menick FJ. The Subunit principle in nasal reconstruction. *Plast Reconstr Surg.* 1985;76:239–2473.
3. Bonin L. Quality improvement in health care: the role of psychologists and psychology. *J Clin Psychol Med Settings.* 2018;25:278–294.

4. Hassid VJ. Nasal tip reconstruction following skin cancer resection: a novel approach combining reconstructive and tip rhinoplasty principles. *Plast Reconstr Surg*. 2018;142:990e–991e.
5. Maillard GF, Clavel PR. Aesthetic units in skin grafting of the face. *Ann Plast Surg*. 1991;26:347–352.
6. Cervelli V, Bottini DJ, Gentile P. Reconstruction of the nasal tip. *J Craniofac Surg*. 2007;18:1380–1384.
7. Khachemoune A, Johnson DS. Reconstruction of a large surgical defect of the nose. *Dermatol Surg*. 2004;30:1187–1190.
8. Rintala AE, Asko-Seljavaara S. Reconstruction of midline skin defects of the nose. *Scand J Plast Reconstr Surg*. 1969;3:105–108.
9. Girijala RL, Ramamurthi A, Walker GD, et al. Revisiting the Rintala advancement flap for nasal tip reconstruction. *Dermatol Online J*. 2020;26:13030/qt5dv0s7zx.
10. Motamedi KK, Amin SH, DeJoseph LM, et al. Aesthetic modification to the rintala flap: a case series. *Aesthetic Plast Surg*. 2014;38:395–398.
11. Saphavee A, Munaretto N, Toriumi DM. Skin grafts vs local flaps for reconstruction of nasal defects: a retrospective cohort study. *JAMA Facial Plast Surg*. 2015;17:270–273.
12. Austin GK, Shockley WW. Reconstruction of nasal defects: contemporary approaches. *Curr Opin Otolaryngol Head Neck Surg*. 2016;24:453–460.
13. van der Eerden P, Simmons M, Zuur K, et al. Full-thickness skin grafts and perichondrial cutaneous grafts following surgical removal of cutaneous neoplasms of the head and neck. *Eur Arch Otorhinolaryngol*. 2010;267:1277–1283.
14. Kalbermatten DF, Haug M, Wettstein R, et al. New posterior auricular perichondrial cutaneous graft for stable reconstruction of nasal defects. *Aesthetic Plast Surg*. 2005;29:489–495.
15. Stucker FJ Jr, Shaw GY. The perichondrial cutaneous graft. A 12-year clinical experience. *Arch Otolaryngol Head Neck Surg*. 1992;118:287–292.