




Comparative Evaluation of Coracoid Graft Dimensions in the Latarjet Surgery for Anterior Glenohumeral Instability*

Avaliação comparativa das dimensões do enxerto do coracoide na cirurgia de Latarjet para instabilidade glenoumeral anterior

Bernardo V.P. Alves¹  Gabriel S. Silva¹ Fábio Y. Matsumoto¹ Marco T. Ferreira¹ Almiro G. Britto¹ Fernando C. Mothes¹

¹Shoulder Surgery Group, Department of Orthopedics and Traumatology, Irmandade da Santa Casa de Misericórdia de Porto Alegre (ISCMPA), Universidade Federal de Ciências da Saúde de Porto Alegre (UFCSPA), Porto Alegre, RS, Brazil

Address for correspondence Bernardo V.P. Alves, Santa Casa de Misericórdia de Porto Alegre, Departamento de Ortopedia e Traumatologia, Rua Prof. Annes Dias 295–Centro, Porto Alegre, RS, 90020-090, Brasil (e-mail: bernardovpalves@gmail.com).

Rev Bras Ortop 2020;55(2):215–220.

Abstract

Objectives The aim of the present study was to describe the dimensions of the coracoid grafts in our Latarjet surgeries and compare them with the results described in the literature. In addition, the feasibility of the 7-millimeter rule was verified.

Methods Individuals with anterior glenohumeral instability with or without bone loss participated in the present study. The dimensions of 31 coracoid process grafts of patients who were submitted to the Latarjet surgical technique were measured with an analogical caliper and recorded for posterior analysis.

Results The dimensions of the coracoid graft did not show statistically significant differences related to gender. The graft width obtained from our sample presented similarities with the dimensions reported in the literature. However, the length and thickness were smaller when compared to the reference study (Young et al, 2013).¹⁵ The 7-millimeter rule was considered feasible regarding the graft dimensions obtained from our sample.

Conclusion The coracoid graft dimensions were similar to the dimensions described in the literature regarding width, but the same was not found for length and thickness; and the 7-millimeter rule was feasible regarding the graft dimensions obtained from our sample.

Keywords

- ▶ shoulder dislocation
- ▶ shoulder joint/injuries
- ▶ joint instability
- ▶ glenoid cavity
- ▶ bone transplantation

Resumo

Objetivo O objetivo deste estudo foi descrever as dimensões do processo coracoide em nossas cirurgias de Latarjet e compará-las com os resultados descritos na literatura. Além disso, a viabilidade da regra dos 7 milímetros foi verificada.

* Study developed by the Shoulder Surgery Group, Department of Orthopedics and Traumatology, Irmandade da Santa Casa de Misericórdia de Porto Alegre, Porto Alegre, RS, Brazil.



Palavras-chave

- ▶ luxação do ombro
- ▶ articulação do ombro/lesões
- ▶ instabilidade articular
- ▶ cavidade glenoide
- ▶ transplante ósseo

Métodos Indivíduos com instabilidade glenoumeral anterior com ou sem erosão óssea participaram deste estudo. As dimensões de 31 enxertos de processo coracoide de pacientes operados pela técnica de Latarjet foram mensuradas com um paquímetro analógico e registradas para análise posterior.

Resultados As dimensões do processo coracoide não demonstraram diferença estatisticamente significativa de acordo com o sexo. A largura do enxerto obtida em nossa amostra apresentou semelhança com as dimensões descritas na literatura. No entanto, o comprimento e a espessura foram um pouco menores quando comparados com o estudo de referência (Young et al, 2013).¹⁵ A regra dos 7 milímetros foi considerada viável com as dimensões do enxerto obtidas em nossa amostra.

Conclusão As dimensões do enxerto do coracoide foram similares às descritas na literatura em relação à largura, mas o mesmo não foi encontrado quanto ao comprimento e espessura; e a regra dos 7 milímetros demonstrou viabilidade com as dimensões do enxerto obtidas em nossa amostra.

Introduction

Latarjet surgery is the technique of choice for many surgeons to treat anterior glenohumeral instability with bone loss.¹⁻¹⁰ It was described in 1954 by Latarjet¹¹ and in 1958 by Helfet.¹² Patte and Debeyre¹³ associated the suture of the coracoacromial ligament with the capsule, and described the triple effect of this technique: a) bone effect of the coracoid process attached to the glenoid border; b) tendon anchorage effect on the lower third of the subscapularis; and c) tensioning effect of the capsule by suturing the coracoacromial ligament to it. The complications that compromise the outcome of surgery most associated with graft size are fracture of the graft during its preparation and positioning on the glenoid border – if it is superior or inferior in excess, the osseous and anchoring effect of the conjoined tendon is compromised, and if it is positioned in an excessively lateral position, then overhanging is favored, as well as the consequent glenohumeral arthrosis.

In the technique described by Walch and Boileau,¹⁴ two 4.5-mm malleolar screws are used. Without an adequate distance between the two holes, and between them and the coracoid process margins, the risk of graft fracture during preparation or mispositioning during glenoid fixation increases. In 2013, Young et al¹⁵ evaluated the dimensions of the coracoid processes after osteotomy and preparation, and verified the reproducibility of the 7-millimeter rule, in which the lower hole in the glenoid is made at least 7 mm from the articular margin to maintain the graft in a satisfactory position.

The aim of the present study was to compare the dimensions of the osteotomized coracoid process prepared in Latarjet surgeries with the results obtained by Young et al,¹⁵ as well as to verify the viability of the 7-millimeter rule considering the coracoid graft dimensions obtained from our sample. Our hypothesis was that the grafts collected from our patients would be smaller than those in the study by Young et al,¹⁵ and that the 7-millimeter rule could favor a glenoid graft positioning error.

Materials and Methods

From July 2015 to January 2017, the dimensions of 32 coracoid processes osteotomized during Latarjet surgeries were measured. One case of intraoperative fracture of the coracoid process was excluded due to the possibility of failure during the measurement – totaling 31 evaluated grafts. The surgical indications were patients with signs and symptoms of anterior glenohumeral instability, with or without glenoid bone erosion. All surgeries were performed by one of the four surgeons from our service.

The technique used in the patients of the present study was described by Walch and Boileau¹⁴ in 2000, with the subscapularis opening in the direction of its fibers and fixation of the coracoid process to the glenoid rim with two screws. The only variation of the surgical technique was in relation to the size and type of screw used – a 4.0-mm cancellous screw (▶ **Figure 1**). After osteotomy of the coracoid process (▶ **Figure 2**) and preparation of its inferior face, the intraoperative measurement was made with an analog caliper by the surgeon, who collected data on the graft dimensions: length in millimeters (from the tip to the base of the coracoid process, near the conjoint tendon insertion); width in millimeters (average distance between the two holes made for fixation; ▶ **Figure 3**) and thickness in millimeters (from the top edge to the bottom edge of the coracoid process).

Data distribution was verified through the Shapiro-Wilk test, and the continuous variables were expressed as mean and standard deviation. Analysis of variance (ANOVA) for one factor was performed for comparison of the thickness, length and width between men and women. The Student *t* test for independent samples was performed to compare the highest and the lowest widths among the measurements obtained by the present study and the reference study.¹⁵ Values of $p = 0.05$ were considered statistically significant. The ANOVA was performed using the International Business Machines Statistical Package for the Social Sciences (IBM SPSS, IBM Corp., Armonk, NY, US) software, version 21.0, and the *t* test

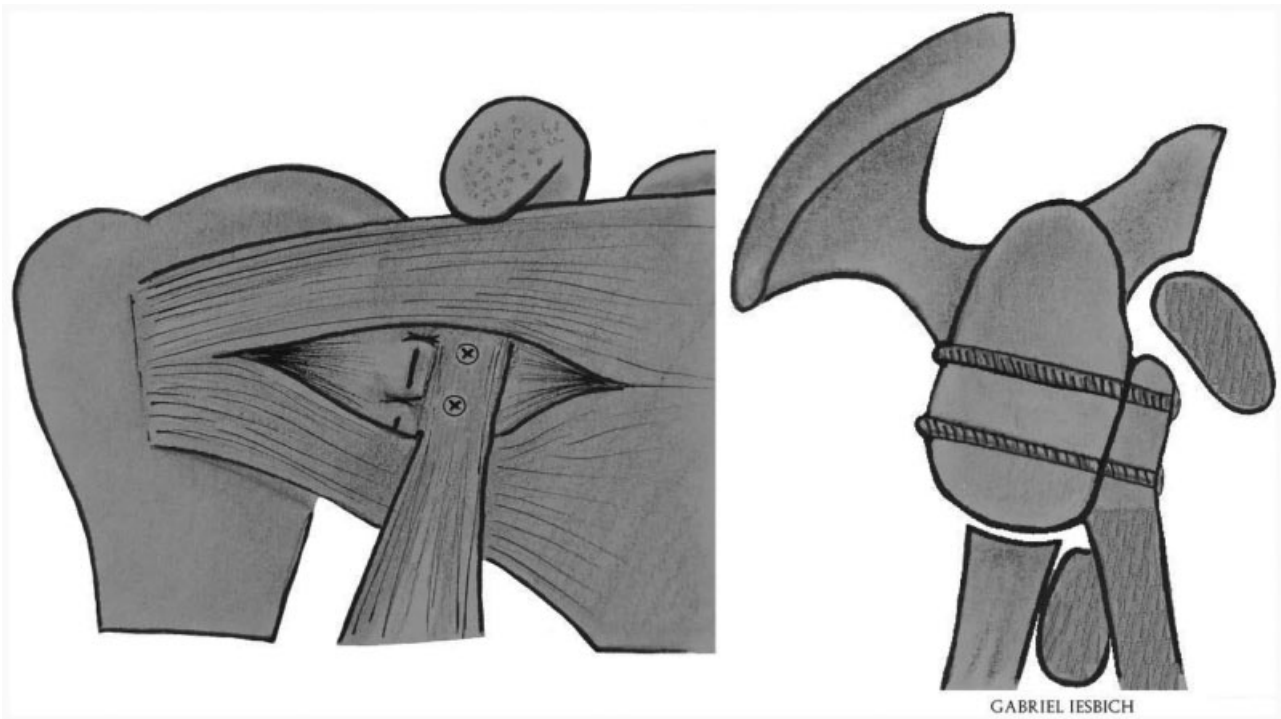


Fig. 1 Latarjet surgery.

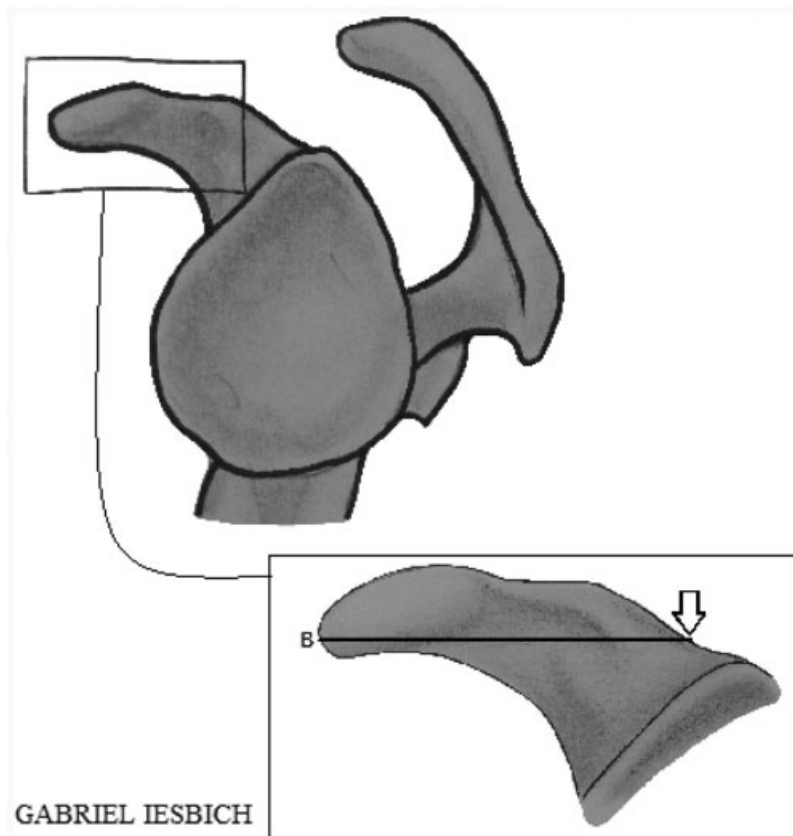


Fig. 2 Graft length measurement site; arrow: ideal site for osteotomy of the coracoid process.

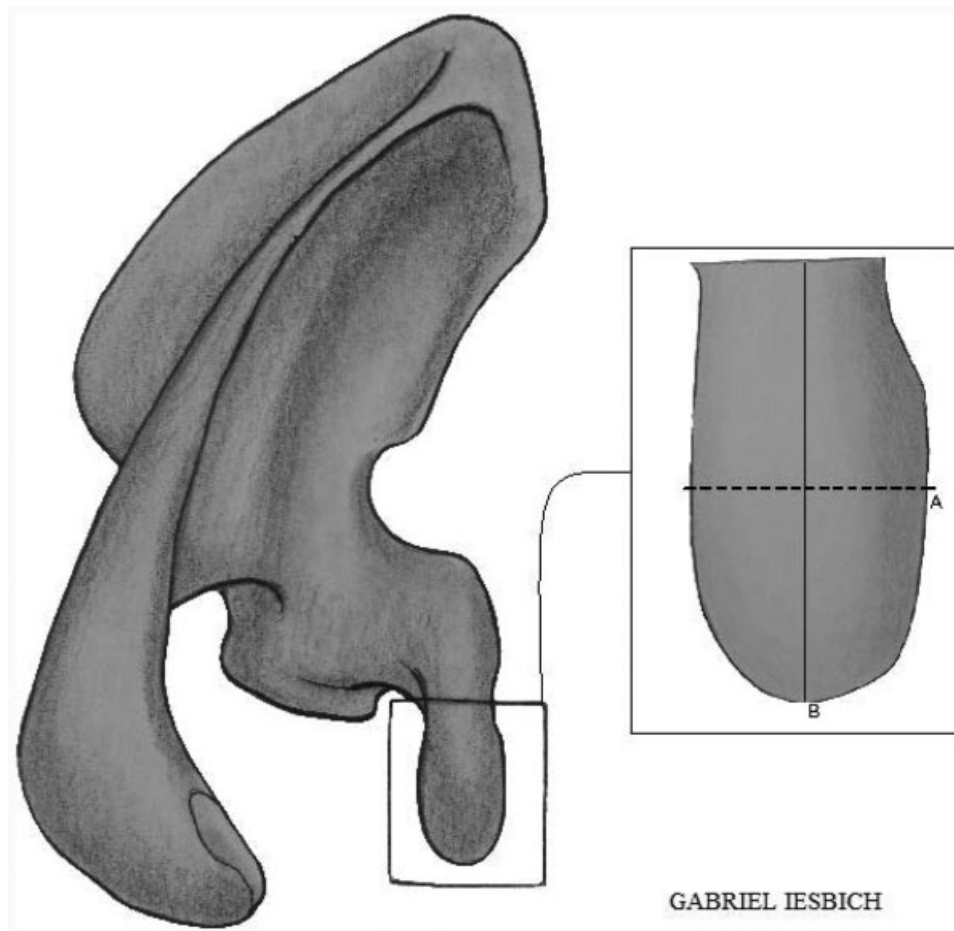


Fig. 3 (A) Location of the width measurement of the graft; (B) location of the length measurement of the graft. Source: Images of our own authorship.

was calculated using the Microsoft Excel software from the Office package (Microsoft Corp., Redmond, WA, US).

The present investigation was approved by the Ethics in Research Committee of the institution that proposed the study under number CAAE 65215317.2.0000.5335. All evaluated patients signed the informed consent form to take part in the study.

Results

We analyzed the dimensions of 31 coracoid processes of 31 patients submitted to the Latarjet surgery (27 males and 4 females; 1 case was excluded due to graft fracture during preparation). The average age of the sample was 30.26 years (18-69 years). Despite the small number of female participants, there was no statistically significant difference between the dimensions of the coracoid processes according to gender (– **Table 1**).

The mean length obtained was of 22.6 ± 1.9 mm, 3.8 mm shorter than that obtained by Young et al.¹⁵ The mean thickness was also significantly thinner than that obtained by Young et al.¹⁵ 7.9 ± 1.5 mm, which is 1.3 mm thinner than the one found in the compared work. The width did not present statistically significant differences in relation to the work by Young et al.¹⁵ (– **Table 2**). These authors performed two width measurements at the height of both holes. In our

Table 1 Graft dimensions according to gender

	Male (n = 27)	Female (n = 4)	p-value
Thickness	8.0 (1.6)	7.2 (1.2)	0.39
Length	22.8 (1.7)	21.7 (2.9)	0.30
Width	14.0 (2.1)	14.5 (2.3)	0.67

Note: Data presented as mean (standard deviation).

Table 2 Comparison of graft dimensions with the reference study (Young et al)¹⁵

	General measurements (n = 31)	General measurements of the reference study (n = 76)	p-value
Thickness	7.9 (1.5)	9.2 (1.4)	< 0.001*
Length	22.6 (1.9)	26.4 (2.9)	< 0.001*
Width	14.0 (2.1)	14.1 (1.8) - superior	0.93
		13.3 (1.8) - inferior	0.06

Notes: Data presented as: mean (standard deviation); *statistical significance.

Table 3 Comparison of graft dimensions with the reference study (Young et al)¹⁵ for males

	Males (n = 27)	Males in the reference study (n = 67)	p-value
Thickness	8.0 (1.6)	9.4 (1.4)	< 0.001*
Length	22.8 (1.7)	26.6 (2.7)	< 0.001*
Width	14.0 (2.1)	14.3 (1.7) - superior	0.47
		13.4 (1.7) - inferior	0.15

Notes: Data presented as mean (standard deviation); *statistical significance.

study, only one measurement was performed, which was compared with the two measurements by Young et al,¹⁵ but no statistically significant differences were found (► **Table 2**).

The dimensions of the graft compared with the reference work according to gender showed that in males the average length obtained was of 22.8 ± 1.7 mm, 3.8 mm shorter than that obtained by Young et al;¹⁵ the mean thickness was also inferior, but no statistically significant difference was found in relation to the width (► **Table 3**). In females, the graft dimensions were like those found in the reference study, with no statistically significant difference (► **Table 4**). There were no complications related to graft loosening or pseudarthrosis.

Discussion

The mean dimensions of the coracoid process obtained in the present study were 22.6 mm (18-26 mm) in length, 14.0 mm (11-20 mm) in width, and 7.9 mm (6-11 mm) in thickness. Regarding the study by Young et al,¹⁵ lower values for thickness and length were obtained, as detailed in the results (► **Tables 2 e 3**). When the data were analyzed separately according to gender, there was no difference in graft dimensions in females (► **Table 4**). There was no statistically significant difference regarding width in either sex, which makes the 7-millimeter rule valid in our patients. By this subjective rule, which is based only on the authors' experience, the lower hole is made 7 mm from the glenoid border, with no need to locate it through graft

Table 4 Comparison of graft dimensions with the reference study (Young et al)¹⁵ for females

	Females (n = 4)	Females in the reference study (n = 9)	p-value
Thickness	7.2 (1.2)	8.8 (1.6)	0.09
Length	21.7 (2.9)	24.8 (4.1)	0.13
Width	14.5 (2.3)	12.6 (1.0) - superior	0.20
		12.2 (1.9) - inferior	0.14

Note: Data presented as mean (standard deviation).

prepositioning, which has no scientific evidence in the literature. In our sample, no statistically significant differences were observed in graft dimensions according to gender, unlike previous studies.^{15,16}

Our hypothesis, which is based on the smaller size of our grafts, is that larger screws would increase the fragility of the prepared coracoid process. The fracture rate of the coracoid process published in the literature is low, ranging from 1.5 to 7%.^{17,18} Athwal et al¹⁷ observed that the area between the two holes was the most fragile region, but there is no defined distance between these holes. Young et al¹⁵ obtained a mean distance of 7.8 ± 1.9 mm between the holes. For arthroscopic surgery, Lafosse and Boyle⁵ developed a guide with 9 mm between the holes. In the present study, this distance was not measured, but it is possible to state that since the evaluated grafts had a shorter length, the interval between the two holes also tends to be shorter, increasing the risk of fracture. When using a smaller drill (with 2.5 mm), which differs from the technique described by Walch and Boileau,¹⁴ which uses 3.2-mm drills, the risk of fracture is probably reduced. In our sample, there were no complications, such as loosening or pseudarthroses, related to the use of 4.0-mm cancellous screws instead of 4.5-mm malleolar screws.

Dolan et al¹⁹ evaluated the dimensions of the coracoid process in scapulas of fresh cadaver specimens without performing osteotomy, and they obtained similar values for the width, but values that were 5.9 mm longer in relation to the length. This difference was expected due to technical difficulties in performing osteotomy exactly at the base of the coracoid process, preserving the insertion of the coracoclavicular ligaments during the surgical procedure. Comparing our results with those of Young et al,¹⁵ we obtained similar width values, but significantly smaller values in relation to length and thickness. A likely explanation would be the technical differences in performing the osteotomy and preparing the lower face of the coracoid process. The dimensions of the inferior face of the coracoid graft may be more influenced by the technical ability in contrast to the width, but this hypothesis still needs confirmation. Another hypothesis already demonstrated in other studies,²⁰ would be the difference in bone structure between the populations evaluated, but this is less likely.

One of the critical moments of Latarjet surgery is the placement of the graft at the glenoid border.²¹ Walch and Boileau¹⁴ first drill the lower hole at approximately 7 mm from the edge of the glenoid. According to the results obtained in the present study, this technique could be applied to our patients, since the width of the grafts was similar to that obtained by Young et al.¹⁵

The present study has some limitations. Firstly, the surgeries were not performed by the same surgeon, and each surgeon's technical skill may alter the point of the osteotomy. Secondly, it was not possible to verify whether the use of a 3.2-mm drill would make the graft more fragile. Thirdly, like the surgical technique, the measurement was not made by the same surgeon, and there may be differences regarding the measurement point. Some complications of Latarjet surgery are related to graft problems,^{6,12,21,22} among

them fractures, mispositioning, loosening and pseudoarthroses, which can lead to the recurrence of instability. Many of these complications can be avoided with a good knowledge of anatomy and of the surgical technique, enabling a good exposure to measure the accurate size of the graft and a fixation in the correct spot of the glenoid. Therefore, we think it is essential to use specific instruments for this surgery.

Conclusion

In the sample studied, similar dimensions were obtained when compared to the reference work¹⁵ considering the coracoid graft width; but the same did not occur for the length and thickness values, which were lower than in our study. In addition, the 7-millimeter rule proposed by other authors was viable in our patients.

Conflict of Interests

The authors have no conflict of interests to declare.

References

- Balg F, Boileau P. The instability severity index score. A simple pre-operative score to select patients for arthroscopic or open shoulder stabilisation. *J Bone Joint Surg Br* 2007;89(11):1470–1477
- Boileau P, Villalba M, Héry JY, Balg F, Ahrens P, Neyton L. Risk factors for recurrence of shoulder instability after arthroscopic Bankart repair. *J Bone Joint Surg Am* 2006;88(08):1755–1763
- Burkhardt SS, De Beer JF. Traumatic glenohumeral bone defects and their relationship to failure of arthroscopic Bankart repairs: significance of the inverted-pear glenoid and the humeral engaging Hill-Sachs lesion. *Arthroscopy* 2000;16(07):677–694
- Gupta A, Delaney R, Petkin K, Lafosse L. Complications of the Latarjet procedure. *Curr Rev Musculoskelet Med* 2015;8(01):59–66
- Lafosse L, Boyle S. Arthroscopic Latarjet procedure. *J Shoulder Elbow Surg* 2010;19(2, Suppl):2–12
- Mizuno N, Denard PJ, Raiss P, Melis B, Walch G. Long-term results of the Latarjet procedure for anterior instability of the shoulder. *J Shoulder Elbow Surg* 2014;23(11):1691–1699
- Paladini P, Singla R, Merolla G, Porcellini G. Latarjet procedure: is the coracoid enough to restore the glenoid surface? *Int Orthop* 2016;40(08):1675–1681
- Young AA, Maia R, Berhouet J, Walch G. Open Latarjet procedure for management of bone loss in anterior instability of the glenohumeral joint. *J Shoulder Elbow Surg* 2011;20(2, Suppl):S61–S69
- da Silva LA, da Costa Lima ÁG, Kautsky RM, Santos PD, do Val Sella G, Checchia SL. Evaluation of the results and complications of the Latarjet procedure for recurrent anterior dislocation of the shoulder. *Rev Bras Ortop* 2015;50(06):652–659
- Ikemoto RY, Murachovsky J, Nascimento LG, et al. Resultados da cirurgia de latarjet no tratamento da instabilidade anterior traumática do ombro associada à erosão óssea da cavidade glenoidal – seguimento mínimo de um ano. *Rev Bras Ortop* 2011;46(05):553–560
- Latarjet M. [Treatment of recurrent dislocation of the shoulder]. *Lyon Chir* 1954;49(08):994–997
- Helfet AJ. Coracoid transplantation for recurring dislocation of the shoulder. *J Bone Joint Surg Br* 1958;40-B(02):198–202
- Patte D, Debeyre J. Luxations recidivantes de l'épaule. *Encycl Med Chir Techn Chir Orthop*. 1982;44:265
- Walch G, Boileau P. Latarjet-Bristow procedure for recurrent anterior instability. *Tech Shoulder Elbow Surg* 2000;1(04):256–261
- Young AA, Baba M, Neyton L, Godeneche A, Walch G. Coracoid graft dimensions after harvesting for the open Latarjet procedure. *J Shoulder Elbow Surg* 2013;22(04):485–488
- Bhatia DN, de Beer JF, du Toit DF. Coracoid process anatomy: implications in radiographic imaging and surgery. *Clin Anat* 2007;20(07):774–784
- Athwal GS, Meislin R, Getz C, Weinstein D, Favorito P. Short-term Complications of the Arthroscopic Latarjet Procedure: A North American Experience. *Arthroscopy* 2016;32(10):1965–1970
- Griesser MJ, Harris JD, McCoy BW, et al. Complications and reoperations after Bristow-Latarjet shoulder stabilization: a systematic review. *J Shoulder Elbow Surg* 2013;22(02):286–292
- Dolan CM, Hariri S, Hart ND, McAdams TR. An anatomic study of the coracoid process as it relates to bone transfer procedures. *J Shoulder Elbow Surg* 2011;20(03):497–501
- Miyazaki AN, Itoi E, Sano H, et al. Comparison between the acromion index and rotator cuff tears in the Brazilian and Japanese populations. *J Shoulder Elbow Surg* 2011;20(07):1082–1086
- Butt U, Charalambous CP. Complications associated with open coracoid transfer procedures for shoulder instability. *J Shoulder Elbow Surg* 2012;21(08):1110–1119
- Shah AA, Butler RB, Romanowski J, Goel D, Karadagli D, Warner JJ. Short-term complications of the Latarjet procedure. *J Bone Joint Surg Am* 2012;94(06):495–501