

# Appropriate use of genetics in a young patient with atrioventricular block and family history of sudden cardiac death



Johnni Rudbeck-Resdal, MD,<sup>\*†</sup> Jens Cosedis Nielsen, MD, DMSc, PhD,<sup>\*†</sup>  
Henning Bundgaard, MD, DMSc,<sup>‡</sup> Henrik K. Jensen, MD, DMSc, PhD<sup>\*†</sup>

From the <sup>\*</sup>Department of Cardiology, Aarhus University Hospital, Aarhus, Denmark, <sup>†</sup>Department of Clinical Medicine, Health, Aarhus University, Aarhus, Denmark, and <sup>‡</sup>Unit for Inherited Cardiovascular Diseases, The Heart Centre, National University Hospital, University of Copenhagen, Copenhagen, Denmark.

## Introduction

Atrioventricular (AV) block is a common condition that occurs at all ages, but most often in the elderly.<sup>1</sup> Among younger patients, AV block is most often seen as a complication of cardiac surgery or as congenital AV block. In some (but rare) cases, AV block is due to genetic causes.

Variants in the lamin A/C gene are associated with AV block, cardiomyopathy, ventricular arrhythmias, muscular dystrophy, and sudden cardiac death.<sup>2,3</sup> Lamin A and lamin C are major structural proteins of the cell nucleus membrane.<sup>4</sup> The cellular mechanism causing AV block in patients with lamin A/C gene variants is not fully understood.<sup>5</sup>

Previous studies have shown that implanting an implantable cardioverter-defibrillator (ICD) in patients with lamin A/C variants complicated by AV block is effective in treating malignant ventricular arrhythmia (MVA), and thereby potentially preventing sudden cardiac death.<sup>6,7</sup>

We report how appropriate use of molecular genetic testing in a 35-year-old man with advanced AV block and family history of sudden cardiac death resulted in an upgrade of the patient's dual-chamber pacemaker to a biventricular ICD (cardiac resynchronization therapy defibrillator [CRT-D]), which most likely saved the patient's life.

## Case report

A 35-year-old man (II-1, [Figure 1](#)) was admitted to hospital (Aarhus University Hospital) owing to the incidental finding

**KEYWORDS** Aborted sudden cardiac death; Atrioventricular block; Genetic; ICD; Lamin A/C; LMNA  
(Heart Rhythm Case Reports 2019;5:169–172)

Dr Jensen has received lecture fees from Abbott and Biosense Webster and is supported by the Novo Nordisk Foundation (NNF18OC0031258). Dr Nielsen is supported by the Novo Nordisk Foundation (NNF16OC0018658). **Address reprint requests and correspondence:** Dr Johnni Rudbeck-Resdal, Department of Cardiology, Aarhus University Hospital, Palle Juul-Jensens Boulevard 99, 8200 Aarhus N, Denmark. E-mail address: [jd@clin.au.dk](mailto:jd@clin.au.dk).

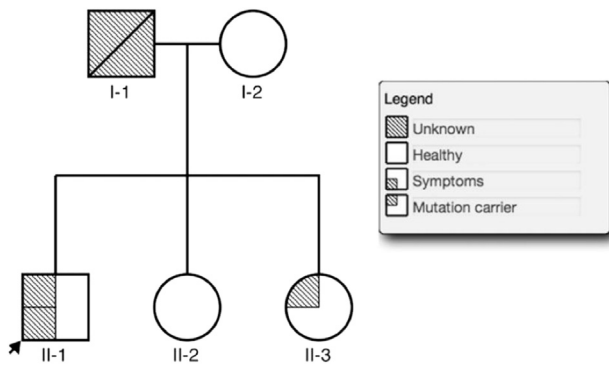
## KEY TEACHING POINTS

- Molecular genetic testing should be considered in younger patients with atrioventricular block and family history of sudden cardiac death.
- Predicting outcome based on clinical or genetic factors in lamin A/C variant carriers is difficult.
- An implantable cardioverter-defibrillator should be considered in patients with atrioventricular block and lamin A/C variant.

of advanced AV block on a routine check-up at his general practitioner. The patient had mild dyspnea during exercise and dizziness, but had no other symptoms and was in good physical condition.

Electrocardiogram at admission showed a heart rate at 25 beats per minute and advanced AV block with narrow QRS complexes ([Figure 2](#)). Echocardiography showed a borderline dilated left ventricle (LV) of 63 mm (left ventricular end diastolic diameter [LVEDD]) or 31 mm/m<sup>2</sup> (LVEDD/body surface area; normal <32 mm/m<sup>2</sup>) and otherwise structurally normal heart with normal systolic LV function, including normal tissue tracking. It was considered that the upper normal-range LV volume could be a result of long-term bradycardia. During admission, telemetry revealed episodes of total AV block with a maximum pause in heart rhythm of 6.6 seconds. A dual-chamber pacemaker was subacutely implanted.

As part of the subsequent family screening, it turned out that the patient's father (I-1, [Figure 1](#)) had died suddenly and unexpectedly while sleeping at the age of 45 years. No autopsy was performed. We identified no other cases of sudden cardiac death, device implantation, or cardiomyopathy in the family ([Figure 1](#)). Molecular genetic testing



**Figure 1** Family pedigree. The arrow points to the index case.

revealed a variant in *LMNA* (c.1411C>T, p.Arg471Cys, NM\_170707.3), ie, in a highly conserved position. Three in silico programs (SIFT, PolyPhen2, and Mutation Taster) predicted this mutation to be disease-causing. An Arg-to-His mutation in the same codon was previously associated with dilated cardiomyopathy.<sup>8</sup>

Molecular genetic testing of the patient's relatives identified his 25-year-old sister (II-3, [Figure 1](#)) as carrier of the same variant. She was asymptomatic with a significant prolongation of the PR interval (340 ms) and narrow QRS complexes.

Our index patient underwent follow-up echocardiography after 6 months pacing, showing no change in LV dimensions. Based on the persistently dilated LV, the family history, and

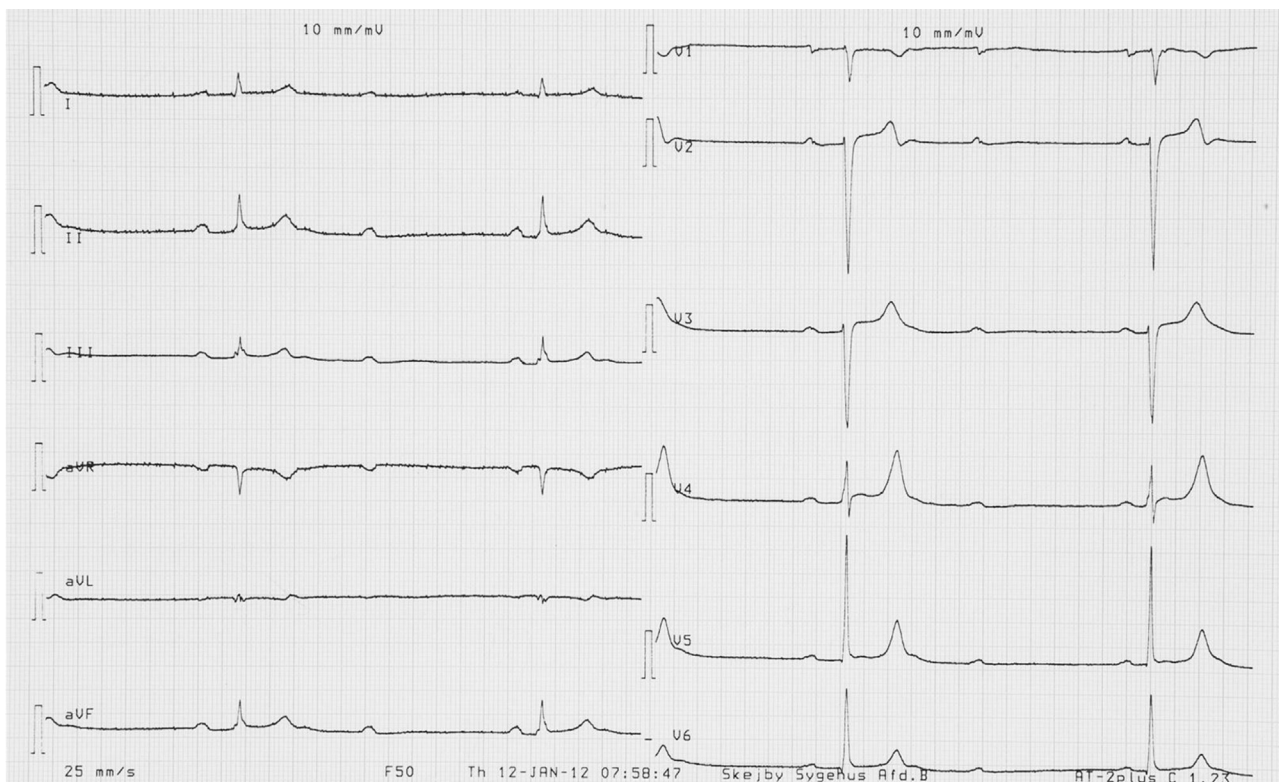
the malignant cause of disease in a proportion of patients with lamin A/C gene variants, it was decided to offer the patient a reoperation with upgrade to a CRT-D. CRT was chosen to minimize risk of progressive LV failure because of permanent right ventricular pacing.

During the night, 2 years after the upgrade, the patient's wife noticed some deep snoring sounds from the patient, followed by a twitch. Tracings from the CRT-D showed ventricular fibrillation (VF) with relevant therapy. Initial anti-tachycardia pacing was inefficient, and VF was terminated by appropriate shock therapy ([Figure 3](#)).

## Discussion

This case shows the important role of molecular genetic testing in predicting disease progression in patients with early-onset AV block. In general, genetic testing should be considered when an individual has a clinical diagnosis of an inherited heart disease, particularly if there is a positive family history.<sup>9,10</sup>

AV block is generally not considered an inherited heart disease, but in younger patients with unexplained AV block we consider it appropriate to obtain a family history focusing on close relatives with early-onset AV block, cardiomyopathy, sudden cardiac death, or muscular dystrophy. In case of a positive family history, genetic testing seems prudent, as genetic findings may add to the clinical decision as well as to cascade screening in the family.



**Figure 2** Twelve-lead electrocardiogram with advanced atrioventricular block.



## References

1. Danish Pacemaker and ICD Register. Danish Pacemaker and ICD Register - Annual report. 2015. Available at [https://ssl.icddata.dk/download/Danish\\_Pacemaker\\_and\\_ICD\\_Register\\_Annual\\_Report\\_2015b.pdf](https://ssl.icddata.dk/download/Danish_Pacemaker_and_ICD_Register_Annual_Report_2015b.pdf). Accessed April 10, 2018.
2. Fatkin D, MacRae C, Sasaki T, et al. Missense mutations in the rod domain of the lamin A/C gene as causes of dilated cardiomyopathy and conduction-system disease. *N Engl J Med* 1999;341:1715–1724.
3. Kumar S, Baldinger SH, Gandjbakhch E, et al. Long-term arrhythmic and nonarrhythmic outcomes of lamin A/C mutation carriers. *J Am Coll Cardiol* 2016; 68:2299–2307.
4. Dittmer TA, Misteli T. The lamin protein family. *Genome Biol* 2011;12:222.
5. Rankin J, Ellard S. The laminopathies: a clinical review. *Clin Genet* 2006; 70:261–274.
6. Meune C, Van Berlo JH, Anselme F, Bonne G, Pinto YM, Duboc D. Primary prevention of sudden death in patients with lamin A/C gene mutations. *N Engl J Med* 2006;354:209–210.
7. Anselme F, Moubarak G, Savoure A, et al. Implantable cardioverter-defibrillators in lamin A/C mutation carriers with cardiac conduction disorders. *Heart Rhythm* 2013;10:1492–1498.
8. Parks SB, Kushner JD, Nauman D, et al. Lamin A/C mutation analysis in a cohort of 324 unrelated patients with idiopathic or familial dilated cardiomyopathy. *Am Heart J* 2008;156:161–169.
9. Ingles J, Zodgekar PR, Yeates L, Macciocca I, Semsarian C, Fatkin D; CSANZ Cardiac Genetic Diseases Council Writing Group. Guidelines for genetic testing of inherited cardiac disorders. *Heart Lung Circ* 2011;20:681–687.
10. Priori SG, Wilde AA, Horie M, et al. HRS/EHRA/APHRS expert consensus statement on the diagnosis and management of patients with inherited primary arrhythmia syndromes: document endorsed by HRS, EHRA, and APHRS in May 2013 and by ACCF, AHA, PACES, and AEPC in June 2013. *Heart Rhythm* 2013;10:1932–1963.
11. Hasselberg NE, Edvardsen T, Petri H, et al. Risk prediction of ventricular arrhythmias and myocardial function in Lamin A/C mutation positive subjects. *Europace* 2014;16:563–571.
12. van Berlo JH, de Voogt WG, van der Kooij AJ, et al. Meta-analysis of clinical characteristics of 299 carriers of LMNA gene mutations: do lamin A/C mutations portend a high risk of sudden death? *J Mol Med (Berl)* 2005;83:79–83.
13. van Rijsingen IA, Arbustini E, Elliott PM, et al. Risk factors for malignant ventricular arrhythmias in lamin a/c mutation carriers a European cohort study. *J Am Coll Cardiol* 2012;59:493–500.