

# Infiltrating lipomatosis of the face: A case series

**Aadithya B. Urs,  
Jeyaseelan Augustine,  
Priya Kumar,  
Shelly Arora,  
Neha Aggarwal,  
Neha Sultana**

*Department of Oral and Maxillofacial Pathology, Maulana Azad Institute of Dental Sciences,  
New Delhi, India*

**Address for correspondence:**

*Dr. Aadithya B. Urs, Department of Oral and Maxillofacial Pathology, Maulana Azad Institute of Dental Sciences, New Delhi, India. E-mail: draadithya@sify.com*

## Abstract

Infiltrating lipomatosis of the face is a very rare entity which is characterized by the collection of non-encapsulated mature adipocytes infiltrating local tissues, resulting in craniofacial deformities. Psychomotor development of the patients is normal, esthetics often being the primary concern to seek treatment. The presentation is always unilateral with hypertrophy of hard and soft structures on the affected side of the face. The pathogenesis of the condition is unclear. This condition shows a wide phenotypic range, uncertain prognosis with high rates of recurrence after surgery, and variable post-op cosmetic improvement. The condition shows no gender predilection, with most of the cases presenting in and beyond the second decade of life. Here, we present a series of four cases presenting in varying age groups with history of recurrence in three cases.

**Key words:** *Hypertrophy, infiltrating, lipomatosis, recurrence*

## INTRODUCTION

Infiltrating lipomatosis of the face is a distinct clinicopathological rare entity which falls under the subgroup of lipomatous tumor like lesions and is characterized by collection of non-encapsulated, mature adipocytes that infiltrate local tissues, leading to craniofacial deformities and tend to recur after surgery.<sup>[1]</sup>

It was first described by Slavin *et al.* in 1983.<sup>[2]</sup> Facial infiltrating lipomatosis causes diffuse overgrowth of subcutaneous fat, muscle, and bone.<sup>[3]</sup> Patients have normal psychomotor development with esthetics often being the primary concern.<sup>[4,5]</sup> Here, we report four cases of chronic infiltrating lipomatosis presenting in varying age groups with a history of recurrence in three cases.

## CASE REPORTS

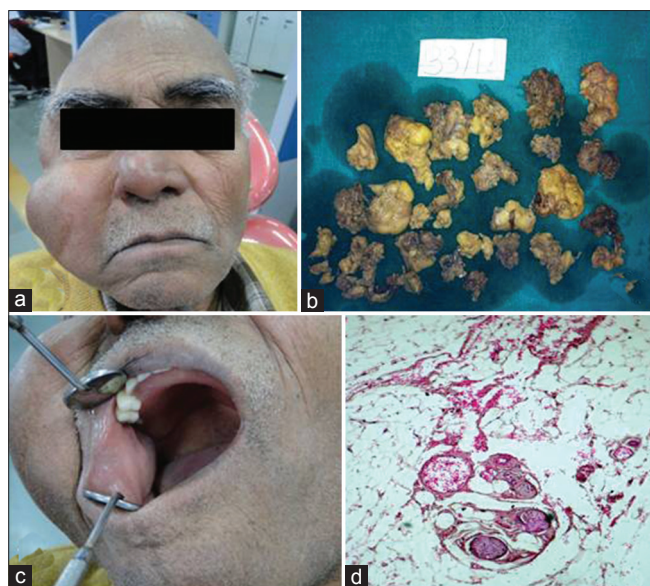### Case 1

A 77-year-old male reported to the outpatient department, complaining of a swelling in the right cheek region since 30 years, with no history of pain or pus discharge. Patient revealed a previous history of liposuction 7 years ago for the same complaint.

On extraoral examination, a swelling was seen on the right cheek, extending from preauricular region to the lower border of the mandible, measuring approximately 8 × 10 cm in size [Figure 1a]. Intraorally, it covered the entire right buccal mucosa [Figure 1b]. The swelling was soft, non-tender, and fluctuant on palpation.

Incisional biopsy was done which was suggestive of infiltrating lipomatosis, following which the patient underwent surgical removal of the lesion. Excised tissue was submitted to the Department of Oral Pathology as multiple soft tissue bits, with the largest bits measuring around 5 × 3 and 5 × 2 cm in size, brown and yellow in color, irregular in outline, and firm in consistency [Figure 1c].

On microscopic examination, large amounts of adipose tissue composed of empty appearing adipocytes with peripherally placed nuclei were seen. The fatty tissue was seen infiltrating through muscle planes and associated with neurovascular bundles. Numerous thick-walled arteries and nerve bundles were observed surrounded by adipose tissue [Figure 1d]. Areas of fibrosis and



**Figure 1:** (a) Extent of the swelling extraorally; (b) Intraoral swelling covering the right buccal mucosa; (c) Gross specimen; (d) Adipocytes infiltrating neurovascular bundle (H and E, ×200)

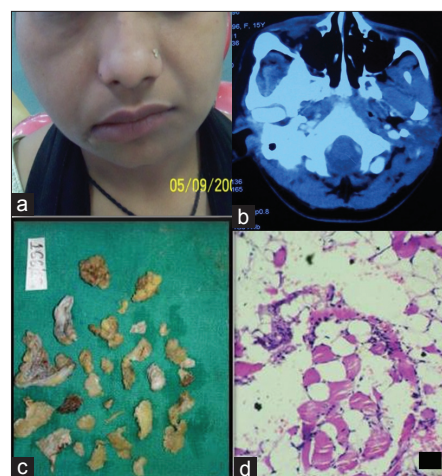
hemorrhage were also noted. The final diagnosis was suggestive of infiltrating lipomatosis.

### Case 2

A 17-year-old female reported with a complaint of swelling in the right cheek, present since birth. The patient first presented with the lesion in 2009. She underwent surgical excision from zygoma and mandible. The lesional tissue was sent for histopathologic examination which was suggestive of an infiltrating lipomatous lesion. In late 2010, the swelling recurred and an incisional biopsy was performed, suggestive of infiltrating lipomatosis. The patient was unwilling to undergo any further treatment. She reported again in 2012 with an increase in the size of the previously reported swelling.

On extraoral examination, a swelling was present unilaterally over the right maxilla/zygoma, extending upward till orbit, posteriorly till the ear lobe, and inferiorly to the lower border of the mandible [Figure 2a]. The swelling was soft on palpation; no lymph nodes were clinically palpable. Intraorally, there was enlargement of the maxillary right posterior alveolar region, extending from the maxillary right second premolar posteriorly up to the tuberosity.

On contrast-enhanced computed tomography (CECT), the right masseter and buccinator appeared heterogeneous with areas of fat attenuation within. There was an increase in the right side buccal fat with extraoral fat stranding which caused poor differentiation of lateral margins of underlying muscles [Figure 2b]. Right parotid and submandibular gland also appeared mildly bulky and heterogeneous with areas of fat attenuation within, likely



**Figure 2:** (a) Extraoral extent; (b) Contrast-enhanced computed tomography showing fatty infiltration of the buccinator, masseter, and parotid gland; (c) Gross specimen; (d) Adipocytes infiltrating the muscle (H and E, ×200)

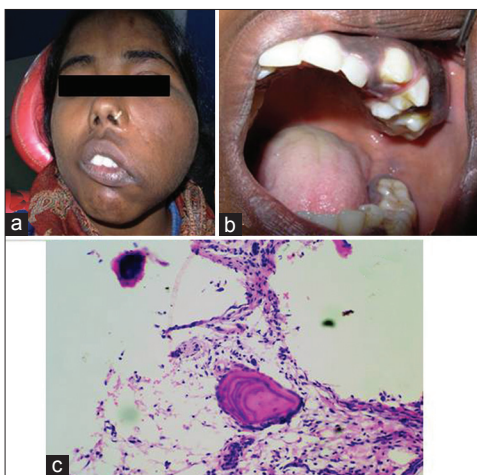
due to fatty infiltration. Right side facial bones appeared mildly thickened. An incisional biopsy was done, which on microscopic examination showed fat cells infiltrating in the muscle and admixed with blood vessels in a loosely collagenous stroma [Figure 2d]. It was suggestive of infiltrating lipomatous lesion. The patient underwent surgical excision and the excised tissue submitted to the department was in the form of multiple soft tissue bits, yellowish in color, the largest measuring  $3 \times 2.5 \times 2$  cm [Figure 2c]. The excisional tissue studied was compatible with infiltrating lipomatosis.

### Case 3

A 20-year-old female presented with complaint of a swelling on the left side of the face, present since birth. There was a previous history of surgery at the age of 5 years for the same complaint. It was provisionally diagnosed as hemifacial hypertrophy as there was associated enlargement of the maxillary alveolus of the same side.

On extraoral examination, a swelling was seen on the left side of the face, extending from preauricular region to the lower border of the mandible, measuring approximately  $8 \times 10$  cm in size [Figure 3a]. The swelling was soft, non-tender, and fluctuant on palpation. Intraorally, there was enlargement of the left maxillary and mandibular alveolar processes, causing displacement of teeth [Figure 3b].

Incisional biopsy was done and the gross specimen was received as two soft tissue bits measuring around  $1.2 \times 1 \times 0.5$  cm,  $2 \times 0.5 \times 0.5$  cm, irregular in outline, creamish brown in color, and soft in consistency. The hard tissue portion (maxillary alveolus) was received as three large-sized hard tissue bits measuring



**Figure 3:** (a) Large swelling on the left side of the face; (b) Intraoral expansion of maxillary alveolar process; (c) Adipocytes infiltrating the marrow spaces (H and E,  $\times 200$ )

around  $2 \times 1.5 \times 0.5$  cm,  $1.5 \times 0.5 \times 0.5$  cm, and  $0.8 \times 0.5 \times 0.5$  cms, white and brown in color and hard in consistency.

On microscopic examination, sections from upper lip and cheek of left side showed large amounts of adipose tissue infiltrating the muscle planes. Numerous blood vessels and extravasated erythrocytes were also observed. Decalcified sections from maxillary alveolus showed adipose tissue within the marrow spaces [Figure 3c]. Few resorbed and some normal bony trabeculae were also seen. Incisional biopsy was suggestive of infiltrating lipomatosis. The patient is scheduled for an excisional surgery for esthetic purpose.

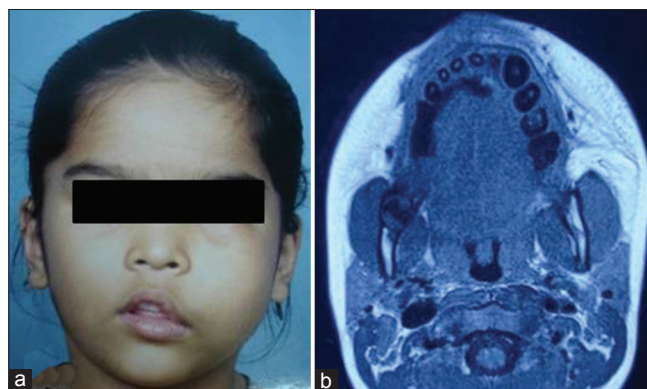
### Case 4

A 5-year-old girl presented with the complaint of swelling on the left side of the face since birth with no history of pain or pus discharge. The swelling showed no change in size since birth.

On clinical examination, there was a diffuse swelling over left cheek region, extending from infraorbital rim to lower border of mandible and anteroposteriorly from the angle of mouth to 2 cm in front of tragus [Figure 4a]. No lymph nodes were clinically palpable. Intraoral examination revealed minor enlargement of alveolar process on the left side, early eruption of 23, 24, 26, and early exfoliation of 63 and 64.

Magnetic resonance imaging (MRI) showed poorly defined lipomatous lesion on the left side of the cheek, in subcutaneous plane, and buccal pad of fat, with secondary hypertrophy of maxillary alveolus and hyperplasia of left maxillary sinus. No fatty infiltration of muscles was seen [Figure 4b].

Incisional biopsy was done. On gross examination, the received soft tissue specimen was measuring  $1.5 \times 0.8 \times 0.4$  cm in size, and was light brown in



**Figure 4:** (a) Diffuse swelling over left cheek; (b) Magnetic resonance imaging showing fatty infiltration



color, soft in consistency, and irregular in shape. Histopathologic examination of the section showed collection of adipocytes with scanty fibrous tissue. A diagnosis of infiltrating lipomatosis was given after correlating with the MRI findings.

The patient is being kept on a regular follow-up and no treatment has been advocated as the patient is very young.

## DISCUSSION

Lipomas are the most common benign tumors of mesenchymal origin.<sup>[6]</sup> Benign lipomatous tumors have been subclassified according to their histologic features and growth patterns into classic lipomas, fibrolipoma, angioliipoma, infiltrating lipomas, intramuscular lipomas, hibernoma, pleomorphic lipomas, lipoblastomatosis, and diffuse lipoblastomatosis. Infiltrating lipomatosis of the face is an uncommon mesenchymal neoplasm in which mature adipocytes invade the adjacent tissue and is extremely rare in the head and neck region.<sup>[7]</sup> While rare, it remains a definite clinical entity. The phenotypic features include soft-tissue and skeletal hypertrophy, premature dental eruption, and regional macrodontia. The etiology, natural history, optimal management, and relationship to other disorders of fatty overgrowth are unclear. There is a high risk for regrowth after resection that is, perforce, subtotal.<sup>[8]</sup>

Infiltrating lipomatosis is classified as a subgroup of lipoma. It occurs after the third decade of life and involves subcutaneous tissue, muscles, and bones.<sup>[6]</sup> Out of our four reported cases, three were females and varied in age from 5 to 77 years. Males and females are usually affected equally; there is no predilection between the right and left sides of the face.<sup>[3]</sup> The condition involves cheek, buccal sulcus, tongue, lip, floor of the mouth, mental area, and parotid gland.<sup>[6]</sup>

The lipomatosis lesion found in childhood includes congenital infiltrating lipomatosis of the face, diffuse lipomatosis, nevus lipomatosis cutaneous superficialis, Michelin tire baby syndrome, and macrocephalia (Bannayan-Zonana syndrome).<sup>[9]</sup> Out of the four cases reported here, two cases were congenital infiltrating lipomatosis. According to Heymans *et al.*, the origin of deformities in congenital infiltrating lipomatosis would be neuronal crest anomalies.<sup>[5]</sup>

The possible mechanisms for lipomatous change that have been proposed are trauma, chronic irradiation, muscular metaplasia, degenerative processes with fatty transformation, multipotent cells of embryonic

origin under the influence of hormones, congenital cytomegalovirus infection, and alteration in chromosome 12.<sup>[1,6,10]</sup>

Infiltrating lipomatosis presents with a diffuse large swelling on the side of the face that is soft, fluctuant, and non-tender. The clinical features of facial lipomatosis include unilateral hypertrophy of soft tissues of the face, most commonly the cheek, with underlying fat infiltration and skeletal overgrowth,<sup>[1,6,8,10-22]</sup> cutaneous capillary blush (usually after resection),<sup>[8]</sup> macrodontia on the affected side,<sup>[1,8,11,14,17]</sup> abnormal root formation,<sup>[11]</sup> early eruption of deciduous and permanent teeth on the affected side,<sup>[8,21,22]</sup> macroglossia,<sup>[8,20,22]</sup> and protuberances on the tongue and buccal mucosa, which are representative of underlying mucosal neuromas.<sup>[8,22]</sup> Unilateral hypertrophy of soft tissues was seen in all the cases studied. Premature eruption of teeth was seen in one case in the present series.

Differential diagnosis includes Proteus syndrome, hemifacial hypertrophy, encephalocraniocutaneous lipomatosis, hemihyperplasia-multiple lipomatosis syndrome, Bannayan-Riley-Rulvacaba syndrome, and vascular malformations (hemangioma).<sup>[8]</sup> In the series reported here, case 3 had a provisional diagnosis of hemifacial hypertrophy.

Imaging evaluation of soft tissue tumors has undergone a dramatic evolution with the advent of CT and MRI, which are useful for definite differential diagnosis.<sup>[23]</sup>

Classic lipomas have CT and MRI signal intensity characteristics similar to those of subcutaneous fat. On CT scans, lipomas appear as homogenous hypoattenuated masses (apart from thin and wispy soft tissue attenuated septa, although on occasion, septa may be thick and nodular). They have a CT number ranging from -60 to -120 HU and do not typically show contrast enhancement. In case 2, CECT of the face revealed right masseter and buccinator appearing heterogeneous with areas of fat attenuation within.<sup>[8]</sup>

On MR images, fat has typical signal intensity. On T1-weighted images, lipomas tend to have high signal intensity that diminishes with progressive T2 weighting. MRI provides better tumor delineation because it has superior soft tissue contrast resolution and clear definition of the location and longitudinal extent of the mass.<sup>[8]</sup> In the presented cases, MRI showed poorly defined lipomatous lesion. Plain radiographs show hypertrophy of facial bones and soft tissue swelling. Ultrasonography (USG) may show adipose tissue, but cannot delineate the real extent of the lesion.<sup>[5]</sup>

Bone changes in congenital infiltrating lipomatosis of face include sclerosis and hyperplasia of the skull, cervical vertebrae, hemimandibular hyperplasia (including ramus, condylar process), accelerated dentoskeletal growth, and zygomatic hyperplasia.<sup>[17]</sup> In one study by Sahai *et al.*, congenital infiltrating lipomatosis of the face has also been associated with temporomandibular joint (TMJ) remodeling, showing hyperplasia of the condylar process and eventually ankylosis. These changes could be related to increased vascularity, periosteal irritation from overlying mass, or regional mesenchymal malformation.<sup>[24,25,26]</sup> In case 4, MRI showed secondary hypertrophy of maxilla of the same side. In case 2, mild flattening of the right condylar head was noted, which may represent secondary degenerative arthropathy.

A biopsy is almost always needed to establish diagnosis and is done in all cases. In gross appearance, the lesion is a brown and yellow-colored mass, irregular in outline, and soft to firm in consistency. There is variability in size ranging from small bits less than  $2 \times 0.5 \times 1.5$  cm to large masses measuring almost  $8 \times 7$  cm. The specimens usually show yellowish white adipose tissue with gray white areas.

The histopathologic examination shows non-encapsulated proliferation of mature adipose tissue surrounded by an extensive capillary network. There is diffuse infiltration of adjacent soft tissue and presence of fibrous tissue with various nerve bundles and thickened wall vessels. The absence of lipoblasts and signs of malignancy in spite of a rapid growth rate is observed. It may also show hypertrophy of subjacent bone.<sup>[1,6,10]</sup> In all our cases, the histopathologic examination revealed adipocytes infiltrating the adjacent tissue and muscle planes, suggestive of infiltrating lipomatosis. Marrow space invasion by adipocytes was noticed in one case. A study evaluating the expression of angiogenic and vasculogenic factors has revealed that neovascularization does not seem to play a role in the pathogenesis of this condition.<sup>[3]</sup>

The treatment modalities available are liposuction and surgical excision. Treatment is primarily for esthetic reasons, and can vary as per the age of the patient and the rate of recurrence. Although the tumors are benign, the rate of recurrence is very high after surgical excision.<sup>[5,9]</sup> Though lipomatous degeneration may occur, there is no report of a frank malignancy.

Among our cases, case 1 and 2 had undergone complete surgical excision and case 3 is scheduled for a surgery. Case 4, being 5 years old, is kept on a regular follow-up. Recurrence was seen in three out of the four cases.

In conclusion, infiltrating lipomatosis of the face is a rare

benign condition with no age or gender predilection. It is characterized by diffuse infiltration of fat in the subcutaneous and muscle planes and bony hypertrophy. Clinical examination associated with especially MRI and CT helps in establishing the diagnosis. The condition has a high rate of recurrence with surgery done for cosmetic purpose.

## REFERENCES

1. Slavin SA, Baker DC, McCarthy JG, Muffarrij A. Congenital infiltrating lipomatosis of the face: Clinicopathological evaluation and treatment. *Plast Reconstr Surg* 1983;72:158-64.
2. Singh K, Sen P, Musgrove BT, Thicker N. Facial infiltrating lipomatosis: A case report and review of literature. *Int J Surg Case Rep* 2011;2:201-5.
3. Couto RA, Mulliken JB, Padwa BL, Hassanein AH, Rogers GF, Kulungowski AM, *et al.* Facial infiltrating lipomatosis: Expression of angiogenic and vasculogenic factors. *J Craniofac Surg* 2011;22:2405-8.
4. Rajeswaran R, Musthy J, Chandrasekharan A, Joseph S. Case report: Congenital infiltrating lipomatosis of face. *Indian J Radiol Imaging* 2008;18:306-9.
5. Heymans O, Ronsmans C. Congenital infiltrating lipomatosis of face. *Eur J Plast Surg* 2005;26:186-9.
6. Chen CM, Lo LJ, Wong HF. Congenital infiltrating lipomatosis of the face: Case report and literature review. *Chang Gung Med J* 2002;25:194-200.
7. Salvatore C, Antonio B, Vecchio WD, Lanza A, Tartaro G, Giuseppe C. Giant infiltrating Lipoma of the face: Ct and MR imaging findings. *AJNR Am J Neuroradiol* 2003;24:263-6.
8. Padwa BL, Mulliken JB. Facial infiltrating lipomatosis. *Plast Reconstr Surg* 2001;108:1544-54.
9. Coffin CM. Adipose and myxoid tumors. *Pediatric soft tissue tumors: A clinical, pathological, and therapeutic approach.* Baltimore: Williams and Wilkins Co; 1997. p. 245.
10. de Rosa G, Cozzolio A, Guarino M, Giardino C. Congenital infiltrating lipomatosis of the face: Report of cases and reviews of the literature. *J Oral Maxillofac Surg* 1987;45:879-83.
11. Mac Millan AR, Oliver AJ, Reade PC, Marshall DR. Regional macrodontia and regional bony enlargement associated with congenital infiltrating lipomatosis of the face presenting as unilateral facial hyperplasia. *Int J Oral Maxillofac Surg* 1990;19:263-6.
12. Donati L, Candiana P, Grappolini S, Klinger M, Siognorini M. Congenital infiltrating lipomatosis of the face relating to cytomegalovirus infection. *Br J Plast Surg* 1990;43:124-6.
13. Patel RV, Gondalino JS. Congenital infiltrating lipomatosis of the face. *Br J Plast Surg* 1991;44:157-8.
14. Kang N, Ross D, Harrison D. Unilateral hypertrophy of the face associated with infiltrating lipomatosis. *J Oral Maxillofac Surg* 1998;56:885-7.
15. Van Wingerden JJ, Erlank JD, Becher JH. Liposuction of congenital infiltrating lipomatosis of the face. *Plast Reconstr Surg* 1988;81:989.
16. Gorken C, Alper M, Bilkay U, Celik N, Songur E. Congenital infiltrating lipomatosis of the face. *J Craniofac Surg* 1999;10:365-8.
17. Boultaureau P, Breton P, Friedel M. Congenital infiltrating lipomatous of the face: Case report. *J Oral Maxillofac Surg* 2000;58:807-10.
18. Ergun SS, Kural S, Ulay M, Bilgic B. Infiltrating lipomatosis of the face. *Ann Plast Surg* 2001;47:346-8.
19. Unal S, Demikaran F, Arslan E, Cinel L. Infiltrating lipomatosis of the face: Case report and review of the literature. *J Oral Maxillofac Surg* 2003;61:1098-101.
20. Pires Fraga M, Mello D, Jorge D, Perin LF, Helen A. Congenital infiltrating lipomatosis. *J Plast Reconstr Aesthet Surg* 2009;62:e561-4.
21. Kamal D, Breton P, Boultaureau P. Congenital infiltrating lipomatosis of the face: Report of three cases and review of the literature. *J Craniomaxillofac Surg* 2010;38:310-4.

22. Kim JE, Gottschall JA, Bachman RP, Nemzer L, Puligandla B, Schauer G. Facial infiltrating lipomatosis: Physical, radiological, and histopathological findings. *Arch Otolaryngol Head Neck Surg* 2010;136:301-3.
23. Cappabianca S, Iscaro FM, Sirignano C, Cantarella R, Del Vecchio W, Grassi R, *et al.* The identification of the criteria of malignancy and the tissue characterization of expansive processes in periskeletal soft tissues: The current role of magnetic resonance. *Radiol Med* 1999;98:125-32.
24. Lachman RS, Finklestein J, Mehlinger CM, Maenza R. Congenital aggressive lipomatosis. *Skeletal Radiol* 1983;9:248-54.
25. Wylie EJ, Kendall B. Cranio-vertebral bony changes in a case of congenital lipomatosis. *Neuroradiology* 1989;31:352-3.
26. Sahai S, Rajan S, Singh N, Arora H. Congenital infiltrating lipomatosis of the face with exophytic temporomandibular joint ankylosis: Case report and view of the literature. *Dentomaxillofac Radiol* 2012. In Press.

**How to cite this article:** Urs AB, Augustine J, Kumar P, Arora S, Aggarwal N, Sultana N. Infiltrating lipomatosis of the face: A case series. *J Nat Sc Biol Med* 2013;4:252-7.

**Source of Support:** Nil. **Conflict of Interest:** None declared.

#### Access this article online

<b>Quick Response Code:</b>	<b>Website:</b> www.jnsbm.org
	<b>DOI:</b> 10.4103/0976-9668.107320