

Access this article online

Quick Response Code:



Website:
www.e-tjo.org

DOI:
10.4103/tjo.tjo_27_18

Megaloblastic anemia and bilateral disc edema: An enigma... Have we figured it out yet?

Harinder Singh Sethi, Mayuresh Naik*, Aastha Gandhi

Abstract:

A 28-year-old male presented with insidious-onset, painless, progressive diminution of vision in both eyes. He denied any other ocular symptoms. On examination, visual acuity in both eyes was 6/60. Color vision and contrast sensitivity were maintained in both eyes. Direct ophthalmoscopy revealed that the optic discs were bilaterally hyperemic and congested, with blurring of all the disc margins and loss of spontaneous venous pulsations. Besides this bilateral disc edema, rest of the clinical examination was normal. Primary intensive search for any intracranial space-occupying lesions returned negative on computed tomography scan imaging. Blood investigations revealed a hemoglobin level of 9.2 g/dl, leukocyte count of 7000 cells/mm³, and serum Vitamin B12 level of 155 pg/ml (200–835 pg/ml). Serum homocysteine and methylmalonic acid levels were done and were found to be elevated. After 4 weeks, visual acuity improved to 6/6 in both the eyes, and laboratory investigations showed no signs of Vitamin B12 deficiency. Nonsurgical causes for papilledema should be considered in the differential diagnosis. Early diagnosis and prompt treatment is the key to a good prognosis in Vitamin B12-deficient optic neuropathy, which has shown to have a good prognosis if treatment is initiated in the first few months after the onset of symptoms.

Keywords:

Bilateral disc edema, Megaloblastic anemia, anemic papilledema

Introduction

A wide variety of insults may lead to dysfunction or compression of the optic nerve, resulting in partial arrest of axoplasmic transport, manifested as disc edema. If the compression is caused by raised intracranial pressure (ICP), the condition is termed as papilledema. On the contrary, if the cause of disc edema is not increased ICP, the term disc edema is simply used.^[1] The common causes of bilateral disc edema include malignant hypertension, space-occupying lesion (benign or malignant), atypical meningitis, idiopathic intracranial hypertension, dural venous sinus thrombosis, atypical optic neuritis, systemic vasculitides (e.g. systemic lupus erythematosus and polyarteritis nodosa),

drug withdrawal (steroid and tetracycline), and pseudopapillitis, whereas the less common causes include anemia, leukemia, lead poisoning, and thyroid ophthalmopathy.

Case Report

A 28-year-old male presented with insidious-onset, painless, progressive diminution of vision in both eyes. He denied any other ocular symptoms. On examination, visual acuity in both eyes was 6/60. Color vision and contrast sensitivity were maintained in both eyes. Direct ophthalmoscopy revealed that the optic discs were bilaterally hyperemic and congested, with blurring of all the disc margins and loss of spontaneous venous pulsations [Figures 1-4]. Besides this bilateral disc edema, rest of the clinical examination was normal.

This is an open access journal, and articles are distributed under the terms of the Creative Commons Attribution-NonCommercial-ShareAlike 4.0 License, which allows others to remix, tweak, and build upon the work non-commercially, as long as appropriate credit is given and the new creations are licensed under the identical terms.

For reprints contact: reprints@medknow.com

How to cite this article: Sethi HS, Naik M, Gandhi A. Megaloblastic anemia and bilateral disc edema: An enigma... Have we figured it out yet?. Taiwan J Ophthalmol 2020;10:71-5.

Department of
Ophthalmology, V.M.M.C
and Safdarjung Hospital,
New Delhi, India

*Address for correspondence:

Dr. Mayuresh Naik,
Department of
Ophthalmology, V.M.M.C
and Safdarjung Hospital,
Ring Road, Ansari Nagar,
New Delhi - 110 029, India.
E-mail: mayureshpnaik@
gmail.com

Submission: 14-04-2018
Accepted: 13-12-2018
Published: 04-03-2020




Figure 1: Humphrey's Visual Field Analyzer report of 30-2 SITA fast testing strategy to show the enlargement of blind spot and resolution on treatment in the left eye




Figure 2: Humphrey's Visual Field Analyzer report of 30-2 SITA fast testing strategy to show the enlargement of blind spot and resolution on treatment in the right eye

His past medical and surgical histories were unremarkable. He was a nonalcoholic, nonsmoker, strict vegetarian by diet, and admitted to having a limited intake of milk and yogurt.

Primary intensive search for any intracranial space-occupying lesions returned negative on computed tomography (CT) scan imaging.

Blood investigations revealed a hemoglobin level of 9.2 g/dl, leukocyte count of 7000 cells/mm³, and serum Vitamin B12 level of 155 pg/ml (200–835 pg/ml), with a mean corpuscular volume (MCV) of 122.8 fl (78–100 fl), mean corpuscular hemoglobin (MCH) of 31 pg (27–33 pg), and MCH concentration of 34 g/dl (33–37 g/dl). Serum folic acid level was 6 ng/ml (2.5–18 ng/ml).

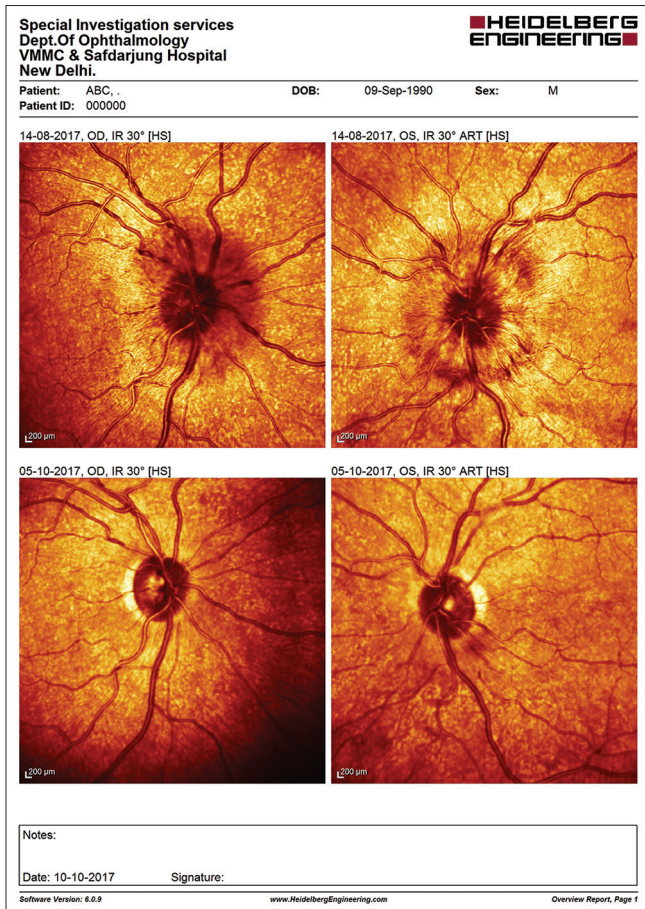


Figure 3: Fundus photograph showing bilateral disc edema and resolution following treatment with Vitamin B12

Peripheral blood smear showed the presence of macrocytic, oval red blood cells that lacked the central pallor of normal red cells, along with the presence of intense anisocytosis and poikilocytosis and macropolymorphonuclear, hypersegmented neutrophils. Promegaloblasts, giant metamyelocytes, and abnormally large megakaryocytes with bizarre, multilobate nuclei were seen, suggesting dysmaturation in the erythroid and myeloid series.

Serum homocysteine and methylmalonic acid levels were done which were found to be elevated. Thyroid function tests were unremarkable, and endomysial and gliadin-related antibodies were negative. Nerve conduction studies were also within normal limits.

A diagnosis of Vitamin B12 deficiency-induced bilateral disc edema was subsequently made, and the patient was commenced on intramuscular Vitamin B12 supplementation of 1000 µg daily for 5 days followed by 1000 µg weekly for 4 weeks and a maintenance therapy of 1000 µg every month, along with an advice to incorporate dietary food items such as milk and curd in his diet. After 4 weeks, visual acuity improved to 6/6 in both the eyes, and laboratory investigations showed no signs of Vitamin B12 deficiency. The patient is on regular follow-up.

Discussion

Anemia is defined as^[2] reduction of the total circulating red cell mass below the normal limits. It can be classified

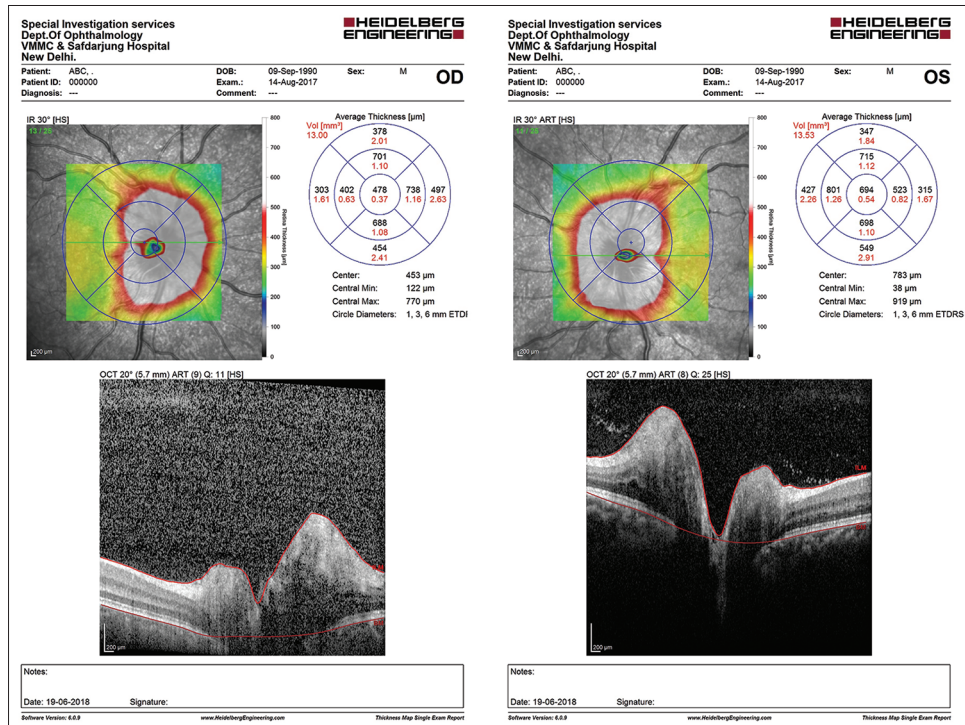


Figure 4: Optical coherence tomography section through the disc demonstrating the peripapillary edema

into the following three types on the basis of the underlying mechanism: anemias of blood loss, which are mainly due to the loss of intravascular volume; hemolytic anemias, which are characterized by the premature destruction of red cells and a shortened red cell lifespan along with elevated erythropoietin levels and a compensatory increase in erythropoiesis; and anemias of diminished erythropoiesis, which stem from the inadequate production of red cells.

Metabolic optic neuropathies manifest as^[3] anemias of diminished erythropoiesis and are characterized by bilaterally symmetrical visual impairment with loss of central visual acuity, dyschromatopsia, centrocecal visual-field defects, temporal optic disc atrophy, and specific loss of the nerve fiber layer in the papillomacular bundle. The three subcategories of metabolic optic neuropathies are hereditary (such as Leber's hereditary optic neuropathy), nutritional deficiencies (such as Vitamin B12 or folic acid), or toxicities (such as ethambutol or cyanide). It is interesting to note that the first of these three is a congenital cause of mitochondrial impairment, whereas the latter two are acquired injuries to mitochondria. Hence, most, if not all, causes of metabolic optic neuropathies are, in fact, related to mitochondrial impairment. At present, there is no effective treatment for hereditary optic neuropathy. Nutritional-deficiency metabolic optic neuropathies are treated by giving supplements of the appropriate nutrient or vitamin, whereas toxic metabolic optic neuropathies are treated by removing or preventing exposure to the toxin in question.^[4]

Vitamin B12-deficient optic neuropathy is uncommonly rare, and early recognition and treatment are important to prevent persistent visual defects.^[4] It is usually associated with causes of decreased intake such as inadequate diet and vegetarianism or impaired absorption due to intrinsic factor deficiency as in pernicious anemia and postgastrectomy, malabsorption states, post ileal resection or ileitis due to any cause, diffuse intestinal disease such as lymphoma, systemic sclerosis, bacterial overgrowth in blind loops, and diverticula of the bowel.

Nguyen *et al.* reported a case of anemic papilledema in a 14-year-old male patient of Crohn's disease being treated with 6-mercaptopurine, mesalamine, and Vitamin D supplements. They postulated that the patient's severe anemia may have precipitated the elevated ICP, causing his symptoms, and recovered on treatment of the increased ICP with oral acetazolamide.^[5] They also reported another case of a 16-year-old female patient diagnosed with leukemia and on intravenous all-transretinoic acid, daunorubicin, and cytarabine (Ara-C). Acetazolamide did not lead to any

improvement in the patient's condition. She urgently underwent a course of palliative craniospinal radiation therapy which led to an improvement in her papilledema with ongoing resolution of nerve hemorrhages and macular exudates. The patient continued taking acetazolamide until her papilledema resolved. Color plates continued to be decreased bilaterally but were stable compared with prior examinations.^[5] Similarly, Biousse *et al.* reported six cases who had bilateral papilledema secondary to iron-deficiency anemia and showed dramatic improvement in signs and symptoms after correction of anemia, obviating the need for acetazolamide.^[6] In contrast, Mangat reported a case of bilateral disc edema (normal brain magnetic resonance imaging, normal cerebrospinal fluid, and normal ICP) in a patient of iron-deficiency anemia who responded well to the management of anemia *per se*.^[7] Schwaber and Blumberg documented a case of papilledema secondary to blood loss anemia which was again completely reversed by blood transfusion.^[8] Foroozan observed a case of unilateral pallid optic disc edema in a patient receiving polyethylene glycol-interferon-alpha (PEG-IFN- α) and ribavirin for hepatitis C and later developed iron-deficiency anemia. Since she resolved after being treated with intravenous dexamethasone and oral iron sulfate, the attribution of the disc edema to the anemia was confounded by the fact that she had received PEG-IFN- α , which in itself had been reported to cause papilledema.^[9] Gupta *et al.* observed a case of aplastic anemia-induced disc edema and visual loss in pregnancy who later resolved with red blood cell and platelet transfusions.^[10]

The most striking attribute to our patient was the fact that he had absolutely neither symptoms nor any hematological nor neurological signs of Vitamin B12 deficiency other than the visual deterioration. Such an unusual presentation is not only rare, but has also not yet been reported in literature.

Cyanocobalamin mediates two important enzymatic reactions in humans.^[11] The first is the conversion of methylmalonyl-coenzyme A to succinyl-coenzyme A and the second is the conversion of homocysteine to methionine. Deficiency of cyanocobalamin thus leads to the accumulation of methylmalonyl-CoA and homocysteine in the serum and these can be used as surrogate markers of Vitamin B12 deficiency.

The exact mechanism of neurological damage in B12 deficiency is still not fully elucidated. Impaired methionine synthesis may lead to the depletion of S-adenosylmethionine which is required for the synthesis of myelin phospholipids. The second hypothesis is that the generation of odd-chained fatty acids, resulting from a deficit of succinyl-CoA, may get incorporated into

the myelin, resulting in the neurological syndrome of Vitamin B12 deficiency.

The Schilling test is used to elucidate the cause of Vitamin B12 deficiency. Patients undergoing Schilling test are given an oral load of Vitamin B12. Hence, if the patient's diet is lacking in Vitamin B12, for example, in veganism, Stage I should produce a normal result. This indicates dietary deficiency in Vitamin B12. If Stage I is abnormal, this shows malabsorption of Vitamin B12. Thus, Stage II is performed to check for gastric pernicious anemia. The result should be normal since the patient is given a dose of Vitamin B12 along with an intrinsic factor which solves the lack in the production of intrinsic factor by the stomach linings. If both Stages I and II of the test are abnormal, it shows that the lack of intrinsic factor is not the cause for the deficiency and the patient does not have classical pernicious anemia or gastric defects. This points to an intestinal cause. Stage III of the test is then carried out, and Stage II is repeated with antibiotics. The antibiotics target and reduce the amount of bacteria in the intestines. If absorption of Vitamin B12 returns to normal after Stage III, it shows that reducing bacterial amounts in the intestines has resolved the deficiency; bacterial overgrowth in the intestines was the cause. However, if results of all Stages I, II, and III are abnormal, Stage IV is done. In Stage IV, the patient will be given pancreatic enzymes for 3 days followed by the radioactive Vitamin B12 to test for pancreatic disorders. A variation of the standard Schilling test is the dual-isotope (or "single stage") Schilling test, which combines Stage I and Stage II tests. However, use of this test has been discouraged because of a high rate of indeterminate results compared with the standard protocol.^[12]

Thus, shunt placement and operative intervention are not always mandated in the treatment of papilledema. Nonsurgical causes for papilledema should be considered in the differential diagnosis. Early diagnosis and prompt treatment is the key to a good prognosis in Vitamin B12-deficient optic neuropathy, which has shown to have a good prognosis if treatment is initiated in the first few months after the onset of symptoms. Patients should be observed initially every 4–6 weeks and then, depending on their recovery, every 6–12 months. At each visit, the patient's visual acuity, color vision, visual fields, pupils, and optic nerves should be assessed. Lack of compliance with therapy may lead to profound bilateral visual loss but never total blindness. Unless the loss of vision is already far advanced, the prospect for recovery or at least improvement is excellent, except for the most chronic cases. The rate of recovery varies from a few weeks to several months.

Conclusion

Early diagnosis and prompt treatment is the key to a good prognosis in Vitamin B12-deficient disc edema, which has shown to have a good prognosis if treatment is initiated on time. Patients should be observed initially every 4–6 weeks and then, depending on their recovery, every 6–12 months.

Informed consent

Informed consent was obtained from the patient. The authors certify that they have obtained all appropriate patient consent forms. In the form, the patient had given his consent for his images and other clinical information to be reported in the journal. The patient understands that his name and initials will not be published and due efforts will be made to conceal his identity, but anonymity cannot be guaranteed.

Financial support and sponsorship

Nil.

Conflicts of interest

The authors declare that there are no conflicts of interests.

References

1. Sadun A, Gurkan S, Patel V. Hereditary, nutritional, and toxic optic atrophies. In: Yanoff M, Duker J, editors. *Ophthalmology*. Vol. 3. Edinburgh: Mosby Elsevier; 2008. p. 321-427.
2. Kumar V, Abbas AK, Aster JC. Diseases of white blood cells, lymph nodes, spleen, and thymus. In: *Robbins and Cotran Pathologic Basis of Disease*. Vol. 9. Philadelphia, PA: Elsevier/Saunders; 2015. p. 1415-25.
3. Sadun AA. Metabolic optic neuropathies. *Semin Ophthalmol* 2002;17:29-32.
4. de Silva P, Jayamanne G, Bolton R. Folic acid deficiency optic neuropathy: A case report. *J Med Case Rep* 2008;2:299.
5. Nguyen HS, Haider KM, Ackerman LL. Unusual causes of papilledema: Two illustrative cases. *Surg Neurol Int* 2013;4:60.
6. Biousse V, Rucker JC, Vignal C, Crassard I, Katz BJ, Newman NJ, *et al*. Anemia and papilledema. *Am J Ophthalmol* 2003;135:437-46.
7. Mangat SS. Papilledema due to iron-deficiency anemia. *Philipp J Ophthalmol* 2010;35:76-8.
8. Schwaber JR, Blumberg AG. Papilledema associated with blood loss anemia. *Ann Intern Med* 1961;55:1004-7.
9. Foroozan R. Unilateral pallid optic disc swelling and anemia associated with interferon alpha treatment. *J Neuroophthalmol* 2004;24:98-9.
10. Gupta SK, Brar VS, Keshavamurthy R, Chalam KV. Aplastic anemia induced disc edema and visual loss in pregnancy: A case report. *Cases J* 2008;1:322.
11. Sethi N, Robilotti E, Sadan Y. Neurological manifestations of Vitamin B-12 deficiency. *Internet J Nutr Wellness* 2004;2:1.
12. Snow CF. Laboratory diagnosis of Vitamin B12 and folate deficiency: A guide for the primary care physician. *Arch Intern Med* 1999;159:1289-98.