



Since January 2020 Elsevier has created a COVID-19 resource centre with free information in English and Mandarin on the novel coronavirus COVID-19. The COVID-19 resource centre is hosted on Elsevier Connect, the company's public news and information website.

Elsevier hereby grants permission to make all its COVID-19-related research that is available on the COVID-19 resource centre - including this research content - immediately available in PubMed Central and other publicly funded repositories, such as the WHO COVID database with rights for unrestricted research re-use and analyses in any form or by any means with acknowledgement of the original source. These permissions are granted for free by Elsevier for as long as the COVID-19 resource centre remains active.

## Parkinsonism with akinetic mutism following osmotic demyelination syndrome in a SARS-CoV-2 infected elderly diabetic woman: A case report



## Parkinsonismo con mutismo aquinético tras síndrome de desmielinización osmótica en una mujer anciana diabética infectada por el SARS-CoV-2

Dear Editor:

Neurological manifestations of severe acute respiratory syndrome coronavirus 2 (SARS-CoV-2) are being widely documented.<sup>1</sup> However, *de novo* movement disorders are scantily reported in COVID-19.<sup>2</sup> Apart from neurological manifestations, SARS-CoV-2 infection can make a previously euglycemic person vulnerable to develop either transient or permanent hyperglycemia.<sup>3,4</sup>

Osmotic demyelination syndrome (ODS), formerly called central pontine myelinolysis, is a serious neurological emergency, which arises from rapid changes in osmotic equilibrium in susceptible neuronal cells, especially oligodendrocytes.<sup>5</sup> However, due to advancement in neuroimaging and our understanding of the pathophysiological processes underlying ODS, more cases of extra-pontine myelinolysis (EPM) are being reported.<sup>3</sup> Among the complications of ODS, parkinsonism has been rarely reported.<sup>6,7</sup>

ODS occurs classically as a complication of the rapid correction of hyponatremia<sup>3</sup>; however, it has been rarely associated with other entities, such as hyperglycemic hyperosmolar state (HHS).<sup>8,9</sup>

We hereby report a case of an elderly diabetic woman with parkinsonism with akinetic mutism following non-dyselectrolytic ODS, which was precipitated by COVID-19 induced HHS.

An elderly Indian woman aged 65 years with adequately controlled type-2 diabetes mellitus (T2DM) presented to the emergency department with fever, body-ache and dry cough for the last 5 days. She was diagnosed to have SARS-CoV-2 infection in the emergency department. Complete blood cell count revealed neutrophilic leukocytosis with neutrophil to lymphocyte ratio of 3; erythrocyte sedimentation rate, C-reactive protein, ferritin, lactate dehydrogenase and hepatic transaminases were raised. Serum electrolytes, blood glucose levels (pre and post-prandial), hemoglobin-A1c, ketones, D-dimer, interleukin-6, cardiac troponins, and thyroid and renal function tests were within normal range. A high-resolution computerized tomography scan of the thorax revealed a severity score of 8/25. She was prescribed inhalational budesonide, oral dexamethasone, doxycycline, ivermectin, antipyretics and subcutaneous basal-bolus insulin regimen. On day 4, she had bouts of unprovoked vomiting and became drowsy. Bedside random capillary blood glucose (CBG) measurement revealed high glucose levels (652 mg/dl). Arterial blood gas analysis revealed no dyselectrolytemia or acid-

base imbalances. Serum osmolarity was 317 mOsm/kg with normal lactate levels. After 48 h of stringent management and monitoring, she was still apathetic and responding rarely and incompletely to commands with long latency and became noticeably sluggish. A neurological examination revealed generalized bradykinesia, hypomimia, monotone and monosyllable incoherent speech, axial and symmetrical appendicular rigidity (MDS-UPDRS score of 60), and akinetic mutism. She had no other neurological deficits.

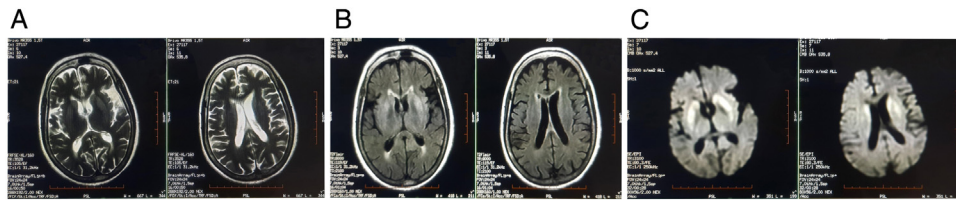
She had no history of addiction and no family history of any neurological disorders. Brain MRI revealed symmetrical hyperintense signals in T2-weighted imaging, T2-FLAIR and DWI over bilateral caudate nucleus and putamen (Fig. 1). Clinical–radiological differential diagnoses that were considered are shown in Table 1. Eventually, she was diagnosed to be a case of an extrapontine variant of osmotic demyelination syndrome (ODS) due to HHS, which was precipitated by COVID-19, that in turn had been treated with dexamethasone.

She was put on levodopa/carbidopa (initially started at 25/6.25 mg 4 times a day and gradually up titrated to 100/25 mg 5 times a day) and pramipexole (1.5 mg/day). After 2 months of follow-up, her features of parkinsonism improved significantly (MDS-UPDRS score of 60 to 20), but with only mild improvement of the features associated with akinetic mutism. Pramipexole was up titrated to 3 mg/day and sertraline (100 mg/day) was added. Throughout her hospital stay, her minimum serum sodium (corrected for hyperglycemia) was 136 mEq/L and maximum was 142 mEq/L. The change in serum sodium was closely monitored and never crossed >5 mEq/L. After another 2 months of follow-up, her mutism also improved significantly and she is currently continuing the same regimen along with drugs and lifestyle modifications for T2DM.

We have described a case of parkinsonism with akinetic mutism associated with the worsening of glycemic control in an elderly diabetic woman suffering from SARS-CoV-2 infection. An event-by-event discussion will aid us in dissecting the pathophysiology of this case.

Firstly, the loss of glycemic control might either be because of corticosteroid therapy, COVID-19 infection itself or lack of physical activity.<sup>3,4</sup>

Secondly, the ODS results from maladaptive stress due to rapid change in the osmotic milieu within the neurons, possibly due to disruption of blood–brain barrier, exposure of glial cells to activated complements and cytokines, which in combination eventually lead to axonal shear injury, cellular energy depletion and apoptosis.<sup>5</sup> However, some researchers attribute this to an osmotic disequilibrium-related endothelial damage and the subsequent release of inflammatory mediators from the injured endothelial cells.<sup>8,10</sup> Rapidly developing HHS is a rare, although documented, risk factor of ODS.<sup>8,9</sup> It is highly plausible that in our patient, HHS developed rapidly enough that oligodendrocytes could not adapt. Interestingly, all the previously mentioned pathogenetic mechanisms (i.e. endothelial damage, disruption of blood–brain barrier, cytokine-mediated cellular injury, etc.) leading to ODS can also occur in COVID-19 itself,<sup>11,12</sup> and this raises the question whether the SARS-CoV-2 infection itself is capable of causing ODS. However,



**Figure 1** Brain MRI revealing symmetrical altered intensity lesions, hyperintense in axial T2WI (A), axial T2-FLAIR (B), axial-DWI (C) sequences, over bilateral caudate nucleus and putamen, sparing the globus pallidus.

**Table 1** Clinical–radiological differential diagnoses of the case.

Differential diagnoses	Odds in this case
Diabetic striatopathy	Should have resolved with swift and sustained control of blood glucose No corresponding T1-WI hyperintense signal changes over striatum Usually, diabetic striatopathy presents with hyperkinetic movement disorders
Sporadic Creutzfeldt-Jakob disease	No pyramidal features No rapidly progressive dementia Hyperacute course No myoclonus No visual cognitive deficits No cerebellar dysfunctions EEG not suggestive of periodic sharp wave complexes No typical cortical/gyral ribbon pattern or pulvinar sign on DWI
Metabolic encephalopathy	No improvement even with prompt correction of hyperglycemia Never had any hypoglycemic episode No episode of dyselectrolytemia Hepatic functions including albumin, prothrombin time and international normalized ratio were normal. There was only mild elevation of levels of transaminase. Serum ammonia levels were normal.
Hypoxic encephalopathy	No myoclonus, tremor and asterixis were noted. Patient was on continuous monitoring and never had an episode of hypoxemia/hypoxia.
Wernicke's encephalopathy	No myoclonus. Hyperacute course No ataxia, ophthalmoplegia and peripheral neuropathy Normal serum thiamine level No background risk factor for development of Wernicke's encephalopathy Periaqueductal grey and mammillary bodies were spared Repletion of thiamine had no effect
Autoimmune encephalitis involving basal ganglia (anti-D2, Anti-CRMP5)	CSF study was normal Clinical history did not fit with the course of autoimmune encephalitis Negative antibody tests on CSF as well as serum for autoimmune encephalitis profile
COVID-19 induced encephalitis involving bilateral basal ganglia	Normal CSF parameters. No mass effect on neuroimaging. No other area of brain, e.g. thalamus, temporal/parietal lobes, inferior frontal gyrus, external capsule, etc. was involved.

we feel that in our patient was due to the rapid surge in plasma glucose and thereby plasma osmolarity.

Thirdly, what caused parkinsonism with akinetic mutism? There are three possibilities. The uncontrolled hyperglycemic state is established as a cause of potentially reversible *de novo* movement disorders (diabetic striatopathy).<sup>13,14</sup> Besides, the EPM variant of ODS is particularly known for its predilection to give rise to *de novo* movement disorders because of the involvement of the crucial striato-thalamo-cortical networks.<sup>6,7</sup> Furthermore, SARS-CoV-2 infection itself can give rise to this type of movement disorder.<sup>2</sup>

Finally, the question is whether the neuroimaging findings can be the result of COVID-19 encephalitis/encephalopathy or autoimmune basal ganglia-encephalitis, triggered by SARS-CoV-2 infection. Basal ganglia involvement in COVID-19 encephalitis and COVID-19 related autoimmune encephalitis have been documented.<sup>2,15</sup> Normal CSF study and negative autoimmune encephalitis panel in both CSF and serum pointed towards the diagnosis of ODS over viral/immune encephalitis. Besides, the onset of the disease with acute rapid deterioration of blood glucose control and the HHS further strengthened the argument in favor of ODS.

In closing, both COVID-19 and dexamethasone worsened the glycemic control of this previously well-controlled diabetic elderly woman further leading to the development of non-dyselectrolytemic ODS. This ODS alone or perhaps, in conjunction with SARS-CoV-2 infection itself, led to akinetic mutism and parkinsonism, which responded to treatment.

## Funding

This study was not funded.

## Author contributions

All authors contributed significantly to the creation of this manuscript; each fulfilled criteria as established by the ICMJE.

## Conflict of interest

The authors declare that they have no conflict of interest.

## References

- Roy D, Ghosh R, Dubey S, Dubey MJ, Benito-Leon J, Kanti Ray B. Neurological and neuropsychiatric impacts of COVID-19 pandemic. *Can J Neurol Sci.* 2020;1–16.
- Ghosh R, Biswas U, Roy D, Pandit A, Lahiri D, Ray BK, et al. De novo movement disorders and COVID-19: exploring the interface. *Mov Disord Clin Pract.* 2021;8:669–80.
- Ghosh R, Dubey S, Roy D, Ray A, Pandit A, Ray BK, et al. Choreo-ballistic movements heralding COVID-19 induced diabetic ketoacidosis. *Diabetes Metab Syndr: Clin Res Rev.* 2021.
- Chatterjee S, Ghosh R, Biswas P, Dubey S, Guria RT, Sharma CB< ET-AL>. COVID-19: the endocrine opportunity in a pandemic. *Minerva Endocrinol.* 2020;45:204–27.
- King JD, Rosner MH. Osmotic demyelination syndrome. *Am J Med Sci.* 2010;339:561–7.
- Tan AH, Lim SY, Ng RX. Osmotic demyelination syndrome with evolving movement disorders. *JAMA Neurol.* 2018;75:888–9.
- de Souza A. Movement disorders and the osmotic demyelination syndrome. *Parkinsonism Rel Disord.* 2013;19:709–16.
- Rodríguez-Velver KV, Soto-García AJ, Zapata-Rivera MA, Montes-Villarreal J, Villarreal-Pérez JZ, Rodríguez-Gutiérrez R. Osmotic demyelination syndrome as the initial manifestation of a hyperosmolar hyperglycemic state. *Case Rep Neurol Med.* 2014;2014:652523.
- Hirosawa T, Shimizu T. Osmotic demyelination syndrome due to hyperosmolar hyperglycemia. *Cleve Clin J Med.* 2018;85:511–3.
- Alleman AM. Osmotic demyelination syndrome: central pontine myelinolysis and extrapontine myelinolysis. *Semin Ultrasound CT MR.* 2014;35:153–9.
- Alquisiras-Burgos I, Peralta-Arrieta I, Alonso-Palomares LA, Zacapala-Gómez AE, Salmerón-Bárceñas EG, Aguilera P. Neurological complications associated with the blood–brain barrier damage induced by the inflammatory response during SARS-CoV-2 infection. *Mol Neurobiol.* 2021;58:520–35.
- Varga Z, Flammer AJ, Steiger P, Haberecker M, Andermatt R, Zinkernagel AS, et al. Endothelial cell infection and endothelitis in COVID-19. *Lancet.* 2020;395:1417–8.
- Chua CB, Sun CK, Hsu CW, Tai YC, Liang CY, Tsai IT. “Diabetic striatopathy”: clinical presentations, controversy, pathogenesis, treatments, and outcomes. *Scient Rep.* 2020;10:1594.
- Ghosh R, Roy D, Chatterjee S, Dubey S, Swaika BC, Mandal A, et al. Hemifacial spasm as the presenting manifestation of type 3c diabetes mellitus. *Tremor Other Hyperkinet Mov (N Y).* 2021;11:14.
- Pizzanelli C, Milano C, Canovetti S, Tagliaferri E, Turco F, Verdenelli S< ET-AL>. Autoimmune limbic encephalitis related to SARS-CoV-2 infection: case-report and review of the literature. *Brain Behav Immun Health.* 2021;12:100210.

R. Ghosh<sup>a</sup>, A. Ray<sup>b</sup>, D. Roy<sup>c,d</sup>, S. Das<sup>e</sup>, S. Dubey<sup>e</sup>, J. Benito-León<sup>f,g,h,\*</sup>

<sup>a</sup> Department of General Medicine, Burdwan Medical College & Hospital, Burdwan, West Bengal, India

<sup>b</sup> Department of General Medicine, R G Kar Medical College and Hospital, Kolkata, West Bengal, India

<sup>c</sup> Department of Biochemistry, All India Institute of Medical Sciences (AIIMS), Jodhpur, Rajasthan, India

<sup>d</sup> Indian Institute of Technology (IIT), Madras, Tamil Nadu, India

<sup>e</sup> Department of Neuromedicine, Bangur Institute of Neurosciences, Institute of Postgraduate Medical Education and Research & SSKM Hospital, Kolkata, West Bengal, India

<sup>f</sup> Department of Neurology, University Hospital “12 de Octubre”, Madrid, Spain

<sup>g</sup> Centro de Investigación Biomédica en Red sobre Enfermedades Neurodegenerativas (CIBERNED), Madrid, Spain

<sup>h</sup> Department of Medicine, Complutense University, Madrid, Spain

\* Corresponding author.

E-mail address: [jbenito67@gmail.com](mailto:jbenito67@gmail.com) (J. Benito-León).

<https://doi.org/10.1016/j.nrl.2021.09.007>

0213-4853/ © 2021 Sociedad Española de Neurología. Published by Elsevier España, S.L.U. This is an open access article under the CC BY-NC-ND license (<http://creativecommons.org/licenses/by-nc-nd/4.0/>).