



Pregnancy-unrelated fibroadenoma in ectopic breast tissue in the axilla and vulva: A case report

Adrian L. Hernandez Lopez^{a,*}, Shila Manandhar^b, Lorrie Dubow^a

^a Department of Obstetrics and Gynecology, Kaiser Permanente Southern California, Los Angeles Medical Center, 4900 Sunset Boulevard 5th Floor, Los Angeles, CA 90027, USA

^b Department of Obstetrics and Gynecology, Kaiser Permanente Northern California, San Rafael Medical Center, 99 Montecillo Rd, San Rafael, CA 94903, USA

ARTICLE INFO

Article history:

Received 19 August 2020

Received in revised form 25 August 2020

Accepted 27 August 2020

Available online xxxx

Keywords:

Ectopic breast tissue

Fibroadenoma

Vulvar disease

Embryonic milk lines

ABSTRACT

Although ectopic breast tissue is rare in the general population, it is important to consider when investigating an axillary or vulvar mass. Ectopic breast tissue most commonly occurs postpartum but is not exclusive to that period. We report the case of a 29-year-old woman with ectopic breast tissue in multiple sites, including the axilla and vulva. The patient initially presented with a painless right axillary mass; it was excised and diagnosed as a fibroadenoma. She was then diagnosed with fibroadenoma of the vulva four years later. While ectopic breast tissue is most commonly found in the postpartum period it can occur outside of pregnancy. Therefore it should be included in the differential diagnoses for axillary or vulvar masses. Additionally, it is important to monitor women with ectopic breast tissue, particularly in the vulva, for recurrence.

© 2020 The Authors. Published by Elsevier B.V. This is an open access article under the CC BY-NC-ND license (<http://creativecommons.org/licenses/by-nc-nd/4.0/>).

1. Introduction

Ectopic breast tissue is a rare condition. It is due to the development of mammary tissue along the milk line which fails to regress during embryologic development, leading to breast tissue separate from normally situated pectoral breasts [1]. The axilla and the vulva are the most common sites of ectopic breast tissue. Ectopic breast tissue in the vulva is extremely rare, with fewer than 50 cases reported in the literature [2,3]. Additionally, very few cases of vulvar fibroadenomas have been reported [4].

The epidemiology of ectopic breast tissue is poorly understood. Although it has been described in people aged 18 to 84 years, it is unclear whether there is an ethnic predisposition to ectopic breast tissue as the majority of the case reports do not comment on the ethnic background of the affected individuals.

The presentation of ectopic breast tissue depends on the level of breast tissue developed and its functionality. Because ectopic tissue is hormone-sensitive it tends to manifest during or shortly after pregnancy in response to elevated estrogen, progesterone, and prolactin. There have even been case reports of vulvar ectopic breast tissue presenting with lactogenesis [4,5]. Although there are very few cases reports of lesions developing outside of pregnancy, these have included the postmenopausal period [3]. Most often, ectopic breast tissue in the vulva is composed of adipose tissue, making it easily mistaken for a

lipoma [3]. Fibroadenoma regardless of the location is diagnosed histologically as the presence of nodular, fibro-glandular breast tissue in a background of normal tissue.

Although the diagnosis is ultimately made with histologic confirmation, certain clinical characteristics such as the timing of mass enlargement and lactogenesis are important clues [5]. This is especially relevant when investigating a newly diagnosed vulvar mass for malignancy. Lev-Cohain et al. 2013 have proposed that heterogeneous high signal intensity of a rapidly enlarging, well-encapsulated mass on T2-weighted magnetic resonance images can be suggestive of lactating fibroadenoma in the vulvar region with the appropriate clinical picture.

Ectopic breast tissue is known to be hormonally responsive and can develop benign mammary characteristics such as fibrocystic changes and fibroadenoma. However, it can also develop malignant changes such as phyllodes, lobular, ductal, and mucinous adenocarcinoma [6,7]. Therefore, although management guidelines are lacking and some patients have been treated expectantly with a resolution of symptoms, the general approach has been to resect these lesions completely to detect or prevent malignancy [5,8].

2. Case Presentation

A 29-year-old African American woman, G1P0101, initially presented to her provider for a palpable and visible right axillary mass first noticed four months previously which had been progressively growing. On physical examination, it was soft, mobile, discrete, nontender, and without associated lymphadenopathy. Mammography

* Corresponding author.

E-mail addresses: Adrian.l.hernandez-lopez@kp.org (A.L. Hernandez Lopez), Shila.manandhar@kp.org (S. Manandhar), Lorrie.x.dubow@kp.org (L. Dubow).

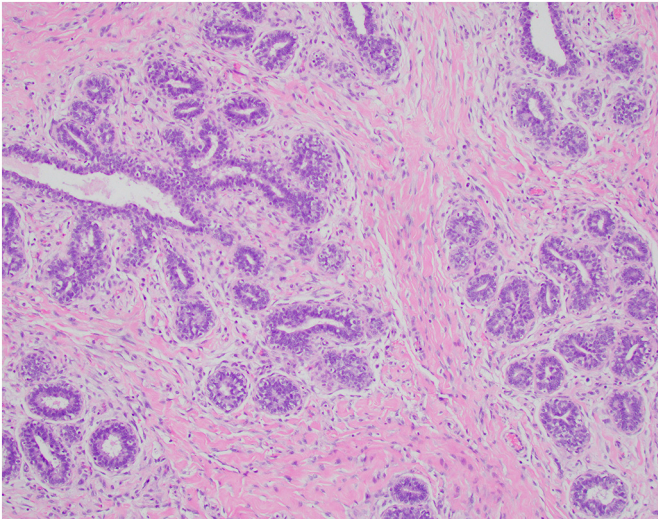


Fig. 1. Fibroadenoma is a histological diagnosis characterized by an overgrowth of nodular, fibro-glandular breast tissue in a background of normal tissue.

showed a 2.5 cm oval mass with circumscribed margins. An ultrasound scan showed it to be hypoechoic and suggested a differential diagnosis of an enlarged lymph node. The patient then underwent excision of the axillary mass. The final pathologic diagnosis was of fibroadenoma and fibrocystic changes of cysts, stromal fibrosis, and apocrine metaplasia (Fig. 1).

Four years later the patient presented to her obstetrician with a painless left vulvar mass (Fig. 2). She had had no other pregnancies in the interim. On examination, the left labia majora was noted to be enlarged to 10 cm with a spongiform-like consistency but without other abnormalities. The patient underwent excision of the mass with less



Fig. 2. Painless left vulvar mass encompassing the left labia majora which was noted to be enlarged to 10 cm with a spongiform like consistency. No galactorrhea or polythelia was noted; lubrication jelly was used during the examination.

than 1 cm margins. The final pathology was consistent with a 7.2 cm fibroadenoma with clear margins. The patient was seen three weeks later and was noted to be healing well with minimal incisional pain.

Six months later the patient complained of a painless right vulvar mass which she noted had started three months prior. She denied any discharge, burning, or pruritus. On examination the right vulva was fluctuant with an approximately 2 cm firm nodule superiorly and a smaller 1 cm nodule midway down the vulva. The left vulvar mass excision site was noted to be well healed. The patient underwent excision with less than 1 cm margins of the right vulvar mass. The final pathology showed a 1.1 cm fibroadenoma with surrounding fibroglandular breast tissue. She was then seen two months later without complaints and with the physical examination showing a well-healed incision site (Fig. 3). Subsequently, a vaginal examination several months later revealed a well-healed vulva without lesions.

3. Discussion

While the differential diagnosis for a vulvar mass is wide, it is important to consider ectopic breast tissue as a potential etiology. Ectopic breast tissue can occur anywhere along the primitive embryonic milk lines, which extends from the axilla to the groin [1,9]. However, ectopic breast tissue of the vulva is extremely rare. Previous case reports have described lactating adenomas, bilateral ectopic breast tissue of the vulva in pregnancy, postpartum unilateral ectopic breast tissue without milk excretion, and primary adenocarcinoma [4,5,10]. The majority of cases reported in the literature involve patients either during pregnancy or shortly after delivery. Our case highlights the possibility of ectopic breast tissue occurring outside of the intrapartum or postpartum period. Although the origin of ectopic breast tissue is still disputed, the presence of benign breast tissue surrounding these lesions supports the diagnosis of ectopic breast tissue origin as opposed to anogenital mammary-like gland origin [9].

Imaging modalities to investigate a vulvar mass have been previously reported [4,11]. While MRI can provide the best soft-tissue resolution, ultrasound can also be used in the evaluation to some extent. Although ectopic breast tissue of the vulva is rare and the exact malignant potential of ectopic breast tissue within the vulva is not known, the possibility of primary carcinoma arising from ectopic breast tissue

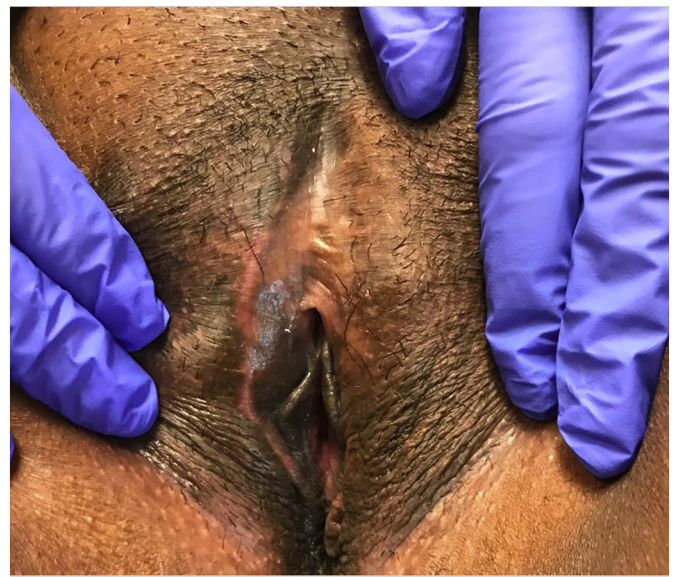

Fig. 3. Right vulva with incision well healed where there was previously a 2 cm firm nodule superiorly and a smaller 1 cm nodule midway down the vulva. The left vulvar mass excision site was also noted to be well healed.

should be considered in the differential diagnosis of vulvar carcinoma [9,10]. The decision to take a punch biopsy before the excision of a vulvar mass should also be considered. A biopsy would be less invasive, although there may be sampling and interpretation errors [12]. Given the soft, spongiform, and benign-appearing nature of the lesions in our patient, the decision was made to excise them with margins less than 1 cm. However, care should still be taken to obtain clear margins given the same potential for malignancy as normal breast tissue.

In the era of whole-genome and transcriptome sequencing, ectopic breast tissue may now be diagnosed more frequently during the investigation of vulvar masses. Grewal et al. 2019 were able to use the genomic characterization of a mammary-like adenocarcinoma to lead to targeted HER2+ treatment for a patient who was initially diagnosed with vulvar adenocarcinoma. This analysis may be extended to other clinical situations such as patients suffering from BRCA or other genetic mutations. Although previous case reports have not revealed a hereditary component, our patient may have a genetic predisposition to ectopic breast tissue, although this has not been evaluated.

In summary, ectopic breast tissue should be a potential differential diagnosis for newly diagnosed vulvar mass lesions. Care should be taken to excise these lesions given that they may harbor the same malignant potential as native breast tissue.

Contributors

Adrian L. Hernandez Lopez cared for the patient and drafted and critically revised the manuscript.

Shila Manandhar cared for the patient and drafted and critically revised the manuscript.

Lorrie Dubow cared for the patient and critically revised the manuscript.

All authors approved the final version of the manuscript.

Declaration of Competing Interest

The authors declare that they have no conflict of interest regarding the publication of this case report.

Funding

No specific grant from funding agencies in the public, commercial, or not-for-profit sectors supported the publication of this case report.

Patient Consent

Obtained.

Provenance and Peer Review

This case report was peer reviewed.

References

- [1] R. Resnik, C.J. Lockwood, T.R. Moore, M.F. Greene, J.A. Copel, R.M. Silver, Creasy and Resnik's Maternal-Fetal Medicine : Principles and Practice, 2019.
- [2] S.N. Deshmukh, A.N. Maske, A.P. Deshpande, S.P. Shende, Unilateral ectopic breast tissue on vulva in an adult female, *Indian J Surg.* 74 (4) (2012) 340–341.
- [3] S. Mikhael, W. Nilsson, K. Patel, S. Graf, Ectopic breast tissue of the vulva in a postmenopausal woman, *Case Rep. Obstet. Gynecol.* 2017 (2017), 7581750.
- [4] N. Lev-Cohain, P. Kapur, I. Pedrosa, Vulvar fibroadenoma with lactational changes in ectopic breast tissue, *Case Rep. Obstet. Gynecol.* 2013 (2013), 924902.
- [5] R.B. Mayer, S. Enengl, H. Witzany, P. Trautner, O. Shebl, P. Oppelt, Postpartum Galactostasis of the vulva in a case of bilateral lactating ectopic breast tissue, *Obstet. Gynecol.* 134 (1) (2019) 138–140.
- [6] Cantu de Leon D, Perez Montiel D, Vazquez H, Hernandez C, Cetina L, Lucio MH, Vulvar fibroadenoma: a common neoplasm in an uncommon site, *World J Surg Oncol.* 7 (2009) 70.
- [7] M.T. Chulia, A. Paya, M. Niveiro, S. Ceballos, F.I. Aranda, Phylloides tumor in ectopic breast tissue of the vulva, *Int. J. Surg. Pathol.* 9 (1) (2001) 81–83.
- [8] S. Larson, S. Yang, A. Chacko-Stacey, D. Mason, E. Hart, Self-resolving vulvar breast tissue arising in the post-partum setting: a case report and review of literature, *J. Hum. Lact.* 36 (2) (2019) 348–351.
- [9] M. Chung-Park, C. Zheng Liu, E.J. Giampoli, J.D. Emery, A. Shalodi, Mucinous adenocarcinoma of ectopic breast tissue of the vulva, *Arch Pathol Lab Med.* 126 (10) (2002) 1216–1218.
- [10] C. Baykal, I. Dunder, I.C. Turkmen, E. Ozyar, An unusual case of mammary gland-like carcinoma of vulva: case report and review of literature, *Eur. J. Gynaecol. Oncol.* 36 (3) (2015) 333–334.
- [11] S.D. Chang, Imaging of the vagina and vulva, *Radiol. Clin. N. Am.* 40 (3) (2002) 637–658.
- [12] B. Cohen Sacher, The Normal vulva, vulvar examination, and evaluation tools, *Clin. Obstet. Gynecol.* 58 (3) (2015) 442–452.