

# Sudden appearance of free fluid during endoscopic ultrasound-guided fine-needle aspiration

Mihai Rimbaș<sup>1,2</sup>, Marian Deaconu<sup>3</sup>, Alexandru Croitoru<sup>3</sup>, Andrei Haidar<sup>1</sup>

<sup>1</sup>Departments of Gastroenterology, and <sup>3</sup>Surgery, Colentina Clinical Hospital, Bucharest, <sup>2</sup>Department of Internal Medicine, Carol Davila University of Medicine, Bucharest, Romania

## ABSTRACT

During endoscopic ultrasound-guided fine-needle aspiration (EUS-FNA) of a pancreatic malignancy, a small quantity of free fluid, not seen before, suddenly appeared in the view, and time was spent ruling out ongoing hemorrhage. However, during follow-up, the patient gradually developed peritoneal signs and was referred for surgery. The images presented elucidate the diagnosis and raise the question of a theoretical change in diagnostic and therapeutic approach.

**Key words:** Biliary plastic stent, duodenal perforation, EUS, EUS-FNA, peritonitis

## INTRODUCTION

Although major complications following endoscopic ultrasonography procedures are rare; we all, as examiners, could be faced with the hypothetical situation of intraprocedural perforation. Therefore, careful consideration of each imaging detail and step of the procedure is of utmost importance in the early identification and management of such an incident.

## CASE REPORT

A 75-year-old male patient presented for endoscopic palliation of the jaundice secondary to an invasive pancreaticobiliary malignancy. Endoscopic retrograde cholangiopancreatography (ERCP) went well and a plastic 10 Fr, 7 cm stent was placed through the papilla, with consecutive improvement in the patient's

clinical status and biochemical tests. Cytopathologic confirmation of the neoplasia was attempted 4 days later using a linear echoendoscope (Olympus GF-UCT180, Olympus Europe GmbH, Hamburg, Germany) with the patient under propofol sedation, but under endoscopic ultrasound (EUS) guidance it was impossible to advance the 22-G needle (EZ Shot, Olympus Europe GmbH, Hamburg, Germany; the only type of needle available) into the tumor from the duodenum, despite multiple attempts. After the first needle pass into one peritumoral lymph node, a small quantity of free fluid, not seen before, appeared in the view [Figure 1]. A couple of minutes were spent ruling out ongoing hemorrhage, after which more needle passes were performed, and the procedure ended apparently without major incidents. There were no alterations in the monitored parameters or requirement of extra sedation or analgesia during the procedure.

After the EUS procedure, despite marked attenuation of jaundice, the patient under close follow-up gradually developed peritoneal signs, marked leukocytosis, and elevated C-reactive protein. In this context, a computer tomography (CT) abdomen was emergently performed and revealed the distal end of the previously inserted

### Access this article online

#### Quick Response Code:



#### Website:

[www.eusjournal.com](http://www.eusjournal.com)

#### DOI:

10.4103/2303-9027.175900

### Address for correspondence

Dr. Mihai Rimbaș, Department of Internal Medicine, Carol Davila University of Medicine, Bucharest, Romania. E-mail: [mrimbas@gmail.com](mailto:mrimbas@gmail.com)

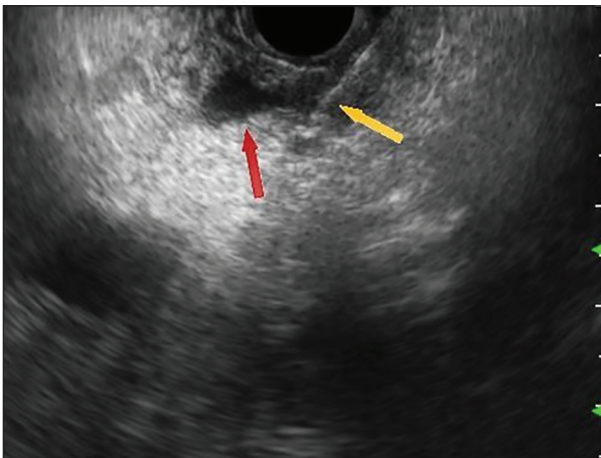
**Received:** 2014-12-26; **Accepted:** 2015-03-18

biliary plastic stent passing through the wall of the inferior genu of the duodenum [Figures 2 and 3]; ascites, but no pneumoperitoneum was present. The findings were confirmed during surgery [Figure 4] that besides removing the plastic stent and the bile from the peritoneal cavity, also carried out a primary duodenal repair and coledoco-jejuno-anastomosis. There was no blood in the peritoneal cavity, confirming the supposition that the small quantity of free fluid seen during the EUS examination was in fact bile. Unfortunately, the patient recovered slowly, being discharged 40 days afterwards, and succumbed 1 month later due to tumor progression.

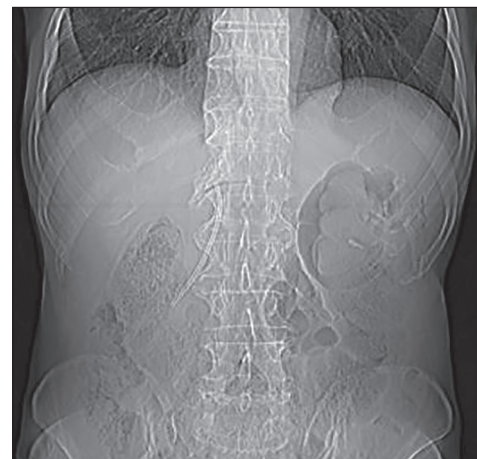## DISCUSSION

Bleeding is the most common complication of EUS-guided fine-needle aspiration (EUS-FNA); extraluminal

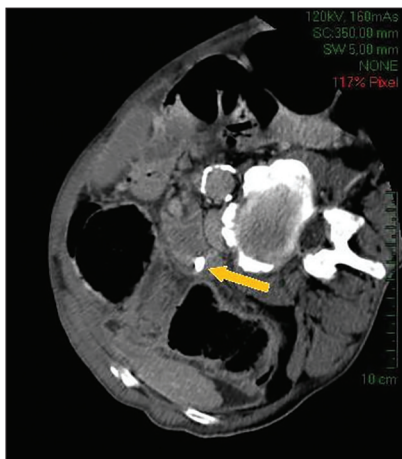
bleeding following EUS-FNA is clearly visualized on EUS as an expanding hyperechoic or hypoechoic region adjacent to the sampled lesion,<sup>[1]</sup> this being initially considered in the presented case. However, the most feared complication related to EUS is perforation, with a reported incidence between 0.075% following diagnostic procedures to 0.25% following interventions.<sup>[2]</sup> Duodenal perforation is the most common type, accounting for 6 out of 10 cases in a German study,<sup>[3]</sup> the most important responsible factors being, besides the physical characteristics of the echoendoscopes<sup>[4]</sup> (lack of forward viewing, higher rigidity and stiffness of the scope tip, larger diameter compared to gastroscopes or even duodenoscopes, longer nonflexible section just proximal to the transducer, and presence of a rigid segment containing the transducer that extends beyond the optical lens), also the significantly longer duration of the EUS examination compared with standard upper



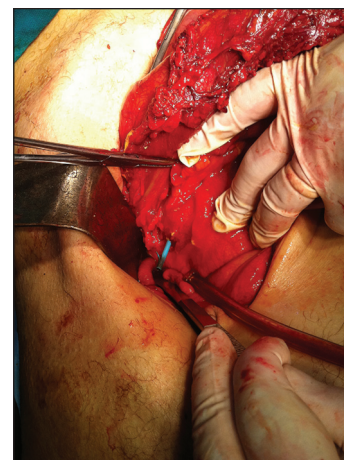
**Figure 1.** A small quantity of free fluid (red arrow) is seen during EUS-FNA of a peritumoral lymph node (not clearly seen); the puncturing needle is also shown (yellow arrow). EUS-FNA = Endoscopic ultrasound-guided fine-needle aspiration



**Figure 2.** Planar CT image showing the position of the stent. CT = Computed tomography



**Figure 3.** Distal extremity of the plastic stent penetrating the duodenal wall (yellow arrow)



**Figure 4.** Confirmatory picture taken from the surgical intervention, revealing the stent penetrating through the inferior genu of the duodenum

digestive endoscopy.<sup>[5]</sup> Moreover, patients who undergo EUS-FNA are approximately 10 times more likely to suffer complications following EUS compared to patients undergoing diagnostic noninterventional EUS,<sup>[6]</sup> with most of the fatal complications occurring after examinations by endoscopists who have performed fewer than 300 EUS procedures.<sup>[7]</sup>

As there are several published case reports of stent-induced perforations of the duodenal wall,<sup>[8,9]</sup> none of them is reported to have occurred immediately after a EUS examination. We think that the duodenal perforation in this case was induced by the multiple attempts at puncturing the primary tumor, somehow determining pushing of the distal end of the stent through the wall of the duodenum, even if the water-filled balloon was not used for the EUS examination. Although it is thought that the balloon technique could protect against perforation induced by the tip of the scope, we think that a wider pressure surface might favor pushing a plastic stent from the common bile duct. Despite these considerations, a retrospective study showed that pre-EUS stenting of biliary obstructions due to pancreatic cancer did not increase the EUS-FNA complication rate, and the accuracy of tissue diagnosis was not impaired if ERCP and endoscopic stenting were performed more than 1 day prior to EUS-FNA,<sup>[10]</sup> once more proving that our case was singular.

Still, the duodenal perforation in the presented case could have been recognized early, given the sudden appearance of free fluid during the procedure (which was thought to represent bleeding), fact that could have majorly altered the therapeutic attitude in this case. There is in fact one published case report that describes an iatrogenic duodenal perforation during EUS managed successfully by endoscopic closure followed by conservative treatment.<sup>[11]</sup> Besides that, one recent retrospective study shows that early identification of duodenal perforations is associated with a much better outcome, possibly avoiding surgery by using endoscopic treatment (usually clipping) and conservative management alone.<sup>[12]</sup>

Therefore, we think that a careful EUS investigation must always be carried out prior to EUS-FNA, so that any changes occurring afterwards could be recognized easily. We also suggest that if there is the slightest suspicion of a perforation during EUS in patients with biliary stents, the correct position of the stent (s) should be confirmed at the end of the examination, in order to avoid the morbidity and mortality related to a stent-induced perforation.

## REFERENCES

1. Affi A, Vazquez-Sequeiros E, Norton ID, et al. Acute extraluminal hemorrhage associated with EUS-guided fine needle aspiration: Frequency and clinical significance. *Gastrointest Endosc* 2001;53:221-5.
2. Niv Y, Gershinsky Y, Kenett RS, et al. Complications in endoscopic retrograde cholangiopancreatography (ERCP) and endoscopic ultrasound (EUS): Analysis of 7-year physician-reported adverse events. *Drug Healthc Patient Saf* 2011;3:21-5.
3. Gottschalk U, Dffelmeyer M, Jenssen C. Complications recording in diagnostic and therapeutic endosonography [Komplikationserfassung der diagnostischen und therapeutischen Endosonografie]. *Z Gastroenterol* 2011;49:V118.
4. Tierney WM, Adler DG, Chand B, et al. ASGE TECHNOLOGY COMMITTEE. Echoendoscopes. *Gastrointest Endosc* 2007;66:435-42.
5. Parusel M, Krakamp B, Janssen J, et al. Endoscopic ultrasonography (EUS) of the upper gastrointestinal tract — prospective multicenter study to evaluate time and staff requirements. *Z Gastroenterol* 2003;41:907-12.
6. Jenssen C, Alvarez-Sánchez MV, Napoléon B, et al. Diagnostic endoscopic ultrasonography: Assessment of safety and prevention of complications. *World J Gastroenterol* 2012;18:4659-76.
7. Lachter J. Fatal complications of endoscopic ultrasonography: A look at 18 cases. *Endoscopy* 2007;39:747-50.
8. O'Connor R, Agrawal S, Aoun E, et al. Biliary stent migration presenting with leg pain. *BMJ Case Rep* 2012;2012.
9. Smart P, Keenan D, Campbell W, et al. Duodenal perforation secondary to migration of endobiliary prosthesis. *BMJ Case Rep* 2012;2012.
10. Fisher JM, Gordon SR, Gardner TB. The impact of prior biliary stenting on the accuracy and complication rate of endoscopic ultrasound fine-needle aspiration for diagnosing pancreatic adenocarcinoma. *Pancreas* 2011;40:21-4.
11. Sebastian S, Byrne AT, Torreggiani WC, et al. Endoscopic closure of iatrogenic duodenal perforation during endoscopic ultrasound. *Endoscopy* 2004;36:245.
12. Jin YJ, Jeong S, Kim JH, et al. Clinical course and proposed treatment strategy for ERCP-related duodenal perforation: A multicenter analysis. *Endoscopy* 2013;45:806-12.

**How to cite this article:** Rimbaş M, Deaconu M, Croitoru A, Haidar A. Sudden appearance of free fluid during endoscopic ultrasound-guided fine-needle aspiration. *Endosc Ultrasound* 2016;5:55-7.

**Source of Support:** Nil. **Conflicts of Interest:** None declared.