

## ORIGINAL RESEARCH—ERECTILE DYSFUNCTION

## A Study of the Early Changes of the Level of Calcitonin Gene-Related Peptide and Histopathology of Penises of Rats with Experimentally Induced Type I Diabetes Mellitus by Streptozocin

Abdel Aal M. El-Kamshoushi, PhD,\* Wafaa I. Abdallah, PhD,\* Suzan F. Helal, PhD,<sup>†</sup> Nesrine M. El Azhary, PhD,<sup>‡</sup> and Eman M. Hassan, PhD\*

\*Dermatology, Venereology and Andrology, Alexandria University, Alexandria, Egypt; <sup>†</sup>Pathology, Alexandria University, Alexandria, Egypt; <sup>‡</sup>Medical Physiology, Alexandria University, Alexandria, Egypt

DOI: 10.1002/sm2.3

### ABSTRACT

**Introduction.** Diabetes mellitus (DM) is a multiorgan disease that leads to neurovascular complications that disturb the normal erectile function.

**Aim.** The aim of the current work was to study the early changes occurring in the level of calcitonin gene-related peptide (CGRP) and histopathological changes in penile tissues of uncontrolled diabetic rats.

**Materials and Methods.** This study was carried on 50 adult male Sprague-Dawley rats divided into two main groups: group I (control, n = 10) and group II (diabetic, n = 40). Type I DM was induced by a single intraperitoneal injection of streptozotocin (60 mg/kg). The tissue level of CGRP and histopathological examination of rat penises were assessed at 2, 4, 6, and 8 weeks after induction of DM.

**Results.** CGRP was higher in the diabetic group at 4, 6, and 8 weeks than in the control group. However, endothelial changes and decreased smooth muscles mass started only 2 weeks after induction of DM.

**Conclusion.** Deterioration of histopathological features of the uncontrolled diabetic rats corporeal tissues is time dependent. Furthermore, vascular changes seem to precede the neurological changes. **El-Kamshoushi AAM, Abdallah WI, Helal SF, El Azhary NM, and Hassan EM. A study of the early changes of the level of calcitonin gene-related peptide and histopathology of penises of rats with experimentally induced type I diabetes mellitus by streptozocin. Sex Med 2013;1:21–29.**

**Key Words.** CGRP; Diabetes Mellitus; Erectile Dysfunction

### Introduction

Penile erection is a complex neurovascular event modulated by psychological, hormonal factors and some cellular components such as endothelial cells and biochemical factors [1].

Erectile dysfunction (ED) has a long list of causes especially in patients who have neurological or vascular problems. So, its prevalence is higher among diabetic men, even at a younger age compared with men without diabetes [2].

Pathophysiology of diabetic ED is multifactorial due to occurrence of neural, vascular, endocrinal, metabolic, and psychogenic changes [3]. This study focused on the vascular and neural aspects of the diabetic ED, trying to discover which precedes the other.

Diabetic neuropathy initially affects small unmyelinated fibers and later, larger myelinated fibers. The putative pathogenesis of diabetic neuropathy includes the accumulation of sorbitol and fructose, auto-oxidation of glucose leading to the

formation of reactive oxygen species, advanced glycation end-products produced by nonenzymatic glycation of proteins, inappropriate activation of protein kinase C and a deficit of neurotrophic supports [4].

Several neurotrophins as neurotrophin 3 (NT-3), NT-4, and nerve growth factor (NGF) are known to have a positive effect on the nerve dysfunction in diabetic cavernous tissue [5]. The latter is even suggested to mediate the action of CGRP [6].

Calcitonin gene-related peptide (CGRP) is an important neuropeptide involved in penile erection [7]. It is present in the central and peripheral nervous system, mainly in close approximation with blood vessels [8] while in the periphery, it is located in small, unmyelinated sensory C fibers and myelinated type A fibers [9]. CGRP is a potent arterial and venous vasodilator that acts directly on the smooth muscles to stimulate adenylate cyclase enzyme. The resulting rise in cyclic adenosine monophosphate (cAMP) activates protein kinase A, which cause opening of potassium channels, leading to muscular relaxation [10].

On the other hand, various pathological changes affect the endothelial cells and smooth muscle of corpus cavernosum in diabetic patients. They lead to endothelial dysfunction, increased the contractile susceptibility of the smooth muscles with decreased response to the relaxation factors and finally fibrosis and atrophy of the corpus cavernosum [11].

The purpose of the current study was to detect the early pathological changes that take place in diabetic rats' corpus cavernosum. In addition, measurement of the level of CGRP in corpus cavernosum was done along 8 weeks to evaluate the effect of diabetes on these components; hoping to solve the debate about which is primary affected: endothelial or neurological component of diabetic erectile tissues.

We hypothesized that the diabetic state would be associated with progressive loss of endothelial integrity in the corporal spaces of the penis. Furthermore, we hypothesized that there would be upregulation of CGRP in diabetic rats consistent with reports by other investigators.

## Material and Methods

### Animal Model Selection

After approval of the experimental protocol by the Ethics Committee of the Faculty of Medicine, Alexandria University, this study was carried on

50 adult male Sprague-Dawley rats, weighing 150–200 g. They were supplied by the lab of the Physiology Department, Faculty of Medicine, Alexandria University. Rats were housed at room temperature, in polypropylene cages, with free access to standard diet and tap water. They were randomly distributed into two main groups:

- Group I (control group): 10 normal rats that received a single intraperitoneal injection of saline (similar volume to the injected amount of streptozocin in group II).
- Group II: 40 rats that received a single intraperitoneal injection of streptozotocin (STZ) in a dose of 60 mg/kg body weight, to induce type I diabetes mellitus (DM) [12]. STZ was purchased from Sigma (St. Louis, MO, USA) and diluted in citrate buffer (0.01 M, pH 4.6).

### Diabetic Status

Induction of diabetes was verified 48 hours after STZ injection. Rats with fasting blood glucose (FBG) levels higher than 300 mg/dL were considered to be diabetic [13]. Group II diabetic rats were further subdivided into four subgroups (IIa, IIb, IIc, and IId), each containing 10 rats and sacrificed 2, 4, 6, and 8 weeks after induction of DM, respectively. No hypoglycemic drugs were given to diabetic rats during the experiment.

### Preparation of Samples

At the end of experimental period, after an overnight fasting, experimental manipulations were carried out with the animals under light ether anesthesia and under complete sterile conditions.

The following parameters were measured at 2 weeks after saline or STZ injection in group I and IIa, respectively, as well as in group IIb at 4 weeks, in group IIc at 6 weeks and finally in group IId at 8 weeks:

1. FBG level (by tail tip prick with the use of glucose-oxidase reagent strips; One Touch Ultra, Johnson & Johnson®, New Brunswick, NJ, USA).
2. Penile tissue was obtained through a circular incision made at the corona with subsequent removal of the foreskin and shaft skin and amputation of the penis at the most extreme proximal position possible.

Excess blood was removed by gently blotting the penis on sterile cotton gauze. The underlying cavernosal tissue was bisected longitudinally into two right and left halves. The right part was kept at

-20°C until homogenization in phosphate buffer saline; subsequently, this tissue was used for determination of CGRP using the Calcitonin Gene Related Peptide (CGRP (Rat, Mouse)) EIA kit (Phoenix Pharmaceuticals, Burlingame, CA, USA) according to manufacturer instructions [14].

The left half of the peeled penile tissue was harvested and immersed in neutral buffered formalin containing 4% formaldehyde for a period of 6 hours. Specimens were subsequently embedded in paraffin and sectioned at 5 µm using a rotor microtome. Sections were stained using hematoxylin and eosin stain for further evaluation under light microscope. Endothelial disease was graded on a four-point scale as (i) normal (no changes); (ii) only flattened endothelium; (iii) flattened with degree of loss in some areas of the lining, i.e., (partial loss); and (iv) total loss of endothelial lining.

After the end of the experiment, animals were killed by exsanguinations.

## Results

The FBG level in the diabetic rats (group IIa, IIb, IIc, and IId) was significantly higher than group I rats ( $P < 0.001$ ). The mean FBG in group I healthy rats was  $74.50 \pm 5.84$  mg/dL. In group II, the mean fasting blood glucose (FBS) was  $405.30 \pm 41.43$  mg/dL in group IIa,  $402.30 \pm 25.94$  mg/dL in group IIb,  $423.0 \pm 42.96$  mg/dL in group IIc, and  $449.60 \pm 35.08$  mg/dL in group IId. Significant increase in the FBG level was noted in group IIb, IIc, and IId in relation to group IIa rats ( $P < 0.001$ ).

The mean level of CGRP in penile tissue in healthy rats was  $0.0104 \pm 0.0007$  ng/mL. In group II diabetic rats, the mean level of CGRP was  $0.0105 \pm 0.0005$  ng/mL in group IIa,  $0.0250 \pm 0.0123$  ng/mL in group IIb,  $8.59321 \pm 13.1155$  ng/mL in group IIc, and  $13.2252 \pm 16.6675$  ng/mL in group IId (Figure 1A, B). It was significantly higher in the diabetic rats of group IIb ( $P_1 = 0.002$ ), group IIc ( $P_1 < 0.001$ ), and group IId ( $P_1 < 0.001$ ) compared with group I (control) as well as group IIa rats ( $P_2 = 0.012$ ,  $P_2 < 0.001$ ,  $P_2 < 0.001$ , respectively).

The level of CGRP increased significantly 4 weeks after induction of DM, kept increasing at 6 weeks and at 8 weeks of induction of DM. No statistically significant changes in the level of CGRP were noted between group IIc (6 weeks diabetic) and group IId (8 weeks diabetic) ( $P_4 = 0.940$ ).

## Histopathological Changes in Endothelium, Smooth Muscles, and Vessel Wall Thickness of Corpora Cavernosa of Rats' Penises (Table 1)

The left halves of the 50 rats (control group and four diabetic groups) were blindly examined by the pathology professor (without respect of being control or diabetic group). The sections were examined by light microscopy by both low power (magnification  $\times 20$ ) and high power (magnification  $\times 40$ ).

In group IIa (2 weeks after induction of DM), significant flattening of endothelial lining and decreased smooth muscle mass occurred in 80% of rats in relation to the control group (Figure 2A, B).

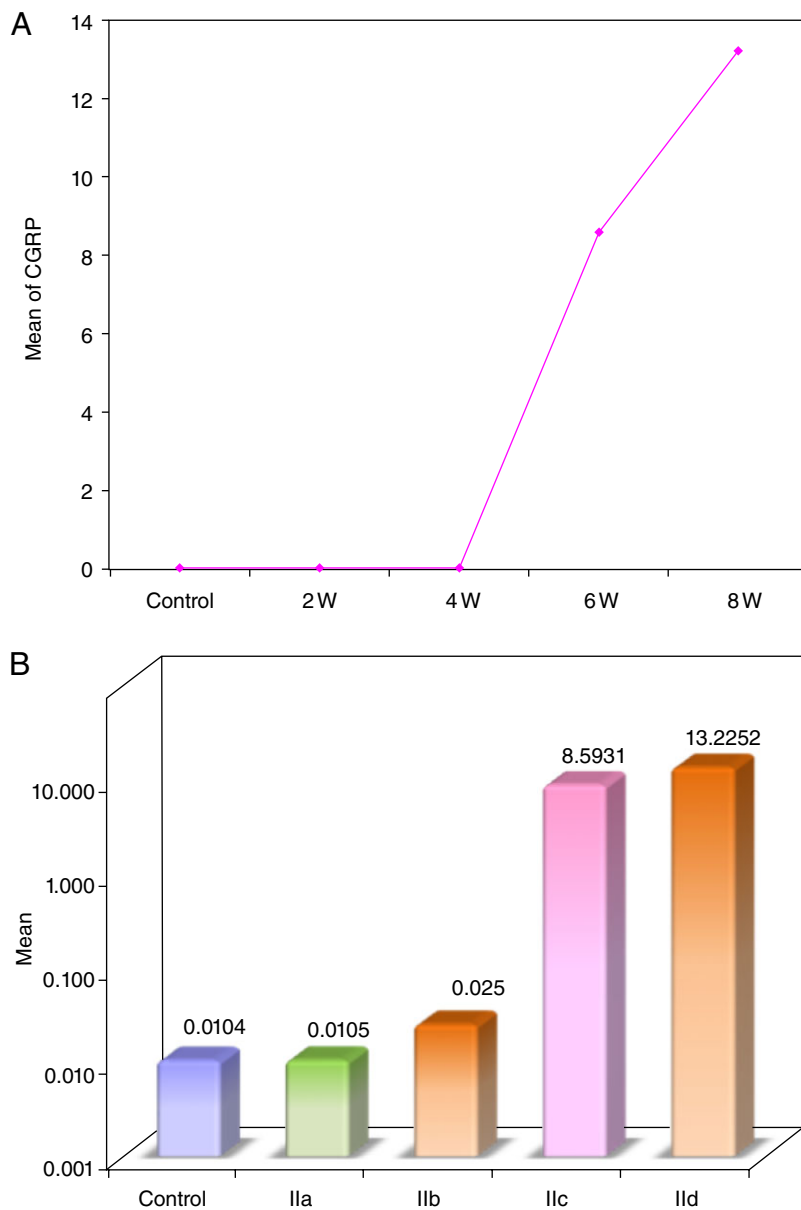
In group IIb (4 weeks after induction of DM), flattening with partial loss of the endothelial lining and decreased muscle mass was reported in 80% of rats, whereas partial fibrosis of the smooth muscles was seen in 20% of rats. The vessel wall thickness started to be decreased (Figure 3A, B). These changes were statistically significant in relation to the other groups.

In group IIc (6 weeks after induction of DM), significant changes were noted in relation to the nondiabetic group such as endothelial lining was flattened and associated with partial loss in 70% of cases, whereas 30% of rats showed total endothelial loss. Smooth muscles were partially fibrosed in 80% of rats and showed complete hyalinization in 20% of rats. The vessel wall thickness was still decreased.

In group IId (8 weeks after induction of DM), endothelial lining was totally lost in 80% of cases and flattened with partial loss in only 20%. Furthermore, 70% of rats showed totally hyalinized smooth muscles and only 30% appeared partially fibrosed. Vessel wall thickness was still decreased (Figure 4). It should be noted that these histopathological changes were not significant in relation to group IIc.

## Relation Between the Tissue Level of CGRP and the Histopathological Changes in Diabetic Rat Penises

During the present study, the level of CGRP showed significant progressive increase in a time-dependent manner and was accompanied with deterioration of the endothelial conditions in the first 6 weeks of the study. There was a positive correlation between the level of CGRP between group IIa and group IIb when the smooth muscles changes showed ill defined wall and decreased muscle mass, also between group IIc and group IIb when partial fibrosis of the smooth muscles



**Figure 1** (A) The level of CGRP in the penile tissue of group II diabetic rats (ng/mL). (B) A bar graph showing the level of CGRP in the penile tissue of group II diabetic rats (ng/mL).

was noted in 80% of rats ( $P = 0.010$ ,  $P = 0.037$ , respectively).

#### Relation Between the FBG and Histopathological Changes in Each Studied Group

There were significant increase in the FBS level in relation to smooth muscle pathology changes as follows: first between group IIa and group IIb when smooth muscles showed ill defined wall with decreased mass ( $P = 0.034$ ), then changes between 6 weeks diabetic rats (group IIc) and 8 weeks diabetic rats (group IId) ( $P = 0.014$ ) when smooth muscles showed partial fibrosis in eight rats and three rats, respectively, and lastly, when complete

hyalinization occurred in the same groups (two rats in group IIc and seven rats in group IId) ( $P = 0.040$ ).

#### Discussion

In the current study, type I DM was induced in group II rats by an intraperitoneal injection of STZ. Forty-eight hours later, all rats showed hyperglycemia  $>300$  mg/dL. In fact, the rat model has been chosen to study the early histopathological changes and changes in the level of CGRP occurring in the penile tissue in case of type I DM for many reasons.

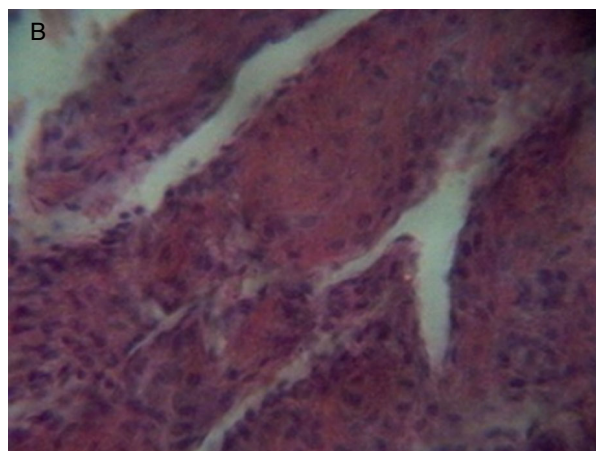
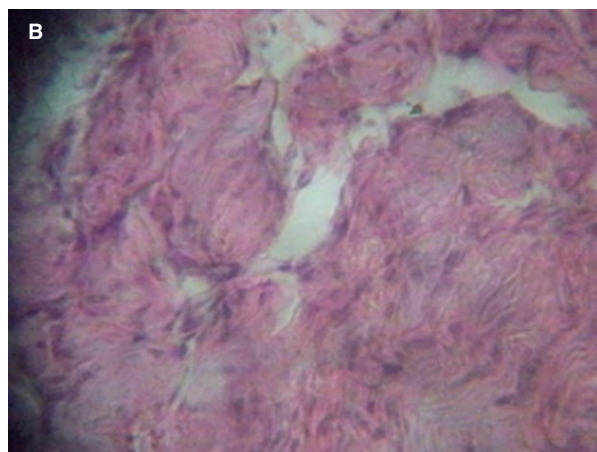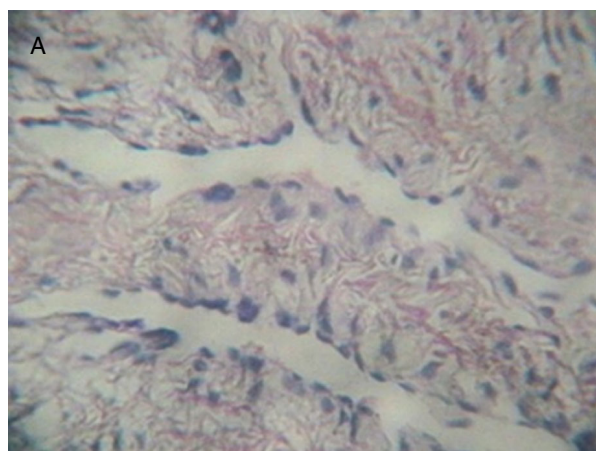
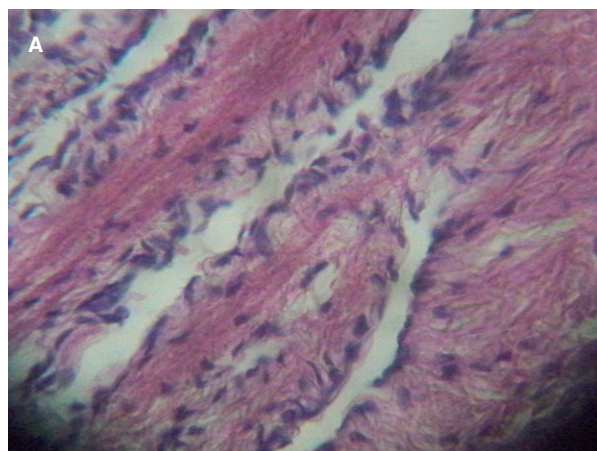


**Table 1** Comparison between the cavernosal endothelial changes in the studied groups

	Group I (Control)		Group IIa (Diabetic 2 W)		Group IIb (Diabetic 4 W)		Group IIc (Diabetic 6 W)		Group IId (Diabetic 8 W)	
	No	%	No	%	No	%	No	%	No	%
Endothelium										
Normal	10	100.0	2	20.0	0	0.0	0	0.0	0	0.0
Flattened	0	0.0	8	80.0	2	20.0	0	0.0	0	0.0
Flattened + partial loss	0	0.0	0	0.0	8	80.0	7	70.0	2	20.0
Total loss	0	0.0	0	0.0	0	0.0	3	30.0	8	80.0
MCp	<0.001*		FEp = 0.001*		MCp < 0.001*		MCp < 0.001*		MCp < 0.001*	
p <sub>1</sub>					MCp = 0.001*		MCp < 0.001*		MCp < 0.001*	
p <sub>2</sub>							MCp = 0.109		MCp = 0.001*	
p <sub>3</sub>									FEp = 0.070	
p <sub>4</sub>										

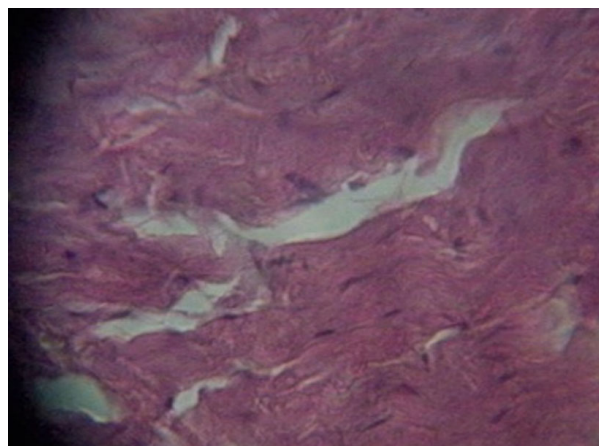
\*Statistically significant at  $P \leq 0.05$ .

MCp = *P* value for Monte Carlo test; FEp = *P* value for Fisher's exact test; p<sub>1</sub> = *P* value between Control with each other weeks; p<sub>2</sub> = *P* value between 2 W with each other weeks; p<sub>3</sub> = *P* value between 4 W with 6 and 8 weeks; p<sub>4</sub> = *P* value between 6 W and 8 W.



**Figure 2** (A) Normal vascular spaces in corpus cavernosum of healthy (control) rats. (B) Flattened endothelial lining in group IIa rats.

**Figure 3** (A) Flattened endothelium with partial loss with decreased smooth muscle mass in group IIb. (B) Flattened endothelial with partial loss in some areas while smooth muscles more atrophic.



**Figure 4** Atrophic hyalinized smooth muscles with loss of endothelial lining in group IIId.

The rat model in particular provides the most valuable and reproducible investigations that significantly contributed to male sexual dysfunction as well as in the development of various treatment modalities [15]. Furthermore, diabetic rats start to develop dysfunctional erectile responses after 6 weeks of induction of diabetes contrarily to half of diabetic men who usually suffer from ED within 10 years of diagnosis of DM [16,17].

With regard to the changes in the FBG level in group II rats (diabetic), it ranged between 350 and 500 mg/dL with progressive significant increase along the first 4 weeks of the present study, with no further significant elevations during the remaining 4 weeks of the study. This may be explained by the progressive damage of beta cells of islets of Langerhans by STZ due to necrosis and apoptosis up to a point where no significant further damage could occur. This is consistent with the findings of other studies that proved the destructive capacity of STZ to the pancreas [18].

CGRP is one of the most potent vasodilators in the body and is postulated to play a role in penile erection. It is found in large amounts in axons innervating the penis of rats, dogs, monkeys, and humans [19,20].

CGRP was chosen in the present work as a marker to evaluate the effect of type I DM on unmyelinated sensory nerve endings in the corpus cavernosum. In the current study, the level of CGRP started to increase significantly in the diabetic rats 4 weeks after induction of DM compared with normal rats and kept on increasing 6 weeks after induction of DM. The previous results may reflect neuroplastic adjustments in the afferent innervations in order to compensate for early

diabetes-induced neuropathic changes that may cause erectile disturbances.

In fact, neurotrophins such as NGF, brain-derived neurotrophic factor, and NT-3 are upregulated in the cavernous tissue of diabetic rats with ED [21]. They play an important role in the repair and regeneration of injured nerves as well as regulating the development and function of postganglionic sympathetic and sensory neurons [22].

NGF in particular has an important role in the growth and maintenance of function of sensory nerves [23]. At a cellular level, NGF upregulates CGRP via a cAMP/ras responsive element [6], and via a constitutively active mitogen-activated protein kinase. In some experiments, the upregulation of CGRP was associated with nerves sprouting, an indication of NGF activity [24]. That is why the increased CGRP level in the current study might result from compensatory increase in the neurotrophin NGF.

The results of the present study are consistent with another study by Morrison et al., who found a significant elevation of CGRP in the rats corpora cavernosa after 12 and 16 weeks of induction of type I DM, though they did not report the early steady changes in the level of CGRP as in the current study [12].

Further studies elucidated the possible protective role of CGRP. It is involved in the mediation of ischemic preconditioning in the heart, heat stress reaction, drug-induced preconditioning, and in endothelial protection [25].

In the present work, in contrast to the expected, no further significant increase in the level of CGRP occurred in the 8th week of DM compared to the 6th week. Other investigators even found that diabetes caused a decrease rather than an increase in CGRP content [26].

The cause of discontinued increase or even decrease in the level of CGRP along the diabetes period is subject to controversies. Some evidence suggests that chronic hyperglycemia may contribute to decreased expression of the neuronal genes that are responsible for NGF formation in diabetes [27–29]. This explanation is supported by the findings of many researchers. Tomlinson DR and his coworkers reported a decreased retrograde axonal transport of NGF and decreased support of NGF-dependent sensory neurons, with reduced expression of their neuropeptides, substance *P* and CGRP in diabetics. As expected, correction of hyperglycemia with intensive insulin therapy normalized these deficits [30].

Unfortunately, studies found that the increased level of neurotrophins could not completely compensate for the severe neuropathy. Similarly, the endogenous increase in CGRP level may be neither enough quantitatively nor sustained long enough to compensate for the nerve dysfunction [21,31,32].

Yorek et al. reported that, after 10–12 weeks of induction of type I DM by STZ, there was a decrease in the CGRP content in epineurial arterioles and the ability of exogenous CGRP to induce vasodilation. These results may be due to measurement of CGRP level after a longer duration of diabetes (10–12 weeks) than the duration of the present study (8 weeks), but it also may indicate that the steady changes in CGRP level in the last 2 weeks of the present study could further decrease with longer duration of hyperglycemia [33].

In the present study, assessment of the diabetic penile tissue revealed progressive pathological changes in the endothelium, smooth muscles, and vessel wall thickness. They were found to coincide with the duration of diabetes. In fact, 2 weeks after induction of type I DM, endothelial flattening occurred in 80% of rats, whereas at 4 weeks, 80% of rats had flattened endothelium with partial loss, and at 8 weeks, the endothelium was completely lost in 80% of rats.

With regard to the smooth muscle changes, the smooth muscle mass decreased starting from the 2nd week after induction of type I DM, progressed to partial replacement by fibrous tissue at 6 weeks and showed complete hyalinization in 70% of rats at 8 weeks. The vessel wall thickness of the affected vasculature also decreased in 100% of rats starting from the 4th week after induction of DM.

These results coincide with other studies that reported that diabetic rabbit penises showed a significant decrease in corporeal vascular volume, trabecular smooth muscles, cavernous artery diameter, and luminal volume compared with controls [34,35].

#### **What Is the Premium Cause of ED: Neuropathy or Vasculopathy?**

A further point of importance should be noted in the present study: significant pathological changes in the endothelium and smooth muscle started in the 2nd week (group IIa) in relation to the control group, whereas the changes of CGRP level started to be significant from the 4th week (group IIb). These results suggest that vascular changes occur

earlier than neurological abnormalities, and they may even play a role in the pathogenesis of neurological ED.

Obrosova et al. suggested that diabetes-induced decrease in nerve blood flow, and resultant endoneural hypoxia plays a key role in functional and morphological changes in the diabetic nerve [36]. Diabetes was also found to induce impairment of endothelium-dependent vascular relaxation in vasa nervosum as well as coronary and mesentery arteries [37].

All these changes could be mostly attributed to the metabolic derangements caused by diabetes such as: first formation of advanced glycation end products in rat and human diabetic corpus cavernosal tissue that bind with vascular collagen and cause vascular thickening, endothelial dysfunction, and atherosclerosis [16].

Second, generation of reactive oxygen species [36]. Third, formation of peroxynitrite, oxidizing agent that rapidly reacts with nitric oxide (NO) that accumulates in vascular beds thus creating NO consumption [38]. In addition, peroxynitrite decrease endoneurial nutritive blood flow and vascular reactivity of epineurial arterioles [39].

All these studies support the suggestion for the primary vascular concept for diabetic ED.

Fourth, diabetes may interfere with the synthesis and/or release of NO from both nerves and endothelium in the corpus cavernosum and that alterations of endothelium-derived responses occur earlier than neurological disturbances. These findings further support the results of the current study [40].

In the first 6 weeks of the study, smooth muscle cell changes ran significantly parallel to elevated CGRP level. It should be noted that vascular smooth muscle cells in the intact vascular wall are differentiated for contraction. However, the response to vascular injury involves transition toward a synthetic phenotype, with increased tendency for proliferation [41]. Exogenous CGRP can transform the phenotype of corpus cavernosal smooth muscles in diabetic ED rats from synthetic to contractile type [32].

In the present study, although up until the 8th week of the study, the changes in FBS level had no significant relation to the deterioration in endothelial lining or the changes in the vessel wall thickness, the FBS level had significant relation to smooth muscles changes between 6th and 8th week of DM.

It was also found that under hyperglycemic conditions, the phenotype of corpus cavernosum



smooth muscles cell change and exhibit less contractility. This could have a key role in the pathogenesis of diabetic ED [42].

These results support the findings of the current work in which decreased smooth muscle component was correlated with high FBS level, which has an impact on the erectile function.

It should be noted that the current study had some limitations. First, the small sample size; which was mostly due to death of rats with untreated uncontrolled diabetes. Second, the relatively short duration of the study. However, our main aim was to assess the early changes in CGRP in corporeal tissues in diabetes. Third, the lack of immunohistochemical staining of corporeal tissues that would further elucidate the sequential pathological changes. This staining is recommended to be done in further studies.

To summarize, DM is characterized by progressive loss of normal endothelium and smooth muscle cells from the corpus cavernosum [43]. The upregulation of the transforming growth factor  $\beta$ -1 (TGF- $\beta$ 1)/Smad/connective tissue growth factor (CTGF) signaling pathway might play an important role in diabetes-induced fibromuscular changes that finally ends by deterioration of erectile function [44].

Our study support the hypothesis that vasculopathy is the primary pathology in diabetic ED as it occurs earlier than neuropathy and may affect vasa nervosa. Furthermore, neuropathy may perpetuate vasculopathy as increased level of CGRP is associated with changes in smooth muscle type.

**Corresponding Author:** Abdel Aal M. El-Kamshoushi, PhD, Alexandria Faculty of Medicine—Dermatology, STDs & Andrology, 398, El Horreya Road, Mostafa Kamel, Alexandria 21311, Egypt. Tel: 002035452180; Fax: 2035452180; E-mail: kamshoushi@yahoo.com

**Conflict of Interest:** The authors report no conflicts of interest.

## References

- Martinez-Salamanca JI, Martinez-Ballesteros C, Portillo L, Gabancho S, Moncada I, Carballido J. Physiology of erection. *Arch Esp Urol* 2010;63:581–8.
- Yohannes E, Chang J, Tar MS, Davies KP, Chance MR. Molecular targets for diabetes mellitus-associated erectile dysfunction. *Mol Cell Proteom* 2010;9:565–78.
- Thorve VS, Kshirsagar AD, Vyawahare NS, Joshi VS, Ingale KG, Mohite RJ. Diabetes-induced erectile dysfunction: Epidemiology, pathophysiology and management. *J Diabetes Complications* 2011;25:129–36.
- Yasuda H, Terada M, Maeda K, Kogawa S, Sanada M, Haneda M, Kashiwagi A, Kikkawa R. Diabetic neuropathy and nerve regeneration. *Prog Neurobiol* 2003;69:229–85.
- Chen Y, Yang R, Yao L, Sun Z, Wang R, Dai Y. Differential expression of neurotrophins in penises of streptozotocin-induced diabetic rats. *J Androl* 2007;28:306–12.
- Freeland K, Liu YZ, Latchman DS. Distinct signalling pathways mediate the cAMP response element (CRE)-dependent activation of the calcitonin gene-related peptide gene promoter by cAMP and nerve growth factor. *Biochem J* 2000;345(Pt 2):233–8.
- Lue TF. Physiology of penile erection and pathophysiology of erectile dysfunction. In: Wein AJ, Kavoussi LR, Novick AC, Partin AW, Peters CA, eds. *Campbell—Walsh urology*. 10th edition. Philadelphia: Saunders Elsevier; 2007:718–49.
- Quirion R, Van Rossum D, Dumont YS, Pierre S, Fournier A. Characterization of CGRP1 and CGRP2 receptor subtypes. *Ann N Y Acad Sci* 1992;657:88–105.
- Edvinsson L, Sams A, Jansen-Olesen I, Tajti J, Kane SA, Rutledge RZ, Koblan KS, Hill RG, Longmore J. Characterisation of the effects of a non-peptide CGRP receptor antagonist in SK-N-MC cells and isolated human cerebral arteries. *Eur J Pharmacol* 2001;415:39–44.
- Han SP, Naes L, Westfall TC. Calcitonin gene-related peptide is the endogenous mediator of nonadrenergic-noncholinergic vasodilation in rat mesentery. *J Pharmacol Exp Ther* 1990;255:423–8.
- Azadzi KM. Vasculogenic erectile dysfunction: Beyond the haemodynamic changes. *BJU Int* 2006;97:11–16.
- Morrison JF, Dhanasekaran S, Howarth FC. Neuropeptides in the rat corpus cavernosum and seminal vesicle: Effects of age and two types of diabetes. *Auton Neurosci* 2009;146:76–80.
- Guneli E, Tugyan K, Ozturk H, Gumustekin M, Cilaker S, Uysal N. Effect of melatonin on testicular damage in streptozotocin-induced diabetes rats. *Eur Surg Res* 2008;40:354–60.
- Porstmann T, Kiessig ST. Enzyme immunoassay techniques, an overview. *J Immunol Methods* 1992;150:5–21.
- Mehta N, Sikka S, Rajasekaran M. Rat as an animal model for male erectile function evaluation in sexual medicine research. *J Sex Med* 2008;5:1278–83.
- Moore CR, Wang R. Pathophysiology and treatment of diabetic erectile dysfunction. *Asian J Androl* 2006;8:675–84.
- Cho SY, Park K, Paick JS, Kim SW. Change of erectile function and responsiveness to phosphodiesterase type 5 inhibitors at different stages of streptozotocin-induced diabetes in rats. *J Sex Med* 2011;8:1352–61.
- Jana K, Chatterjee K, Ali KM, De D, Bera TK, Ghosh D. Antihyperglycemic and antioxidative effects of the hydro-methanolic extract of the seeds of *Caesalpinia bonduc* on streptozotocin-induced diabetes in male albino rats. *Pharmacognosy Res* 2012;4:57–62.
- Yucel S, Baskin LS. Identification of communicating branches among the dorsal perineal and cavernous nerves of the penis. *J Urol* 2003;170:153–8.
- McNeill DL, Papka RE, Harris CH. CGRP immunoreactivity and NADPH-diaphorase in afferent nerves of the rat penis. *Peptides* 1992;13:1239–46.
- Dai YT, Chen Y, Yao LS, Yang R, Sun ZY, Wen DG. Expression of nerve growth factor in cavernous tissue and its effects on the treatment of rats with diabetic erectile dysfunction. *Zhonghua Nan Ke Xue* 2005;11:748–51, 54.
- Huang EJ, Reichardt LF. Neurotrophins: Roles in neuronal development and function. *Annu Rev Neurosci* 2001;24:677–736.
- Terenghi G. Peripheral nerve regeneration and neurotrophic factors. *J Anat* 1999;194:1–14.
- Durham PL, Russo AF. Differential regulation of mitogen-activated protein kinase-responsive genes by the duration of a calcium signal. *Mol Endocrinol* 2000;14:1570–82.



- 25 Li YJ, Song QJ, Xiao J. Calcitonin gene-related peptide: An endogenous mediator of preconditioning. *Acta Pharmacol Sin* 2000;21:865–9.
- 26 Rittenhouse PA, Marchand JE, Chen J, Kream RM, Leeman SE. Streptozotocin-induced diabetes is associated with altered expression of peptide-encoding mRNAs in rat sensory neurons. *Peptides* 1996;17:1017–22.
- 27 Dobretsov M, Hastings SL, Stimers JR, Zhang JM. Mechanical hyperalgesia in rats with chronic perfusion of lumbar dorsal root ganglion with hyperglycemic solution. *J Neurosci Methods* 2001;110:9–15.
- 28 Brewster WJ, Fernyhough P, Diemel LT, Mohiuddin L, Tomlinson DR. Diabetic neuropathy, nerve growth factor and other neurotrophic factors. *Trends Neurosci* 1994;17:321–5.
- 29 Zheng H, Fan W, Li G, Tam T. Predictors for erectile dysfunction among diabetics. *Diabetes Res Clin Pract* 2006;71:313–9.
- 30 Tomlinson DR, Fernyhough P, Diemel LT. Role of neurotrophins in diabetic neuropathy and treatment with nerve growth factors. *Diabetes* 1997;46(suppl 2):S43–9.
- 31 Bivalacqua TJ, Champion HC, Abdel-Mageed AB, Kadowitz PJ, Hellstrom WJ. Gene transfer of prepro-calcitonin gene-related peptide restores erectile function in the aged rat. *Biol Reprod* 2001;65:1371–7.
- 32 He SH, Wei AY, Ye TY, Yang Y, Luo XG, Liu Y, Zhang T. Calcitonin gene-related peptide induces phenotypic transformation of corpus cavernosum smooth muscle cells in diabetic rats with erectile dysfunction. *Zhonghua Nan Ke Xue* 2011;17:913–7.
- 33 Yorek MA, Coppey LJ, Gallett JS, Davidson EP. Sensory nerve innervation of epineurial arterioles of the sciatic nerve containing calcitonin gene-related peptide: Effect of streptozotocin-induced diabetes. *Exp Diabetes Res* 2004;5:187–93.
- 34 Simopoulos DN, Gibbons SJ, Malysz J, Szurszewski JH, Farrugia G, Ritman EL, Moreland RB, Nehra A. Corporeal structural and vascular micro architecture with X-ray micro computerized tomography in normal and diabetic rabbits: Histopathological correlation. *J Urol* 2001;165:1776–82.
- 35 Burchardt T, Burchardt M, Karden J, Buttyan R, Shabsigh A, de la Taille A, Ng PY, Anastasiadis AG, Shabsigh R. Reduction of endothelial and smooth muscle density in the corpora cavernosa of the streptozotocin induced diabetic rat. *J Urol* 2000;164:1807–11.
- 36 Obrosova IG, Drel VR, Oltman CL, Mashtalir N, Tibrewala J, Groves JT, Yorek MA. Role of nitrosative stress in early neuropathy and vascular dysfunction in streptozotocin-diabetic rats. *Am J Physiol Endocrinol Metab* 2007;293:E1645–55.
- 37 Davidson EP, Kleinschmidt TL, Oltman CL, Lund DD, Yorek MA. Treatment of streptozotocin-induced diabetic rats with AVE7688, a vasopeptidase inhibitor: Effect on vascular and neural disease. *Diabetes* 2007;56:355–62.
- 38 Pacher P, Obrosova IG, Mabley JG, Szabo C. Role of nitrosative stress and peroxynitrite in the pathogenesis of diabetic complications. Emerging new therapeutical strategies. *Curr Med Chem* 2005;12:267–75.
- 39 Nangle MR, Cotter MA, Cameron NE. Effects of the peroxynitrite decomposition catalyst, FeTMPyP, on function of corpus cavernosum from diabetic mice. *Eur J Pharmacol* 2004;502:143–8.
- 40 Bozkurt NB, Pekiner C. Impairment of endothelium- and nerve-mediated relaxation responses in the cavernosal smooth muscle of experimentally diabetic rabbits: Role of weight loss and duration of diabetes. *Naunyn Schmiedebergs Arch Pharmacol* 2006;373:71–8.
- 41 Owens GK, Kumar MS, Wamhoff BR. Molecular regulation of vascular smooth muscle cell differentiation in development and disease. *Physiol Rev* 2004;84:767–801.
- 42 Wei AY, He SH, Zhao JF, Liu Y, Liu Y, Hu YW, Zhang T, Wu ZY. Characterization of corpus cavernosum smooth muscle cell phenotype in diabetic rats with erectile dysfunction. *Int J Impot Res* 2012;24:196–201.
- 43 Gupta S, Moreland RE, Pabby A. Diabetes-induced structural changes in rabbit corpus cavernosum. *Int J Impot Res* 1996;8:136.
- 44 Zhou F, Li G-Y, Gao Z-Z, Liu J, Liu T, Li W-R, Cui WS, Bai GY, Xin ZC. The TGF- $\beta$ 1/Smad/CTGF pathway and corpus cavernosum fibrous-muscular alterations in rats with streptozotocin-induced diabetes. *J Androl* 2011;33:651–9.