

# Arthroscopic Fixation Technique for Avulsion Fracture of the Posterior Cruciate Ligament From the Tibia



Hiroyuki Kan, M.D., Ph.D., Shuji Nakagawa, M.D., Ph.D., Manabu Hino, M.D., Shintaro Komaki, M.D., Yuji Arai, M.D., Ph.D., Hiroaki Inoue, M.D., Ph.D., and Kenji Takahashi, M.D., Ph.D.

**Abstract:** This study describes an arthroscopic pullout fixation technique for small and comminuted avulsion fractures of the posterior cruciate ligament from the tibia. Intra-articular surgery required 3 arthroscopic portals, the anterolateral, anteromedial, and posteromedial portals. To simplify surgery, the posterolateral portal was omitted. A 2.4-mm K-wire was inserted through the anterior incision to the center of the bone fragment. This central guidewire was subsequently overdrilled with a 4.0-mm cannulated drill. The fixation material consisted of Pass Telos artificial ligaments inserted through the fiber loop of a fixed suspensory device such as RIGIDLOOP. The leading end of the thread of the RIGIDLOOP was pulled out through the anteromedial portal. The button of RIGIDLOOP was gradually advanced through the bone tunnel. The button was pulled out and flipped over the bony fragment. The artificial ligament was pulled distally to reduce the bony fragment, and fixed onto the tibia using a ligament button while applying anterior drawer force to the proximal tibia with the knee flexed at 90°. This minimally invasive procedure was successful in treating small and comminuted avulsion fracture of the tibial attachment of the posterior cruciate ligament.

Surgical reduction and fixation of the fragment have yielded better results than conservative therapy in the treatment of avulsion fractures of the posterior cruciate ligament (PCL) from the tibia.<sup>1</sup> Until recently, surgical reattachment frequently has involved posterior approaches to the fracture site.<sup>2</sup> These approaches, however, require large skin incisions to avoid damage to the popliteal neurovascular structures that are

located immediately behind the site and are therefore difficult to remove. Arthroscopic methods, however, are both safe and less invasive than posterior repair approaches. Although several procedures for arthroscopic suture fixation of bony fragments have been described,<sup>3</sup> these procedures are technically complicated and anatomically unfamiliar even to experienced knee surgeons. This study describes an arthroscopic pullout fixation technique for avulsion fractures of the PCL from the tibia without the need for any complicated surgical techniques.

## Indications

This method has been found to be suitable for patients with large bone fragments and few dislocations, as well as for patients with no dislocations if early rehabilitation is required. Because the bone hole must be created with a 4.0-mm drill, this method is not indicated for patients with small bone fragments or crushing. Computed tomography (CT) scanning before surgery is required to assess the extent of dislocation and the size of bone fragments, as other surgical procedures may be optimal, including the pull-out technique<sup>4</sup> if the bone fragments are crushed, or the Burks approach<sup>2</sup> if the dislocation is very large (Table 1).

From the Department of Orthopaedics, Kyoto Interdisciplinary Institute Hospital of Community Medicine (H.K., M.H., S.K.); Department of Sports and Para-Sports Medicine, Graduate School of Medical Science, Kyoto Prefectural University of Medicine (S.N., Y.A.); and Department of Orthopaedics, Graduate School of Medical Science, Kyoto Prefectural University of Medicine (H.I., K.T.), Kyoto, Japan.

The authors report that they have no conflicts of interest in the authorship and publication of this article. Full ICMJE author disclosure forms are available for this article online, as [supplementary material](#).

Received May 24, 2020; accepted August 6, 2020.

Address correspondence to Yuji Arai, M.D., Ph.D., Department of Sports and Para-Sports Medicine, Graduate School of Medical Science, Kyoto Prefectural University of Medicine, 465 Kawaramachi-Hirokoji, Kamigyo-ku, Kyoto 602-8566, Japan. E-mail: [y123arai@koto.kpu-m.ac.jp](mailto:y123arai@koto.kpu-m.ac.jp)

© 2020 by the Arthroscopy Association of North America. Published by Elsevier. This is an open access article under the CC BY-NC-ND license (<http://creativecommons.org/licenses/by-nc-nd/4.0/>).

2212-6287/20919

<https://doi.org/10.1016/j.eats.2020.08.006>

**Table 1.** Pearls of the Arthroscopic Fixation Technique for Avulsion Fracture of PCL

1. This surgical procedure is indicated for patients with large bone fragments and few dislocations.
2. CT before surgery was required to assess the extent of the dislocation and bone size.
3. If a bone fragment is floating, it is held down with an angle guide to reduce it, followed by insertion of a guidewire.

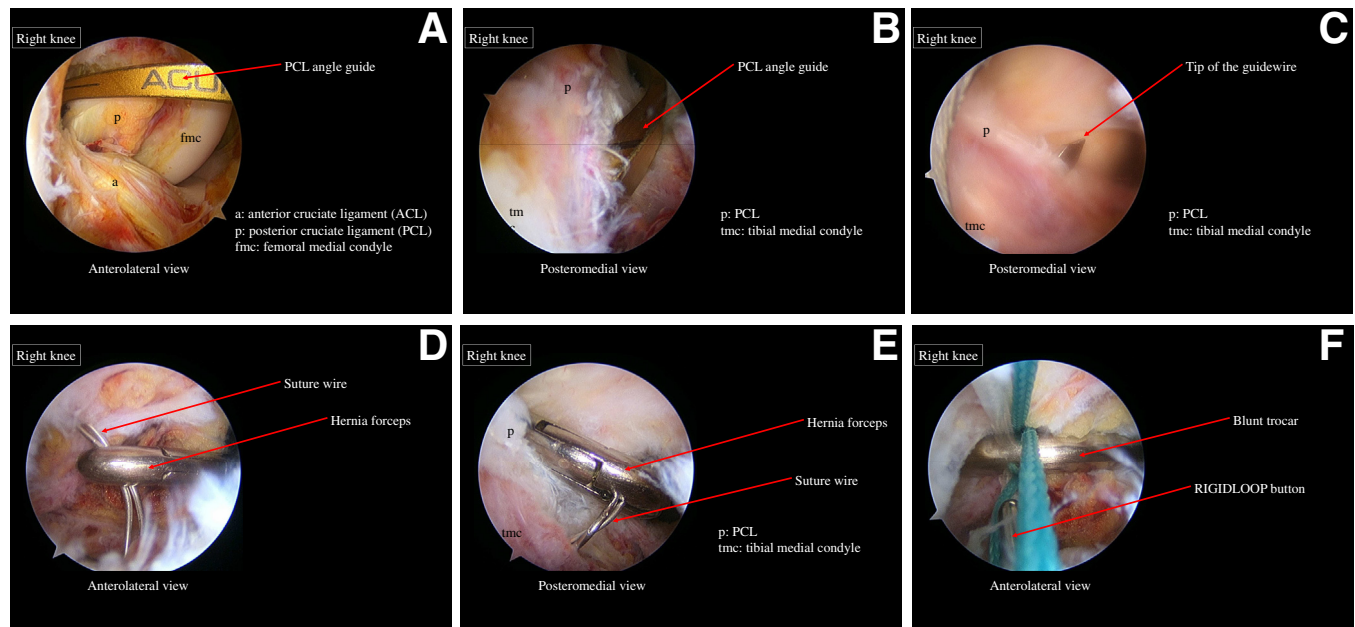
CT, computed tomography; PCL, posterior cruciate ligament.

### Surgical Technique (With Video Illustration)

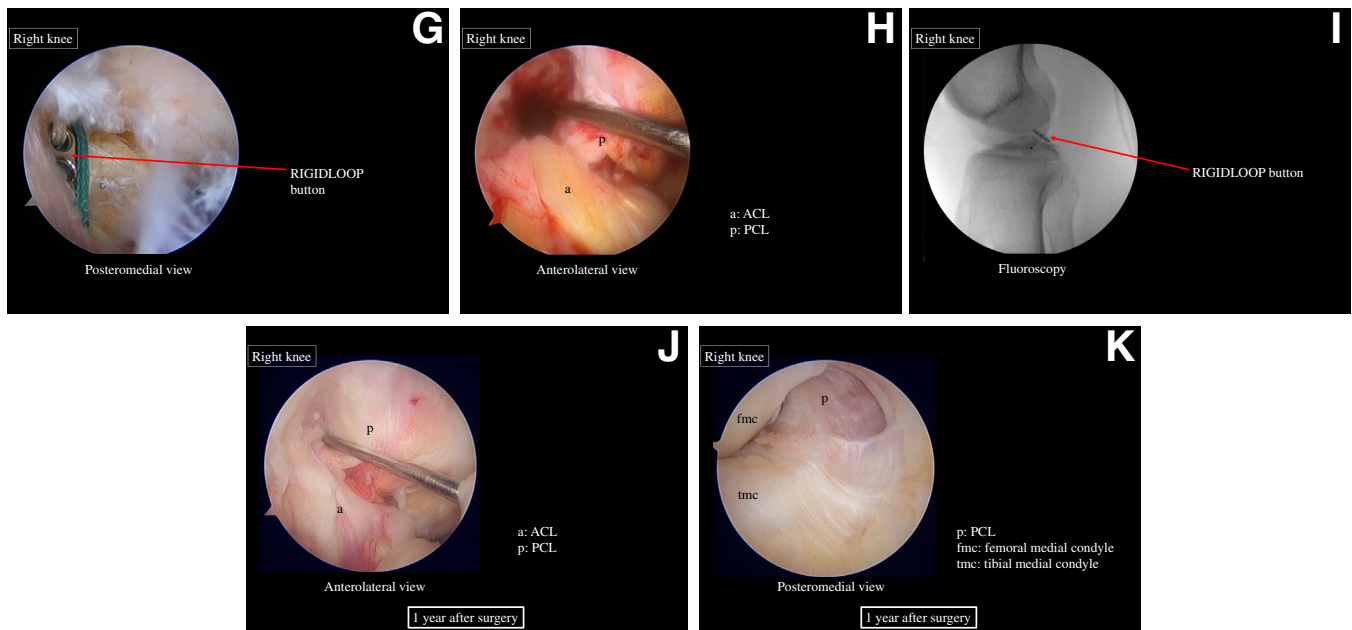
The patient is placed in the supine position under general anesthesia. With a leg holder, the knee is flexed at 90° during surgery, a position that relaxes the posterior structures and avoids neurovascular injury.<sup>5</sup> Three arthroscopic portals are created, the anterolateral, anteromedial, and posteromedial portals, whereas the posterolateral portal is omitted (Video 1). The anteromedial and anterolateral portals are positioned just medial and lateral to the medial and lateral borders of the patellar tendon, enabling easier access to the posterior compartment. The entire joint is thoroughly examined

through the anterolateral and anteromedial portals, and associated lesions are treated arthroscopically. The fat pads and synovium are dissected to ensure a visual field through the anterolateral portal. The scope is gently inserted from the anteromedial or anterolateral portal, through the space between the PCL and medial femoral condyle, and advanced into the posteromedial compartment. If this procedure is difficult, a blunt trocar is inserted in a sheath from the anteromedial portal into the posteromedial compartment while viewing through the anterolateral portal. The trocar in the sheath is replaced with the arthroscope to visualize the posteromedial compartment.

Under direct visualization, a 23-gauge spinal needle is inserted percutaneously into the posteromedial compartment at the joint level to determine the location of the posteromedial portal. The posteromedial portal is made using an outside-in technique, and the sheath is inserted through this portal. With the surgeon viewing through the anterolateral portal, the synovial membrane between the anterior cruciate ligament (ACL) and the PCL of the intercondylar fossa is dissected. The arthroscope in the sheath is gently inserted from the anterolateral portal, through the



**Fig 1.** Surgical procedure. Anterolateral (A) and (B) posteromedial views showing insertion of a tibial PCL guide through the ACL and PCL into the center of the bony fragment, followed by reduction of the avulsion fracture under direct arthroscopic visualization. (C) Posteromedial view showing insertion of a 2.4-mm guidewire toward the center of the bony fragment. (D) Anterolateral view showing the area between the ACL and the PCL. The suture wire was bent upwards with a hernia forceps inserted from the posteromedial portal. (E) Posteromedial view showing insertion of a hernia forceps from the anteromedial portal through the space between the ACL and PCL. The forceps subsequently grabbed the tip of the suture wire and pulled it out through the anteromedial portal. (F) Anterolateral view showing gradual pulling of the RIGIDLOOP button with a blunt trocar inserted through the posteromedial portal. (G) Posteromedial view showing flipping of the RIGIDLOOP button over the bony fragment. Arthroscopic (H: Anterolateral view) and fluoroscopic (I) confirmation of the reduction and fixation of the fragment after tying the ligament. Anterolateral (J) and (K) posteromedial views showing removal of the fixation device and performance of arthroscopy 1-2 years after surgery. (a, ACL; ACL, anterior cruciate ligament; fmc, femoral medial condyle; p, PCL; PCL, posterior cruciate ligament; tmc, tibial medial condyle.)



**Fig 1.** Continue

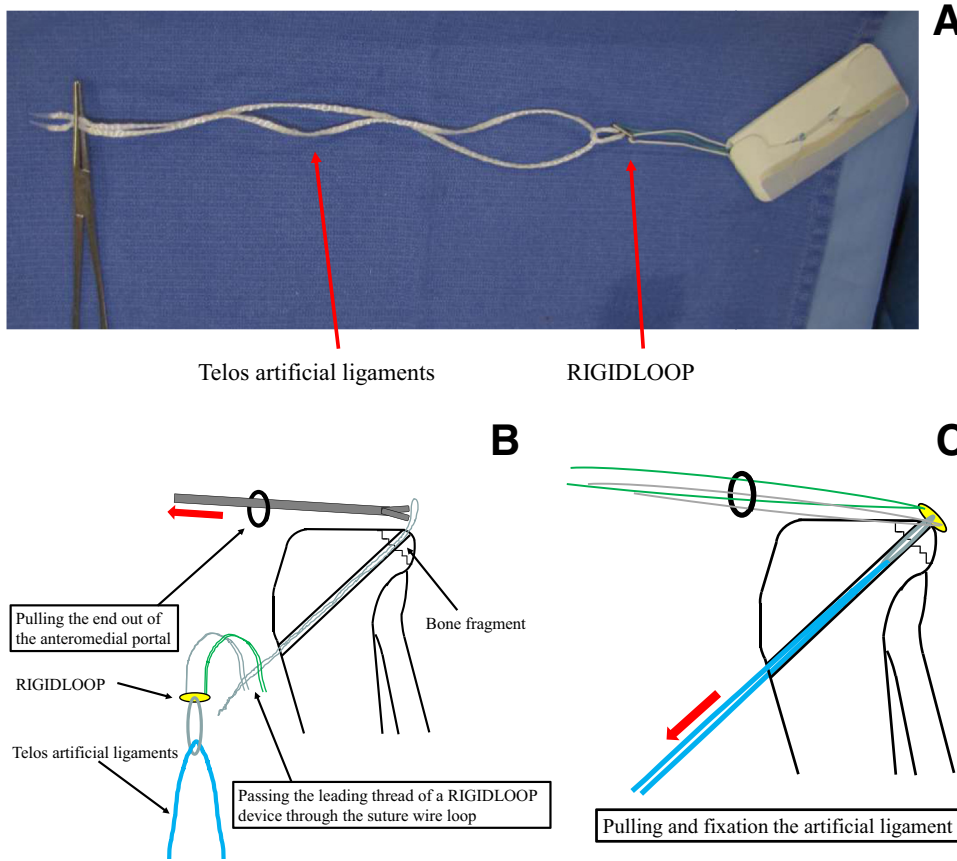
space between the ACL and PCL, and into the posteromedial compartment. A shaver is inserted through the posteromedial portal to remove hematomas and synovia behind the avulsed fragments. Use of a 70° arthroscope during this step provides a better visual field. Under arthroscopic view from both portals, the sizes and thicknesses of the avulsed fragments are carefully ascertained using a blunt trocar or probe. Blood clots and soft tissue located between the fracture site and the posterior capsule are debrided using a motorized shaver through the posteromedial portal until the avulsed fragment and tibial bony bed are clearly released from the posterior capsule. While shaving around the fragment, particular care is taken to avoid injuring the PCL and bony fragment. The medial wall of the posterior septum requires partial shaving during the process, but complete perforation of the septum is not necessary.

If the fracture does not extend to the lateral side of the tibia, the posterior septum can be dissected from the tibia, the posterior septum can be dissected from the posteromedial portal. A tibial PCL guide (Smith & Nephew, Andover, MA) is inserted between the ACL and PCL in the center of the bony fragment, as determined by direct arthroscopic visualization (Fig 1 A and B). A 2-cm longitudinal incision is made just medial and 3 cm distal to the tibial tubercle. A 2.4-mm guidewire is inserted into the center of the bony fragment (Fig 1C). If a bone fragment is floating, it is held down with an angle guide to reduce it, followed by insertion of a guidewire. Guidewire placement is confirmed fluoroscopically, followed by appropriate fine-tuning, if required. The position of the wire is confirmed arthroscopically through the anterolateral and posteromedial portals. To avoid damage to the posterior neurovascular bundle, the tip of

the guidewire is covered with a protector inserted through the posteromedial portal, and the tip is overdrilled with a 4.0-mm cannulated drill. The angle and the distance from the puncture site point to the PCL attachment is determined by CT or magnetic resonance imaging before surgery.

A 0.55-mm stainless suture wire is folded to make a loop and introduced into the posteromedial compartment via the bone tunnel. This wire is bent upwards with a forceps inserted into the posteromedial portal (Fig 1 D). A forceps, inserted through the anteromedial portal between the ACL and PCL from anteromesial portal, is used to grab the tip of the looped wire and pull it out from the anteromedial portal (Fig 1E).

The fixation material consists of Pass Telos artificial ligaments (Aimedic MMT, Tokyo, Japan) inserted through the fiber loop of a fixed suspensory device such as RIGIDLOOP (DePuy Synthes Mitek, Raynham, MA) (Fig 2A). The leading end of the thread of the RIGIDLOOP is passed through the suture wire loop, relayed, and pulled out through the anteromedial portal (Fig 2B). The button of RIGIDLOOP is gradually advanced through the bone tunnel by pulling the green and white suture using a blunt trocar inserted from the posteromedial portal (Fig 1F). The button is pulled out and flipped over the bony fragment (Fig 1G). The artificial ligament is pulled distally to reduce the bony fragment and fixed onto the tibia using a Ligament button (KYOCERA, Kyoto, Japan) while applying anterior drawer force to the proximal tibia with the knee flexed at 90° (Fig 2C). After the ligament is tied, reduction and fixation of the fragment are confirmed arthroscopically and fluoroscopically (Fig 1 H and I).



**Fig 2.** (A) Passage of Telos artificial ligaments through the fiber loop of a fixed suspensory device, such as RIGIDLOOP, used as a fixing material. (B) Passage of the leading thread of a RIGIDLOOP device through the suture wire loop, followed by relay of the thread and pulling its end out of the anteromedial portal. (C) Pulling and fixation of the artificial ligament onto the tibia using a Ligament button (KYOCERA) while applying anterior drawer force to the proximal tibia with the knee flexed at 90°.

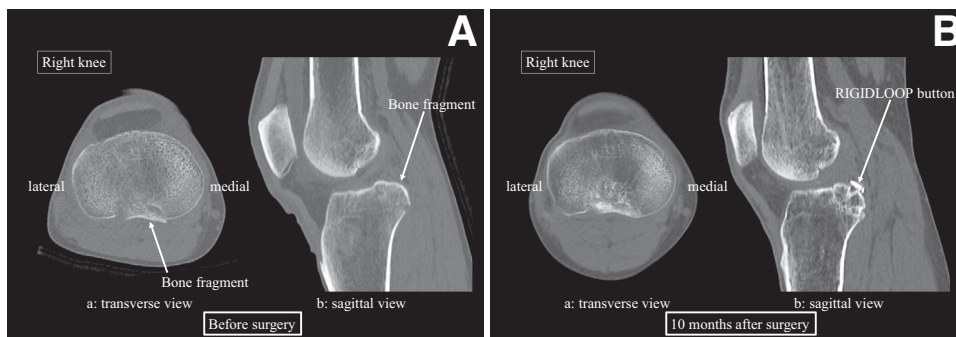
**Postoperative Therapy**

Isometric exercises to strengthen the quadriceps muscle are started 2 days postoperatively. Partial weight bearing is initiated after 2 weeks of postoperative non-weight bearing exercises, with full-weight bearing initiated 4 weeks after surgery. Range of motion exercises are performed without restrictions. Radiographs and CT imaging are performed 3 to 6 months later to confirm bone union (Fig 3), after which patients are

allowed to return to their job and play sports without any restrictions. One to two years after surgery, the fixation device is removed and arthroscopy is performed (Fig 1 J and K).

**Discussion**

The described procedure is simple to perform and does not require any special equipment. A posterior incision is not required, allowing surgery to be



**Fig 3.** (A) Preoperative CT images (a, transverse view, b, sagittal view) showing a thin avulsed fragment of the posterior cruciate ligament arising from the tibial attachment. (B) CT images at 10 months after surgery (a, transverse view, b, sagittal view) showing that the fragment was well reduced to the tibial attachment and bone union was achieved. (CT, computed tomography).



**Table 2.** Benefits and Limitations of the Procedure

Benefits
1. A posterolateral portal is unnecessary.
2. No specific instruments are required.
3. Uses thick artificial ligaments, leading to stronger reduction and fixation.
Limitations
1. Not indicated for patients with small or crushed bone fragments, or those with large dislocations.
2. Large dislocated fragments are difficult to reconstruct.
3. The PCL reconstruction technique is required.

PCL, posterior cruciate ligament.

performed with only 3 portals, omitting the posterolateral portal. The use of a thick artificial ligament allows for more effective reduction and fixation of bone fragments than previously reported procedures.

Treatment of avulsion fractures of the PCL depends on the degree of avulsion fracture displacement. Conservative therapy is generally performed if the degree of avulsion fracture displacement is mild, whereas surgery is performed in patients with marked displacement and tibial posterior instability.<sup>6</sup> Internal fixation by surgery results in faster postoperative therapy and better outcomes than conservative therapy. Surgery has been recommended even for patients with relatively mild displacement.

In the past, internal fixation was highly invasive, requiring marked opening of the back of the knee. A posterior approach to open reduction and internal fixation of PCL avulsion fractures was found to be effective in fractures involving large dislocations.<sup>2</sup> However, this method is highly invasive with a risk of neurovascular damage. Moreover, the fixation material was difficult to remove.

Recent developments in instruments and techniques for arthroscopic surgery have enabled minimally invasive surgery. For example, arthroscopic fixation using a special forceps guide on avulsion fractures of the PCL in cadaveric knees was first reported in 1988.<sup>6</sup> A subsequent study reported arthroscopic fixation with 4.5-mm cannulated screws, followed by the use of screws, K-wires, and suture wires/threads.<sup>7</sup>

Large bone fragments can be reduced and fixed with screws or K-wires in an anterograde or retrograde manner. Alternatively, these fragments can be reduced and fixed using suture anchors. Direct fixation of small and thin or comminuted fragments to the bone bed, however, is difficult, as the suture wire/thread cannot be pulled out to the anterior side of the tibia for reduction and fixation of the fragment.<sup>3</sup> In particular, arthroscopic surgery using a pullout procedure requires accurate examination and visualization of the fragment and bone bed, as well as the ability to pull the fixation wire/thread from the posterior to the anterior side of the fragment.

An excellent arthroscopic view was obtained by insertion through a posterolateral portal and the creation of a transseptal portal, resulting from the dissection of the posterior septum that separates the posterior joint space into medial and lateral compartments.<sup>3</sup> The center of the posterior septum did not contain significant amounts of tissue,<sup>8</sup> but there were interindividual variations in angiogenesis, suggesting that the creation of posterolateral and trans-septal portals can damage neurovascular bundles.<sup>4</sup>

Arthroscopic fixation using a suspensory fixation device was found to require only anteromedial, anterolateral, and posteromedial portals, without the need for a posterolateral portal.<sup>4,9,10</sup> An arthroscopic fixation technique for avulsion fractures of the PCL with a small or comminuted fragment was found to require drilling a 2-mm hole in the tibia,<sup>4</sup> a surgical procedure that was convenient and less invasive than previous methods. The bone hole was made with a 2-mm K wire, allowing its use for small and shattered bone fragments. However, it requires a skilled and special surgical technique, in which 2 wires are inserted into only the medial and lateral borders of the bony fragment.

The present study describes our developed arthroscopic fixation technique for avulsion fractures of the PCL involving only the posteromedial compartment. This surgical procedure requires only 3 portals: one anteromedial, one anterolateral, and one posteromedial portal. A posterior approach is required, but a posterolateral portal and posterior septum resection are not, avoiding the risk of neurovascular bundle damage. This technique can be performed using instruments and devices commonly used in ligament reconstruction, without any special equipment. Only one bone hole is needed, and no special techniques are required. In addition, this technique uses Telos artificial ligaments 2.5-mm in width, leading to stronger reduction and fixation. This surgical procedure is thus convenient and less invasive while providing more secure fixation than previously described methods (Table 2).

## Acknowledgments

We thank Dr. Yoshikazu Kida for narrating the video.

## References

1. Song Jae-Gwang, Nha Kyung-Wook, Lee Se-Won. Open posterior approach versus arthroscopic suture fixation for displaced posterior cruciate ligament avulsion fractures: Systematic review. *Knee Surg Relat Res* 2018;30:275-283.
2. Hooper PO 3rd, Bevan PJ, Silko C, Farrow LD. A posterior approach to open reduction and internal fixation of displaced posterior cruciate ligament tibial osseous avulsions. *JBJS Essent Surg Tech* 2018;8:e6.
3. Kim SJ, Shin SJ, Choi NH, Cho SK. Arthroscopically assisted treatment of avulsion fractures of the posterior

- cruciate ligament from the tibia. *J Bone Joint Surg Am* 2001;83:698-708.
4. Nakagawa S, Arai Y, Hara K, Inoue H, Hino M, Kubo T. Arthroscopic pullout fixation for a small and comminuted avulsion fracture of the posterior cruciate ligament from the tibia. *Knee Surg Relat Res* 2017;29:316-320.
  5. Matava MJ, Sethi NS, Totty WG. Proximity of the posterior cruciate ligament insertion to the popliteal artery as a function of the knee flexion angle: Implications for posterior cruciate ligament reconstruction. *Arthroscopy* 2000;16:796-804.
  6. Sasaki SU, da Mota e Albuquerque RF, Amatuzzi MM, Pereira CA. Open screw fixation versus arthroscopic suture fixation of tibial posterior cruciate ligament avulsion injuries: A mechanical comparison. *Arthroscopy* 2007;23:1226-1230.
  7. Martinez-Moreno JL, Blanco-Blanco E. Avulsion fractures of the posterior cruciate ligament of the knee: An experimental percutaneous rigid fixation technique under arthroscopic control. *Clin Orthop Relat Res* 1988;237:204-208.
  8. Ahn JH, Ha CW. Posterior trans-septal portal for arthroscopic surgery of the knee joint. *Arthroscopy* 2000;16:774-779.
  9. Gwinner C, Kopf S, Hoburg A, Haas NP, Jung TM. Arthroscopic treatment of acute tibial avulsion fracture of the posterior cruciate ligament using the tightrope fixation device. *Arthrosc Tech* 2014;3:e377-e382.
  10. Gwinner C, Hoburg A, Wilde S, Schatka I, Krapohl BD, Tobias Jung TM. All-arthroscopic treatment of tibial avulsion fractures of the posterior cruciate ligament. *GMS Interdiscip Plast Reconstr Surg DGPW* 2016;5:Doc02.